



A SYSTEM OF
OPERATIVE
SURGERY

EDITED BY
F. F. BURGHARD

OXFORD MEDICAL
PUBLICATIONS







Digitized by the Internet Archive
in 2007 with funding from
Microsoft Corporation

OXFORD MEDICAL PUBLICATIONS

A SYSTEM OF
OPERATIVE SURGERY

OXFORD : HORACE HART
PRINTER TO THE UNIVERSITY

MS.
B.

OXFORD MEDICAL PUBLICATIONS

A
SYSTEM
OF
OPERATIVE SURGERY

BY VARIOUS AUTHORS

EDITED BY

F. F. BURGHARD, M.S. (LOND.), F.R.C.S. (ENG.)

TEACHER OF OPERATIVE SURGERY IN KING'S COLLEGE, LONDON

SURGEON TO KING'S COLLEGE HOSPITAL

SENIOR SURGEON TO THE CHILDREN'S HOSPITAL, PADDINGTON GREEN

IN FOUR VOLUMES

VOL. I

THE PRINCIPLES AND TECHNIQUE OF WOUND TREATMENT
THE METHODS OF LOCAL ANALGESIA

AMPUTATIONS

OPERATIONS UPON ARTERIES, VEINS, AND LYMPHATICS

OPERATIONS UPON NERVES

OPERATIONS UPON MUSCLES, TENDONS, TENDON SHEATHS, AND BURSAE

OPERATIONS FOR NON-TUBERCULOUS AFFECTIONS OF BONES AND JOINTS
PLASTIC SURGERY

LONDON

HENRY FROWDE
OXFORD UNIVERSITY PRESS

HODDER & STOUGHTON
WARWICK SQUARE, E.C.

1909

1265-04
28/2/13

EDITOR'S PREFACE

GR^{EAT} as have been the advances made in Surgery during the last fifteen years, there is no direction in which they have been more noticeable than in the elaboration of those comparatively small but important details of operative technique which do so much to ensure a low mortality and a successful result.

These improvements have been developed simultaneously throughout the whole of the vast field covered by modern Surgery, and it has become increasingly difficult for any single writer to deal with such an important subject as Operative Surgery in an authoritative and efficient manner. The scope of the subject is so wide that it is difficult to ensure that the work when published shall be thoroughly up to date, while a second and even greater difficulty is for any one, however great his ability and experience, to deal equally exhaustively and authoritatively with all of the many branches of which he would have to treat.

To avoid both of these difficulties and thus to make sure that the work shall reflect faithfully the present position of British Operative Surgery, the plan has been adopted of securing the co-operation of a number of prominent British Surgeons. Each writer deals with a branch of the subject in which he has had special experience, and upon which, therefore, he is entitled to speak with authority.

Besides the two important points just referred to, a third equally important one has been kept in view throughout. Particular care has been taken to make the work of as much practical utility to the reader as possible. Not only are the various operations described in the fullest detail and with special

reference to the difficulties and dangers and the best methods of overcoming and avoiding them, but the indications for the individual operations are described at length, and the after-treatment and results receive adequate notice.

It is therefore hoped that the work will be useful alike to those who are about to operate for the first time, and to those surgeons of experience who desire to keep themselves informed as to the progress that has been made in the various branches of Operative Surgery.

The division of the work into a number of sections each written by a different author, necessarily involves some overlapping of subjects and some diversity of opinion upon points of technique. Efforts have been made to prevent overlapping of subjects as far as possible by care in their distribution and by conference between the authors concerned, but no attempt has been made to harmonize conflicting views. Each author supports his individual opinions by the weight of his authority, and any discrepancies may be taken to represent the absence of unanimity on various minor points that is well known to exist among surgeons of all countries.

The task of editing a work contributed to by so many writers might well appear to be an onerous one, but, owing to the promptitude, courtesy, and forbearance of all concerned, it has been a source of great pleasure, and the Editor's most cordial thanks are tendered to all those who have devoted so much time and trouble to the work.

PREFACE TO VOLUME I

PRESSURE of circumstances has necessitated the separation of the Sections dealing with the Operations upon Bones and Joints into two parts, viz. those upon Non-tuberculous and those upon Tuberculous affections. Of these the former appears in Vol. I and the latter will appear in Vol. II; between the two comes Plastic Surgery, which was originally intended to follow the latter.

Special thanks are due to Mr. J. Keogh Murphy for much valuable help in seeing the volume through the Press. Thanks are also due to Mr. Barker for the loan of several blocks illustrating Spinal Analgesia and his method of wiring the patella, and to Messrs. Allen & Hanburys, who have kindly placed their collection of illustrations of instruments at the disposal of the Editor. Some of the blocks illustrating Spinal Analgesia have been kindly lent by the *Journal of the Royal Army Medical Corps*. A few of the figures appearing in the section dealing with Plastic Surgery have been modified from Cheyne and Burghard's *Manual of Surgical Treatment* by permission of the authors.

To the several artists concerned in the production of the illustrations—nearly all of which are from original preparations or sketches—the Editor is much indebted for the skill they have shown and for the rapidity with which they have executed the work. Mr. Butterworth in particular has rendered invaluable assistance in this respect.

CONTRIBUTORS TO THIS VOLUME

C. B. LOCKWOOD, F.R.C.S. (Eng.)

Surgeon to St. Bartholomew's Hospital

The Principles and Technique of Wound
Treatment

CAPTAIN J. W. H. HOUGHTON, R.A.M.C.

The Methods of Local Analgesia

FRED^C. F. BURGHARD, M.S. (Lond.), F.R.C.S. (Eng.)

*Teacher of Operative Surgery in King's College, London;
Surgeon to King's College Hospital; and Senior Surgeon
to the Children's Hospital, Paddington Green*

Amputations

Operations upon Arteries, Veins, and Lymphatics

Operations upon Nerves

Operations upon Muscles, Tendons, Tendon Sheaths,
and Bursæ

Operations for Non-Tuberculous Affections of the
Bones and Joints

T. P. LEGG, M.S. (Lond.), F.R.C.S. (Eng.)

Surgeon to the Royal Free Hospital

Plastic Surgery

CONTENTS

SECTION I

THE PRINCIPLES AND TECHNIQUE OF WOUND TREATMENT

By C. B. LOCKWOOD, F.R.C.S. (Eng.)

Surgeon to St. Bartholomew's Hospital.

CHAPTER I

INTRODUCTION

	PAGES
Scientific Tests, 4. Medical Education and Asepsis, 5	3-5

CHAPTER II

AIR INFECTION: OPERATING THEATRES

Air Infection, 6. Operating Theatres, 8	6-11
---	------

CHAPTER III

STERILIZATION

Sterilization of Instruments, 12; of Dressings, Bandages, Swabs, Garments, and Towels, 12; of Silk and Silkworm-gut, 12; of Catgut, 14; of Marine Sponges and Swabs, 14. Costume for operating, 15. Gloves, 16. Ward Units and Asepsis, 16	12-16
--	-------

CHAPTER IV

CONTACT INFECTION

Disinfection of the Hands, 17. Disinfection of the Patient's Skin, 19. The use of Chemicals, 21	17-23
---	-------

CHAPTER V

DRAINAGE OF WOUNDS: TREATMENT OF INFECTED WOUNDS

Drainage, 24. Methods of operating and Asepsis, 25. The Organization of Operations, 26. Treatment of Infected Wounds, 28.	24-28
---	-------

SECTION II

THE METHODS OF LOCAL ANALGESIA

By CAPTAIN J. W. H. HOUGHTON, R.A.M.C.

CHAPTER I

INFILTRATION AND REGIONAL ANALGESIA	PAGES 31-39
---	----------------

CHAPTER II

SPINAL ANALGESIA	40-60
----------------------------	-------

SECTION III

AMPUTATIONS

By FRED^c. F. BURGHARD, M.S. (Lond.), F.R.C.S. (Eng.)

Teacher of Operative Surgery in King's College, London; Surgeon to King's College Hospital; and Senior Surgeon to the Children's Hospital, Paddington Green.

CHAPTER I

INDICATIONS: DANGERS: GENERAL PRINCIPLES: PRINCIPAL METHODS OF CONTROLLING HÆMORRHAGE: AND THE PRINCIPLES OF OPERATING

Varieties, 63. Indications, 64; *Cases in which Amputation is always required*, 64; *Cases in which Amputation is only occasionally required*, 65. Dangers, 68; *Shock as influencing the time of Amputation*, 69; *Hæmorrhage*, 71; *Sepsis*, 71. General Principles underlying Amputations, 71; Amputation *v.* Conservative Treatment, 72. The particular form that the Amputation shall take, 72. The characters of a good Stump, 73. The characters of a faulty Stump, 75. Conical Stump, 76. Methods of controlling Hæmorrhage, 77. Methods of fashioning Flaps, 82. Factors influencing the Surgeon's choice of Methods, 84. Methods of raising the Flaps, 85; *how to hold the Knife*, 86; *Retractors*, 89. Division of the Bone, 89. The arrest

	PAGES
of Hæmorrhage and closure of the Wound, 93. Drainage, 93. The Method of immobilizing the Limb, 94. The future of the Stump, 94. Mortality, 95	63-95

AMPUTATIONS IN THE UPPER EXTREMITY

CHAPTER II

AMPUTATIONS OF THE HAND AND WRIST

Amputations of the Fingers, 96; *Surgical Anatomy*, 96. Disarticulation at the Terminal Inter-phalangeal Joint, 97. Amputation through one of the Phalanges—*by a single long Palmar Flap*, 101; *by Antero-posterior Flaps*, 101; *by Lateral Flaps*, 101; *by a large Internal or External Flap*, 101. Disarticulation at the Metacarpo-phalangeal Articulations, 101; *Surgical Anatomy*, 102. *Amputation by the Circular Racket Incision*, 103; *by an oblique Racket Incision*, 104; *by a single large Lateral Flap (Farabeuf's Amputation)*, 106. Amputation of the Thumb, 107; *by an Elliptical Incision*, 107. Amputation of a Digit with its Metacarpal Bone, 109; *Amputation of the Thumb with its Metacarpal Bone*, 109. *Amputation of a Finger with its corresponding Metacarpal Bone*, 112. *Amputation of more than one Finger with their corresponding Metacarpal Bones*, 114. Disarticulation at the Wrist-joint, 116; *by a Circular Incision*, 116; *by an Elliptical Incision*, 117; *by a long Palmar Flap*, 118; *by a single External Flap*, 121 96-122

CHAPTER III

AMPUTATIONS OF THE FOREARM AND ELBOW

Amputation through the Forearm, 123; *by the Circular Cuff Method*, 126; *by equal Antero-posterior Flaps*, 129. Disarticulation at the Elbow-joint, 131; *by the Circular Method*, 132; *by an Elliptical Incision*, 134 123-138

CHAPTER IV

AMPUTATIONS THROUGH THE UPPER ARM AND SHOULDER

Amputations through the Upper Arm, 139; *Circular Amputation*, 142; *by Antero-posterior Flaps*, 143; *by a large External Flap*, 145. Disarticulation at the Shoulder-joint, 146; *Spence's Amputation*, 148; *by the Modified Racket Method*, 150 139-152

CHAPTER V

PAGES

INTERSCAPULO-THORACIC AMPUTATION (Removal of the Upper Extremity, together with the Scapula and a portion of the Clavicle) . 153-157

AMPUTATIONS IN THE LOWER EXTREMITY

CHAPTER VI

AMPUTATIONS OF THE FOOT

Amputations of the Great Toe, 158. Disarticulation at the Interphalangeal joint, 158; at the Metatarso-phalangeal Joint, 159; by a large Internal Flap (Farabeuf's Method), 160; by a large square Internal Flap, 162; by the Racket Incision, 163. Disarticulation of the Outer Toes at the Metatarso-phalangeal Joints, 164. Disarticulation through the Tarso-metatarsal Joints, 165; Lisfranc's Operation, 166. Disarticulation at the Medio-tarsal Joint; Chopart's Amputation, 175; Tripiet's Operation, 178. Sub-astragaloid Disarticulations, 178; Farabeuf's Operation, 179; Nélaton's Operation, 187; Roux's Operation, 188; Racket Incision, 188. Disarticulation at the Ankle-joint; Syme's Amputation, 189; Operation by a large Internal Flap, 194; the Racket Method, 196. Trans-calcaneal Amputations; Pirogoff's Amputation, 196; Le Fort's Operation, 199; Gordon Watson's, 200 158-202

CHAPTER VII

AMPUTATIONS OF THE LEG AND KNEE

Amputations through the Leg, 203. Supra-malleolar Amputation; by an oblique Elliptical Incision, 206; by a long Posterior Flap, 209; Amputation through the Middle of the Leg, 212; by a long Posterior and short Anterior Flap (Hey's Amputation), 212; by a single long Anterior Flap (Lister's Operation), 214. Amputation at the 'Seat of Election', 216; by the Circular Method, 217; by equal lateral Skin Flaps, 219; by a large External Flap (Farabeuf's Method), 221. Disarticulation at the Knee-joint, 225; by Stephen Smith's Operation, 225; by an oblique Elliptical Incision, 229. Trans-condyloid and Supra-condyloid Amputations, 231; by long Anterior and short Posterior Flaps, 232; Lister's Modification of Carden's Operation, 233; the Stokes-Gritti Amputation, 235 203-238

CHAPTER VIII

AMPUTATIONS THROUGH THE THIGH AND DISARTICULATIONS
AT THE HIP-JOINT

	PAGES
Amputations through the Thigh, 239; <i>by the Circular Method</i> , 239; <i>by long Anterior and short Posterior Flaps</i> , 241. Disarticulation at the Hip-Joint, 245; <i>Choice of Operation</i> , 246; <i>Methods of controlling Hæmorrhage during the Operation</i> , 246. Furneaux Jordan's Amputation, 249. Amputation by Lateral Flaps—the so-called Anterior Racket Method, 253. Amputation by Transfixion, 257	239-257

SECTION IV

OPERATIONS UPON ARTERIES, VEINS, AND LYMPHATICS

By FRED^C. F. BURGHARD, M.S. (Lond.), F.R.C.S. (Eng.)

Teacher of Operative Surgery in King's College, London; Surgeon to King's College Hospital; and Senior Surgeon to the Children's Hospital, Paddington Green.

CHAPTER I

ARTERIORRHAPHY

Indications, 261; Operation, 262; suturing a Longitudinal Incision, 263; End-to-end Suture, 265	261-265
---	---------

CHAPTER II

ENDO-ANEURYSMORRHAPHY

Indications, 265; Operation, 268; the Obliterative Suture, 271; the Restorative Suture, 273; Obliteration of the Sac, 274; Results, 275	266-277
---	---------

CHAPTER III

OPERATIONS FOR ANEURYSMAL VARIX AND VARICOSE
ANEURYSM

Aneurysmal Varix, 278; Varicose Aneurysm, 279	278-279
---	---------

CHAPTER IV

REVERSAL OF THE SYSTEMIC CIRCULATION IN A LIMB	280-283
--	---------

CHAPTER V

LIGATURE OF ARTERIES

PAGES

General Considerations, 284; Exposure of the Artery, 285; Ligature of the Artery, 287; Difficulties and Dangers, 291; After-treatment, 291	284-292
--	---------

LIGATURE OF THE ARTERIES OF THE LOWER EXTREMITY

CHAPTER VI

LIGATURE OF THE ARTERIES OF THE FOOT AND LEG

Ligature of the Dorsalis Pedis Artery, 293. Ligature of the Anterior Tibial Artery, 295; <i>in the Upper Third</i> , 297; <i>in the Middle Third</i> , 299; <i>in the Lower Third</i> , 301. Ligature of the Posterior Tibial Artery, 302; <i>in the Middle of the Leg</i> , 303; <i>in the Lower Third</i> , 304; <i>behind the Inner Ankle</i> , 305	293-305
--	---------

CHAPTER VII

LIGATURE OF THE ARTERIES OF THE KNEE AND THIGH

Ligature of the Popliteal Artery, 306; <i>from the Inner Aspect of the Thigh</i> , 307; <i>from the Back of the Leg, in the Upper Part of the Popliteal Space</i> , 310; <i>in the Lower Part of the Popliteal Space</i> , 311. Ligature of the Femoral Artery, 313; <i>in Hunter's Canal</i> , 316; <i>at the Apex of Scarpa's Triangle</i> , 318; <i>below Poupart's Ligament (the Common Femoral)</i> , 320	306-323
--	---------

CHAPTER VIII

LIGATURE OF THE ARTERIES OF THE PELVIS

Ligature of the External Iliac Artery, 324; <i>the Extra-peritoneal Operation</i> , 325; <i>Astley Cooper's Operation</i> , 326; <i>the Trans-peritoneal Operation</i> , 329. Ligature of the Internal Iliac (Hypogastric) Artery, 330. Ligature of the Common Iliac Artery, 331. Ligature of the Superior Gluteal Artery, 334. Ligature of the Sciatic (Inferior Gluteal) Artery, 336. Ligature of the Internal Pudic Artery, 337	324-338
--	---------

CHAPTER IX

LIGATURE OF THE ABDOMINAL AORTA

Indications, 339. Operation, 341	339-343
--	---------

LIGATURE OF THE ARTERIES OF THE UPPER EXTREMITY

CHAPTER X

LIGATURE OF THE ARTERIES OF THE HAND AND FOREARM

	PAGES
Ligature of the Radial Artery, 344; <i>in the Upper Third</i> , 346; <i>in the Middle Third</i> , 348; <i>in the Lower Third</i> , 348; <i>in the 'Anatomical Snuff-Box'</i> , 349. Ligature of the Ulnar Artery, 350; <i>in the Lower Third</i> , 350; <i>in the Middle Third</i> , 351; <i>in the Upper Third</i> , 353	344-353

CHAPTER XI

LIGATURE OF THE ARTERIES OF THE UPPER ARM AND AXILLA

Ligature of the Brachial Artery, 354; <i>in the Middle of the Arm</i> , 355; <i>at the Bend of the Elbow</i> , 358. Ligature of the Axillary Artery, 358; <i>of the First Part</i> , 360; <i>of the Third Part</i> , 363	354-364
--	---------

CHAPTER XII

LIGATURE OF THE ARTERIES OF THE NECK

Ligature of the Innominate Artery, 365; <i>through an Δ-shaped Incision</i> , 366; <i>through a Median Vertical Incision</i> , 368. Ligature of the First Part of the Right Subclavian, 370; <i>through an Oblique Incision</i> , 371; <i>through an Δ-shaped Incision</i> , 372. Ligature of the Third Part of the Subclavian, 373. Ligature of the Common Carotid Artery, 375; Relations of the Left Common Carotid in the Thorax, 375; Relations of the Common Carotid in the Neck, 376; <i>Ligature above the Omo-hyoid</i> , 377; <i>Ligature below the Omo-hyoid</i> , 379; Ligature of the External Carotid Artery, 383. Ligature of the Internal Carotid Artery, 386. Ligature of the Vertebral Artery, 388. Ligature of the Lingual Artery beneath the Hyo-glossus Muscle, 390. Ligature of the Facial Artery, 393. Ligature of the Temporal Artery, 394. Ligature of the Occipital Artery, 394	365-396
--	---------

CHAPTER XIII

OPERATIONS UPON VEINS

Plastic Operations, 397. Arterio-venous Anastomosis, 398. Operations upon Varicose Veins, 399; <i>Trendelenburg's Operation</i> , 401; <i>Excision of Varices</i> , 401. Venesection, 403. Intra-venous Infusion, 405	397-407
---	---------

CHAPTER XIV

OPERATIONS UPON THE LYMPHATICS

Suture of the Thoracic Duct, 408. Lymphangioplasty, 408	408-409
---	---------

SECTION V

OPERATIONS UPON NERVES

By FRED^C. F. BURGHARD, M.S. (Lond.), F.R.C.S. (Eng.)

Teacher of Operative Surgery in King's College, London; Surgeon to King's College Hospital; and Senior Surgeon to the Children's Hospital, Paddington Green.

CHAPTER I

NERVE SUTURE: PLASTIC OPERATIONS UPON NERVES

	PAGES
Nerve Suture, 413; <i>Primary Nerve Suture</i> , 413; <i>Secondary Nerve Suture</i> , 416. Plastic Operations upon Nerves, 418; <i>Autoplastic Nerve-bridging</i> , 420; <i>Heteroplastic Nerve-bridging</i> , 420; <i>Nerve-transplantation Methods</i> , 423. Nerve-grafting (Implantation), 425	413-429

CHAPTER II

OPERATIONS UPON THE CRANIAL NERVES AND THE GASSERIAN
GANGLION

Exposure of the Supra-orbital Nerve, 430. Resection of the Superior Maxillary Nerve, 431; <i>at the Infra-orbital Foramen</i> , 431; <i>at the Foramen Rotundum</i> , 432. Resection of branches of the Inferior Maxillary Nerve, 433; <i>the Inferior Dental Nerve</i> , 433; <i>the Lingual Nerve</i> , 434; <i>the Auriculo-temporal Nerve</i> , 434. Removal of the Gasserian Ganglion, 435; <i>the modified Cushing Method</i> , 437; <i>the Hartley-Krause Method</i> , 447; <i>Doyen's Method</i> , 450. Anastomosis of the Facial Artery, 452; <i>with the Hypoglossal Nerve</i> , 453; <i>with the Spinal Accessory Nerve</i> , 454. Resection of the Posterior Primary Divisions of the First Three Cervical Nerves, 455. Exposure of the Brachial Plexus in the Neck, 457	430-458
--	---------

CHAPTER III

OPERATIONS UPON THE NERVES OF THE EXTREMITIES

Exposure of the Median Nerve, 459. Exposure of the Ulnar Nerve, 460. Exposure of the Musculo-spiral Nerve, 461. Exposure of the Great Sciatic Nerve, 464. Exposure of the Internal Popliteal (Tibial) Nerve, 466. Exposure of the External Popliteal (Common Peroneal) Nerve, 466. Exposure of the Anterior Crural (Femoral) Nerve, 466	459-466
---	---------

SECTION VI

OPERATIONS UPON MUSCLES, TENDONS, TENDON
SHEATHS, AND BURSAEBy FRED^C. F. BURGHARD, M.S. (Lond.), F.R.C.S. (Eng.)Teacher of Operative Surgery in King's College, London; Surgeon to King's
College Hospital; and Senior Surgeon to the Children's Hospital,
Paddington Green.

CHAPTER I

OPERATIONS UPON MUSCLES

	PAGES
Muscle Suture, 469. Muscle-lengthening, 472	469-472

CHAPTER II

OPERATIONS UPON TENDONS

Division of Tendons (Tenotomy), 473; *of the Tendo Achillis*, 475; *of the Tibialis Anticus (anterior) Tendon*, 478; *of the Tibialis Posticus (posterior) and the Flexor Hallucis Longus Tendons*, 479; *of the Peronei Tendons*, 481; *of the Hamstring Tendons*, 482; *of the Biceps Tendon*, 482; *of the Semimembranosus and Semitendinosus Tendons*, 483; *of the Sterno-mastoid*, 484. Tendon Suture, 487; *Primary*, 488; *Secondary*, 492. Tendon-lengthening, 493. Tendon-shortening, 496. Tendon-transplantation and Tendon-grafting, 497 473-502

CHAPTER III

OPERATIONS UPON TENDON SHEATHS AND BURSAE

Excision of the Sheath of a Tendon, 503. Operations upon Bursæ, 505 . 503-505

SECTION VII

OPERATIONS FOR NON-TUBERCULOUS AFFECTIONS
OF THE BONES

By FREDC. F. BURGHARD, M.S. (Lond.), F.R.C.S. (Eng.)

Teacher of Operative Surgery in King's College, London; Surgeon to King's
College Hospital; and Senior Surgeon to the Children's Hospital,
Paddington Green.

CHAPTER I

OSTEOTOMY

	PAGES
Macewen's Supra-condyloid Osteotomy, 511. Osteotomy of the Tibia, 513.	
Sub-trochanteric Osteotomy of the Femur, 516	509-516

CHAPTER II

OPERATIONS FOR OSTEOMYELITIS AND ITS SEQUELÆ

Operation for Acute Infective Osteomyelitis, 517. Sequestrotomy, 518; Removal of a Sequestrum following Acute Infective Osteomyelitis, 519; <i>in recent cases</i> , 519; <i>in long-standing cases</i> , 522. Operations for the Obliteration of Septic Cavities in Bone, 523; <i>Plastic Operations upon Cavities in Bone</i> , 524. Removal of a Sequestrum due to Syphilitic or the so-called 'Quiet' Necrosis, 527. Operations for the Obliteration of Aseptic Cavities in Bone, 528. Removal of a Tuberculous Sequestrum, 529. Bone-grafting, 529	517-531
---	---------

CHAPTER III

OPERATIONS UPON FRACTURES

Operations upon Recent Fractures, 532; <i>upon Recent Simple Fractures</i> , 533; <i>upon Recent Compound Fractures</i> , 544; After-treatment, 546. Operations upon Fractures of long standing, 547; <i>for Ununited Fracture</i> , 547; <i>for Mal-union</i> , 550. After-treatment and Results, 550	532-551
--	---------

SECTION VIII

OPERATIONS FOR NON-TUBERCULOUS AFFECTIONS
OF JOINTS

By FRED^c. F. BURGHARD, M.S. (Lond.), F.R.C.S. (Eng.)

Teacher of Operative Surgery in King's College, London; Surgeon to King's College Hospital; and Senior Surgeon to the Children's Hospital, Paddington Green.

CHAPTER I

GENERAL CONSIDERATIONS

	PAGES
Arthrotomy, 555. Arthroplasty, 557. Arthrodesis, 559. Arthrectomy, 560. Excision, 560	555-560

CHAPTER II

OPERATIONS UPON THE WRIST-JOINT

Excision of the Wrist, 561	561-564
--------------------------------------	---------

CHAPTER III

OPERATIONS UPON THE ELBOW-JOINT

Arthrotomy and Drainage, 565. Operations for Intra-articular Fractures, 565. Operations for Fracture of the Olecranon, 567. Operations for Dislocations, 568. Excision of the Elbow, 569. Arthrodesis, 573.	565-574
---	---------

CHAPTER IV

OPERATIONS UPON THE SHOULDER-JOINT

Arthrotomy and Drainage, 575. Operations for Fractures involving the Shoulder-joint, 576. Operations for Dislocations of the Shoulder, 577. Operation in Recent Cases, 578. Operations for Unreduced Dislocation, 579. Excision of the Shoulder, 581; <i>Kocher's Posterior Resection</i> , 586. Arthrodesis, 588. Excision of the Scapula, 589	575-591
---	---------

CHAPTER V

OPERATIONS UPON THE ANKLE-JOINT: OPERATIONS UPON
THE TARSAL BONES AND JOINTS

Arthrotomy and Drainage, 592. Arthrotomy for Fractures into the Joint, 593; <i>Operation for Compound Pott's Fracture</i> , 594; <i>for Simple Recent Pott's Fracture</i> , 594; <i>for Simple Pott's Fracture of long standing</i> , 595; <i>for Fractures of the Astragalus</i> , 596. Arthrodesis, 596. Excision of the Ankle-joint, 597. Operations upon the Tarsal Bones and Joints, 597; <i>Excision of the Astragalus</i> , 597; <i>Excision of the Os Calcis</i> , 601	592-602
--	---------

CHAPTER VI

OPERATIONS UPON THE KNEE-JOINT

	PAGES
Removal of displaced Semilunar Cartilages, 603. Arthrotomy and Drainage, 606. Repair of the Crucial Ligaments, 608. Removal of the Synovial Membrane of the Knee, 609. Operations for Intra-articular Fractures, 611. Operations for Fracture of the Patella, 611; for <i>Recent Fractures</i> , 612; for <i>Fractures of long standing</i> , 621. Excision of the Knee, 625; for <i>Arthrodesis</i> , 632; for <i>Ankylosis</i> , 632	603-633

CHAPTER VII

OPERATIONS UPON THE HIP-JOINT

Arthrotomy of the Hip, 634. Drainage of the Hip-joint, 635. Osteotomy of the Neck of the Femur, 636. Operations for Fractures of the Neck of the Femur, 637. Excision of the Hip-joint by an External Incision, 642. Operations for Traumatic Dislocations, 645. Operations for Congenital Dislocations, 647	634-651
--	---------

SECTION IX

PLASTIC SURGERY

By T. P. LEGG, M.S. (Lond.), F.R.C.S. (Eng.)

Surgeon to the Royal Free Hospital.

CHAPTER I

GENERAL PRINCIPLES: SKIN-GRAFTING

General Principles, 655; Methods of cutting and using Flaps, 657. Methods of suturing, 659. The Closure of Triangular Gaps, 662; of Quadrilateral Gaps, 662; of Elliptical Gaps, 663. Skin-grafting, 664; <i>Thiersch's Method</i> , 670; <i>Reverdin's</i> , 672; <i>Wolfe's</i> , 673	655-674
---	---------

CHAPTER II

RHINOPLASTY

General Principles, 675. Complete Rhinoplastic Operations; <i>The Indian Method</i> , 676; <i>The Italian Method</i> , 679. Partial Rhinoplastic Operations; <i>Operations for defects of the Bridge of the Nose</i> , 679; <i>Cheyne's Method</i> , 679; <i>Subcutaneous Injection of Paraffin for Restoration of the Bridge</i> , 681. Operations for Restoration of the Soft Parts, 683; <i>Syme's Operation</i> , 683; <i>Keegan's Method</i> , 683. Operations for Restoration of the Alæ Nasi and Side of the Nose, 686; <i>Langenbeck's Method</i> , 686; <i>by a Flap taken from the same side of the Nose</i> , 686. Formation of a New Columella, 689. Plastic Operations on the Auricle, 691	675-692
---	---------

CHAPTER III

PLASTIC OPERATIONS ON THE LIPS, MOUTH, AND FACE

	PAGES
General Principles, 693. Operations on the Lips; <i>for Ectropion</i> , 694; <i>Restoration of the Lips</i> , 697; <i>Operations for Microstoma</i> , 702. Plastic Operations on the Cheek, 704; Closure of a Large Defect, 708; Closure of a Small Defect, 713; <i>Gussenbauer's Operation</i> , 714. Operations for Ankylosis of the Lower Jaw, 715. Operations for Syphilitic Affections of the Palate, 717	693-718

CHAPTER IV

OPERATIONS FOR CONGENITAL AND ACQUIRED DEFORMITIES

Operations for Webbed Fingers; <i>General Principles</i> , 719; <i>Methods of operating</i> , 720; <i>Simple Division</i> , 720; <i>by Triangular Flap at Base of the Web</i> , 722; <i>Didot's Operation</i> , 723. Operations for Supernumerary Digits, 724. Operations for acquired Contractions of the Fingers; <i>General Principles</i> , 725; <i>Dupuytren's Contraction</i> , <i>Adams's Operation</i> , 726; <i>Division of the Fascia by Open Methods of operating</i> , 727. Operations for Cicatricial Deformities after Injuries; <i>General Principles</i> , 730; <i>Methods of using Flaps</i> , 731. Operations for Hammer-toe, 734	719-736
INDEX	737-751

LIST OF ILLUSTRATIONS

FIG.	PAGE
1. Diagram illustrating the Irritation produced in the Tissues by Injections of Sodium Chloride Solutions of Various Strengths	33
2. Syringe for Subcutaneous Infiltration	34
3. Needle-holders	35
4. Long Needles for Subcutaneous Infiltration	35
5. Infiltration of the Skin in Operations for Goitre	37
6. Infiltration of the Deeper Structures in Operations for Goitre	37
7. A Method of illustrating the Position assumed by a Heavy Injection Fluid (Sp. Gr. 1.0230) under the Influence of Gravity	48
8. Apparatus designed to show the Result of Injections of Coloured Fluids of Various Specific Gravities	49
9. Glass Tube showing Bier's Light Solution remaining about the Point of Injection	51
10. Glass Tube showing the Gravitation of a Heavy Injection Fluid	51
11. Diagram showing Method of Lumbar Puncture	53
12. Position of the Patient for Puncture in Low Operations	54
13. 'Record' Syringe and Needles for Spinal Analgesia	55
14. Lateral Position for Puncture when High Analgesia is required	57
15. Patient rolled over on the Back after the Injection has been made	58
16. Lynn Thomas's Hæmostatic Forceps	80
17. Wyeth's Pins	81
18. Finger Bistoury	85
19. Knife for Circular Amputation	85
20. Syme's Foot Knife	85
21. Methods of holding the Amputating Knife	86
22. Method of holding Amputating Knife when making Circular Incisions	87
23. Method of applying a Two-tailed Linen Retractor	88
24. Application of a Three-tailed Linen Retractor	89
25. Gigli's Wire Saw	90
26. Steadying the Saw when dividing a Bone	91
27. Bevelling off the Bone in Amputations	92
28. Finger Bistoury	97
29. Amputation at the Terminal Inter-phalangeal Joint by the Long Palmar Flap. Making the Dorsal Incision	98
30. Amputation at the Terminal Inter-phalangeal Joint by the Long Palmar Flap. Completing the Palmar Incision	99
31. Amputation of the Tip of the Thumb by a Long Palmar Flap	100
32. Amputations at the Metacarpo-phalangeal Articulations	102
33. The Projection left after Disarticulation at the Metacarpo-phalangeal Joint by the Circular Racket Method	104

	PAGE
FIG.	
34. Racket Incisions for Disarticulation at the Metacarpo-phalangeal Joints of the Thumb, Index and Little Fingers	105
35. Farabeuf's Amputation at the Metacarpo-phalangeal Joints of the Thumb and Little Finger	107
36. Disarticulation at the Metacarpo-phalangeal Joint of the Thumb by an Elliptical Incision	108
37. Amputation of the Thumb with its Metacarpal Bone by the Oblique Racket Incision	110
38. Method of manipulating the Thumb during its Removal	111
39. Incisions for Removal of a Finger with its Corresponding Metacarpal Bone	113
40. Incisions suitable for Removal of Three Fingers with their Corresponding Metacarpal Bones	114
41. Incisions for Removal of all the Fingers	115
42. Incision for Removal of all the Fingers with their Corresponding Metacarpal Bones	115
43. Disarticulation at the Wrist by a Circular Incision	117
44. Disarticulation at the Wrist by an Elliptical Incision	118
45. Disarticulation at the Wrist by a Long Palmar Flap	119
46. The Method of disarticulating at the Wrist	120
47. Disarticulation at the Wrist-joint by a Large External Flap	121
48. The Circular Amputation. Commencing the Incision	124
49. The Circular Amputation. Finishing the Incision	125
50. The Circular Amputation by the Cuff Method	126
51. A Diagram illustrating the Method of dividing the Periosteum and Interosseous Membrane. (<i>After Farabeuf</i>)	127
52. Section across the Middle Third of the Forearm	128
53. Amputation through the Forearm by Equal Antero-posterior Flaps	130
54. Disarticulation at the Elbow-joint by a Circular Incision	133
55. Transverse Section through the Bend of the Elbow	134
56. Disarticulation at the Elbow-joint by an Elliptical Incision	135
57. Commencing the Elliptical Incision for Disarticulation at the Elbow-joint	136
58. Method of terminating the Elliptical Incision for Disarticulation at the Shoulder-joint	137
59. Disarticulation at the Elbow-joint by a Large External Flap	138
60. The Circular Amputation. Commencing the Incision	140
61. The Circular Amputation. Finishing the Incision	141
62. Appearance of the Limb after a Circular Amputation	143
63. Amputation through the Arm by Equal Antero-posterior Flaps	144
64. Incision for Spence's Disarticulation at the Shoulder-joint	147
65. Raising the Outer Flap in Spence's Amputation	148
66. Disarticulating in Spence's Amputation	149
67. Stump of Spence's Disarticulation at the Shoulder-joint	150
68. Disarticulation at the Shoulder by the Modified Racket Method	151
69. The Anterior Incision for the Interscapulo-thoracic Amputation	154
70. The Posterior Incision for the Interscapulo-thoracic Amputation	155
71. The Cicatrix left after an Interscapulo-thoracic Amputation	156
72. Disarticulation of the Great Toe at the Inter-phalangeal Joint	159

LIST OF ILLUSTRATIONS

XXV

FIG.	PAGE
73. Farabeuf's Disarticulation at the Metacarpo-phalangeal Articulation of the Great Toe	161
74. The Stump left after Farabeuf's Amputation of the Great Toe	162
75. Disarticulation of the Great Toe by an Internal Flap	163
76. Disarticulation of the Great Toe by the Racket Method	164
77. Cutting the Plantar Incision in Lisfranc's Amputation	167
78. Incisions for Lisfranc's Amputation	168
79. Raising the Plantar Flap in Lisfranc's Amputation	169
80. Method of grasping the Foot when cutting the Dorsal Incision in Lisfranc's Amputation	170
81. Method of disarticulating the Base of the Second Metatarsal Bone	171
82. Disarticulation of the Front Half of the Foot in Lisfranc's Amputation	172
83. Stump of Lisfranc's Amputation seen from the Outer Side	173
84. Lisfranc's Amputation. Stump seen from the Inner Side when the Incision has been correctly planned	173
85. The Appearance presented by the Stump of a Lisfranc's Amputation when the Flaps have been improperly planned	174
86. Incisions for Chopart's Amputation	176
87. Incisions for Farabeuf's Sub-astragaloid Disarticulation	179
88. Cutting the Plantar Portion of the Incision on the Left Foot in Farabeuf's Sub-astragaloid Disarticulation	181
89. Separating the Os Calcis from the Astragalus in Farabeuf's Sub-astragaloid Disarticulation	182
90. The Final Stages of clearing the Os Calcis in Farabeuf's Sub-astragaloid Disarticulation	183
91. The Appearance of the Flaps after Farabeuf's Sub-astragaloid Disarticulation	185
92. Stump left after Farabeuf's Sub-astragaloid Disarticulation	186
93. Method of applying Dressings to the Stump of Farabeuf's Sub-astragaloid Disarticulation	187
94. Incisions for Nélaton's Sub-astragaloid Disarticulation	188
95. Racket Incisions for Sub-astragaloid Disarticulation	189
96. Incisions for Syme's Disarticulation at the Ankle-joint	191
97. Syme's Foot Knife	191
98. Disarticulation at the Ankle by a Postero-internal Flap	195
99. Incisions for Pirogoff's Amputation	197
100. Lines of Bone Section in Pirogoff's Amputation	198
101. The Stump after Pirogoff's Amputation	199
102. Le Fort's Amputation	199
103. Incisions for Gordon Watson's Amputation	200
104. Gordon Watson's Trans-calcaneal Amputation	201
105. Supra-malleolar Amputation by the Oblique Incision	206
106. Marcellin Duval's Amputation through the Lower Third of the Leg by the Oblique Incision	207
107. Method of bevelling off the Subcutaneous Edge of the Tibia	209
108. Amputation through the Lower Third of the Leg by a Long Posterior Flap	210
109. Amputation through the Lower Third of the Leg by a Single Posterior Flap	211

FIG.	PAGE
110. Hey's Amputation through the Middle of the Leg	213
111. Incisions for Lister's Amputation in the Middle of the Leg	214
112. Lister's Amputation. Cutting the Posterior Flap	215
113. Amputation at the 'Seat of Election' by the Circular Incision	217
114. The Three-tailed Linen Retractor in use for Amputation through the Leg	218
115. Amputation at the 'Seat of Election' by Equal Lateral Skin Flaps	220
116. Incisions for Farabeuf's Amputation at the 'Seat of Election'	221
117. Dividing the Structures in the large outer flap in Farabeuf's Amputation at the 'Seat of Election'	222
118. Flaps after Farabeuf's Amputation at the 'Seat of Election'	223
119. Stump after Farabeuf's Amputation at the 'Seat of Election'	224
120. Incision for Stephen Smith's Disarticulation at the Knee-joint	226
121. Disarticulation at the Knee-joint by Stephen Smith's Method	227
122. Stump left after Stephen Smith's Disarticulation at the Knee-joint	228
123. Faulty Incisions for Stephen Smith's Disarticulation	230
124. Disarticulation through the Knee-joint by an Oblique Elliptical Incision	231
125. Trans-condyloid Amputation of the Femur by Long Anterior and Short Posterior Flaps	233
126. Incisions for Lister's Modification of Carden's Amputation	234
127. Removing the Articular Surface of the Patella in the Stokes-Gritti Amputation	236
128. The Flaps after a Stokes-Gritti Amputation	237
129. Bevelling the Linea Aspera in Amputation through the Femur	241
130. Amputation through the Middle of the Thigh by unequal Antero-posterior Flaps	243
131. Cutting the Posterior Flap by Transfixion in Amputation through the Lower Third of the Thigh	244
132. India-rubber Tourniquet applied for Disarticulation at the Hip-joint	247
133. Incision for Furneaux Jordan's Disarticulation at the Hip	250
134. Stump left after Furneaux Jordan's Amputation	251
135. Improved Method of marking out the Flaps in Furneaux Jordan's Amputation	252
136. Incisions for the Anterior Racket Disarticulation at the Hip	254
137. Disarticulation at the Hip by the Anterior Racket Method	255
138. Flaps left after Disarticulation at the Hip by the Anterior Racket Method	256
139. Stump after Disarticulation at the Hip-joint by the Anterior Racket Method	257
140. Crile's Artery Compression Clamps	263
141. Dorrance's Artery Suture	264
142. End-to-end Union of an Artery by Dorrance's Suture	265
143. The Obliterative Suture in Endo-aneurysmorrhaphy. (<i>After Matas</i>)	271
144. Spring-eyed Needles	272
145. The Reconstructive Suture in Endo-aneurysmorrhaphy. (<i>After Matas</i>)	272
146. Obliteration of the Wall of the Sac in Endo-aneurysmorrhaphy. (<i>After Matas</i>)	273
147. Diagram illustrating a Transverse Section through an Aneurysm obliterated by Matas's Method. (<i>After Matas</i>)	274
148. The Reconstructive Method as applied to Large Arteries. (<i>After Matas</i>)	275

LIST OF ILLUSTRATIONS

xxvii

FIG.	PAGE
149. Diagram illustrating the Method of reversing the Systemic Circulation	281
150. Correct Method of holding the Knife when cutting down upon an Artery	286
151. The "Stay-knot" of Ballance and Edmunds	290
152. The Dorsalis Pedis Artery	294
153. The Incision for Exposure of the Dorsalis Pedis	295
154. Landmarks for the Anterior Tibial Artery	296
155. The Anterior Tibial Artery in the Upper Third	298
156. The Anterior Tibial Artery in the Middle of the Leg	299
157. Transverse Section through the Middle of the Leg to show the Relations of the Anterior Muscles	300
158. The Anterior Tibial Artery in the Lower Third of the Leg	301
159. Incisions for Exposure of the Posterior Tibial Artery	303
160. Incision for Ligature of the Popliteal Artery from the Inner Side of the Thigh	308
161. The Popliteal Artery from the Inner Side of the Thigh	309
162. Section through the Thigh immediately above the Patella	310
163. Incision for Exposure of the Popliteal Artery in the Lower Part of the Popliteal Space	311
164. The Popliteal Artery in the Lower Part of the Left Popliteal Space	312
165. Incisions for Ligature of the Femoral Artery	313
166. Line of the Femoral Artery when the Lower Extremity is fully extended	314
167. Section through the Thigh at the Level of the Upper Part of Hunter's Canal	315
168. Ligature of the Femoral Artery in Hunter's Canal	317
169. Transverse Section through the Thigh (Hunter's Canal)	318
170. Ligature of the Superficial Femoral at the Apex of Scarpa's Triangle	319
171. Ligature of the Common Femoral beneath Poupart's Ligament	322
172. Sir Astley Cooper's Incision for Extra-peritoneal Ligature of the External Iliac Artery	326
173. Ligature of the Right Common Iliac Artery	333
174. The Superior Gluteal Artery	335
175. The Sciatic and Internal Pudic Arteries	337
176. Ligature of the Abdominal Aorta	342
177. Incisions for the Radial and Ulnar Arteries on the Front of the Forearm	345
178. The Radial Artery in the Upper Third of the Forearm	346
179. The Radial Artery in the Middle Third of the Forearm	347
180. The Radial Artery at the Wrist	348
181. The Line of the Radial Artery in the 'Anatomical Snuff-box'	349
182. The Ulnar Artery at the Wrist	351
183. The Ulnar Artery in the Middle of the Forearm	352
184. Incision for Ligature of the Brachial Artery in the Middle of the Arm	355
185. The Brachial Artery in the Middle of the Arm	356
186. The Brachial Artery at the Bend of the Elbow	357
187. The First Part of the Axillary Artery	361
188. Incision for Ligature of the Third Part of the Axillary Artery	362
189. The Third Part of the Axillary Artery	363
190. Ligature of the Innominate Artery	367
191. Ligature of the Third Part of the Subclavian Artery	373
192. Incisions for Ligature of the Common and External Carotid Arteries	378

FIG.	PAGE
193. Ligature of the Common Carotid above the Omo-hyoid	379
194. Incisions for Ligature of the Common and Internal Carotid and the Lingual Arteries	380
195. Ligature of the Common Carotid below the Omo-hyoid	381
196. Ligature of the External Carotid Artery	385
197. Ligature of the Internal Carotid Artery	387
198. Ligature of the Vertebral Artery	389
199. Ligature of the Lingual Artery	391
200. Ligature of the Facial Artery	393
201. Ligature of the Temporal Artery	394
202. Ligature of the Occipital Artery	395
203. Canulæ for Intra-venous Infusion	406
204. Simple End-to-end Suture of a Nerve	414
205. Lateral Suture of a Nerve	415
206. Nerve-bridging by Reflected Slips	420
207. Nerve-bridging by Strands of Catgut	421
208. Nerve-bridging by Protective Tubes	421
209. Nerve-bridging by the Combined Method	422
210. Diagram illustrating the Repair of one Nerve with a Portion of another	423
211. Nerve-grafting by Lateral Implantation	426
212. Nerve-grafting by Double Lateral Implantation	427
213. Method of grafting where Two Parallel Nerves are divided	428
214. Incision for Removal of the Gasserian Ganglion	439
215. Section of the Zygoma	440
216. Forceps for Removal of the Skull	441
217. Exposure of the Floor of the Middle Fossa of the Base of the Skull	442
218. Schoemaker's Artery Forceps	443
219. Exposure of the Gasserian Ganglion	444
220. Crile's Artery Clamps and Hæmostatic Spatula	445
221. De Vilbiss's Skull Forceps	448
222. Guarded Chisel for Skull Operations	448
223. Gigli's Wire Saw Introducer	449
224. Osteoplastic Flap reflected	450
225. Doyen's Bone Section for Removal of the Gasserian Ganglion	451
226. Posterior Cervical Plexus	456
227. Incision for Exposure of the Musculo-spiral Nerve at the Bend of the Elbow	462
228. Exposure of the Musculo-spiral Nerve in Front of the Elbow	463
229. Exposure of the Great Sciatic Nerve	465
230. Muscle Sutures	469
231. Mattress Suture for uniting Muscle	470
232. Muscle-lengthening	471
233. Tenotomes	474
234. Incision for Division of the Sterno-mastoid	485
235. Methods of Simple Tendon Suture	490
236. Tendon-lengthening by Oblique Suture	494
237. The \perp -method of Tendon-lengthening	494
238. Tendon-lengthening by Reflected Slips	495
239. Reflected Slips reinforced by Catgut Sutures	495

LIST OF ILLUSTRATIONS

XXIX

FIG.	PAGE
240. Hibbs's Method of Tendon-lengthening	496
241. Autoplastic Tendon-grafting	496
242. Implantation of Tendons	498
243. Various Methods of Tendon-grafting	499
244. Osteotomy Instruments	510
245. Method of holding Macewen's Osteotome	512
246. Farabeuf's Rugines	521
247. Obliteration of a Cavity in the Shaft of the Tibia	525
248. Peters's Bone Forceps	538
249. Wire Sutures for Oblique Fractures	539
250. Wire Sutures for Transverse Fractures	539
251. Bone Peg for the Fixation of Fractures	541
252. Metal Collars for the Fixation of Fractures	542
253. Metal Plates for the Fixation of Fractures	542
254. Screws and Plates for Fractures	543
255. Bone Staple-plate for Fractures	543
256. Willard Bartlett's Splint for Compound Fractures	545
257. Keyhole Saw for Bone	549
258. Structures concerned in Lister's Excision of the Wrist	562
259. The Parts removed in Excision of the Wrist by Lord Lister's Method	563
260. Reflection of the Soft Parts in Excision of the Elbow	570
261. Sawing the Humerus in Excision of the Elbow	571
262. Sawing the Radius and Ulna in Excision of the Elbow	572
263. Incision for Excision of the Shoulder-joint	581
264. Preservation of the Biceps Tendon in Excision of the Shoulder-joint	582
265. Disarticulation of the Head of the Humerus in Excision of the Shoulder-joint	583
266. Sawing the Head of the Humerus in Excision of the Shoulder-joint	584
267. Incision for Excision of the Astragalus	598
268. Exposure of the Astragalus	599
269. Removal of the Astragalus	600
270. Methods of inserting Sutures in Comminuted Fractures of the Patella	614
271. Bone Drill for Wiring	614
272. Passing the Wire in Fracture of the Patella	615
273. Twisting the Wire in Fracture of the Patella	617
274. Barker's Method of securing Fractures of the Patella	619
275. Lord Lister's Operation for Union of a Fracture of the Patella of long standing with Wide Separation of the Fragments	623
276. Incision for Excision of the Knee	627
277. Sawing the Condyles of the Femur in Excision of the Knee	628
278. Sawing the Tibia in Excision of the Knee	629
279. Howse's Excision Splint	630
280. Diagram illustrating the Method of pinning Fractures of the Neck of the Femur	640
281. Excision of Hip by Kocher's External Incision	643
282. Exposure of the Head of the Femur in Kocher's Excision of the Hip	644
283. Anterior Incision for Exposure of the Hip-joint	649
284. Closure of a Large Defect by means of Flaps	656
285. Method of closing a Large Defect by means of Flaps	657

FIG.	PAGE
286. Different Methods of using Sutures	660
287. The Method of using India-rubber Tubing and Silkworm-gut as ' Relief of Tension ' Sutures	661
288. Method of closing a Triangular Gap of Small Size	662
289. Method of closing a Triangular Gap of Large Size	663
290. Method of closing a Triangular Defect by using a Curved Incision	664
291. Method of closing a Large Triangular Defect by means of Flaps	664
292. Method of closing a Small Quadrilateral Defect	665
293. Method of closing a Large Quadrilateral Defect	666
294. The Closure of an Elliptical Area by undermining the Skin and Sub- cutaneous Tissues around it	667
295. Closure of a Large Elliptical Area by means of Flaps	668
296. Thiersch's Method of Skin-grafting	670
297. Thiersch's Method of Skin-grafting. The Grafts in Position	671
298. A Broad Smooth Metallic Spatula for transferring the Skin Grafts	672
299. Thiersch's Knife for cutting Skin Grafts	672
300. The Indian Method of Rhinoplasty	677
301. Sir Watson Cheyne's Method of restoring the Bridge of the Nose	680
302. Mahu's Syringe for the Injection of Cold Paraffin Wax	682
303. Syme's Operation for the Restoration of the Soft Parts of the Nose	684
304. Keegan's Method of Rhinoplasty	685
305. Langenbeck's Method of Rhinoplasty	687
306. Restoration of the Ala Nasi by a Flap taken from the Same Side of the Nose	688
307. Restoration of the Ala Nasi	689
308. Restoration of the Ala Nasi by a Flap taken from the Cheek	690
309. Formation of the Columella from the Upper Lip	691
310. Formation of the Columella from the Dorsum of the Nose	691
311. Operation for Ectropion of the Lower Lip	694
312. Operation for Severe Ectropion of the Lower Lip, with much Scar Tissue	695
313. Restoration of the Lower Lip by means of a Flap taken from the Upper Arm	696
314. Restoration of the Lower Lip by Submaxillary Incisions	697
315. Restoration of the Lower Lip, after Removal of Epithelioma	698
316. Restoration of the Lower Lip by Horizontal Incisions through the Cheeks	699
317. Restoration of the Upper Lip, following an Injury	701
318. Dieffenbach's Operation	702
319. Restoration of the Lower Lip by Quadrilateral Flaps	703
320. Restoration of the Upper Lip	704
321. Restoration of the Upper Lip. Completion of the Operation shown in the Previous Figure	705
322. Operation for Microstoma	706
323. Operation for Microstoma. Formation of New Angle of the Mouth	707
324. Method of Closure of a Large Gap in the Cheek by Transplantation of a Flap from the Submaxillary Region	708
325. Restoration of a Large Defect in the Cheek. Completion of the Operation shown in Fig. 324	709

LIST OF ILLUSTRATIONS

xxxii

FIG.	PAGE
326. Closure of a Defect in the Cheek by gliding a Flap from the Submaxillary Region	710
327. Israel's Method of closing a Defect in the Cheek	711
328. Method of closing a Defect in the Cheek by Superimposed Flaps	713
329. To illustrate the Closure of a Small Defect by a Flap taken from the Skin over the Masseter	714
330. Gussenbauer's Operation	715
331. Operations for Ankylosis of the Lower Jaw	716
332. Operations for Webbed Fingers	721
333. Didot's Method of operating for Webbed Fingers	722
334. Didot's Method of operating for Webbed Fingers	723
335. Operation for Dupuytren's Contraction by Excision of the Contracted Fascia	728
336. Operation for Dupuytren's Contraction by a V-shaped Incision	729
337. To show how a Flap may be used to correct Cicatricial Contraction	731
338. To illustrate the Use of a Flap with Two Pedicles	733
339. To show how the Palm of the Hand may be covered with a Flap taken from the Buttock	733
340. To show how a Flap may be taken from the Skin of the Abdomen and applied to the Forearm	734
341. To show how a Flap taken from one Leg may be applied to the other	735

SECTION I
THE PRINCIPLES AND TECHNIQUE OF
WOUND TREATMENT

BY

C. B. LOCKWOOD, F.R.C.S. (Eng.)
Surgeon to St. Bartholomew's Hospital

CHAPTER I

INTRODUCTION

DURING the past decade the principles which underlie the treatment of wounds have been better understood. To-day every one aims at the exclusion of bacteria, because it is recognized that they are the cause of all the different kinds of sepsis.

It is customary to call surgery which aims at the exclusion of bacteria 'Aseptic', and a successful result, 'Asepsis.' This definition is logical and scientific, and affords those who accept it a clear and distinct standard of excellence to aim at.

Throughout this article the words 'aseptic' and 'asepsis' will be used in this sense, and will thus be applied to the end to be attained, and not to the means by which it is hoped to be attained. The latter are numerous and ever-changing. Those of to-day may be discarded to-morrow, when better have been found; but the principle can never alter.

The highest degree of technical skill and knowledge is required to exclude bacteria before, during, and after operations. But, above all, it is necessary to know whence they come, how they enter, and the means by which they can be kept out. Each addition to our knowledge has taught that prevention is better than cure, and thus asepsis is more likely to be attained amidst a germless environment than where they abound.

Whilst 'aseptic' and 'asepsis' are so easy to define, it is otherwise with 'septic' and 'sepsis', because, as is well known, such general terms do not admit of exact definition. It is, however, universally agreed that every kind of sepsis is caused by bacteria. Yet, since it was first applied to that which stank, the meaning of the word 'septic' has continually altered. Our notions keep on growing clearer and more scientific; but a few years ago we should have been content to say that a wound which suppurated had become septic. Now, however, we must know the kind of infection. When that has been ascertained we might still say the case was septic, but should go on to speak of it as one of 'streptococcic infection', 'staphylococcus aureus infection,' 'pneumococcus infection,' or of 'colon bacillus infection', and so on. After having been scientifically diagnosed by culture media or inoculation experiments, the infection may then be treated

scientifically with appropriate disinfectants, with therapeutic sera, or with vaccines. It is quite impossible to diagnose the kind of infection in the blood, or in a wound, ulcer, abscess, tissue, or organ, by ordinary clinical methods. Culture media are indispensable, and inoculations into animals have at times to be resorted to. Therefore no hospital is properly equipped which cannot place at the disposal of its surgeons and physicians skilled bacteriologists and a bacteriological laboratory, in which the cultural tests can be carried out and the sera and vaccines prepared. The application of scientific methods to the diagnosis of infection amounts almost to a revolution in surgery. Hitherto most have been content to rely upon clinical methods, and to label a suppuration of the scalp, or of the vulva, with names such as 'cellulitis', or 'vulvitis'. But a child dying of 'cellulitis' of the scalp had diphtheria of the scalp, and recovered after therapeutic serum had been given. A child with vulvitis also had diphtheria of the vulva. Over and over again the discovery of streptococci in the tissues, or in the blood, has been followed by the successful administration of antistreptococcic serum. The staphylococcus aureus, too, has been fought with appropriate vaccines after the method of Wright. In the last instance the results are less rapid and less certain than those obtained with some of the sera which are used for diphtheria or for streptococcus poisoning.

The incidence of wound infection may be inferred from the local and general clinical signs. Even such mild forms as staphylococcus epidermidis albus are accompanied by some local inflammation and a slight alteration in the pulse-rate and in the temperature of the body. But the kind of infection can only be diagnosed by cultural tests, and without these the absence of infection or asepsis cannot be inferred. Thus culture media and inoculation experiments have to be continually resorted to.

There is yet another province of aseptic surgery, and one in which much remains to be done. Besides the exclusion of bacteria from wounds aseptic surgery should aim at rendering aseptic that which has become infected, whether it be wound, ulcer, part, or organ. The means at our disposal so far are disinfectants, vaccines, and therapeutic sera.

Considerable skill and experience may be needed for the diagnosis of the infection, especially an infection of the blood. Here, as Dr. Horder has shown, results may be got by introducing considerable quantities (1 or 2 cc.) of blood into the culture tube.

Scientific Tests. Our surgical methods aim at the exclusion of bacteria, and success is not taken for granted until scientific tests have been made. For this purpose culture media are indispensable adjuncts. As a rule some of the test object is placed, with suitable precautions, in a broth culture tube. This is a delicate and reliable test. It brings

infection to light when least suspected; unless such safeguards be used errors are sure to abound. Gelatine and agar plates are also in constant use. In our surgical work at St. Bartholomew's, tests are systematically applied to everything that comes in contact with the wound—air, water, skin of hands, gloves, instruments, sponges, swabs, silk, gauze, catgut, fishing-gut, and, indeed, anything that could convey infection. Such things as air and water are only tested occasionally. But things which have to be specially prepared by others are subjected to continuous systematic tests. In consequence the proportion of asepsis has increased in the most gratifying way. Occasionally the most unsuspected sources of infection have been brought to light. On one or two occasions the small suture needles were found to be infected—we never could discover how this came about—but after it had been detected by the cultural tests the needles were always sterile.

In addition culture media are in constant requisition for testing wounds whenever the dressings are removed. As a rule the first dressing takes place on the eighth or ninth day after the operation, but wounds are often tested at several consecutive dressings. The test is made by drawing a platinum wire along the incision and by dropping one or more of the sutures into broth.

We know of no records of cases in which everything brought in contact with the wound, and likewise the wound itself, proved sterile when subjected to the stringent test of culture media. For years we seldom attained this high standard of perfection, but latterly we have achieved it in about ten per cent.

Medical Education and Asepsis. The exigencies of medical education have also a bearing upon the question of asepsis. In our hospitals house-surgeons and dressers are appointed for limited periods. As I have said elsewhere¹ these gentlemen do their work remarkably well, and with great devotion, but unfortunately their period of office comes to an end just as they are beginning to be efficient. This system tends to a slight increase in the percentage of sepsis, but is of great educational value, and sends out into the world numbers of well-trained men. As a result the inhabitants of the British Isles have at their disposal one of the best medical services that exists.

¹ *Lettsomian Lectures on Aseptic Surgery in Theory and Practice.* 1904.

CHAPTER II

AIR INFECTION : OPERATING THEATRES

THE atmosphere is one of the most important parts of the environment of an operation. The baneful effects of germ-laden air show themselves very clearly now that operations are done without antiseptics, and now that we know that other sources of infection can be eliminated. A while ago, a temporary operating theatre was being used for the first time. Its cubic capacity was less than 5,000 feet, and a large audience was present for the occasion. The atmosphere became almost unbearable, a clear indication that it had excessive quantities of bacteria in it. Of the three patients operated upon, the first—a case of gastro-enterostomy—died some days afterwards of a sub-acute form of peritonitis. The union between the stomach and the jejunum was perfect. The peritoneum was not soiled during the operation. The second patient had complete removal of the breast performed for carcinoma. The wound suppurated. The third had a myxo-sarcoma of the brachial plexus removed, and the wound healed, as is the rule, by first intention. Clearly the dilute chemical antiseptic—1 in 4,000 biniodide of mercury solution—used at these operations was not a sufficient safeguard against such an atmosphere.

The labours of Pasteur, Tyndall, and of Lister taught us much about the air as a source of wound infection. Additions have been made by Flügge, Gordon, and many others. But much remains to be done, and the practical application of what has been learnt to the science of ventilation is still in its infancy. Asepsis is, of course, easier to attain in a germ-free atmosphere than in one laden with bacteria derived from human beings, horses, and other animals.

Atmospheric bacteria abound most in the densely inhabited parts of cities, and become fewer, but do not entirely disappear, in suburban districts. Dr. M. H. Gordon reported to the Local Government Board that the air of the city of London sixty feet above the pavement contained intestinal bacteria (*B. mesentericus* type), colon bacillus, bacillus enteritidis spirogenes, bacillus subtilis, which is harmless, and fifteen different kinds of staphylococci. Streptococci derived from the mouths and throats of human beings were also found, and also others

which Andrewes and Horder had separated from horse-dung. When dust is present the bacterial inhabitants are multiplied, and may be of such dangerous varieties as erysipelas, tubercle, tetanus, or spreading gangrene.

In planning operating theatres, the germ-laden outside air has to be taken into consideration, and we are still seeking for the best method of ensuring a supply of germless air. In some theatres the Plenum system is in use. In this a supply of air is drawn in from the outside, washed, filtered, warmed, moistened, and then forced along conduits to the operating theatres, wards, offices, or dwelling-rooms. These are built without fire-places or windows which open. The air in them, being forced in by fans, is always at a pressure slightly above that of the atmosphere. For operating theatres this system has many advantages, for we know whence the air comes and what has been done to it. The system is, however, expensive and rather apt to get out of order. The so-called 'natural' system of ventilation can be arranged so as to supply purified air. The 'natural' system extracts the hot air at the top of the room. The air-supply enters below, and after having been filtered through gauze or wool, passes over hot-water or, better still, electrical radiators, which raise its temperature to 65° F. This system is cheap and fairly efficacious. The extraction of air is done by electrical fans. These ought to change the whole air-contents of the theatre once in ten minutes, but draughts are difficult to avoid. Tobin's tubes are often used in operating theatres. They supply air which is cold and falls to the floor, creating a draught. They also permit the entrance of dust and presumably of the bacteria which go along with dust.

The air of operating theatres is liable to bacterial contamination from sources much more dangerous than the outer air. Flügge, Gordon, and others have clearly proved that no bacteria are ejected from the mouth or air-passages during quiet breathing, or whilst the voice is being used in ordinary conversational tones, but loud speaking scattered mouth or throat bacteria a distance of forty feet, laughing or sneezing would send them much further. But latterly other observers (*e. g.* M. de Léon) have made experiments which show that some may eject bacteria during ordinary conversation. The bearing of these important facts upon the conduct of operators, assistants, nurses, and audience is obvious. Wounds should not be talked over. In cases of even slight catarrh a mouth-covering should be worn by the surgeon and by his assistants. It may be assumed that when any one laughs or sneezes in an operating theatre the wound is bombarded with bacteria. When we consider the infirmities of human nature we must conclude that there should always be a glass screen between the audience and the area of the operating theatre. This

need not be carried as far as the ceiling, but should reach at least two feet above the heads of the audience. Such a screen does not prevent the audience from hearing, and moisture does not collect upon it. A glass screen ought also to prevent the diffusion of dust brought in upon the feet of the audience. The mud and dust of streets and roads abound in pathogenic bacteria of the most deadly kinds. An enumeration is unnecessary. We aim at the exclusion of all. So long as the mud is wet no bacteria enter the atmosphere from it. But mud soon dries, is stamped and trampled into dust, and scattered through the air. In places, therefore, in which an audience collects, a screen should be provided. Gordon found that bacteria were carried surprising distances on boots, and disseminated very widely. The boots of members of the House of Commons carried bacillus prodigiosus over six hundred feet. Every one on the floor of the theatre should wear suitable overalls. Ours are made of strong brown holland, and can be easily washed and sterilized. These have decided advantages over gum boots.

Mud and dust are also introduced into the theatres upon the feet of attendants who bring the patients in. This is obviated by placing the patient upon a wheeled operating table which can be pushed in from the anæsthetic room by those with proper foot-covering.

OPERATING THEATRES

It is advisable that each surgeon should have his own operating theatre and his own staff of assistants and nurses. This tends to uniformity of technique and to uniformity of results. Operations are done more accurately and quickly when all are used to working together, and chances of infection are lessened.

The theatre should be in proximity to the wards, and beneath the same roof. This avoids exposure to cold, and after severe operations the patient can be put back to bed as soon as possible. An ideal arrangement is for each surgeon to have on either hand his own ward units; a male ward of about twenty beds and a female ward of twenty beds, and his own theatre in close proximity. The ward unit comprises the usual small isolation wards and offices.

For the septic cases separate wards and theatres should be set apart. This ought to adjoin the isolation ward, and be managed by its sister and nurses. Although it is not possible to exclude all sepsis from the chief operating theatres, yet by good organization and management it can be reduced to a minimum.

Quality of air and cubic capacity. The quality of the air in operating theatres depends in no small degree upon their cubic capacity. Whilst no exact rule can be laid down, yet I have observed that about

10,000 cubic feet is a comfortable size for an operating theatre. It is agreed upon by sanitarians and others that the biological and chemical state of the air is not the only thing to be taken into consideration, and that the human senses and sensations are delicate and reliable guides to the wholesomeness of the air we are breathing. Most surgeons are familiar with the utter weariness felt after hours spent in ill-ventilated and stuffy theatres. This kind of air has been examined over and over again and always has an excess of carbonic acid gas, of organic impurities, and of bacteria. It is also wanting in certain undefinable vital properties essential to our well-being. An ideal atmosphere to operate in would be free from dust and germs, from unpleasant odours, fresh, not too dry, not too moist, warmed to 65° F., and renewed without the creation of draughts. In spite of all the efforts that have been made it is doubtful whether the ideal atmosphere has been achieved. The Plenum system gives good results, but those who have experience of it are by no means unanimous in recommending it. The air of the Plenum system seems to be wanting in those undefinable vital properties without which none is fresh and agreeable. I myself experience a feeling of weariness and sleepiness after half an hour of a modified Plenum system. The system, too, wants attention from attendants, who may neglect their duties. It is also expensive, and buildings specially made for it are difficult to alter. The so-called 'natural' system can be worked in most theatres, is inexpensive, and easy to manage. The air which it supplies is of good quality, provided it is changed often enough. After having worked in a number of theatres of various sizes and all ventilated by the 'natural' system, I am inclined to think that a theatre with 10,000 cubic feet of air-space is about right. Provided this air is changed about once in ten minutes it suffices for about twenty people, including the patient. At St. Bartholomew's the air is changed by means of electrical fans situated at the ceiling. Care is to be taken that these are not over the operating table. It is admitted from the outer air and passed over hot-water radiators. Electrical radiators would be much better because they are soon cold when off. In the hot-water radiators the cooling is slow and the pipes continue to give out much heat. This makes it easy to manage and adjust the air supply to the size of the audience. It is, moreover, under the control of the operator, for he can direct the fan to be worked fast or slow.

Operating equipment. The operating theatre should be as simple and as plain as possible, the walls smooth, impervious, and rounded off. With the Plenum system objectionable hot-water pipes and radiators, which are so difficult to keep clean, can be done without. Also, the temperature can be kept at about 65° F.—for the entering air can be

warmed in winter and cooled in summer; or electrical radiators should be fitted. Their connexions do not, of course, give off heat whether in use or out of use. The sinks should be plain and capacious and with abundant outflow. Elbow taps are the simplest and best and do not easily get out of order. Elaborate washhand-basins are unnecessary; a bowl can be put in the sink, filled from the tap, and after use tilted over into the sink. Suitable bowls can be easily cleansed and sterilized. Instrument cases should be kept in an adjoining room.

Lighting. Every possible source of atmospheric contamination should be excluded from operating theatres. In these days of electric light it is hardly necessary to refer to ordinary gas. It is usually reckoned that each gas-jet vitiates as much air as three people. The electric glow-lamp has none of these disadvantages, and in its various forms has been one of the most valuable adjuncts of modern surgery. It can be conveniently fitted upon adjustable arms which neither collect nor disseminate dust; or projected upon the field of operation by reflectors.

Sterilizers for instruments, and even those for dressings and garments, are sometimes placed within operating theatres. This is most objectionable. The atmosphere is polluted, filled with vapour, and the heat is unbearable. Sterilizing rooms should be provided apart from operating theatres. Small sterilizers for emergency instruments and for silk are almost as objectionable. They should be in an adjoining room not in direct communication with the theatre. Dressing-rooms for surgeons and assistants should be arranged in close proximity. They should be furnished with an abundant water-supply. A bath-room, too, should be provided. During a great part of the year a bath-room would not be used in this country. But in very hot weather it is a decided aid to personal comfort and cleanliness.

Electrical fittings. The electrical installation should provide for a head-lamp, an indispensable adjunct which often converts a difficult and dangerous dissection into an easy one. When an electrical installation is not available a charged accumulator should be at hand. Excellent accumulators can now be obtained capable, in a very small compass, of supplying a head-lamp for many hours. In large hospitals the electrical fittings for cauteries and for a motor are needed.

Operating Tables. The operating table should, as I have already explained, be on wheels, but with an arrangement for placing it firmly on the floor. In addition its height should be capable of easy adjustment without disturbing the patient. The head of the table should raise and lower, and in the middle an adjustment for the Trendelenburg position is indispensable. The foot end should provide for the lithotomy

position. The heating of the table should be by means of hot-water tins or, preferably, by electric glow-lamps or resistance coils. Whichever system of heating is used, infinite care is needed to prevent the patient from being burnt. Many of the tables which meet all these requirements have handles and levers projecting from them which hurt the operator.

It is becoming more and more the habit for surgeons to sit during prolonged operations, such, for instance, as the complete removal of the mammary gland, pectoral muscles, and contiguous lymphatics. The stool ought to have a screw for adjusting its height, and should rotate easily on its axis, and be firm on its base.

CHAPTER III

STERILIZATION

Sterilization of instruments. This is a simple matter ; the instruments are boiled for twenty minutes in a solution of ordinary washing soda and water. The soda helps to remove blood or grease and renders the temperature a shade higher. The edges of knives should be protected by wrapping the blade in soft gauze. I have not found that knives were blunted when reasonable care was taken. Chemical disinfectants are quite untrustworthy for the sterilization of instruments. Mr. Lang infected forceps with foecal material, and then failed to disinfect them with 25 per cent. solution of formalin, although they were soaked in it for twenty-four hours. Formalin is acknowledged to be a very powerful germicide with excellent powers of penetration. After removal from the sterilizer our instruments are placed in 1 in 60 carbolic acid lotion to protect them from air infection. Some surgeons place their instruments in warm salt solution, and others merely lay them out upon a sterilized cloth.

Sterilization of dressings, bandages, swabs, garments, and towels, and the clothing of the patient. Wherever large quantities of materials have to be disinfected a separate sterilizing room has to be provided and placed under the charge of skilled and trustworthy attendants—a senior nurse can manage the sterilizing, but a man is required to attend to the boiler and assist with the lifting. But it is essential that the results of the disinfection should be watched and frequently tested by the bacteriologist. Most of the sterilizers used in this country are protected by letters patent. At St. Bartholomew's we use an apparatus which works well and gives reliable results. The things which come from it are sterile, dry, and undamaged. The steam-pressure in the sterilizing chamber is 10 lb. and the temperature 240° F.

Sterilization of silk and silkworm-gut. Twisted silk, Japanese silk, or celluloid thread or whatever is chosen for ligatures and sutures, should be boiled separately in water. Silk speedily becomes brittle when boiled in soda solution. For my private cases I carry a small sterilizer heated by a spirit-lamp. The silk is sterilized in this, taken out by myself, and put straight into the wound, no one else being allowed

to touch it on any pretext whatever. Chinese silk, celluloid thread, or silkworm-gut is treated in exactly the same way. Silkworm-gut seems to be quite unharmed by repeated boilings, provided no soda is used. But in practice, silk which has been sterilized is not always tolerated by the tissues in which it is placed. The reason for this is by no means clear, and the problem is not so simple as it seems to be. Every surgeon has met with instances in which, after every imaginable precaution has been taken, buried silk sutures have been extruded after the slow formation of a little pus. Assuming that no strong chemical has been used, it is probable that the extrusion of the silk is caused by implantation infection. Bacteria may have got upon the silk from the hands, or from the atmosphere. Indeed with the methods and environment of to-day it is questionable whether a wound is ever closed without some bacteria being shut up within it. The effect of these depends upon a number of things—first upon the virulence of the bacteria. Fortunately the more serious kinds of infection, such as staphylococcus pyogenes aureus, streptococcus pyogenes, or colon bacillus, are unusual. Some form of staphylococcus albus is usually implanted. But even such a microbe as that grows in silk when the conditions are favourable. One of the most favourable conditions for suppuration is afforded by fleshy muscular tissues. I have come to the conclusion that it is not as a rule desirable to try to unite the fleshy parts of muscles with silk. The chances of extrusion are so considerable. Therefore I use catgut chromicized to last thirty days for bringing fleshy muscle together, as, for instance, the fibres of the internal oblique and transversalis after appendicectomy, or the fibres of the rectus abdominis after laparotomy. The way in which silk is knotted also seems to have some kind of effect. I prefer silk to chromicized catgut for repairing the inguinal canal in the radical cure of hernia, for it does not disappear for about twelve months. When the silk sutures fastening the arciform fibres of the internal oblique and transversalis to Poupart's ligament used to be pulled tight, suppuration occasionally took place around them, but has diminished now that the loop is made loose. Also the size of the silk has to be taken into consideration. The risks of suppuration are greater with No. 4 or No. 5 twisted silk than with 000. The last size is so easy and pleasant to tie and stops on so well, that it is freely used in operations such as the removal of the mammary gland, pectorals, and axillary lymphatics, and is never seen again. Sterilized silk is tolerated by some tissues better than by others. As I have just said, fleshy muscle tolerates it very badly, but the peritoneum, on the other hand, tolerates it exceedingly well. Tendon and aponeurosis also tolerate silk well, and likewise nerve.

The burying of silk, as in the radical cure of hernia, is a stringent test of asepsis.

Catgut. Many of the objections to silk are overcome by catgut, which is indispensable for septic operations, such as those about the rectum, or in which pus is encountered; for instance, in appendicular abscess, pyosalpinx, or pyonephrosis. When silk is used for pedicles or ligatures in septic cases it becomes infected, and a persistent sinus or fistula results. Catgut should also be used for ligatures in cases of tuberculosis, especially in the removal of tuberculous cervical glands. Silk ligatures would probably become tuberculous, and cause delay in healing. It is strange to note that in their writings some surgeons advise the use of silk to secure the appendix and meso-appendix, although there be an abscess at the time of the operation.

The use of chromicized catgut is also indicated for suturing together fleshy muscle substance—as, for instance, the internal oblique and transversalis after appendicectomy. Also for suturing the ureter after the removal of a stone from it.

Catgut is treacherous material and needs the greatest care in its preparation. It is to be remembered that raw catgut may have in it virulent bacteria, derived from intestinal contents, or, when obtained from diseased animals, may even contain anthrax. A marked advance in the safety of catgut was made when Reverdin pointed out that the layer of grease put upon the raw catgut by the manufacturer was one of the main obstacles to its disinfection by chemicals or heat. An extraordinary number of methods have been devised for the disinfection of catgut, but none is trustworthy unless it overcomes the grease. In addition, after any method of preparation, the catgut must have the tests of the bacteriologists. Also its physical properties should not be impaired.

For ordinary purposes, such as operations for piles or fistula, or tuberculous glands, a reliable catgut can be prepared with a minimum of labour by soaking raw catgut in methylated ether for forty-eight hours, and then transferring it to a watery solution of mercuric iodide 1-250. After having soaked in this for seventy-two hours it is ready for use. The catgut is kept ready for use by merely keeping it immersed in the same solution. Iodine catgut is also quite reliable, ties well, and retains its toughness. After extraction of grease the gut is soaked, after the manner of Candius, for eight days in a 1 per cent. watery solution of iodine and iodide of potash. But when greater lasting properties are required they can be obtained by the method of hardening in chromic acid, a method which we owe to the immortal founder of aseptic surgery, Lord Lister.

Marine sponges and swabs. The physical properties of marine

sponges make them well suited for clearing wounds of blood or other fluids. They are, however, difficult to cleanse and disinfect, and any want of care, or any inaccuracy, is sure to be followed by very serious results. In consequence many surgeons prefer to use swabs or sponges made of a ball of absorbent wool which may be enclosed in a single layer of gauze. These are easy to disinfect by heat, and, being cheap, can be thrown away after use. But in abdominal operations the utmost vigilance is needed lest any be left in the peritoneal cavity. They may also disappear in the recesses of deep wounds, and not long ago we extracted some wool which had been left in the axilla. Flat swabs or rolls of gauze can take the place of flat sponges.

I myself only use marine sponges prepared under my own supervision, or by experienced and trustworthy nurses. They are frequently submitted to bacteriological tests. An infection with anything but the common and harmless hay bacillus from the air is now unknown. Marine sponges should be chosen of soft fine texture and of round shape. The small ones should be rejected, and those which comfortably fill the palm of the hand kept. The sand, which is used as an adulteration to make them weigh heavier, should be knocked and shaken out, and the bits of shell or of coral dissolved out with a dilute solution of one of the mineral acids, such as nitric or hydrochloric. This is removed by soaking in hot water and washing soda, which also helps to get rid of the remains of any animal matter. Next the sponge is disinfected and bleached by immersion in a solution of sulphurous acid (B. P.) for twelve hours. This is finally removed with boiled water, and the sponge is ready for use, or can be kept in 1 in 40 solution of carbolic acid. This is thoroughly removed with the salt solution, or dilute biniodide lotion used at the operation. Two sponges suffice for most operations and a flat one may be wanted too.

Costume for operating. The foot-covering of brown holland has already been mentioned. A suitable gown of material which can be washed and sterilized is also worn. This should reach from the neck to the feet, and effectually cover such garments as the operator has kept on. To prevent the scurf falling from the scalp it is advisable that a head-covering of linen be worn. I myself am accustomed to wear a cap or, when the theatre or room is very hot, to wrap a yard of antiseptic or of sterilized gauze turbanwise round the head. This is simple and efficacious. Those who have beards should cover them up with a veil of sterilized gauze—or mask of gauze. Any one with a cough or cold should wear one, too, or absent themselves. During quiet breathing or quiet conversation a mouth and nose covering is not essential. But no talking should be done over the wound. Sisters and nurses should be

clothed on similar lines, and as few as possible allowed upon the floor of the theatre. At St. Bartholomew's my sisters and nurses wear long cotton stockings over their boots and legs. These, of course, are washed and sterilized before use. There is no evidence to show that at certain times nurses are additional sources of infection.

The custom which prevails of bringing patients into the operating theatre clad in woollen garments and blankets does not conduce to asepsis. Before the operation sterilized garments, including a cap, should be sent to the ward and worn by the patient during the operation.

Gloves. The thin rubber gloves now worn by surgeons should be a comfortable fit, neither so tight as to constrict and numb the fingers, nor so loose as to make ridges or folds. Care should be taken to see that they are not punctured or torn. This can usually be found out by distending the glove with water from the hot-water tap. As I have already said, this boiled water is sterile. The gloves themselves are sterilized by boiling them for not less than twenty minutes. We have tested them on many occasions and found them sterile. It will be found easier to draw rubber gloves on the hands after they have been filled with water or lotion.

WARD UNITS AND ASEPSIS

The arrangement of the ward units has a bearing upon the question of asepsis. It is to be remembered that in a proportion of cases, perhaps in 10 or 15 per cent., the wound has to be dressed within forty-eight hours for the removal of the drainage-tubes put in to prevent the accumulation of blood, inflammatory effusion, or of synovial fluid. However well and expeditiously this dressing is done there is always a danger of infection. Contact infection is more difficult to avoid when the ward has septic cases in it, and patients are crowded together owing to deficient floor-space. Also, air infection is more to be feared when the cubic space per patient is too small and when the system of ventilation is bad. When the cubic space is properly utilized, about 1,700 cubic feet of air per patient and 100 square feet of floor-space will be adequate, but the air has to be changed six times in the hour without producing draughts. This can be done by the 'natural' system of ventilation aided by proper windows, Tobin's windows, and good extractors.

Organization and sepsis. The organization of the ward work has a distinct bearing upon the question of asepsis. Surgeons, house-surgeons, and dressers should as far as possible confine their services to aseptic cases. Should it be necessary for them to dress septic wounds they should be left until last. In any case a separate staff should be provided for the isolation wards used for erysipelas, cellulitis, pyæmia, septicæmia, and so forth.

CHAPTER IV

CONTACT INFECTION

DISINFECTION OF THE HANDS

THE certainty with which the hands can be disinfected depends in no small measure upon the condition of the skin. Smooth, thin, well-cared-for skin is easier to disinfect than that which is rough or injured. Operations should not be done whilst the hands have upon them septic wounds or ulcers. Neither acetone collodion, nor gloves, nor finger-stalls, can be relied upon to afford the patient perfect security.

It is also wise, as far as possible, to avoid bringing the hands in contact with sepsis. Therefore rubber gloves should, if possible, be worn for the digital examination of septic orifices, and for dressing septic cases. In the last, however, gloves may be dispensed with if the dresser is so adept that by using forceps he can avoid any contact with his fingers. In arranging the order of operations, the aseptic should come first, and afterwards those in which sepsis might be encountered. Thus an arthrotomy or radical cure of hernia would come before appendicectomy, and appendicectomy before an operation for pyosalpinx.

Volumes have been written by Haegler, Leedham Green, and others, on the preparation and disinfection of the hands. But with our present means and methods their disinfection is not a scientific certainty. Marked progress has, however, been made, and greater certainty is reached as the difficulties are better understood. It is not probable that the inexperienced or the careless will ever disinfect the skin of their hands.

The steps in the preparation of the hands are as follows:—At the outset the nails should be cut as short as possible. No amount of scraping or scrubbing removes infective material from beneath the nails. Next, the skin contains a certain amount of grease, which is a bar to the penetration of disinfectants into its grooves and furrows and into the mouths of its sweat and sebaceous glands, where the bacteria lurk.

Numbers of methods have been devised to overcome the greasiness of the skin, and prepare it for disinfection. Some are too violent, and cause that roughness which is such a bar to asepsis. Probably abundant washing with hot water and soft soap aided by a soft nail-brush is as

good as any. In the actual process of disinfection we now know that the penetration of the disinfectant into the skin has to be achieved. For this purpose alcohol is, as Fürbringer pointed out, of invaluable service. It has a threefold use, for it penetrates through and removes the grease, acts as a rather powerful germicide, and dehydrates the skin so as to favour the penetration of watery solutions of disinfectants. But we have always to remember that pure alcohol does not kill bacteria, and has to be mixed with a proportion of water. We find that 25 per cent. of water is sufficient. To save time I have for long used a 1 in 500 solution of mercuric iodide in spirit and water, and have gradually learnt how to get aseptic results with it. By the side of the basin of solution of mercuric iodide in spirit we place another of watery solution of mercuric iodide, 1 in 500, and dip the hands a number of times from one into the other. By this means Dr. Hurtley found by chemical analysis that an appreciable quantity of mercuric iodide¹ had entered the skin and could be found in the little pieces snipped off. Furthermore, Dr. Hurtley found mercuric iodide in the skin of my hands twenty-seven hours after they had been prepared for an operation—and after they had been used in the ordinary way, and washed a number of times. It is obvious that a bacterial growth is not likely to be obtained from a scrap of skin saturated with mercuric iodide. It might contain bacteria which had merely been stunned by the chemical; or it might have enough chemical in it to inhibit their growth, or, in other words, it might be antiseptic. But hands prepared with the two strong solutions of mercuric iodide will bear a more stringent test. When using milder measures we found that although the piece of skin did not infect broth, nevertheless the fingers might infect pieces of sterilized silk dragged roughly through them. But after the two strong solutions had been repeatedly applied, sterilized silk could be dragged through the fingers without infection; on the other hand only two-fifths of it was aseptic after having been dragged roughly through the palms of the hands. There is, therefore, still room for improvement in our methods. But it is reassuring to know that the fingers are so near to asepsis. It is, of course, quite unusual in the course of operations for silk to be dragged through the palms of the hands: instruments, however, are continually being placed there.

Doubtless aseptic results can be attained by the use of other disinfectants. Each surgeon has to learn that which suits his skin the best, for there can be no doubt that what suits one skin may not suit another. But, whatever disinfectant is used, its results ought to be put to the proof of *culture media* over and over again.

The use of rubber gloves does not, in my opinion, absolve the operator

¹ Often referred to as biniodide of mercury.

from the necessity of disinfecting his hands. Gloves not infrequently have small holes in them and are often punctured or torn during the course of the operation. For some operations gloves are undesirable because they interfere with the sense of touch, and because they are so slippery. But no efficacious method has yet been devised to exclude the skin of the patient from the field of operation. It is, therefore, of the highest importance to achieve its disinfection.

Contact with undisinfected instruments used to be a fruitful source of infection. Even now instances of contact infection through the use of undisinfected instruments are by no means rare—perhaps this form of infection is commonest in the genito-urinary tract.

DISINFECTION OF THE PATIENT'S SKIN

The preparation of an aseptic field of operation necessitates the disinfection of the patient's skin. This makes demands upon the skill and ingenuity of the surgeon. In many regions, such as the scalp, the groins, and the armpits, the size of the sweat and of the sebaceous glands makes the task very hard. But, in addition, septic orifices or a septic ulcer may have to be disinfected or sealed off.

Thus the difficulties of skin disinfection depend in no small degree upon the region. The skin of the limbs is easiest to disinfect, then that of the chest and abdomen; the skin of the back is still more difficult, and still more so that of the groins, scrotum, perineum, axilla, and scalp.

The mode of preparation and disinfection of the patient's skin is similar to that of the hands. But, as a preliminary, all the hair within the field of operation is shaved off. The shaved area should be a wide one and æsthetic considerations should not be allowed to weigh against the safety of the patient. Thus I prefer to see the whole scalp cleared for operations upon the cranium. It is best to have the shaving done before the patient is on the operating table, otherwise loose hairs are apt to enter the wound, which may be in the abdomen.

The cutaneous grease is next removed by copious washing with warm water and soap, aided by ether, ether soap, turpentine, petrol, or similar agents. Here, as elsewhere, more depends upon the way in which the chemical is used than upon the kind of chemical which is used. Afterwards the disinfection is carried out by repeated alternations of spirit and mercuric iodide (1-500) lotion and watery solution of mercuric iodide (1-500).

For operations about the face and neck, infection from the mouth and nose is most difficult to avoid. Here the apparatus of the anæsthetist has also to be reckoned with. I have tried various screens, but have not

found any which were satisfactory. A skilful anæsthetist often helps by pumping the anæsthetic through a tube introduced into the nose. The assistant, too, can aid by keeping mucus or saliva out of the wound. Septic stumps should be removed and a disinfectant mouth wash diligently used.

For operations upon the parotid gland or parotid region, the external ear should be disinfected and plugged with antiseptic gauze.

The disinfection of the external organs of generation of either the male or the female is uncertain, and therefore, whatever efforts may have been made to render them aseptic, they should, if possible, be kept out of the field of operation by means of antiseptic gauze, and by towels properly arranged and securely fastened. This can be successfully done in operations for the radical cure of hernia.

When a septic orifice such as the anus is near the field of operation, every effort should be made to disinfect it, and in addition it should be plugged with antiseptic gauze, covered with antiseptic gauze, and shut off by the careful adjustment of aseptic towels fastened with safety-pins or by sewing.

In spite of these precautions a septic orifice, such as the anus, remains a source of danger both during and after operations, and this should be taken into consideration in planning incisions. Thus, in amputation through the hip-joint, I prefer to make a circular cut at the junction of the upper with the middle third of the thigh, and another vertical one down the front and outer part of the thigh, but not too far out to prevent the exposure of the common femoral vessels, which have to be ligatured.

A septic sore or ulcer is so difficult to disinfect that whenever possible it should be healed before the operation is undertaken. For instance, a sore caused by an ill-fitting truss should be allowed to heal before operating for the radical cure of hernia; an ulcer of the leg before wiring an ununited fracture of the tibia and fibula. A distinction is to be made between sores or ulcers which are acutely inflamed and septic, and those which are chronic. No one would hope for an aseptic result if the field of operation had an acutely inflamed or septic sore within it. The presence of such an one would be a strong indication for delay. But it is otherwise with those which are chronic. These, by washing, disinfection, and scraping with Volkmann's spoons, may be rendered harmless.

An ulcer which cannot be healed, such for instance as a cancerous ulcer of the breast, should be washed and disinfected, and then thoroughly burnt with an actual cautery. A most dangerous bacillus lurks in these ulcers, and has been the cause of many deaths from septicæmia.

The disinfection of the anal canal and rectum is hardly within the

range of possibility, but there has been a vast improvement in anal and rectal surgery since surgeons have recognized how much can be achieved by assiduous preparation. As a rule, the alimentary tract can be thoroughly cleaned out, so that no fœcal matter is seen during the operation. Then shaving and washing with soap and water, followed by douching with one of the creolin lotions, brings about a state of affairs which, if not aseptic, at all events gives excellent results. But improvements in surgery are seldom attributable to one cause. In rectal surgery the improvement has also coincided with the systematic drainage of the rectum by large rubber tubes, and the protection of the wound by means of iodoform gauze. Iodoform is a most valuable adjunct to rectal surgery.

THE USE OF CHEMICALS

When the difficulties of obtaining an aseptic environment are considered, the question naturally arises whether additional security cannot be secured by the use of antiseptics. By some this question has been answered in the negative. Imbued with the idea that all antiseptics are harmful to the tissues, and, by impairing their vitality, render them less resistant to infection, they bring nothing stronger than normal saline solution in contact with the wound. To this system the term aseptic is applied and some peculiar virtue is attributed to the relinquishment of chemical antiseptics. It may be noted, however, that most of those who use the word aseptic in this way, use strong chemicals to disinfect the skin, and some even for their ligatures. The system which eschews chemicals necessitates the sterility of everything brought in contact with the wound, the sterility of the patient's skin, and the sterility of the atmosphere which bathes the wound. In addition it necessitates scientific accuracy on the part of the operator, of the assistants, and of the nurses. It leaves no margin for error, although to err is human. Doubtless the endeavour to eschew chemical antiseptics is a reaction against the abuse of those of excessive strength which in former times were indiscriminately applied. One in twenty carbolic lotion and one in one thousand sublimate were in constant use. The surface of the wounds to which either had been applied was coagulated and killed. This layer of coagulation necrosis reached a depth of $\frac{1}{16}$ to $\frac{1}{8}$ of an inch. The inflammation which ensued poured out an effusion which collected and often decomposed unless abundant drainage had been provided.

It may be conceded forthwith that the acme of good operating consists in damaging the tissues as little as possible either by manipulation or with chemicals. But before determining to do without antiseptics the whole organization and environment of the operation ought to be taken

into consideration. If danger is to be apprehended from dust, unskilled assistants, imperfectly disinfected hands or skin, or some source of infection within the field of operation, then it would be better to have the additional security afforded by chemical antiseptics. When asepsis has once been attained it can be continued by using very dilute antiseptics; for the immersion of instruments one in sixty carbolic lotion; for the cleansing of blood from the hands or gloves and for removing blood from sponges I usually use one in two thousand or more often one in four thousand solution of mercuric iodide. But when sure of the environment and assistants, I am quite content to use salt solution. I have not observed that wounds treated in this manner behave differently from those treated with dilute antiseptics. Corner and Nitch¹ report four per cent. of suppuration for the high operation for varicocele; my percentage for 100 consecutive cases of radical cure of hernia done inside and outside the hospital was three per cent. It is usually assumed on quite insufficient evidence that dilute solutions of mercuric iodide are harmful to the tissues. But after their use the naked eye can detect no change in the cut surface of the wound, nor have I been able to detect any change with the microscope. Also one in four thousand solution of mercuric iodide did not cause more alteration in blood than normal saline solution. Therefore for operations done in the air of London, whose bacteriology is beginning to be better understood, I still prefer to use dilute antiseptic lotions; one in four thousand solution of mercuric iodide suffices. When any source of error in the environment or in the preparation of the patient is suspected, the strength is increased to one in two thousand. Doubtless many other antiseptics may be found to fulfil the same purpose, but this happens to be one whose properties are thoroughly well known, and to which I have become accustomed.

But a knowledge of and familiarity with chemical antiseptics is indispensable. Infective conditions of wounds, abscesses, sinuses, and ulcers have to be overcome, likewise those of the urinary bladder, uterus, oral passages, middle ear, lacrymal apparatus, and so forth. The behaviour of antiseptics in the laboratory should be known, but only clinical experience can tell whether they are suitable. Antiseptics which are borne by one patient may not be borne by another. I have seen gangrene of the tip of the finger follow the application of one in twenty carbolic lotion for but a few hours. Iodoform is an excellent application for most patients, but in a few it causes skin eruptions, iodism, or even delirium and symptoms akin to septic intoxication. The urinary bladder is markedly intolerant of the mercurial antiseptics, sublimate, mercuric iodide, or mercuric cyanide. The pain which follows their use is usually

¹ *British Medical Journal*, vol. i, 1905, p. 196.

great, and cystitis may be aggravated. On the other hand, solutions of nitrate of silver in distilled water cause but little pain, and give excellent results. Washing out the urinary bladder with solutions of nitrate of silver is an art in itself, and can only be done properly by one trained in aseptic surgery. Clinical experience also teaches that solutions of peroxide of hydrogen are the most efficacious in infection with bacteria of the colon bacillus group, and other intestinal bacteria. Its use is therefore indicated in cases of appendicular abscess. It also acts well in some pelvic abscesses connected with the broad ligament and Fallopian tubes, also in foul-smelling suppurations in the middle ear. The various antiseptic solutions of creolin, too, are efficacious in the treatment of septic conditions about the rectum or vagina. Solutions of iodine give good results when it is necessary to wash out a large cavity, such as an empyema. There can be no question but that iodoform powder and gauze are valuable in the treatment of rectal wounds. Powdered crystals are the best, and are not so likely to be adulterated.

CHAPTER V

DRAINAGE OF WOUNDS : TREATMENT OF INFECTED WOUNDS

DRAINAGE

WHEN the blood escapes from the vessels and is no longer in contact with their healthy endothelial lining, it clots. Changes begin forthwith in the clot itself, and in the tissues around. Those in the clot, when favourable, lead to the removal of its serum, of its blood pigments, and, lastly, of its fibrin. Or, the clot may be vascularized and organized, and converted into fibrous tissue. Last of all, and most important, it may be liquefied and changed into a dark coloured fluid, which has irritating¹ properties.

This process of liquefaction has been described by Sargent and Dudgeon in connexion with blood in the peritoneum. They attribute it to infection with a staphylococcus albus. My own observations lead me to agree with these observers that liquefied clot is always infected. Serum stained with blood pigment may be mistaken for liquefied clot. In the case of clots in wounds the infection varies, but some form of staphylococcus albus is by far the commonest. A wound clot seldom escapes infection, but fortunately the infection is nearly always of the mildest type, and leads neither to suppuration nor to extrusion of buried sutures.

In the tissues around the extravasated blood an inflammatory process at once begins. The kind of inflammation and its intensity depend in no small degree upon the quantity of clot and upon the kind of change it is undergoing. That which surrounds disappearing or organizing clot is mild and subsides without ill effects. But even this favourable course is accompanied with a slight degree of constitutional disturbance. But when the clot is infected and softens, the accompanying heat, redness, and inflammatory œdema may be so intense that the fluid swelling is thought to be pus, an anticipation which is often realized when the infecting organism belongs to one of the more virulent types of pyogenic bacteria, such, for instance, as staphylococcus aureus.

When we consider the chances of environment infection ; the dangers

¹ An irritant is that which inflames.

of contact infection, especially by the hands; and, finally, the difficulty of disinfecting the skin of the patient, we can easily understand why blood-clots are so often infected, and why their presence in a wound, the tissues, or cavities of the body is so deleterious.

The inferences from this are obvious. During the operation every care should be taken to avoid the extravasation of blood into soft tissues or into places such as Douglas's pouch, whence it might not be removed. The tissues of the axilla, groin, or scrotum are especially liable to fill with blood unless the cut vessels are at once clamped or, better still, clamped with pressure forceps before being cut across. Also every trace of oozing should be stanchèd before the wound is closed. It is not wise to trust to pressure. Also, when the patient is fat, a series of sutures should be put in to bring the cut surfaces of the fat accurately together and obliterate any space into which bleeding might take place. In the scrotum the vessels which retract and contract during the operation relax and bleed afterwards, and as the tissues of the scrotum are so loose, a large hæmatoma easily forms. Therefore, in scrotal wounds free drainage should be provided for the first twenty-four hours. When muscular tissues have been cut across, as, for example, in amputation through the thigh, or in removal of the breast and pectoral muscles, drainage is advisable, also when large areas of cancellous bone are sawn through, as in resection of the knee. It is also wise to provide drainage when there is a cavity which cannot be obliterated by suturing or by pressure, as, for instance, operations in which cranial contents have been removed. Drainage tubes are usually taken out in twenty-four hours, but when their removal at that time might be painful, as in amputation cases, then they are left for four or five days. A great variety of devices have been employed for drainage. The ordinary red rubber tube is the least painful, and is quite efficient. Hæmorrhage is easily excited during reaction by injudicious movement or stimulation.

METHODS OF OPERATING AND ASEPSIS

A great deal of research has been done, and tends to prove that when the wound is closed, bacteria are imprisoned within its lips. We might have assumed this from our knowledge of wound environment, and of the difficulties of skin disinfection. As a rule the imprisoned bacteria are few in numbers, and belong to harmless species, and perish without producing any harmful effects. But we have to reckon with the entrance of more dangerous kinds such as staphylococcus aureus, streptococci, and colon bacillus, which only require to be placed under favourable conditions to develop their highest virulence. A wound provides, of

course, the most favourable temperature. It may also provide the most favourable conditions of moisture and food. A collection of serum within the lips of a wound is a perfect culture medium for bacteria. Such collecting places should not be made, or if made, should not be allowed to remain, or, if unavoidable, should be drained. We have already pointed out the baneful effects of blood-clot. But besides serum and clot, the bruised, damaged, and dead tissues afford suitable breeding places and food for bacteria. Healthy clean-cut tissues bathed in plasma, and full of active phagocytic cells, will resist and overcome a certain dose of infection, but tissues which are torn, bruised, and strangulated by sutures and ligatures serve for their propagation.

Good surgery, therefore, consists in observing the rules of asepsis, but also in making clean, straight incisions right down to the desired point. This should be done with the knife and knife alone. The less the tissues are touched with dissecting forceps, pressure forceps, clamps, or dissectors, the better is their vitality preserved. To make a clean cut down to anything, an accurate knowledge of anatomy is essential. Also anatomical knowledge is needed to recognize the structure which is being sought for, otherwise an unnecessary disturbance of parts makes those recesses in which blood, serum, and eventually pus, collect.

To avoid bruising and extravasation of blood the vessels should be clamped before being cut, or before they have had time to bleed and infiltrate the loose tissues with blood. If possible the clamp should be applied to the vessel itself, and as little tissue as possible included. The vitality of tissues is impaired by crushing, or they may be killed outright. Dead tissues are breeding places for bacteria.

Ligatures should be put on the bleeding vessels themselves and they should not include and strangulate portions of the tissues. Experience has shown that thick ligatures are more likely to grow bacteria than thin ones, so that the thinnest are now used, and yet secondary hæmorrhage is unknown. The thinness of the ligature depends in a large degree upon the force used in tying it. We have here an opportunity for gentle handling and tact. I have already mentioned the way in which the different tissues behave towards sutures and ligatures (see p. 13).

THE ORGANIZATION OF OPERATIONS

In hospitals the organization of operations is carried out by the resident staff, and by the sisters and nurses. In nursing homes there is usually a staff which has been trained in all the methods of preventing infection. But when operations are done in private houses the organization of the operation has to be supervised by the surgeon himself. As

a rule, an operating surgeon has anæsthetists, assistants, and nurses with whom he is accustomed to work, and upon whom he can rely. I believe that when the surgical methods are simple, and aim at sterility, a well-equipped and sanitary dwelling can be made to fulfil the necessary conditions as well as a nursing home, and as well as many of the older hospitals. It is well that this be so, because there are cases of grave emergency which cannot be moved, and must be done on the spot. It is difficult to estimate the relative safety of operations done in hospital, nursing home, or private dwelling. The percentage of suppuration was least in the cases done in private dwellings or hotels (3·63 per cent.), then the hospital cases (5·84 per cent.), and then those in nursing homes (7·6 per cent.).¹ These percentages are too high, and have, I believe, been slightly reduced. It is, however, to be noticed that the class of operation done in private dwellings is rather less severe than that in nursing homes or hospitals.

The first step in organizing an operation in a private dwelling is to see that the sanitation is perfect, and that no sewer gas can enter the room of the patient from any sink, bath, washstand, or drain ventilator. It is often advisable that the surgeon himself should see personally to this point. A well-ventilated, airy, capacious, well-lighted room should be chosen, and one out of the way of the noises of the house or street. It should, of course, contain a fireplace. It is the duty of the nurse to prepare the room not later than the day before. It should be stripped of curtains, carpets, and all articles of furniture which act as dust traps. In London suitable operating tables and utensils can be hired for the occasion, also sterilized gowns and towels. It is usually convenient to have the necessary instruments sterilized and carry them to the scene in a wrapping of sterilized gauze, or of cyanide gauze, but it is quite easy to sterilize towels, basins, jugs, and a large supply of water in a private dwelling.

It is, as a rule, desirable that the surgeon who did the operation should be available afterwards in case of any question arising. But nowadays the telephone is usually found in well-equipped private houses; and operating surgeons are usually provided with motor cars, so that there need not be any delay. Indeed, telephones and motor cars have vastly altered surgical practice. There can be no question but that many operations can be done well and safely in the comfortable and sanitary English home; and amidst their home surroundings the patients are undoubtedly happier and more comfortable. For the friends of the patient the home operation is a great convenience and boon.

¹ *Lettsonian Lectures on Aseptic Surgery in Theory and Practice*, by C. B. Lockwood (London, 1904), p. 39, &c.

TREATMENT OF INFECTED WOUNDS

In hospital practice the system adopted at St. Thomas's is much to be commended. Every case of suppuration is recorded by an independent observer, and posted for public inspection. The kind of infection ought to be recorded too. The kind of infection implies so much.

The treatment of septic wounds has been referred to. When such a misfortune occurs, the first step is a cultural diagnosis of the infection. This is a guide to the degree and course of the infection, and to its ultimate treatment. For instance, an infection with *staphylococcus albus* would probably be attended with moderate constitutional disturbance, and run a favourable course, whilst an infection with *staphylococcus pyogenes aureus*, or with *streptococcus pyogenes*, would be severe, and attended with danger.

The next step is to provide for drainage by opening up the wound, and by putting in rubber tubes. If necessary an anæsthetic should be given and incisions made. Buried silk sutures should be removed, but it is well to wait until the acute stage of septic inflammation has subsided. It is not usual for all the sutures to be infected and require removal, but only a part. Furthermore, during the period of acute inflammation the swelling, bleeding, and suppuration render them difficult to see. If a stitch should remain after the acute inflammation has subsided, it is best to give a general anæsthetic and remove all the septic silk sutures. This is usually a prolonged and troublesome proceeding. Should the septic inflammation not subside with reasonable quickness, the cultural diagnosis is a guide to the next step in treatment. An infection with *streptococcus pyogenes* would call for the use of an appropriate anti-streptococcic serum which, as in a case described by Horder, may be prepared with the streptococcus found in the wound. Or an infection with *staphylococcus pyogenes aureus* might be treated with a vaccine prepared with the culture from the wound. However, it is rare nowadays to have to resort to any of these measures, for the percentage of sepsis is minute, and it is usually of a mild type.

SECTION II
THE METHODS OF LOCAL ANALGESIA

BY

CAPTAIN J. W. H. HOUGHTON, R.A.M.C.

CHAPTER I

INFILTRATION AND REGIONAL ANALGESIA

THE following article is little more than a full abstract of three papers by Mr. Barker of University College Hospital which have appeared in the *Brit. Med. Journal* of Dec. 24, 1904, March 23, 1907, and Jan. 1908, supported by what I have seen of his practice and experimental work as his assistant for many months and my own subsequent experience at the Queen Alexandra Military Hospital at Millbank (*vide Journal of the Royal Army Medical Corps*, Nov. 1907). Mr. Barker has kindly sanctioned my making this use of his contributions to the subject and also of the illustrations published in them, for which I desire to express my cordial thanks.

Though the production of local analgesia has been attempted by surgeons for many years, it was only recently that a degree of success attended their efforts.

The discovery by Corning, in 1885, that cocaine applied to the trunk of a sensory or mixed nerve abolished sensation throughout the area of its distribution was the first step leading to the elaboration of our present methods.

Schleich, utilizing this discovery, did much in evolving a technique which is familiarized under his name; while Cushing and Braun, by independent work, enlarged the scope and usefulness of local analgesics.

For some years cocaine was the drug chiefly employed in the production of local analgesia, but its use was found unsatisfactory.

The toxic effects of cocaine injected hypodermically restricted its use to small quantities in limited operation areas, while the analgesic effect was of short duration and insufficient for any but the simplest surgical procedures. It is, however, still largely used abroad.

These defects were for a time combated by the employment of the drug in high dilution and by frequent fresh injections as its effects passed off. But the method at best was cumbersome.

The discovery of eucaine by Merling removed one of these objections, since eucaine is far less dangerous than cocaine, and of almost equal analgesic value. Other substances have since been used, such as stovaine, eucaine lactate, novocaine, and tropacocaine, which possess good analgesic properties when injected and have less toxic effects than cocaine. The duration of the analgesia can also be prolonged.

Braun was the first to suggest the concurrent use of the active principle

of the supra-renal gland, which has the property of constricting the smaller vessels of a part into which it is injected, so that with a solution containing one of the less toxic analgesic substances and supra-renal extract an injection may safely be made causing complete analgesia lasting from one to three hours.

When adrenalin combined with eucaïne is injected hypodermically, the skin becomes blanched and anæmic. The blood-supply in the part is slowed, and the eucaïne is not carried away at once by the blood-stream into the general circulation, but remains at the site of injection.

By this localization of the eucaïne its effects on the nerves of the part are intensified and prolonged, so that combined with adrenalin less eucaïne is required to produce a complete analgesia.

Also, as the eucaïne is thus localized for a considerable time—an hour or more—it only reaches the circulation of the higher nerve-centres very slowly, and then probably as an innocuous compound having undergone change during its local absorption in the tissue cells. Braun found experimentally that a lethal dose of cocaine, if combined with adrenalin and injected into a rabbit, produced little or no toxic effect.

A knowledge of these facts enables us, on the one hand, to employ less of the drug when adrenalin is added, seeing that its analgesic action is concentrated locally, and, on the other hand, it justifies us in increasing the area of injection, and if necessary the amount of eucaïne, since its toxic effects on the higher nerve-centres are restrained or abolished.

I have on more than one occasion injected six grains of B. Eucaïne combined with adrenalin where an extensive area had to be dealt with in an adult, with no immediate or subsequent ill effects. In practice this amount suffices for the larger operations, and should be regarded as a maximum. There is another factor to be considered, which is essential to the success of any hypodermic injection, namely, the osmotic tension of the injected fluid.

It has been found experimentally that the endermic injection of physiological salt solution (0.9 per cent. NaCl) produces a painless wheal, and that the injection of distilled water causes a burning pain, with great irritation of the part, which may be followed by local necrosis, though the injected fluid be sterile.

The hypodermic injection of saline solutions of varying strengths will produce irritation and necrosis or painless swellings according as they differ from or approximate to the normal physiological strength, 0.9 per cent. NaCl, which has the same osmotic tension as the blood (see Fig. 1).

The osmotic tension of a fluid can also be determined by cryascopy, Beckmann's apparatus showing the temperature at which blood freezes

to be 0.56° C., while 0.9 per cent. NaCl in distilled water has the same freezing-point.

The importance of these considerations becomes evident when we realize that the injection of an isotonic fluid is harmless to the tissues, while the injection of a non-isotonic fluid will cause irritation, delay healing, and may cause local necrosis.

The selection of the most suitable analgesic substance is our next consideration, and, while I have given several of them an extended trial, including stovaine and novocaine, I find that for ordinary procedures none gives more satisfactory results than the hydrochlorate of B-eucaine, a synthetic product, chemically known as benzoyl-vinyldiaceton-alkamin.

This substance occurs as a white powder, soluble in water to the extent of $3\frac{1}{2}$ per cent., and can be sterilized in solution by boiling without undergoing change.

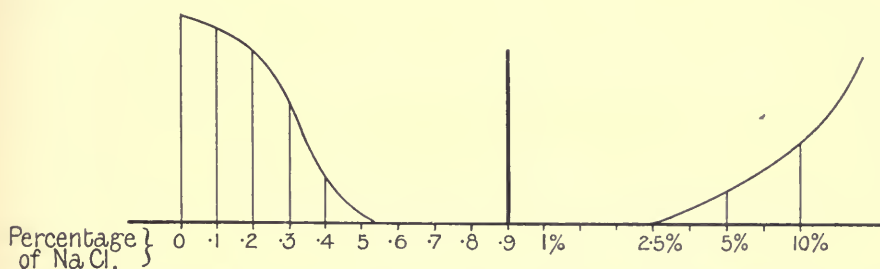


FIG. 1. DIAGRAM ILLUSTRATING THE IRRITATION PRODUCED IN THE TISSUES BY INJECTIONS OF SODIUM CHLORIDE SOLUTIONS OF VARIOUS STRENGTHS. (After Braun.) The curved line denotes the degree of irritation produced.

The most suitable strength of the eucaine and adrenalin solution has only been determined after much experience.

I have found that for ordinary surgical work the quantities formulated by Braun and adopted by Mr. Barker, of University College Hospital (whose work with local analgesia is well known), cannot be improved upon.

The amounts are as follows :—

- B-eucaine 0.2 gram. = 3 grains
- Sodium chloride 0.8 gram. = 12 grains
- Aqua destillata 100 c.c. = $3\frac{1}{2}$ oz.
- Adrenalin chloride (1 in 1,000) min. 10

the strength of the adrenalin chloride in this solution being 1 in 200,000, and that of the B-eucaine 1 in 500.

All this fluid can be safely injected, if necessary, and is ample for any ordinary procedure, but I have injected double this amount of solution when extensive areas had to be dealt with, and have seen no subsequent ill effects.

This solution produces no pain on injection, and does not cause loss of vitality in the tissues. It freezes at the same temperature as blood, and is therefore isotonic.

The solution is easily made : a glass beaker is obtained of about 200 or 300 c.c. capacity, and 100 c.c. of distilled water poured in ; to this are added 0.2 gramme B-eucaine and 0.8 gramme pure sodium chloride, and the contents are boiled.

After a few minutes' boiling to ensure sterility, the beaker is cooled to blood heat and 10 drops of a 1 in 1,000 solution of adrenalin chloride are added, and the solution is ready for use. If boiled longer, enough sterile water must be added to bring the amount up to 100 c.c.

A syringe (see Fig. 2) of about 10 c.c. capacity, with a fine needle and able to withstand boiling, completes the outfit. The syringe which has given most satisfaction is that recommended by Mr. Barker. It is made of glass and metal, with a vulcanite piston, and supplied with a straight and curved receiving tube (see Fig. 3), to which a Freienstein needle can be fitted by means of a small screw cap.




FIG. 2. SYRINGE FOR SUBCUTANEOUS INFILTRATION.

A long *blunt* needle (see Fig. 4) with a lateral eye and special cap with rubber washer, devised by Mr. Barker, is also of service for deep infiltration in the neighbourhood of vessels or parts liable to be wounded by a sharper instrument.

In using this solution, a few practical points may be noted :—

(1) The solution should be freshly made, and boiled to ensure its sterility. Compressed powders containing B-eucaine and sodium chloride in the above proportions are easily procurable.

(2) The liquid preparations of supra-renal extracts lose their specific action as vaso-constrictors when boiled or after exposure to light and air ; while the dried preparations are often uncertain in action and of doubtful sterility. Hence adrenalin solution, which is issued sterile in ruby-coloured bottles, must be carefully stoppered when not in actual use, and guarded from extraneous contamination.

(3) When brought in contact with an alkali, supra-renal extract becomes inert, hence all sterilization of the syringe must be done in pure distilled water.

The recent synthesis of adrenalin, however, gives us a substance of

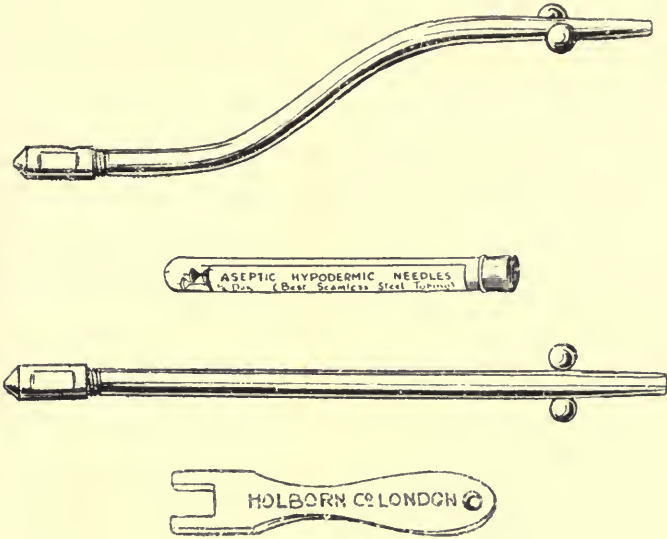


FIG. 3. NEEDLE-HOLDERS. These fit the syringe, and the hypodermic needles are fixed into the steel cap at the end. The small spanner is for tightening the steel cap when adjusting the needles.

equal value as a vaso-constrictor and greater stability in that it is unaffected by light and does not deteriorate when boiled in dilution. When added to eucaïne solution it undergoes the same colour-change to pink as does the ordinary adrenalin solution.




Fig. 4. LONG NEEDLES FOR SUBCUTANEOUS INFILTRATION. These needles have a blunt end and a lateral opening.

The duration of the analgesia depends upon the adrenalin added. Without adrenalin, sensation is only suspended by eucaïne for fifteen minutes, with it for two or three hours,—as long, in fact, as the ischæmia lasts. But, on the other hand, the analgesia is produced more slowly when adrenalin is employed with eucaïne. It is advisable, therefore, before all larger opera-

tions, to wait some thirty minutes after injection before proceeding to operate. This time is necessary to allow the eucaïne to exert its maximum effect, and the infiltration œdema to subside, when the anatomical landmarks of the injected area become plainly visible. This is due to the anæmia produced by the adrenalin showing white in comparison with the surrounding skin, and is of use to the surgeon in defining his limits of insensibility.

Local analgesia may be induced in a given area by two different methods :—

(1) By the injection of eucaïne solution directly into the tissues to be operated upon, sometimes termed infiltration analgesia.

(2) By the injection of eucaïne solution into or around the nerves supplying a given part. This produces a break of nerve conductivity at the level of the injection, while motor and sensory paralysis follow in the distribution area below the level of the injection. This has been termed regional analgesia.

No rigid distinction, however, need be drawn between these two methods, as in practice excellent results are often obtained by a combination of both.

As an illustration of the technique employed : suppose a patient with varicose veins requires their excision.

The skin of the leg having been carefully prepared and the position of the vein marked, the eucaïne solution and syringe are sterilized and cooled.

The syringe (see Fig. 2) is now filled, taking care that all air-bubbles are excluded, and the needle mounted in the bent holder (see Fig. 4) is thrust into the skin over the vein and the solution slowly injected. A wheal is formed, and the skin is raised by the injected fluid over an area of about 2 inches in length and 1 inch in breadth. The needle is now withdrawn, and the syringe being refilled, it is again inserted at the extremity of the wheal, where sensibility is diminished, and more solution is injected.

The tissues on each side of the vein are injected in like manner until the infiltrated area is of sufficient extent to cover the requirements of the operation. Twenty c.c. of the solution are usually ample for each vein. Half an hour is allowed to elapse before the operation is begun, during which time other cases can be infiltrated or the surgeon's hands and instruments receive their final sterilization.

By the end of this time, the œdema has nearly disappeared. The infiltrated area appears white, and is an excellent guide to the extent of the analgesia. An incision may now be made, when on cutting the tissues their bloodlessness will be remarkable.

For the removal of a finger or toe regional analgesia is more suitable. Suppose that amputation of the terminal phalanx of a digit is necessary.

The usual preparations being complete, the needle is inserted at the base of the finger. Eucaine solution is injected superficially and deeply on all sides, and a distended ring is formed around the base of the finger, the object in view being to infiltrate all the nerves to the part, both the



FIG. 5. INFILTRATION OF THE SKIN IN OPERATIONS FOR GOITRE. The continuous line shows the incision and indicates the region in which the superficial infiltration is performed. (After Barker.)

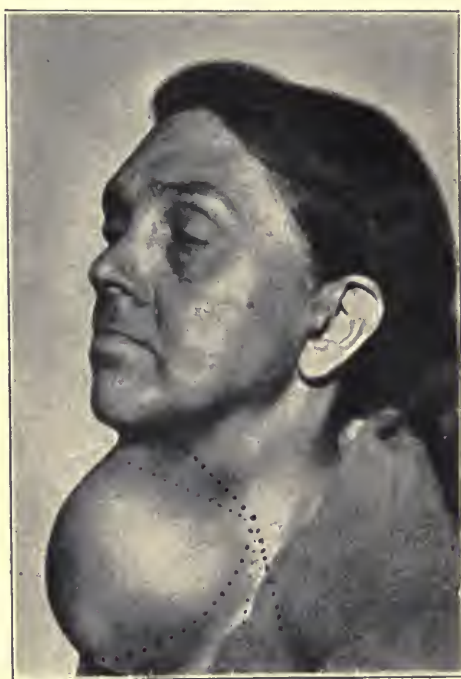

FIG. 6. INFILTRATION OF THE DEEPER STRUCTURES IN OPERATIONS FOR GOITRE. The dotted lines show the directions in which the blunt needle is pushed to infiltrate the deeper structures. (After Barker.)

deeper nerve-trunks and the finer superficial nerve-twigs, and thus to produce a break of nerve conductivity at the level of the injection. After thirty minutes the surgeon can proceed to amputate with perfect confidence that the patient will feel no pain.

For the removal of a thyroid tumour, a combination of infiltration and regional analgesia is best adapted. Here, not only the skin incision but the deeper parts to which the operation will extend require consideration. It will be necessary, therefore, so to inject, as to bring the solution

in contact with most of the nerves of the cervical plexus, at points well above the field of operation.

Suppose Kocher's collar incision is selected.

The skin is first injected along the line of the proposed incision (see Fig. 5), then with the long blunt-pointed needle (see Fig. 4) mounted in the holder (see Fig. 3), a preliminary puncture having been made with a large Hagedorn's needle thrust under the skin, the solution is injected hypodermically so as to infiltrate all the nerves reaching the part from above and laterally. The lines of injection with the blunt needle are shown by dotted lines (see Fig. 6).

Particular care must be given to those nerves approaching the tumour round the sterno-mastoids, where a deeper injection is necessary.

To ensure all the nerves being saturated in their various planes, a large amount of solution must be used and ample time allowed for the eucaïne to exert its full effect.

The procedure in these three cases has been more fully described as indicative of what may be successfully undertaken by this method. But local analgesia is admirably adapted for other surgical procedures, such as the removal of cysts and inflamed bursæ, the excision of pieces of rib, or operations on the male genitalia.

For the removal of foreign bodies such as needles, or any operation on the extremities, where the nerves can easily be infiltrated on the proximal side, this method will be found most useful.

It is especially indicated for the operative treatment of strangulated herniæ in old people, or those with pulmonary or cardiac affections, where the administration of a general anæsthetic is attended by grave risks.

Whether this method should be used as a routine in the performance of such operations as the radical cure of hernia and appendicectomy may be left to individual judgment.

For abdominal operations, more perfect insensibility with complete muscular relaxation can be obtained by the induction of *spinal* analgesia.

Local analgesia should not, however, be attempted in cases where the surgeon has doubts as to the extent of his manipulation. It must never be forgotten that the analgesia is only local; so dragging of the tissues must be carefully avoided, lest structures be pulled upon which lie outside the anæsthetic area.

This is especially to be remembered in abdominal operations, where the extreme sensitiveness of the parietal peritoneum is not easy to abolish, while the intestines, though insensitive, should be lightly handled or a drag will be felt on the mesentery, which has the reflexions of the parietal peritoneum at its root.

As a rule, local analgesia is not suitable for operations on children or on adults lacking in self-control, as the operator requires the confidence and co-operation of the patient. To gain this he must have confidence in his methods and by his manner communicate this feeling to the patient.

As for general anæsthesia, so also for local, the preparation of the patient beforehand is important. All cleansing of the skin and operation area should be completed before the injection is attempted. A preliminary fast is not necessary, but a light meal or a little stimulant has a sedative effect on the nervousness of one facing an operation, while an anxious patient may be soothed by a small injection of morphia.

During the operation, it is inadvisable to allow the patient a view of the proceedings or to ply him with questions as to his sensations.

If he has pain he will immediately notify the fact, while his natural apprehensiveness may be allayed by a cup of tea or some light literature. After operations done in the above manner it is not necessary to keep the patient in the recumbent position as was formerly the case with cocaine. Many of my patients have walked away after operation.

As the analgesia passes off, and sensation returns in the part, pain may be felt in the wound.

This is only what occurs when a general anæsthetic is administered, and seldom requires the administration of a sedative.

When the vaso-constrictor action of the adrenalin wears off, reactionary hæmorrhage need not be feared, unless some larger vessel has been left unsecured, or too much adrenalin has been added to the solution. I have not experienced such an occurrence. Doubts may also be entertained as to the rapidity of wound healing after large injections. These are groundless, as experience shows that when the solution is isotonic and sterile, primary union is invariable.

The term analgesia, as applied to this procedure, has been used in preference to anæsthesia. It is more accurate, for in many cases tactile sensation is not completely lost, though pain in the same area is entirely abolished.

CHAPTER II

SPINAL ANALGESIA

A FURTHER development of regional analgesia is to be found in the production of spinal analgesia. In this method, the physiological block to afferent and efferent nerve impulses is effected nearer the great nerve centres, the spinal canal itself being the site of the injection.

When considering the mechanism of anæsthetics we at once recognize that the principles underlying general anæsthesia and those on which local anæsthesia are based are widely divergent.

In general anæsthesia the higher nerve centres are first affected by drugs, and through them the cord and nerves to the site of operation. Thus the whole system is saturated with a powerful drug to produce unconsciousness of pain during manipulation in some limited area.

In local analgesia, *per contra*, the object in view is to produce a painless area of sufficient extent to permit the same manipulations to be undertaken, and to accomplish this without the general flooding of the tissues by a toxic agent. According to the degree of success attending this latter aim will it appeal to the interest of the surgeon and affect the welfare and safety of his patient.

Though puncture of the spinal canal has been practised for many years as a recognized aid in diagnosis and in the treatment of various diseases, it was but recently that the idea of injecting the dural sac to produce analgesia was evolved.

About ten years ago spinal analgesia was first produced by Bier with cocaine, and a week later he requested his assistant to inject his own lumbar sac to observe its effects. On the same day he injected his assistant, and their careful observations on themselves did much to place the use of cocaine in this way in its true position and to show its special disadvantages. During the last five years, since the discovery of stovaine by Fourné, the procedure has become established, and in the hands of careful pioneers has been adopted in general use.

This delay was due to the avowal by Bier, after a cautious trial of the method, that so long as cocaine was the only drug available, the disagreeable sequelæ seen in some cases would prevent the general adoption of spinal analgesia.

With the use of stovaine a new point was reached, and the results since obtained in thousands of cases in France and Germany, and hundreds in England, demonstrate that an addition to our surgical resources of enormous value has been made.

In considering the advantages obtained by this method the following points become prominent :—

A small quantity of an analgesic agent is localized in the spinal sac, the higher nerve-centres being as a rule unaffected. This is surely less harmful than charging the whole circulation with a poison such as chloroform.

The heart and lungs are scarcely affected, so that in morbid conditions of these organs, life-saving operations are rendered possible, which would have been almost certainly fatal under general anæsthesia. There are many people also whose dread of a general anæsthetic will cause them to refuse an operation of even the most urgent necessity rather than to submit themselves to the effects of general anæsthesia.

To these spinal analgesia is an inestimable gain. There are, of course, some dangers attached to the proceeding. Septic organisms may be introduced into the spinal meninges. But no one should attempt this procedure whose aseptic technique is not unquestionable; while the simplicity of the apparatus required renders the danger of infection far less than in many operations daily undertaken. The syringe and needle with the small amount of solution necessary can easily be sterilized by boiling. The amounts of solution required for injection are now well known, so that an overdose should be equally impossible.

So far, spinal analgesia has only been generally applied to the lower half of the body, although some have used it exceptionally for thoracic operations or even higher. Nevertheless, if it only be found safe and of value below the xiphisternum, and local or regional analgesia be employed for the upper part of the body, much will be gained.

As to the age limits of applicability, no hard and fast rule can be laid down. The method has been used on children by Deetz with success, and operations have been undertaken on individuals of 80 years of age.

In old people, however, with damaged lungs, liver, kidneys, or heart, all operations with any anæsthetic are more or less dangerous, and in such cases it is difficult to apportion the risk between the anæsthetic and the shock of apprehension, or of the operation itself, even though the last be slight. Syncope is very likely to follow even slight violence without operation in old, decrepit people.

Perhaps it is well, therefore, at all events for the present, to avoid spinal analgesia in very old individuals; at least, this appears to be the opinion of many of those who have had the largest experience of the

method. It is just in such cases that regional analgesia is so useful, and can be employed much more often than is generally supposed, and with risks so small as to be negligible.

Sex offers no bar to the procedure. It is as suitable for women as for men: In fact, the case of a nervous countrywoman has given prominence to this. She received an injection on two separate occasions. At the first operation she was tearful and excited; a fortnight later she volunteered readily for another 'prick in the back', and was cheerful throughout the operation, having felt nothing after the initial puncture on either occasion.

The duration of the analgesia varies somewhat, the average time being about one hour, while the time from injection to complete analgesia is from two to ten minutes. These periods can be modified by altering the dose and the position of the patient, and will be more fully discussed when the technique is under consideration.

The usual sequence of events after injection is, first, formication in the feet; then loss of the knee and cremasteric reflexes, followed by loss of sensation, usually first in the perineum, and later in the feet, groins, and abdomen. Here again the position of the patient during and immediately after injection is a determining factor in modifying the course of events.

In approaching this subject of the production of analgesia by the injection of drugs into the spinal canal, and thus causing a physiological block in the lower nerve-roots, we are confronted by several problems. The ease or difficulty of their solution is only fully realized during practical experience of the procedure.

The results obtained at first, by earlier workers, were irregular or 'wayward', both as to the height and duration of the analgesia, while several cases suffered from those 'by-effects' which led to the disuse of cocaine. This is not surprising when we realize that in the adoption of a new method, new principles are involved, which require careful study before they are fully understood. This want of uniformity which was experienced by early operators has shown itself in various ways.

First, it was noted, as a rare exception, that where lumbar injection has been accomplished apparently correctly, no effect whatever has followed.

Secondly, where analgesia has followed injection, the height or duration of the analgesia was not sufficient for the completion of the operation; for instance, a gastro-enterostomy was required in a patient, and analgesia was only adequate to the level of the umbilicus.

Thirdly, that a series of cases may be injected with the same amount of the same solution, and no 'by-effects' follow; then two or three cases may suffer from headache or sickness, though the conditions in all have apparently been the same.

These experiences lead to a consideration of the following questions :
How to explain that in a few cases no analgesia at all follows an apparently orthodox injection ?

How to account for the occasional variations in height and duration of the analgesia ?

What are the causes of these ' by-effects ', which, though slight, are not infrequent, and how may they be eliminated ?

As these difficulties were met by several workers in earlier cases, their explanations are now available for those about to undertake this method. There is no doubt that when no effect at all followed the injection, this was due to the fact that the needle had only partially entered the dural sac ; and, though the spinal fluid flowed from the needle on puncture, the injection did not enter the sac at all.

This difficulty has been surmounted by the use of a canula longer than the puncturing needle, and is referred to more fully later.

The variations in height and duration of the analgesia may be accounted for in some cases by the imperfect penetration of the dura and consequent loss of some of the injection fluid outside the sac.

In other cases this want of uniformity may be due to a difference in the physical properties of the injected solutions, altering their behaviour within the spinal canal.

The ' by-effects ' may be caused by the altered pressure in the dural sac, as much as by the injection of a toxic drug ; for they are known to occasionally follow simple lumbar puncture when no substance of any kind has been injected.

The compound used to suspend the functions of the nerves with which it comes in contact, and thus to permit of lengthy operations being performed under its influence, should have other attributes to commend its use.

It should cause no local or general permanent ill effect to the tissues of the body, and no transient disturbances in them apart from its specific action. The first of these requirements has been met by stovaine and several other drugs.

Stovaine has been found in local, regional, and spinal analgesia to suspend the functions of nerves for a variable period. With the addition of the active principle of the adrenal gland, the duration of its specific effects has been much prolonged. In one reported case analgesia lasted as long as five hours.

The advantages to be gained by such prolonged analgesia, however, are not apparent, while the addition of adrenal substance is of doubtful expediency and possible danger. The less disturbance produced in the spinal canal the safer the procedure, and the adrenal compounds are not

altogether free from irritating properties. Stovaine alone has been, so far, found to produce no local or general ill effects on the tissues when properly used, and thousands of patients who have undergone local and spinal analgesia with it are now going about years after, showing no injurious effects of any kind (Tuffier).

The intra-dural injection of stovaine, however, is occasionally followed by transient by-effects, which, though causing temporary discomfort, soon pass away, and are of small consequence. Their causation has been variously explained. Headache and faintness have been ascribed in many cases to psychical disturbances, which is not unreasonable where they occurred during or just after operation.

Where the headache has been more persistent, it may be due to an alteration of pressure within the spinal sac, caused either by the sudden withdrawal of cerebro-spinal fluid, or by mild irritation the result of the puncture, or the stimulus of the injection. In some cases in France, where the headache resisted other treatment; relief was obtained by subsequent lumbar puncture and the removal of a few cubic centimetres of fluid. Such cases have all apparently done well ultimately. Nausea and vomiting occur in a few cases, and usually pass off quickly. They seldom supervene if the patient is kept quiet and not shaken during the operation or in removal to the ward, and probably follow the same causal agent as the headache.

Whatever their explanation, these 'by-effects' remain obscure, the more so as they are not uniformly present, a majority of cases showing no signs of them. With experience in the procedure and careful attention to details based on a study of the physical factors involved, their occurrence is reduced to a minimum.

That the specific action of stovaine is limited almost exclusively to the locality into which it is injected in moderate doses seems highly probable from experience in its use as a local and spinal anæsthetic.

Its effects on the pulse are slight, and a patient after injection usually looks and feels as warm as before. Where large doses have been given this may not be the case, but after injection of moderate doses no well-defined general effects of any great importance have been observed independently of its specific action.

As in all injections into the tissues, the sterility of the injected fluid is of prime importance. In intra-dural injections this is a *sine quâ non*. With stovaine this is easily secured, as its solutions may be boiled under pressure at 115° C. for fifteen minutes without loss of potency. Too much or too prolonged heat renders it inert, which may explain an occasional failure in its use unless it has been prepared by an expert.

Also, all fluids injected into the body tissues should possess the same

osmotic tension as the blood serum. In other words, they should produce neither shrinking nor swelling of the blood or tissue cells by osmosis. The importance of this has been explained in connexion with fluids for local infiltration, and in great measure the same reasoning holds good for intra-dural injections. It has been found experimentally that a 5 per cent. solution of stovaine in distilled water freezes at about $0.58^{\circ}\text{C}.$, almost the same point as that of blood serum, which freezes at $0.56^{\circ}\text{C}.$

If this were the only test applied, stovaine in 5 per cent. solution should be nearly isotonic with the blood.

If a drop of blood, however, be added to a 5 per cent. or 4 per cent. solution of stovaine and the mixture be examined under the microscope, in five minutes the red corpuscles will be found pale and swollen, in ten minutes nearly invisible, and in twenty minutes they have all disappeared (Barker).

Or again, if a 5 per cent. solution of stovaine together with a truly indifferent solution such as normal saline, 0.91 per cent. NaCl, or normal glucose solution, 5 per cent. glucose in distilled water, be drawn into a sedimentation tube with a droplet of blood, the hæmoglobin becomes rapidly diffused in the column of liquid, and there is no sedimentation of blood cells (Barker).

This does not occur if stovaine is not added to these normal solutions—a control showing the cells unchanged at the end of twenty-four hours.

Thus stovaine has a specific hæmolytic action. In further proof of this it is found that, to an isotonic solution of NaCl or glucose, in which blood cells are seen to be unaltered after twenty-four hours, if a 5 per cent. solution of stovaine be added, the cells rapidly swell, grow pale, and disappear, no trace of them being left in $1\frac{1}{2}$ hours. No combination of NaCl or glucose with stovaine has as yet prevented this hæmolytic action of the drug. Also, if a 5 per cent. solution of stovaine be mixed with an equal quantity of cerebro-spinal fluid, and a drop of blood be added, complete destruction of all blood cells occurs in about one hour, and nothing is then seen under the microscope but débris and oily globules (Barker, *loc. cit.*).

From this we may surmise that a 5 per cent. solution of stovaine injected into the spinal canal is also hæmolytic, though there is no evidence to show that the small amount of the drug injected has produced any injurious effect as the result of its hæmolytic action.

There are, moreover, other physical qualities which an injection compound may possess, which until recently appear to have been overlooked or insufficiently studied. Amongst these, the question of the density of the injected fluid in comparison with that of the liquor spinalis has only lately received due consideration (Barker, *loc. cit.*).

There are only three ways by which an analgesic solution injected through the second lumbar interspace can make its direct effects felt in the mid-dorsal region, or even higher, as is sometimes the case in this procedure. These are either (1) by slow diffusion; (2) by a shifting upwards of the whole column of cerebro-spinal fluid in which it is suspended; (3) by gravitation, if the injected compound be heavier than the liquor spinalis.

It must not be forgotten that spinal analgesia is only an extension of the principle of regional or local, in which the drug is brought into direct contact with certain nerve-elements whose functions it is desired temporarily to suspend. Within the spinal dura, which we are precluded from injecting above the second lumbar interspace, it is desired in many cases to affect the roots or cord as high as the mid-dorsal region. This can only be accomplished in one of the ways indicated above, modified, of course, more or less, by their combinations.

(1) Diffusion alone of one fluid in another is a slow process and is unlikely to be the mode by which the injected fluid is spread in this procedure.

(2) Bier and his followers have aimed at shifting the injected compound upwards or downwards with the whole mass of the liquor spinalis by raising or depressing the pelvis.

That the cerebro-spinal fluid does recede somewhat towards the head on elevation of the pelvis is undoubted, but it is difficult to imagine its receding to such an extent as to carry with it a mass of fluid lighter than itself the distance from the second lumbar to the fifth dorsal vertebra, some eight or ten inches. It is probable that with such a fluid as he has used, whose specific gravity is 1.0058, suspended in the liquor spinalis, whose specific gravity is 1.0070, what was achieved by elevation of the pelvis was rather a more rapid diffusion of the injected fluid, due to the consequent oscillation of the liquor spinalis, aided, perhaps, by vascular pulsation.

This rapid diffusion would, of course, dilute the injection and might, perhaps, carry it further than was desirable.

(3) There remains, then, the third possibility, namely, the action of gravity. This force may affect an injected fluid heavier than the liquor spinalis, and carry it through the latter to the most dependent position of the canal. Thus a heavier injection may behave quite differently to one of lesser density such as that just referred to.

It is easy to observe the behaviour of one fluid injected slowly into another, if the first be coloured with an aniline dye. If both have the same temperature and specific gravity, the injected fluid forms at first a distinct coloured cloud, which slowly diffuses itself through the whole

mass into which it enters, if the latter be in a state of rest. On the other hand, if the injected fluid has the same temperature, but a much greater sp. gr., it sinks rapidly in a definite stream to the bottom of the second fluid, and remains there as a distinct stratum without diffusion, for a time proportionate to its density and viscosity (see Figs. 7 and 8).

A consideration of these points shows that if we aim at localizing a spinal injection to any particular region of the cord we can utilize the force of gravity acting upon an injected compound of greater density than the liquor spinalis.

Thus, the heavier injection would sink to the lowest part of the canal, independently of any displacement of the cerebro-spinal fluid.

Here it would remain, more or less undiluted, in contact with the surrounding structures.

The densities of some of the compounds used to produce spinal analgesia taken at room temperature are here appended:—

(1) Chaput's—Stovaine 10 per cent., NaCl 10 per cent., distilled water 80 per cent. Sp. gr. = 1.0831.

(2) Barker's (No. 2)—Stovaine 5 per cent., glucose 5 per cent., distilled water 85 per cent. Sp. gr. = 1.0230.

(3) Bier's—Stovaine 4 per cent., NaCl 0.11 per cent., Epirenin borate 0.01 per cent., aq. destill. ad 100 per cent. Sp. gr. = 1.0058.

Cerebro-spinal fluid. Sp. gr. 1.007.

The first of these compounds, a very heavy fluid, in which the common salt is present at the point of saturation, at ordinary temperatures has long been used by Chaput and Tuffier with good results.

Their reasons for employing such a high percentage of sodium chloride, as stated by the former, were that M. Billon, who prepared the compound for them, hoped thereby to prevent the splitting up of the stovaine by the alkalinity of the spinal fluid.

That it does not do so is evident to any one who adds some of this compound to the cerebro-spinal fluid withdrawn. It will then be seen that the latter becomes almost at once milky in character. If a little of the fluid in this state be examined microscopically, it will be seen that this turbidity is due to the presence of small particles of an oily nature, which in the course of time run together into larger globules.

The undoubted success which has attended the use of this compound is probably due to its high sp. gr. Owing to this it sinks rapidly and almost undiluted through the lighter spinal fluid, and comes to rest in an almost unbroken stratum at the lowest point it can reach in the spinal canal.

It has, however, the defect that its high percentage of NaCl alone renders it much more hypertonic than the other two fluids, which in conjunction with the hæmolytic action of the stovaine, ought to lead, at

least theoretically, to some irritation of the tissues with which it comes in contact. This is to some extent diminished no doubt by the French method of injection, in which the small amount of compound in the syringe is mixed before injection with the spinal fluid escaping from the needle by first drawing back the piston before the syringe is emptied into the canal.

This hypertonicity is strongly objected to by many, and has in fact been supposed by some to be the cause of the headache which sometimes followed the use of this solution, and possibly also of the occasional sickness.




FIG. 7. A METHOD OF ILLUSTRATING THE POSITION ASSUMED BY A HEAVY INJECTION FLUID (sp. gr. 1.0230) UNDER THE INFLUENCE OF GRAVITY. The glass tubes are bent to the curves of the spine and are filled with normal saline solution (sp. gr. 1.0060). A represents the vertical position for injection, B the dorsal position assumed after injection, and C the lateral position. (From Mr. Barker's photographs of his tubes.)

Bier's compound, on the other hand, is actually lighter than the cerebro-spinal fluid, and can only be moved in the spinal canal by diffusion or oscillation of its contents in elevation of the pelvis.

In consequence of its greater weight the glucose-stovaine solution

may, like Chaput's, be made to flow in any direction within the canal, in obedience to the laws of gravity. It is also slightly viscid, and remains for a considerable time undiffused, the drug exerting its full power at a given point.

With a solution such as this, of comparatively high density and viscid character, diffusion and consequent dilution are limited. Thus a smaller




FIG. 8. APPARATUS DESIGNED TO SHOW THE RESULT OF INJECTIONS OF COLOURED FLUIDS OF VARIOUS SPECIFIC GRAVITIES. The tubes are bent to the curves of the spinal canal and are filled with normal saline solution (sp. gr. 1.0060). The top tube contains Bier's light solution (sp. gr. 1.0058), the middle contains Chaput's solution (sp. gr. 1.0831), whilst the lowest contains Barker's (No. 2) solution (sp. gr. 1.0230).

dose can produce a full effect, and the solution, by means of gravity, be localized so as to exert its specific action at the desired level.

Whether this stovaine-glucose solution will in its further use satisfy all the requirements supposed to be desirable, remains to be seen in a larger number of cases. Theoretically it ought to be safe, and in the cases where it alone has been used the results were remarkably uniform. In the last

200 cases I have noted, a solution containing 5 per cent. glucose and 5 per cent. stovaine was used.

In all these cases the aim has been to keep the amount of the drug as small as possible, and to carry the effect on the nerve-roots by position or slight elevation of the pelvis only as high as was considered absolutely necessary for the operation in hand.

Considerable headache was seen in 23 per cent. of these cases, and vomiting in 15 per cent., either during or after operation, but in only three cases were either intense.

From what I have seen in 200 cases injected by Mr. Barker at University College Hospital, and in nearly 100 cases injected by Major Spencer or myself at Millbank, I am inclined to think that the frequency and extent of these sequelæ are largely determined by movements of the solution in the spinal canal caused by either a lowering of the patient's head and neck, or by a disturbance of his body position. Those patients whose heads were sufficiently raised and whose positions were unaltered after the injection appeared to have escaped all but the most trifling subsequent by-effects.

There are several other drugs which have been used to produce spinal analgesia, differing widely in their physical properties.

Their sp. gr. and freezing-points in 5 per cent. solutions are here given, and show a remarkable difference between each other and between the sp. gr. of the liquor spinalis. Hence they would behave quite differently if injected into the latter.

Alypin 5 per cent., aq. destil. 95 per cent., sp. gr. 1.0056, freezing-point 0.053° C.

Novocaine 5 per cent., aq. destil. 95 per cent., sp. gr. 1.0090, freezing-point 0.555° C.

Tropacocaine 5 per cent., aq. destil. 95 per cent., sp. gr. 1.0106, freezing-point 0.0545° C.

Stovaine 5 per cent., aq. destil. 95 per cent., sp. gr. 1.0064, freezing-point 0.0585° C.

Cerebro-spinal fluid, sp. gr. 1.007.

It is quite evident that a 5 per cent. solution of alypin, with its low sp. gr. 1.0056, ought to float in the higher layers of the spinal fluid, while a 5 per cent. solution of tropacocaine, with a sp. gr. of 1.0106, would rapidly sink to the lower layers. The greater uniformity of results which are claimed by some for tropacocaine may, possibly, be due in part to its greater density, perhaps more so than to any difference in its specific action on nerve-structures.

We cannot, therefore, expect to obtain exactly uniform results if we employ solutions of widely different specific gravities.

A failure to appreciate this may largely account for the irregularities which have been reported in the action of some of these drugs.

To demonstrate the general behaviour of various fluids when injected into the spinal canal, glass tubes, bent as accurately as possible to the

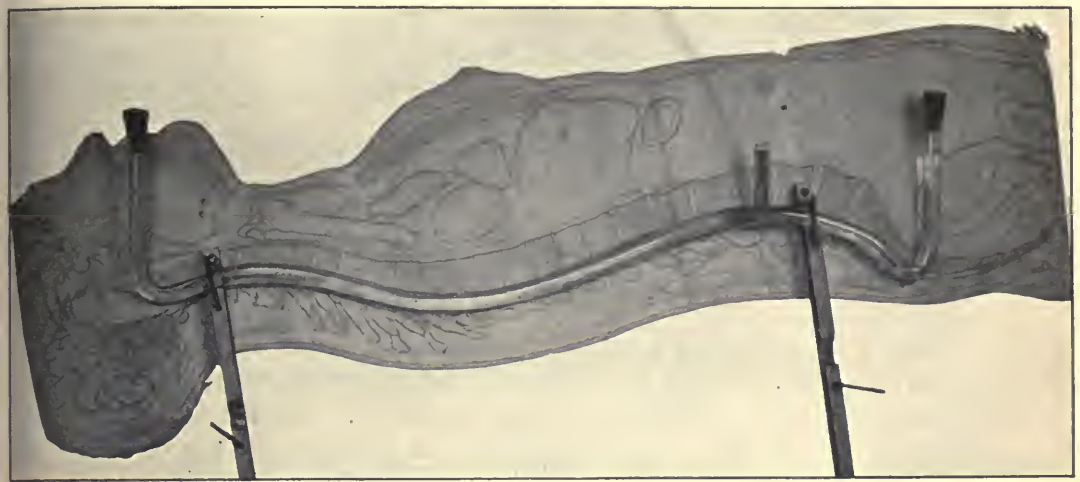


FIG. 9. GLASS TUBE SHOWING BIER'S LIGHT SOLUTION REMAINING ABOUT THE POINT OF INJECTION. The glass tube follows the curve of the spinal canal, and is applied over a drawing taken from Braune's frozen section; the injection is introduced through the vertical arm.

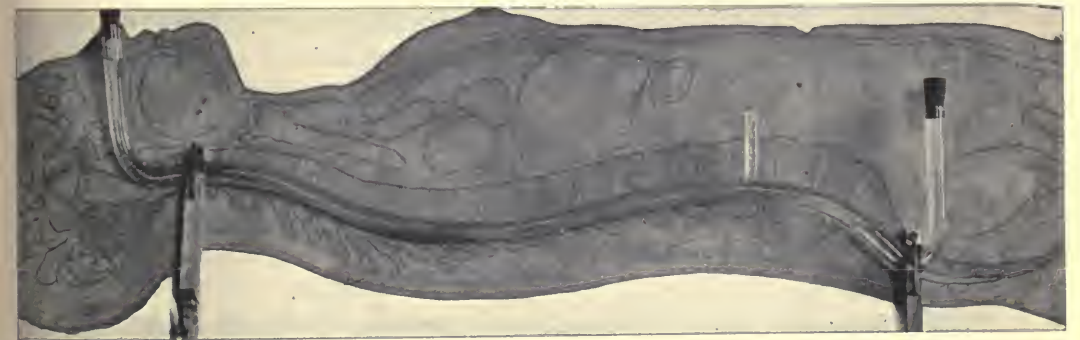

FIG. 10. GLASS TUBE SHOWING THE GRAVITATION OF A HEAVY INJECTION FLUID. The fluid, which is coloured, has gravitated to about the fifth dorsal vertebra.

curves of the spinal canal, have been made by Mr. Barker (see Figs. 7 to 10). These were filled with saline solution of sp. gr. 1.0070 to represent the cerebro-spinal fluid, and have been used at various inclinations to observe what occurs, at all events *in vitro*, when some of the different compounds now in vogue for spinal analgesia are injected into the lumbar sac.

Of course, it is conceded that certain vital phenomena would modify the conditions somewhat, but, in the main, what occurs here furnishes us with fairly correct evidence on most of the physical points connected with these injections in the living subject.

All the injected compounds were coloured with the same amount of aniline, and used at the same temperature as the saline solution in the tubes. They were slowly passed into the latter with the usual needle as on the living patients, through the arm corresponding to the second lumbar interspace (see Fig. 9).

The figures represented are from photographs of the conditions actually present in the tubes *in situ* two minutes after injection.

The lighter injected compound is seen in one case to remain more or less completely at the site of injection (Bier's solution, top tube), while the heavier solutions quickly run to the most dependent part of the curve and settle there.

That a similar event takes place in the living is evidenced by the regularity with which analgesia is produced above the level of the lumbar region when a glucose-stovaine solution is injected. The height of the analgesia varies a little according as the head and neck are raised, and so the dorsal curve increased, but with the pelvis elevated two inches it usually reaches to the level of the sixth dorsal vertebra (see Figs. 8 and 9).

It is necessary to have a thorough knowledge of the technique involved before attempting the production of spinal analgesia.

The first problem which presents itself is how to pierce the lumbar dural sac with the point of a needle, and through it to inject our solution completely into the cerebro-spinal fluid below the termination of the spinal cord. The human cord terminates at its lowest extremity opposite the second lumbar vertebra, and is below this out of reach of harm. The dural sac extends to about the level of the third sacral vertebra. The configuration of the bones below the fourth lumbar spine, however, makes a needle puncture below this level a matter of great difficulty, if not a practical impossibility, so that our choice of a puncture spot is restricted to the second or third interspaces of the lumbar vertebræ.

Here the sac can be reached laterally between the laminæ, or the needle can be thrust exactly in the middle line between the second and third, or third and fourth lumbar spines. It is now generally acknowledged that puncture in the middle line is the easiest and safest method. Here the puncture is least painful, and there is less risk of wounding any nerve-structure or vessel if the needle is kept true to the middle line and only just penetrates the dural sac completely (see Fig. 11).

At either side there is a possibility of touching the strands of the cauda equina.

Besides this, any small quantity of fluid injected in the middle line can spread freely through the liquor spinalis, whereas, if delivered among the nerves of the cauda equina on either side, it has a tendency to be entangled there and to pass upwards or downwards in their interstices on that side alone, and so fail to reach the general cavity of the dural sac.

The consequence of this may be an effect too low for the contemplated operation, or a one-sided analgesia. Though the latter might be desirable for some operations, there is no guarantee that, if the needle were

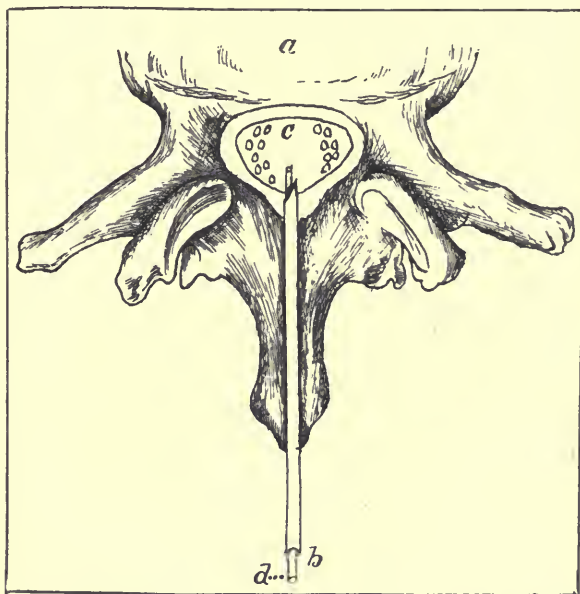


FIG. 11. DIAGRAM SHOWING METHOD OF LUMBAR PUNCTURE. The sketch shows the third lumbar vertebra, *a*, with section of the dura, *c*, containing the cauda equina. The hollow needle, *b*, has been passed in part through the dura in the middle line. The hollow canula, *d*, passed through the hollow needle, *b*, reaches well within the dural sac. (*Barker.*)

designedly entered between the laminae on one side, its point would not become engaged among the nerves of the cauda on the other side.

This appears to have been the cause of some of the few one-sided analgesias which were early recorded. The middle line, therefore, is the preferable site for the entrance of the hollow needle. Here the analgesic compound passes freely into the spinal fluid, and can move unhindered upwards or downwards from the point of entry; it can now be influenced in various ways and for varying objects, according to its density in relation to that of the spinal fluid.

A convenient guide is the fourth lumbar spine, which is on a level with the highest points of the iliac crests. A line drawn between these two points across the back will indicate this spine (see Fig. 12).

The hollow needle is thrust in just above this or the third spine, and aimed straight forward and a little upward. If this is accurately done, no difficulty, as a rule, is experienced in reaching the middle of the sac. In some very stout people, the spines may not be easily felt with the finger,

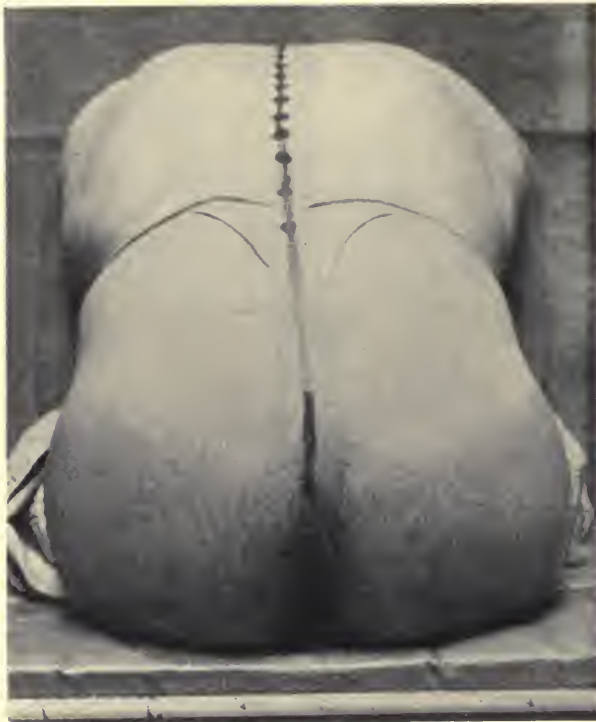

FIG. 12. POSITION OF THE PATIENT FOR PUNCTURE IN LOW OPERATIONS. The line touching the iliac crests is shown as a guide to the fourth lumbar spinous process. (*Barker.*)

and the point of the needle may strike bone; its upward slant is then changed, and the needle-point thrust in a lower direction. This usually is sufficient to pass the spine without necessitating a fresh skin puncture if the back has been well rounded to obtain the greatest amount of separation between the spines.

In a few cases it may happen that the spines are clubbed or twisted at their ends, or even overlap. In such, we may fail to reach the sac, but such failures are not common.

With a little practice lumbar puncture becomes quite easy. It was only in early cases that I experienced any difficulty in the procedure, though with abnormal spines considerable trouble may be encountered.

Whether the patient during the puncture should sit on the edge of the table, with the back rounded to its maximum, or lie on his side (see Fig. 14) with the knees well drawn up, depends on the operation and the height of analgesia required. Spinal puncture is certainly easier in the first position.

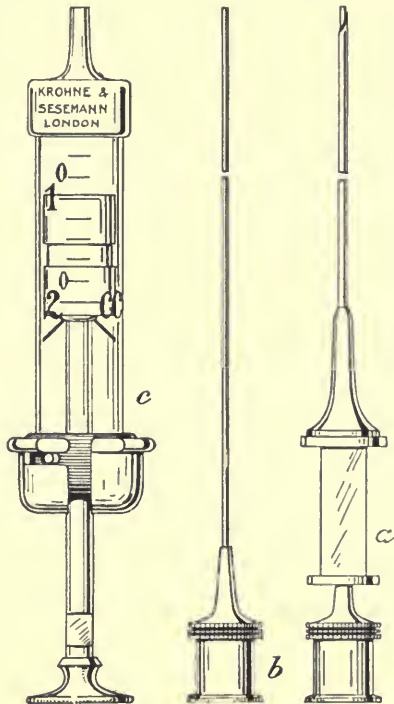


FIG. 13. 'RECORD' SYRINGE AND NEEDLES FOR SPINAL ANALGESIA. *a* is the sharp-pointed hollow needle; *b*, the long blunt-pointed canula which passes through it.

The needle I have employed is that used by Bier, followed by Mr. Barker. It has a close-fitting stylet, and the point is oblique and hollowed, so as to secure sharpness without too much lengthening of the terminal opening.

The object of this is that, when the dura is punctured, the whole of the open end of the needle may lie within the sac without the point being pushed so far as to wound any of its contents.

It is obvious that, if the open end of the needle were only partially

through the dura, as is shown in Fig. 11, the spinal fluid might run out freely enough through the needle, but that when the analgesic compound was injected, part of it might enter the sac, while part of it might escape through that portion of the oblique opening which had not entered the sac, and be lost in the extra-dural space.

As the operator is dealing with very small amounts of injection fluid, such a loss, if it were only three or four drops out of ten or twelve, would make all the difference between partial and complete analgesia. To prevent such a loss, a means has been devised by Mr. Barker for delivering all the injection compound beyond the point of the needle, whether the whole of its opening lie actually within the sac or not. This consists of a second canula (see Fig. 13) slender enough to fit the first hollow needle loosely and long enough to project beyond its point about 1 mm., when the cone at its base is pushed home. This canula is attached to the syringe, which is filled with the solution through it.

When the puncture with the hollow needle is made, and 2 or 3 c.c. of spinal fluid have run out through it, the canula, still attached to the charged syringe, is passed through the needle until its cone is home. The end of the canula, which is blunt, now projects beyond the point of the needle for 1 mm. and must be within the dural sac.

The syringe is now emptied through the canula, and all its contents must be delivered within the canal, even though only half of the oblique opening of the puncturing needle may have penetrated the sac. The syringe best adapted for this procedure is one known as the 'Record', with a capacity of 2 c.c. and graduated in fifths of a c.c.

The procedure employed is as follows :—

In a case where an abdominal operation is called for, and where analgesia is required at least to the level of the ensiform cartilage, the stovaine solution must be brought in contact with the nerve-roots as high as the sixth dorsal vertebra.

The needle, canula, and syringe are boiled for ten minutes in plain water to ensure their sterility. When cool, the canula is fitted on to the nozzle of the syringe.

One of Billon's ampoules containing the sterile stovaine-glucose solution is now taken and the end broken off. The canula is introduced into the fluid which is drawn up into the syringe. The syringe is then turned point upwards with the canula still attached, and bubbles are dislodged by gentle tapping. In this position all fluid except the required dose is expelled, and the syringe is laid aside on a sterilized towel.

The patient is now brought in and his confidence established by a few words.

The skin over his lumbar area is always prepared beforehand as care-

fully as the region of the operation. He is now placed on the table on his side, and the sterile compress removed from his back.

A final cleansing with biniodide and spirit is effected, and the skin is then washed with sterile water and dried to remove all trace of antiseptics, which might possibly be carried by the needle into the dural sac.

While lying on his side, with head and neck carefully raised, a block is placed under his pelvis, which is thus elevated about one inch or sufficiently high to cause the sixth dorsal vertebra to be the most dependent part of his spinal column (see Fig. 14).

This can be approximately gauged by carrying the eye along the spinous processes, great care being taken that the neck and head are sufficiently raised to prevent the injection running higher.

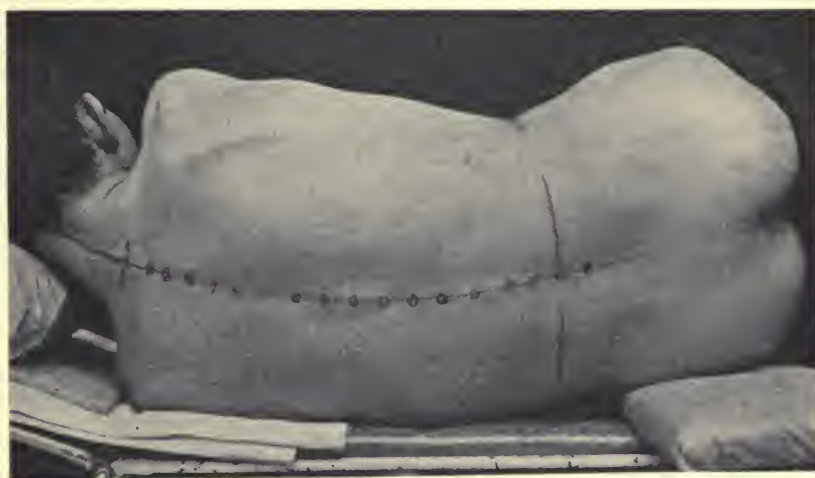

FIG. 14. LATERAL POSITION FOR PUNCTURE WHEN HIGH ANALGESIA IS REQUIRED. (*Barker.*)

His knees are now flexed on his abdomen, and his back rounded as much as possible in the lumbar region. A sterile towel is laid across his pelvis, and the iliac crests and fourth lumbar spine are determined. The skin on either side of the selected interspace, second or third lumbar, is steadied by two fingers, and the needle, with stylet in position, is sharply thrust through the skin in the middle line for about one inch. The stylet may now be withdrawn. The needle is then pushed firmly through the interspinous ligaments, after which little resistance is felt, and a sensation as of crossing an empty space is conveyed. Eventually the dural sac is punctured, and the spinal fluid flows out in rapid drops, or more rarely in a continuous stream.

This is most important, as otherwise we have no guarantee that the

sac has been reached by the needle. If the drops come very slowly, the needle should always be turned round on its axis, when they usually come more rapidly.

In no case should the analgesic solution be injected unless the spinal fluid runs out satisfactorily. When 2 or 3 c.c. of liquor spinalis have run off into a measure-glass, the slender canula attached to the syringe is inserted and pushed home; then the measured solution is injected into the sac by a slow thrust of the piston.

The needle, canula, and syringe are now rapidly withdrawn together, and the puncture immediately covered with plaster. The patient is now gently rolled on to his back (see Fig. 15), the pelvic elevation being main-

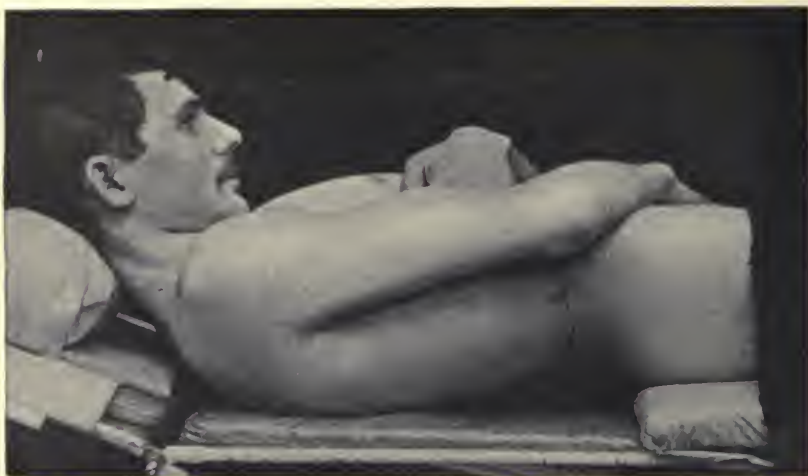

FIG. 15. PATIENT ROLLED OVER ON THE BACK AFTER THE INJECTION HAS BEEN MADE. (*Barker.*)

tained, or preferably he is kept in the same position for one or two minutes. By this time the solution has produced its analgesic effect on the side on which he is lying. The height of the analgesia is noted, and, if satisfactory, he is now gently rolled on to his back, when the other side of his body becomes quickly analgesic. The block under his pelvis may now be removed.

As a rule, two minutes elapse after the injection before the patient feels a numbness in his feet, then the perineum becomes analgesic, and later the trunk as high as the most dependent segment of the cord. For an abdominal operation, analgesia to the level of the fifth dorsal vertebra is ample. While moving the patient on to his back, he should be disturbed as little as possible, so that the spinal injection may not be diffused until

it has reached the desired level. The head and neck throughout the whole procedure, and subsequently in the ward, should be most carefully elevated. None of the injection fluid is required at this level, and in fact its presence would be undesirable. The freedom from shaking and steadiness with which the patient is lifted and carried to his bed are distinct factors in preventing the occurrence of subsequent headache.

The puncture as described above is not painful once the skin is passed, but if the needle scratch the periosteum pain is felt at the moment.

For an operation in the anal region a simpler procedure is available.

Here, the analgesia is not required at a high level, so elevation of the pelvis is unnecessary. The usual preparations being complete, the patient is placed in the sitting posture across the end of the table. His feet may rest on a chair, and he is directed to bend his head and shoulders forward and so to round his back that the greatest separation is obtained between his lumbar spines (see Fig. 12).

The fourth lumbar spine is defined, and the needle thrust into the skin immediately above it. When the sac is reached the injection is carried out as described, and the patient is gently laid on his back with head and shoulders raised.

In two or three minutes the anus becomes insensitive, and its sphincters completely relaxed. The patient is now quietly placed in the lithotomy position, with head and shoulders elevated, and the operator can proceed to work. It is not advisable to allow the patient a view of what is happening, so a specially designed screen is arranged in front of his face which completely fulfils this purpose.

A notable point in this procedure is the complete muscular relaxation obtained by spinal analgesia. This is especially remarkable during anal and abdominal operations, where the muscles are found flaccid and toneless, and there is a complete absence of that straining and intestinal protrusion which so frequently hamper the surgeon when a general anaesthetic is employed.

In only a very few cases has any trace of blood appeared through the puncturing needle, either before, during, or after the escape of spinal fluid. This was probably due to the fact that the middle line was carefully adhered to, and the extra-dural veins, which are more developed laterally, were not so liable to puncture. To secure perfect asepsis in the whole procedure is beyond everything absolutely necessary, and in the nature of things ought to be comparatively easy to any one realizing its importance. The skin in the lumbar region is no more difficult to clean than in other parts of the body.

The needle and syringe require simple boiling, and should never be utilized for any other purpose. The water in which they are boiled must

be free from any alkali, a trace of which destroys stovaine. The injection fluid must be carefully prepared, not only in regard to its sterility, but also with regard to the strength of its solution. It is better when made fresh.

The glucose-stovaine solution used in the series referred to was taken from Billon's sealed glass ampoules, which were sterilized previously at a temperature of 110° Centigrade for ten minutes.

The amount injected in any one case has not exceeded 6 centigrammes of stovaine, or 1.2 cubic centimetres of Barker's solution, though 5 centigrammes of stovaine or 1 cubic centimetre of Barker's solution (No. 2) is ample for operations to be completed within fifty minutes; in many cases the analgesia lasted an hour and a half with this amount.

SECTION III
AMPUTATIONS

BY

FRED^c. F. BURGHARD, M.S. (Lond.), F.R.C.S. (Eng.)

Teacher of Operative Surgery in King's College, London; Surgeon to King's
College Hospital; and Senior Surgeon to the Children's Hospital,
Paddington Green

CHAPTER I

INDICATIONS : DANGERS : GENERAL PRINCIPLES : PRINCIPAL METHODS OF CONTROLLING HÆMORRHAGE : AND THE PRINCIPLES OF OPERATING

Varieties. IN connexion with the extremities it has been the custom to use the term 'amputation' to denote any operation by which a limb or any integral portion of a limb is severed from the rest of the body. It is, however, preferable to subdivide amputations into two distinct groups, viz. (i) *Amputations* proper, or those in which the limb is removed after division of bone, and (ii) *Disarticulations*, or those in which removal is effected through one of the joints. The decision as to whether the surgeon will perform a true amputation in preference to a disarticulation in any given case will be influenced as a rule by the special circumstances connected with the injury or disease for which the operation is required, but certain points should be borne in mind when the conditions allow the surgeon his choice between the two.

Speaking generally, it may be said that, owing to the larger size and smoother contours of the articular ends, they furnish the best surfaces upon which pressure may be borne in the lower extremity, or from which purchase may be taken for the movements of an artificial limb in the upper extremity, and that therefore a disarticulation should be preferred to a true amputation when either of these points is of cardinal importance. When, however, the object is to obtain the most perfect æsthetic result, it has to be remembered that after a disarticulation it is impossible to fit an artificial limb which will preserve the normal movements. Thus, for instance, if a patient be fitted with an artificial limb after a disarticulation at the knee-joint, and the limb be furnished with an artificial knee-joint, this must necessarily be on a lower level than the one on the sound side in order to permit of flexion; therefore, although the difference in the level of the knee-joints on the two sides may pass unnoticed when the patient is upright or walking, it becomes apparent at once when the knee is bent, as in sitting down. For this reason most instrument-makers prefer a stump resulting from an amputation through the condyles of the femur to one left after a disarticulation at the joint, although obviously the basis of support in the latter case is larger and

more stable than in the former; this point, however, is dealt with more fully later on.

Indications. In former days it was much easier to define exactly the cases that called for amputation than it is at the present time. There are still a few groups of cases in which amputation must always be resorted to, but the limits of the very large group in which amputation is only occasionally required are still vague, and are constantly changing with the advances made by conservative surgery. Owing to the great improvement not only in the actual treatment of wounds, but also in the various other directions which have been opened up by the improved methods of securing asepsis, such as nerve suture, bone, tendon and skin grafting, &c., it has become possible to save and make useful members of limbs that were formerly condemned. The cases, therefore, in which amputation may be done will be considered in two large groups—(A) those in which amputation is invariably required, and (B) those in which it is only occasionally called for.

(A) Cases in which amputation is always required. (i) *Avulsion of a limb.* Here there can be no question as to the necessity of amputation, since the limb has been actually removed by the agent causing the injury, and the operation generally resolves itself into some form of ‘trimming’ operation, having for its object the removal of the damaged tissues together with enough bone to allow the skin to be brought together neatly over the end of the stump.

(ii) *Malignant disease of bone.* When malignant disease attacks a bone some form of amputation is absolutely necessary; for choice this should take the form of disarticulation at the joint above the seat of the growth, so that the entire bone and its lymphatic supply shall be removed. In the extremities, at any rate, it is hardly ever wise to remove only a portion of the bone, as recurrence under these circumstances is almost inevitable. This statement, however, does not include the so-called myeloid sarcoma, which is of low malignancy, and for which a much more limited operation, such as enucleation of the growth, or, at the most, an amputation through the bone immediately above the upper limit of the growth, will suffice.

(iii) *Severe crush-fractures.* These are the cases in which there may be the greatest difficulty in deciding whether to amputate or to try to save the limb. The old rule that amputation should be practised when either the main artery, vein, or nerve were divided no longer holds good, neither does the dictum that extensive laceration of the skin demands amputation. Also, a wound of a neighbouring joint may often be treated safely by disinfection and drainage, and the limb preserved, even when considerable portions of bone have been comminuted or entirely

destroyed, as in gunshot injuries; thanks to modern methods of splicing and grafting bones, a useful limb need not be despaired of. It is obvious that amputation will be necessary if the main artery, vein, and nerve have all been damaged, but, provided that one of these structures remains intact, the position of affairs is not hopeless. Collateral circulation may be restored even after damage to both artery and vein, whilst, if these structures be intact but the nerve be divided, the extra time necessary for suturing the nerve does not materially add to the gravity of the case. Even when the skin has been extensively destroyed, the application of Thiersch's skin grafts, either immediately after the accident or at some subsequent period, when it is seen how much of the skin will die, will often give the patient a useful limb which would otherwise have been sacrificed.

(B) Cases in which amputation is only occasionally required. (i) *Gangrene*. Some form of amputation is nearly always necessary in cases of gangrene, except in the slightest type of the senile variety, and in those trivial cases that accompany Raynaud's disease, frost-bite, and the application of heat or caustics. Even when the gangrenous part is allowed to separate spontaneously, some form of amputation is necessary, as the surgeon will be obliged to cut away portions of the protruding bone in order to get the soft parts to meet comfortably over it. The particular period of the disease and the exact situation in the limb at which the amputation should be practised must necessarily vary with the affection which calls for amputation; the important point is that it should be done in a situation where the blood-supply is good. Thus, for instance, it is useless to amputate through the foot or leg in senile gangrene, owing to the indifferent vascularity of those parts; the amputation should be done either in the region of the knee-joint or through the lower third of the thigh, as otherwise gangrene of the flaps is likely to occur. This is the principal risk of amputation in cases of gangrene, and it is increased enormously by the occurrence of sepsis, which leads to a rapidly spreading septic gangrene that is very fatal. There are of course other risks incidental to special cases, such as diabetic coma in cases of gangrene in diabetics.

(ii) *Compound fractures*. The remarks made concerning bad crush-fractures (*vide supra*) will serve to indicate the type of cases that require amputation in this kind of fracture. Few, if any, ordinary compound fractures, even if they extend into the neighbouring joints or are accompanied by occlusion of the main artery or vein, or division of the main nerve alone, are looked upon as suitable for amputation nowadays. In arriving at a decision in these bad cases the surgeon must take into consideration the age, the general health, and even the social position

of his patient, before he can judge whether amputation or conservative surgery is the better line of treatment. In addition to this, the most important point of all, namely the possibility of keeping the wound aseptic throughout, must not be lost sight of, and this question will be influenced to some extent by the considerations previously mentioned. Old age, with its liability to shock, to lung mischief from confinement to bed, and to bed-sores, together with the depressing influence of a prolonged convalescence, is against a too strenuous attempt to save a limb that must necessarily require a long period for healing. An amputation followed by primary union and necessitating only the minimum confinement to bed will often prove far better for an aged patient than too persistent attempts to save the limb. The situation of the fracture, and therefore the possibility of keeping the parts at rest effectually, or the wounds free from infection, also bear strongly upon this point, as do also the social circumstances of the patient. It is of primary importance that if an attempt be made to save the limb in bad cases of compound fracture, the conditions should be such that there is very little likelihood of sepsis supervening. Lastly, the character of the limb when it is eventually saved must be taken into consideration. A stiff limb, which is constantly liable to ulceration, although it may satisfy a well-to-do patient who can take all due care and can have all requisite attention, will be worse than useless to a working man, in whom the exact opposite is the case. In cases of doubt, however, it is well to remember that conservative surgery should have the benefit of the doubt, as it is always possible to amputate at a subsequent period should circumstances render it advisable.

(iii) *Intractable joint-disease.* Many cases of joint-disease require amputation. Foremost among these are suppurative arthritis, either acute or chronic ; in the former case to avoid general pyæmia, and in the latter lardaceous disease. Tuberculous joint-disease also calls for amputation when it is too extensive to be dealt with by excision, and particularly when the limb is riddled with septic sinuses ; here amputation not only removes the disease, but eliminates the possibility of lardaceous disease and restores the patient to health after a comparatively short convalescence. Amputation is often necessary in weakly persons who are the subject of advanced tuberculous disease, especially when there is tuberculous mischief elsewhere, as recovery from amputation is shorter, and makes less tax upon the general powers than does the protracted convalescence following a severe operation like excision.

(iv) *Intractable suppuration in an extremity.* Owing to improved methods of wound treatment, intractable suppuration in an extremity is much rarer than it used to be ; there are, however, certain groups of

cases in which it is still a prominent feature, and which can only be treated satisfactorily by amputation. Such cases, for instance, as those of acute infective osteomyelitis in which the whole of one of the long bones is implicated frequently demand removal of the limb ; and amputation through the arm or forearm is still resorted to fairly often in the treatment of intractable cellulitis of the hand and forearm following whitlow. This serious affection, however, is becoming less formidable nowadays, owing to the earlier diagnosis and improved methods of treatment by the various sera, &c. Amputation, on the other hand, is of little or no service in these fulminating septicæmic cases, in which the organisms are disseminated rapidly by the blood-stream without the formation of any considerable focus at the point of infection ; this type is a general blood-disease, and removal of the focus of infection is not only of no avail but actually adds to the patient's danger by reason of the shock it gives rise to.

(v) *Certain cases of deformity.* There are a number of cases of deformity, congenital or acquired, in which amputation is done either to obtain an improved æsthetic result or to provide the patient with a firmer basis of support for locomotion. Thus stiff fingers after whitlow, and certain deformities after burns, &c., are often treated by amputation, although the wider application of skin-grafting has reduced the number of these cases considerably. Amputation, however, is often very useful in treating the severe deformities following infantile paralysis, in which the limb, besides being useless for the purpose of support, suffers from defective nutrition, which renders it a constant source of discomfort and danger to the sufferer.

(vi) *Ulcers.* Many chronic ulcers of the leg are seen in the out-patient departments of hospitals in which a permanent cure is not to be looked for. When the ulcer is of many years' standing, and is so extensive that it encircles the limb either entirely or in great part, there is little hope of obtaining a satisfactory result by any method of palliative treatment. The circulation, both systemic and lymphatic, is so much interfered with by the chronic inflammatory process in and around the ulcer, that not only is it almost impossible to promote complete cicatrization by any means, but, even should this end be attained eventually, the ulcerative process will recur on the very slightest provocation, and the time spent in securing healing will be expended in vain. The application of Thiersch's grafts to these ulcers has done much to secure rapid healing, but in the extensive cases under consideration widespread sloughing and recurrence of the ulcer in all its former extent will frequently take place after it, even though the most elaborate precautions be taken to prevent it ; and, as these intractable ulcers only occur in the poorer classes, to whom

confinement to bed generally means loss of wage-earning, the matter is one of great seriousness.

Amputation affords the only rapid and certain cure in these bad cases, and the particular form of amputation required will generally be one at the 'seat of election' (see p. 216), on account of the situation of the ulcer. This should be recommended for extensive ulcers of long standing that almost entirely surround a limb and are accompanied by much induration of the non-ulcerated parts in the immediate vicinity, but it must be admitted that the patient will rarely accept the advice, preferring the inconvenience and pain of the ulcer to the loss of the limb.

(vii) *Tetanus*. It is still the custom with many surgeons to amputate that portion of the limb in a person attacked by tetanus in which the source of infection has occurred. It would seem, however, that this is not really necessary. It is doubtful how far any local treatment at all is necessary, if anti-tetanic serum be employed. Certainly vigorous local removal of infected tissues and application of antiseptics will do away with the necessity for amputation—except in parts such as the finger or toe, where local treatment would irreparably damage the limb, and where, therefore, immediate amputation is to be preferred.

Dangers. Nearly all the risks attaching to operations in former years have disappeared now, as a result of the improvements in the treatment of wounds; practically the only real danger attending the removal of a limb is *shock*, and this only occurs when the operation is one of considerable magnitude. It is well known that the degree of shock varies with different operations. It is much more marked in amputations of the lower extremity than in those of the upper; in the latter region it is seldom met with, whilst in the former the old rule still holds good, that the severity of the shock increases directly with the nearness of the amputation to the trunk. This rule, however, must be qualified to the extent of saying that the degree of shock met with does not constitute any real risk to life except in a few of the more severe amputations, such as amputation through the upper third of the thigh, or disarticulation at the hip-joint. Modern methods of guarding against shock will suffice to avert the danger of a fatal termination in all cases except those just enumerated; in them there is no doubt a definite mortality directly resulting from the severity of the operation. The exact percentage cannot well be estimated, as sufficient data are not obtainable; but that cases of death from pure shock, as distinct from those due to hæmorrhage or early sepsis, do still occur after the major amputations in the lower extremity, must be admitted by all practical surgeons.

The shock resulting from these major amputations appears to be due mainly, if not entirely, to the division of the large nerve-trunks close to

the body, and there is a most remarkable difference in the mortality of such an operation as disarticulation at the hip-joint when the operation is done, on the one hand, by a method such as Furneaux Jordan's (see p. 249), that involves division of the vessels and nerves comparatively low down in the thigh, and on the other, when it is done by one such as the anterior racket method, which necessitates their division on a level with Poupert's ligament. Allowing for the elimination of deaths from early sepsis, the mortality in these latter cases is still nearly as great as it was in former times. Since the shock appears to be due to the division of the nerve-trunks, and since the experience of those using stovaine and other local analgesics tends to show that these substances abolish shock much more than does a general anæsthetic, it would appear that the mortality of these severe amputations may possibly be diminished in the near future by the use of one of these local analgesics, either injected into the nerve-trunks at the point of section, or into the vertebral canal itself. Full details upon this subject will be found in Section II.

That the shock, however, is not entirely due to division of nerve-trunks close to the nerve-centres is proved by the fact that there is much less shock met with after the extensive interscapulo-thoracic amputation of Berger (see p. 151) than after disarticulation at the hip-joint by the anterior racket method, which is still not infrequently accompanied by fatal shock. This serious danger of shock must therefore be guarded against by every means in the surgeon's power; of these the most important is rapidity of operation, and no case of this kind should be undertaken unless the surgeon is provided with plenty of skilled assistance, and can operate in surroundings that are most favourable to minimizing shock.

I have recently adopted a modified Trendelenburg position for operations about the pelvic region and lower extremity that are likely to be accompanied by severe shock, and I have been much pleased with the results; shock seems certainly to be diminished to an appreciable extent, and moreover there appears to be less oozing from the wound, especially in cases of amputation. In these latter cases the true Trendelenburg position is difficult to use, owing to the undue height of the pelvis and the necessity of getting the sound limb out of the way, but if the operating table be so constructed that the head of it can be lowered, instead of the pelvic portion being raised, a similar effect can be obtained to the true Trendelenburg position. If such a table be not available the surgeon will need to stand upon a suitable stool.

Shock as influencing the time of amputation. It happens occasionally, particularly in severe machinery, gunshot, or railway injuries, that a patient who is the subject of a crush-fracture that inevitably requires

amputation comes under the surgeon's notice in an almost moribund condition from the excessive shock due either to the injury to the limb alone or to the combined effects of that and some severe internal lesion. The question that arises is, Shall amputation be performed at once, or shall an interval be allowed for a certain amount of rallying to take place? This question in the past has generally been answered by saying that amputation should be postponed until enough reaction has occurred to warrant the surgeon in thinking that the operation can be borne successfully. It must be allowed, however, by those who have seen these very severe cases, that this plan has not been productive of much good; the expected reaction has not taken place in many cases, and the patient has died of shock without any operation having been done.

When it is realized what an important part nerve irritation plays in the production of shock, it would appear that the quickest and surest way of bringing about the required reaction from the profound shock is to remove such powerful causes as the irritation of the large nerve-trunks by the fractured bony surfaces—in other words, by performing amputation forthwith. Until the damaged nerve-trunks are divided, they must be transmitting fresh impulses all tending to prolong the shock.

The chief danger hitherto has been the administration of the anæsthetic, from which the patient has often not recovered, and strenuous efforts have been made, by injecting eucaïne into the nerve-trunks and their vicinity, by the free use of strychnine and the administration of ether, to minimize this risk as much as possible.

At present, however, we have in Spinal Analgesia (see p. 40) a most valuable means of combating shock of this kind. It is remarkable how much the general condition improves after its employment; pain ceases, the pulse improves, and the restlessness disappears. The amputation may be undertaken forthwith, and the danger inseparable from a general anæsthetic is absent. It is precisely in this group of cases that spinal analgesia finds one of its most brilliant applications, and it should be employed in these cases to the exclusion of general anæsthesia. The patient is so deeply under the effect of the primary shock that he will be probably quite indifferent to the pain of the lumbar puncture.

It is true that these considerations apply only to the lower extremity, and that in the present state of our knowledge we cannot get safe spinal analgesia for similar work in the upper limb. It must be remembered, however, that the shock is hardly ever so severe in the case of the upper extremity, and that it will generally be possible to use some general anæsthesia such as ether here, provided that eucaïne, stovaine, or some other local analgesic be injected into the nerve-trunks and that only the

smallest possible quantity of ether be used. The important point is that the limb should be removed rapidly, and so a potent source of prolongation of the shock removed.

Hæmorrhage, which was formerly a serious danger in these cases, is now of little importance, owing partly to the introduction of anæsthetics, which allows of greater deliberation in operating, whereby it is possible to secure the main vessels in certain cases before dividing them, and partly also to the universal adoption of the aseptic treatment of wounds, as a result of which sepsis and its frequent accompaniment, secondary hæmorrhage, have become practically non-existent. In situations where it is difficult or impossible to secure proper compression of the main vessels by a tourniquet, such, for example, as disarticulation at the hip and shoulder joints, the surgeon can deliberately expose and secure the vessels before he divides them, and therefore is not obliged to trust to digital compression by an assistant, as he had to do in former times, when no anæsthetic was employed and the operation had to be done therefore with great rapidity; a serious risk of hæmorrhage is thus avoided.

Sepsis should be practically unknown at the present day, even in the most serious cases. Even when the operation is practised near parts that it is impossible to sterilize, it is possible to avoid sepsis altogether by choosing a form of amputation in which the cicatrix is as far removed as possible from any source of infection, as, for instance, disarticulation at the hip-joint by the anterior racket incision. It must not be forgotten, however, that a large amputation, such as one through the thigh or at the shoulder, requires the utmost vigilance in avoiding sepsis, and, should infection occur, the result is likely to prove disastrous, owing to the large size of the cut surfaces and the rapidity with which septic absorption takes place.

General principles underlying amputations. Several other important principles must be remembered if an amputation is to be performed with complete success. Chief among these are the means of obtaining a satisfactory stump, the methods of controlling hæmorrhage, and the general principles underlying the fashioning of flaps. Besides this there are certain general rules to be remembered in connexion with the dressing of the wound and the after-treatment of the stump, including in this the fitting of artificial limbs.

When, however, a surgeon sees a case in which the question of amputation has obviously to be discussed, the first question that he has to decide is whether amputation shall be performed or whether some form of conservative treatment shall be adopted. Should he decide in favour of amputation, the next important step is to formulate clearly in his

mind his reasons for choosing the particular form of amputation he decides to adopt in the case before him. We shall consider these two points separately. The first one has been discussed already in connexion with the indications for amputation (see p. 64), but it will be well to recapitulate them here.

Amputation v. conservative treatment. Amputation is, or should be, always followed by primary union and rapid convalescence, and therefore it is suited for those cases of tuberculous disease, gangrene, or crush-fracture in which the advanced age or feeble general condition of the patient, or the absence of suitable hygienic surroundings, &c., makes it clear that a prolonged convalescence would probably extinguish the sufferer's chances of recovery. Striking illustrations of this are seen in the rapid and permanent restoration to health when amputation has been done for intractable suppuration or bad tuberculous bone-disease. Age in itself is not a bar to conservative treatment, but the question of shock is influenced to a large degree by that of age, and elderly patients bear severe shock badly; therefore a prolonged and difficult operation, such, for instance, as excision of one of the large joints, is likely to be dangerously severe in an old patient, and an amputation is much to be preferred.

The patient's occupation also has some bearing upon the question. When the adoption of conservative treatment must necessarily involve a long illness, possibly leaving the patient with a stiff limb that will be a hindrance in his daily work, it may suit his purpose better to have a sound and thoroughly useful stump instead of a stiff and useless limb. An example of this may be seen in certain cases of chronic ulceration of a varicose leg, which the most painstaking conservative treatment fails to keep healed for more than a few weeks or months at a time, and then only after prolonged confinement to bed. Amputation in these cases rids the patient of a painful and troublesome sore at once, and renders him able to do his work without interruption.

Constitutional disease, although formerly considered of great importance, exerts but little influence nowadays in deciding the question as to whether amputation shall be performed or not; it has, however, some bearing upon the choice of the particular form of amputation chosen (see p. 74).

The particular form that the amputation shall take must be influenced by a number of considerations. In the first place, the exigencies of the situation may call urgently for one of the more rapid and easy forms of amputation, possibly involving the sacrifice of portions of the limb that would otherwise be saved were the surgeon able to proceed more deliberately and under more favourable circumstances; good examples

of this are met with in military surgery, where rapidity is often all-important. The sex of the patient also occasionally, but rarely, influences the question ; for example, in amputation of fingers the appearance of the hand may be of more importance to a female patient than its strength, and the surgeon may therefore choose an operation designed to restore the symmetry of the limb as much as possible, in preference to one which has for its object the maintenance of the full strength of the hand so essential to working men. The social position or the occupation of the patient may also have to be considered. In working men a firm basis of support, which is capable of withstanding all the pressure to which the stump is likely to be exposed, is of primary importance ; in well-to-do patients, on the other hand, for whom all the resources of the instrument-maker's art can be invoked, length of stump or strength of limb may be sacrificed to improved appearance. Disarticulation through the knee-joint, for example, furnishes a most serviceable stump suitable for working men, but is disliked by instrument-makers because of the impossibility of fitting it with an artificial limb that shall have the artificial knee-joint on the same level as the natural one.

The most important point, however, in the majority of cases is to adopt whatever form of amputation will give the patient a perfectly sound stump and at the same time will entail the least sacrifice of parts. The longer the limb the better is the functional power afterwards, as a rule ; but this point must be subordinated to the necessity of securing a good stump. It will be necessary, therefore, to consider the qualities of a good and the defects of a faulty stump.

The characters of a good stump. A good stump will be of proper shape, sound and healthy, and it must be as serviceable to the patient as it is possible to make it, so that when fitted with an artificial limb it will attain the maximum of usefulness.

A stump cannot be sound and healthy unless it possesses properly proportioned covering for the end of the bone. If the flaps be cut too short they can only be made to meet over the bone with a certain amount of tension, and this causes them to become adherent and painful. On the other hand, if the flaps be too long, the fault, although not so vital as the opposite condition, nevertheless is somewhat serious, as it not only may endanger the vitality of the parts from defective blood-supply, but it necessitates drainage for a longer period, and a considerable time must elapse before the parts shrink and become sufficiently consolidated to bear the proper amount of pressure. These remarks apply especially to amputations in the lower extremities, but they are also applicable in some degree to amputations in the upper limb. The soft parts should be freely movable over the end of the bone, and the cicatrix itself should

not be bound down to that structure. A scar closely adherent to the bone is a constant source of trouble and inconvenience, as it is always liable to ulceration from direct pressure or from friction between the bone and the artificial limb. Moreover, an adherent scar is likely to be unduly sensitive from the irritation of nerve-ends which are caught in it, and it is not at all uncommon for cases of adherent cicatrix to require a secondary amputation for the relief of this condition. At the end of the operation the flaps should come together without the least sign of tension, because a certain amount of retraction takes place during healing, and flaps that can only just be made to meet at the time of the operation are likely to give trouble at a later period; the flaps are pressed against the end of the bone and are thereby irritated, an undue amount of granulation tissue forms as a result of this, and stiff adherent flaps ensue. The end of the stump should be firm in consistency, and, as far as possible, symmetrical in shape, as this greatly facilitates the fitting of a satisfactory artificial limb.

In fashioning the flaps due regard must be paid to the region of the stump upon which pressure will have to be borne when an artificial apparatus is fitted, and an effort should always be made to provide that surface, if possible, from the surface of the limb best calculated to bear pressure. Thus, for instance, the tissues of the sole of the foot, the palm of the hand, or the extensor surfaces of the lower extremity, stand pressure more satisfactorily than do the tissues on the opposite aspects of the limb. Again, it must not be forgotten that a stump is not likely to be satisfactory unless its vascular supply is good, and no form of amputation should be entertained that does not provide for this. This point is not of much importance in healthy subjects, as almost any form of amputation will be followed by satisfactory union in aseptic cases, but in diseased conditions it is of primary importance not to amputate through a region in which the blood-supply is likely to be insufficient for the needs of the tissues. In senile gangrene, for instance, amputation through the foot or the leg is very likely to be followed by sloughing of the flaps from insufficient blood-supply, whereas an amputation through the knee-joint will probably be successful owing to the more abundant vascularity in the latter situation. The blood-supply of the flaps may also be interfered with after the operation by undue pressure from the splint or by too tight bandaging. Lastly, when skin flaps are being raised their blood-supply must not be imperilled, as it easily may be, by raising the skin only and leaving the deep fascia behind, and the edge of the knife must always be kept at right angles to the surface that is being cut, so as to avoid undercutting the flaps and damaging the blood-supply. In certain amputations, such as Syme's, it is easy for a careless

operator to prick the posterior tibial artery, which is the main source of blood-supply to the flap, and thus endanger its vitality.

The position and characters of the cicatrix are also matters of importance, for there are few complications after amputation worse than a persistently painful scar. Stress has been already laid on the importance of cutting the flaps so as to obviate this complication, and attention has been drawn to the fact that the flaps must be so planned that the cicatrix lies out of the way of any pressure to which the stump may be exposed when the patient is fitted with an artificial limb.

Another matter of some importance is that the divided bone-ends should always be fashioned so as to enable them to bear pressure without causing irritation to the soft parts covering them. Thus, for instance, in a Syme's amputation the malleoli are cut off in order to provide a horizontal surface upon which the limb can rest. In other amputations sharp edges and spicules of bone are clipped away, and the sharp crest of the tibia is always bevelled off. To some extent this rounding-off process occurs in all cases of amputation, the medullary canal being plugged by a firm mass of bony or fibrous tissue, but careful management is necessary to obtain the best result in the shortest time. The entire shaft of the divided bone wastes considerably unless the weight of the limb is transmitted directly through it.

In this connexion it is perhaps well to consider the question of the formation of a cuff of periosteum, which was originally introduced with the object of closing in the medullary canal, and so preventing sepsis from spreading along it. For this purpose such a procedure is of course unnecessary at the present day, but the formation of a cuff of periosteum has a certain value in helping to produce a mass of callus around the cut end of the bone, and so to round off that structure and prevent it from irritating the soft tissues of the stump.

The characters of a faulty stump. A stump may be unsatisfactory for many reasons. If the flaps be cut too short the skin will be scanty, and may be so stretched that its circulation is interfered with and it is permanently ill nourished. A similar result may follow sloughing of flaps which were originally quite long enough; the remainder becomes tightly stretched over the end of the bone. The scar also may be a source of discomfort, pain, or danger. If it is exposed directly to pressure from the artificial limb and is thereby constantly irritated, it will break down and ulcerate or become warty or hypertrophic, and eventually may be the starting-point of an epithelioma. An ulcerating cicatrix may occur in a stump in which the flaps have been cut too short; it is also occasionally met with after an amputation done through badly nourished tissues, as in cases of infantile paralysis. A painful stump is

another source of great suffering to the patient. The most common cause of this condition is the implication of the severed ends of the main nerves in the cicatrix ; these become bulbous, and intense pain is experienced on the slightest pressure, so that it is impossible for an artificial limb to be worn. A similar condition may follow septic mischief in the stump. This complication can be avoided entirely if the surgeon identifies and cuts short the severed nerve-trunks on the face of the stump at the end of the operation. A less frequent cause of painful stump is chronic osteitis of the cut end of the bone. This causes pain when any pressure is borne upon the limb, or when the end of the stump is struck. The osteitis is generally due to sepsis, and often persists after necrosis has taken place. It may, however, result from leaving sharp edges or spicules of bone, instead of removing them cleanly at the time of the operation.

Conical stump. In former days this was a fairly common sequela of amputation, and it is occasionally met with even now. The amputation stump, which was satisfactory at the time of operation, becomes shrunken and pointed, the end of the bone forming the apex of the cone and being adherent to the cicatrix, which is often tender, painful, and ulcerated. As time goes on, this condition increases in severity, and often ends in exposure and necrosis of the bone-ends, so that the only remedy is to re-amputate higher up. It is sufficient to mention the causes of this condition to indicate the means of avoiding it. Perhaps the commonest cause is cutting the flaps too short at the time of the operation, so that they can only be drawn together with considerable tension ; healing may take place satisfactorily, but during the consolidation of the stump a certain amount of shortening of the skin and muscles takes place, resulting in the formation of the conical stump. Another cause is sloughing in an otherwise correctly fashioned stump ; this is a less frequent cause than it was formerly. Apart from these two causes there are cases, especially in growing children, in which the amputation stump, although quite satisfactory at the time of the operation and during the period of healing, becomes conical as time goes on ; this is owing partly to the continued retraction of the muscles, but probably mainly to the excessive growth of the bone out of all proportion to the rest of the soft parts. This condition only occurs in growing subjects, and can only be guarded against by making the flaps full long at the time of the operation. It is not, however, a condition of such seriousness, as it is easy to amputate higher up when the degree of conicity of the stump is so great as to threaten ulceration of the scar over the bone, or when the growing period has ceased, after which the condition will not recur. Before that time, however, recurrence of a conical stump has been known after a second or even a third amputation.

Methods of controlling hæmorrhage. Many methods are employed to control bleeding during an amputation ; they may be classified as follows :—

(i) **Digital compression.** This is the simplest plan of all, and is in common use for the smaller amputations, such as those of the fingers, in which the circulation can be efficiently controlled by gripping the lateral surfaces of the digit firmly between the thumb and forefinger so as to occlude the digital vessels.

Digital compression was frequently employed in former times in amputations so high up the limb that a tourniquet could not be used because of the risk of its slipping. In disarticulations at the hip and shoulder joints, for instance, it was usual to have the main vessel controlled by the fingers of an assistant. This was done by pressure made over the skin or through an incision directly over the vessel. It is needless to say that to render this uncertain method safe a skilled assistant is required whose fingers will not get tired ; it is very difficult to maintain efficient pressure for any length of time, and the least relaxation of pressure may give rise to dangerous bleeding. If digital compression be employed the surgeon must perform his amputation rapidly, and hence it has fallen largely into disuse now that rapidity is no longer regarded as one of the chief essentials in amputating.

Another method of digital compression, namely that in which the assistant slipped his fingers beneath the flap containing the main vessels as the surgeon cut it, and compressed the vessels in it between his thumbs and fingers, has almost disappeared from present-day practice, largely owing to the abandonment of amputations by transfixion. Like the previous method, this requires a skilled assistant thoroughly used to perform the responsible duty entrusted to him.

(ii) **Temporary ligature.** A substitute for digital compression that has come into vogue recently is the use of a temporary ligature applied to the main vessel. Thus, for instance, in disarticulation at the hip or shoulder the common femoral or the subclavian vessels may be exposed, and a loop of silk or tape passed around them ; traction upon this loop kinks and occludes the vessels, and it is easy to maintain this traction throughout the operation. The method is perfectly effectual in arresting the circulation, and experiments show that a temporary ligature of this kind does no appreciable damage to the vessel-wall. Under certain circumstances, as, for instance, where special apparatus is not available, the method may be made use of. It has the obvious disadvantage that it entails an extension of the original operation, in that a separate incision is required to expose the vessels above the point at which they will be divided ; both the artery and its companion vein should be included

in the ligature. When the main vessels have been ligatured on the face of the stump, the temporary ligature is withdrawn and the wound made for its passage round the vessel is sutured.

(iii) **Preliminary permanent ligature of the main vessels.** This method forms an integral part of certain operations, such as disarticulation at the hip by the anterior racket method, and also in Spence's disarticulation at the shoulder as it is usually practised nowadays. The main vessels, both arteries and veins, are exposed by an incision which subsequently forms part of the amputation incision, and are secured and divided between two ligatures ; the cut ends are then turned out of the way, and the amputation is proceeded with. This is an exceedingly valuable method, particularly in disarticulation at the hip, as ligature of the common femoral controls nearly all the bleeding from the flaps, and in addition the vessel is easily exposed and tied, while it is not easy to secure it with certainty by any other means.

(iv) **Circular constriction of the limb.** This very old method has been simplified and improved by Esmarch. In its original form a band encircling the limb and provided with a screw-down apparatus which could exert direct pressure over the main artery, was applied circularly round the limb at the desired level. As this form of tourniquet depends for its efficacy upon the correct application of the pressure pad over the artery, and as it is quite possible that this may slip during the course of the operation, the method has manifest drawbacks, and Esmarch's plan of arresting the circulation entirely by stretching an indiarubber cord transversely around the limb is in all ways preferable. Esmarch used the rubber cord in conjunction with an elastic bandage wound spirally up the limb from the extremity to the level at which the transverse ligature was to be applied ; this was done with the view of emptying the limb of blood as far as possible, and so preserving to the patient an amount that would otherwise have been lost. This plan is excellent in all cases except those in which the spiral compression of the limb is likely to drive other substances than blood back into the circulation, for example, infective organisms or growth. In these cases a simpler plan is that recommended by Lord Lister, who found that by elevating the limb for about five minutes without employing any compression at all, the extremity became bloodless from reflex contraction of the vessels, and the object aimed at by Esmarch was attained without danger.

The circular indiarubber band is put on the stretch before it is applied, and its centre is placed over the main artery of the limb and the rest of the band is then wound firmly round the limb three or four times, the ends being tied together or secured in forceps. The band should be sterilized by boiling, and its thickness will vary with the size of the

limb to which it is to be applied ; a stouter band will be required for the thigh than for the upper arm. Unless the surgeon has enough assistants to allow him to tell off one especially to look after the tourniquet and nothing else, the part of the limb to which the band is to be applied should be purified as carefully as the actual area of operation ; it is necessary to loosen the tourniquet during the operation, and the risk of infecting the flaps will be very great unless this part of the limb has been made aseptic. The bandage should be applied round either the thigh or the upper arm, and not the forearm or leg ; in the latter situations the vessels lie deep between the two bones which protect them from compression. Some experience is needed to apply the tourniquet efficiently without damaging the structures that it compresses ; if it be wound too tight, thrombosis of the vein or damage to the nerves may occur. It should be applied just tightly enough to arrest the arterial circulation, as tested by feeling the pulse below. Another useful application of this tourniquet is as a figure-of-eight around the groin and pelvis in disarticulations at the hip, such as Furneaux Jordan's (see p. 249).

This method is very useful and of wide application ; it requires no expert assistance or elaborate apparatus, and its chief disadvantage is that it is not applicable to amputations higher up than the middle of the thigh or upper arm. It is apt to give rise to rather persistent oozing when its pressure is relaxed, due apparently to the vaso-motor paralysis that it necessarily produces. In order to minimize this inconvenience the tourniquet should be removed as soon as the main vessels have been secured on the face of the stump ; by the time that the ligatures have all been applied the oozing will probably have ceased.

(v) **Hæmostasis by special apparatus.** Much ingenuity has been expended in devising mechanical methods for preventing hæmorrhage when an Esmarch bandage is inapplicable. The most difficult cases are disarticulations at the hip and shoulder joints, and various special forms of apparatus have been invented for use in these operations. None of these are wholly satisfactory, and, inasmuch as they all involve small preliminary operations for their proper application, they do not seem to offer any material advantage over the more certain method of ligaturing the main vessels before the actual amputation is undertaken or, when that is impossible, of securing the main trunk above by means of a temporary ligature. The only real advantage that these forms of apparatus possess is, that they enable the surgeon to dispense with a certain amount of extra assistance.

Pressure Forceps of Lynn Thomas. This is a convenient method of temporary compression that resembles Esmarch's bandage in so far as it compresses certain portions of the stump tissues *en masse*. The forceps

designed by Mr. Lynn Thomas (*Brit. Med. Journal*, 1904) (see Fig. 16) have one blade smooth and the other serrated, and have a catch by means of which they can be made to exert considerable pressure. The smooth blade is inserted through a small hole in the skin and pushed well beneath the vessel or vessels that it is desired to occlude temporarily. The serrated blade remains outside the limb, and any desired amount of compression can be exerted by clamping the handles together so that the vessel and the soft parts around it, together with the skin, are clamped between the blades of the forceps. It is however not essential to employ special forceps for this purpose as various forms of intestinal clamp-forceps answer the purpose admirably. The forceps should be thrust through the skin as high up as possible above the base of the flap; their

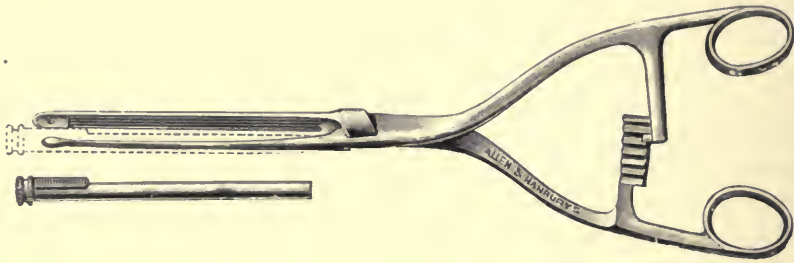


FIG. 16. LYNN THOMAS'S HÆMOSTATIC FORCEPS. The probe-pointed blade underruns the tissues to be compressed; the flat grooved one exerts pressure over the skin externally. The hollow tube figured below is only used on the battle-field to protect the probe-pointed blade from contamination.

pressure is relaxed and they are removed when the main vessels have been controlled.

These forceps seem to have a definite sphere of usefulness, and may well take their place as a necessary part of the surgeon's amputation outfit. They can be used when it is impossible to employ a rubber tourniquet, and they have the great advantage over the latter that there is no fear of their perishing from want of use, which is such a great drawback to Esmarch's bandage; they are also said to give rise to much less persistent oozing after removal, and that only from the skin.

Wyeth's Pins. Wyeth introduced the pins called by his name in order to widen the range of usefulness of Esmarch's rubber band, which they prevent from slipping when applied high up around the thigh, as for disarticulation at the hip-joint. They are stout steel pins or skewers which are made to transfix the soft parts, one on the outer and one on the inner side of the limb. Above the pins the rubber band is drawn around the limb as tightly as possible; the

method is very similar to that of the transfexion pins used to prevent the *écraseur* from slipping in former days. The pins should transfix about three inches of the skin with the subjacent muscle, and should be long enough to project about three inches on either side, and stout enough to bear the strain of the rubber band above them without snapping. One end should be sharp, and the other furnished with some form of handle by which they can be driven through the skin. They should go well into the muscles, but should be applied at some part where no important structure is likely to be transfixed. It is quite immaterial

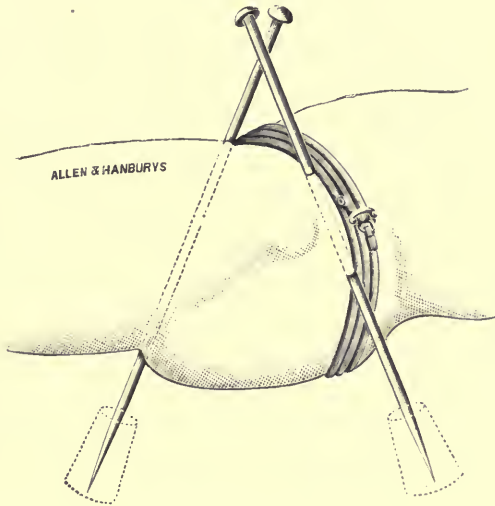


FIG. 17. WYETH'S PINS. On the outer side the tensor fasciæ femoris is transfixed by the stout pin shown in the drawing, the sharp end of which is guarded by rubber or cork. On the inner side most of the adductors may be transfixed so as to supply a firm basis of support which will prevent the circularly applied rubber band from slipping. It is usual in addition to apply a pad over the femoral and gluteal arteries beneath the rubber band.

on which side of the limb they are placed; the surgeon will be guided by the demands of the individual case. In a disarticulation at the hip the most convenient spots will be beneath the anterior superior spine, transfixing the tensor fasciæ femoris on the outer side and the adductor longus just below the fold of the groin on the inner side (see Fig. 17).

It is important to remember that the divided vessels should be secured at the end of the first stage of the amputation before disarticulation is commenced, as otherwise the vessels may retract out of the way and bleed in spite of the tourniquet when the support given by the head of the bone has been lost.

Methods of fashioning flaps. The circular amputation. The circular method is the parent of all the amputations that have since been practised. It is obviously the quickest and simplest form, and when the soft parts are damaged up to the same level on the two sides of a limb it allows the bone to be sawn nearer to the area of damage than does any other; it is therefore very economical. The cut surface it leaves is smaller than that in any other amputation, and the blood-supply of the flaps is good, all the vessels being cut at right angles to their long axis.

In its crudest form the amputation consists of a circular incision carried through the soft parts down to the bone; the soft parts are retracted for a sufficient distance and the bone is sawn. The plan of dividing the soft parts so that a hollow cone is formed on the face of the stump (see p. 143) is a great improvement upon the older clumsy method, and should always be adopted, as otherwise it is very difficult to approximate the flaps properly, owing to the large mass of muscle divided. The circular method, however, has a disadvantage which prevents its use under certain circumstances; the cicatrix necessarily lies over the end of the bone, and therefore the method is out of the question for cases in which pressure has to be borne directly upon the end of the stump, as in many amputations in the lower extremity. Moreover, in a muscular limb it is difficult to retract the muscles sufficiently to secure proper exposure of the bone at the proposed point of division, and the flaps can seldom be brought together neatly; the stump is puckered and often becomes conical. On the other hand, the circular method is very useful in the upper extremity, where the length of limb that can be preserved is a matter of primary importance, and no pressure is thrown upon the end of the bone.

Amputation by an elliptical incision. This is the first development from the simple circular method and its evolution is due to various causes. It soon became evident that in amputations in the lower extremity it was necessary to place the scar well away from the end of the bone. By making the incision around the limb at an obtuse angle to its long axis instead of at right angles to it the incision is made to reach a lower point on one aspect of the limb than on the other, so that a single long flap was formed, which could be drawn over the end of the bone, and the cicatrix thus placed well out of the way of pressure. Moreover, when the soft parts are damaged higher up on one side of a limb than the other, a true circular amputation would involve an unnecessarily high division of bone, whereas an elliptical incision with its lowest point on the side on which the sound tissues extend the lowest allows the bone to be divided as low down as possible. Also, the amount of retraction of

the skin and subcutaneous tissues varies in different parts of the limb, and it may require an elliptical instead of a circular incision to make the level of the incision on the two sides of the limb equal after this retraction has taken place.

Flap methods. From these two primary types, the circular and elliptical amputations, the modern flap methods have been evolved. Thus from the true circular method came the modified circular and the racket amputations, whilst from the elliptical incision was derived the oblique racket, the lanceolate incision of Kocher, and the amputations by unequal flaps. The primitive circular amputation was useful only in limbs circular in contour and containing a single bone, such as the thigh and the upper arm; in tapering limbs or those with two parallel bones extra incisions had to be added to the circular or elliptical ones, so as to enable the muscles to be retracted easily up to the desired bone level. Thus a single longitudinal incision added to the circular one gave the ordinary transverse racket incision, whilst two such vertical incisions on opposite sides of the limb gave rise to the equal flap method. Similarly, the addition of a single vertical cut to the elliptical incision gave the oblique racket, and by a later development the lanceolate incision (Kocher), whilst two vertical incisions gave the unequal flap method. In early days these flaps had square corners, but a further development, a sacrifice to neatness, was a rounding-off of the corners so that the U-shaped and semicircular flaps came into use.

The flap method possesses great advantages. Excellent and easy exposure of the bone at the point of section is obtained by it, and the surgeon can fashion his flaps from any region of the limb that he desires; while after the bone has been sawn, they come together easily. The disadvantages are not serious, and they only apply to amputations by unequal flaps. In them the bone has to be divided higher up than is absolutely necessary, except when the soft parts are damaged higher up the limb on one side than on the other. This, however, is rarely a point of great importance, but if it is, the method must be rejected in favour of the circular, if that method be available. A disadvantage of the flap method is that the blood-supply of the flaps, especially the longer one, is not so good as in a circular amputation. This is doubtless true, but, unless the length of the flap be extreme, as for instance in Teale's amputation, there is no risk of sloughing in an aseptic case. The surgeon, however, should bear this point in mind when amputating in regions or on subjects with impaired vascular supply, and should then adopt a method that is not open to this objection.

When planning his flaps the surgeon must remember that, after division, various circumstances influence the amount of retraction of the soft parts, especially the muscles. The muscles which are free between their points of origin and attachment, such as the biceps, hamstrings, &c., contract most; those which have a wide bony origin contract least. The flexors generally contract much more than the extensors, and allowance must be made accordingly in cutting them; thus, when amputating through the lower third of the thigh the muscles are cut much more directly to the bone on the flexor than on the extensor surface. The more muscular the subject, the more marked is the retraction; and, conversely, the minimum amount of retraction is met with in atrophied or inflamed muscles. After amputation the muscles thrown out of use undergo almost complete atrophy, becoming converted into a mass of fibrous tissue. Muscular contraction should come to a standstill soon after the operation; any further shortening is due to inflammatory contraction.

The retraction of the skin is considerable, and, like that of the muscles, varies in different parts of the body, and under different conditions. It is least where the subcutaneous tissue is scanty and the skin is thin and has deep connexions with the subjacent bones or aponeuroses. Thus, in the neighbourhood of the knee-joint the retraction is comparatively slight, as it also is when there is inflammation or œdema of the soft parts. Speaking generally, the retraction of the skin is more marked the nearer the line of amputation is to the trunk, and the average shrinkage is about one-third of the length of the flap. It must be remembered that in the dead body the retraction of the skin is much less than in the living subject, and in the bodies prepared with formalin for dissecting-room purposes there is practically no retraction at all.

Factors influencing the surgeon's choice of methods. The first essential in selecting a method of amputation is to see that it provides the most useful stump possible. The next is to choose one that will do this with the least possible sacrifice of healthy tissue. The longer the stump the more satisfactory it is to the patient, and as a rule the more easily fitted by the instrument-maker, and therefore all so-called 'expensive amputations', such as Teale's, which involve division of the bone at a higher level than is absolutely necessary, are to be avoided. Hardly inferior in importance to these points is the necessity for securing for the end of the stump ample covering provided from parts suited for bearing pressure, and a healthy, narrow and sound scar so placed that it is not exposed to irritation. The last important point influencing the surgeon's choice is that the flaps must have an ample blood-supply. This becomes a factor of great importance in elderly persons, or those subject to arterial

disease ; in them it may be necessary to amputate through the knee or even higher for a small patch of gangrene in the foot solely because of the inadequate blood-supply below this point.

Other minor factors may influence the surgeon's choice, but they are much less important now than formerly. Rapidity in operating was at one time esteemed greatly, but this factor is now taken into consideration only in cases that are likely to be accompanied by severe shock ; in them rapidity of operation is important, as it is an essential factor in the prevention of shock. Rapidity has now given way to methodical and careful fashioning of flaps, followed by accurate approximation. Other things being equal, the surgeon will of course always choose the method which is easiest of performance, and which allows him to expose and divide the bone with the least inconvenience and expenditure of trouble.

Methods of raising the flaps. Marking out and raising the flaps was formerly always performed with the old-fashioned amputating knife ; now it is generally done with a large scalpel. Formerly the flaps were largely cut by transfixion, and this necessitated the use of the long knives



FIG. 18. FINGER BISTOURY. The blade is very narrow in proportion to its length and the cutting edge is horizontal.



FIG. 19. KNIFE FOR CIRCULAR AMPUTATION.

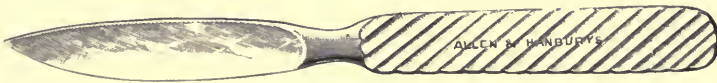

FIG. 20. SYME'S FOOT KNIFE. This is useful for all operations where flaps have to be raised from bone. It is stout and has a short blade, which is easily manageable.

so often found in amputation cases, which have blades at least one and a half times the length of the transverse diameter of the limb they are intended for use upon. Save in a few exceptional cases that will be mentioned later, the long and clumsy amputating knives have entirely gone out of use. The modern surgeon performs practically all the major amputations with a knife not larger than an ordinary breast knife ; indeed for the majority an ordinary scalpel suffices. Occasionally special knives

are required ; for example, amputation of the terminal phalanges of the fingers by a long palmar flap is done by means of the so-called ' finger knife ', viz. a bistoury about three inches long with a very narrow blade in order to allow the knife to be turned at right angles after it has passed through the inter-phalangeal joint (see Fig. 18). The circular amputation also requires a special knife of considerable length ; when the true circular operation is done the knife shown in Fig. 19 is useful ; it has a rounded

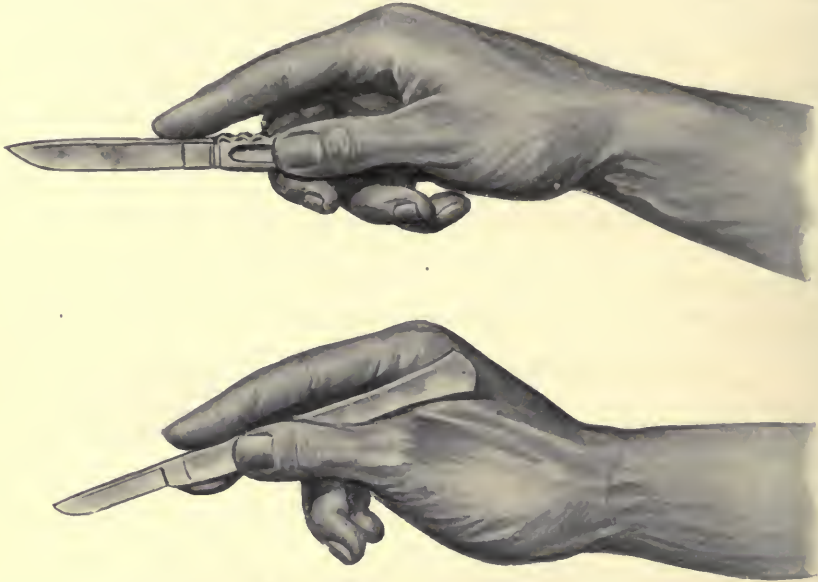


FIG. 21. METHODS OF HOLDING THE AMPUTATING KNIFE. The upper figure shows how the knife should be held when marking out the skin incision. If held in this way, the operator has perfect control over the blade, which should be made to trace out the incision while the knife is held nearly horizontal, as shown in the figure. This brings the whole of its edge to bear upon the skin and makes an easy and smooth incision. The lower figure shows the manner in which the knife is held for fine dissecting work. This is a wrong manner in which to hold the knife during amputations, as the greater delicacy of manipulation that it ensures is obtained at a great sacrifice of power.

end and its cutting edge is slightly concave so as to bring as large an extent of it as possible into contact with the structures to be divided. For all other purposes the ordinary scalpel, a breast knife, or, when flaps have to be raised from bone as in Syme's amputation, the short-bladed, stout-backed knife shown in Fig. 20 raises the flaps better, as the surgeon has much more control over it.

How to hold the knife. In an amputation the knife should always be held as shown in Fig. 21 except when a circular amputation is being

performed ; then the knife is held as in Fig. 22. Both these methods of holding the knife give the maximum amount of control over the blade and point. The blade of the knife should always be kept at right angles to the surface that is being divided ; if it be inclined at an angle the tissues are undercut, and the vitality of the flaps may be interfered with by wounding the vessels supplying them. The knife should be made to cut with the belly and not with the point only ; a common mistake with beginners is to mark out the flaps with the point of the knife only, and the result of this is to throw the skin into folds in front of the knife, so that an ugly irregular incision results. The most satisfactory way of cutting a flap is to plunge the point of the knife into the skin at the commencement of the incision, and then to depress the handle until nearly the whole of the cutting edge is in contact with the skin, when the knife is made to trace out the flap by drawing it along with a gentle sawing movement, employing nearly the whole of the belly of the knife in the process.

When performing a circular amputation, the knife is drawn steadily round the limb from heel to tip, and should not be made to cut the incision with one portion of its edge only, as is often done. By doing it correctly no undue pressure is thrown upon the soft parts, which are consequently evenly divided without displacement or irregularity.

When disarticulating, only the point of the knife should be used to divide the various ligaments connecting the bones ; owing to the irregular

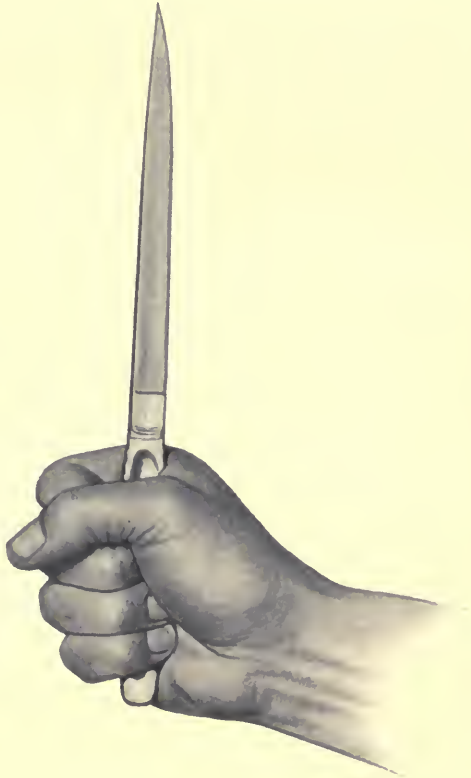


FIG. 22. METHOD OF HOLDING AMPUTATING KNIFE WHEN MAKING CIRCULAR INCISIONS. The knife is held thus when performing a circular amputation or dividing muscles by a circular sweep. It enables the knife to be carried as far as possible round the limb and at the same time gives the operator perfect control over it.

outline of the joint surfaces, the knife is often much hampered in its movements if more than the point be employed.

Flaps are only cut by transfixion when many tendons have to be divided. The reason for this is that these structures are difficult to cut from without inwards, as they retract unequally and roll under the



FIG. 23. METHOD OF APPLYING A TWO-TAILED LINEN RETRACTOR. The figure shows how the two tails of the bandage cross one another in order to retract the soft parts and leave the bone exposed. The two tails are crossed under the assistant's upper hand as shown in the figure.

knife; in order to secure a neat and uniform line of section, therefore, they are best divided in one mass by introducing the knife between the bone and the tendons, and cutting through them by a quick upward sawing movement. Formerly the entire flap was often cut by transfixion, the knife being entered through the skin, thrust across the limb between

the bones and the soft parts on a level with the line of bone section, and the flaps of skin and muscle cut by carrying the knife down with a sawing movement a certain distance, and then cutting straight out. Nowadays the skin flap is never cut by transfixion, except in amputations of the terminal phalanx of the fingers by a long palmar flap ; when transfixion is employed, as in the lower third of the forearm and the thigh, the skin flap is marked out first and its edges allowed to retract, and the tendons are cut by transfixion subsequently.




FIG. 24. APPLICATION OF A THREE-TAILED LINEN RETRACTOR. The three tails of the bandage can be traced in the figure. Of these the middle passes through the interosseous membrane and is partially covered by the two lateral tails, which keep back the soft parts from the tibia and fibula.

Retractors. After the flaps have been cut and dissected up sufficiently the bone is sawn. In order to protect the flaps from damage by the saw while the bone is being divided, they must be held back by suitable retractors. Retractors of many kinds have been introduced, but there are few so satisfactory as the two or three-tailed linen bandage, used for amputations where there are a single or two parallel bones respectively. Figs. 23 and 24 show how these are employed.

Division of the bone. This is generally done with a saw; cutting-pliers should be avoided, as they crush the bone to some extent, while

chisels are very clumsy implements for this purpose. An ordinary tenon saw of suitable size is the most generally useful kind. The blade should be at least an inch wider than the bone that has to be divided ; otherwise the saw must have a movable back. The tenon saw is easy

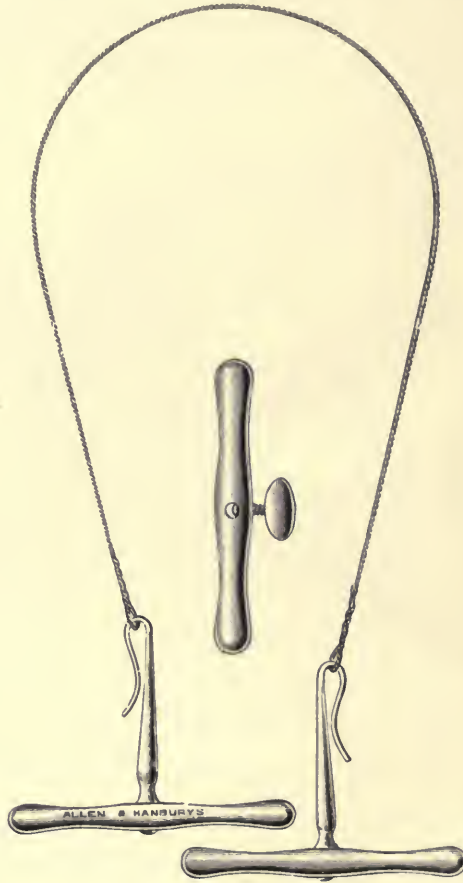

FIG. 25. GIGLI'S WIRE SAW. The two handles are shown hooked into the ends of the saw, which is passed round the bone either by means of the fingers or drawn through by a stout ligature. The handle in the centre of the figure is very useful should the saw snap during its application ; the broken end is then threaded through the hollow in the extra handle and clamped by the screw.

to handle, and cuts a clean level surface. Other saws, such as Butcher's, the metacarpal saw, &c., are only needed under special circumstances ; Butcher's saw is very useful when a convex or concave surface has to be cut. Gigli's wire saw (see Fig. 25) is very useful for dividing the lower jaw, and also in removal of the superior maxilla.

Before sawing a bone it is well to turn up a cuff of periosteum, which is allowed to fall together over the cut end of the bone when the flaps are sutured ; this method facilitates the rounding off of the bone end, and enables it to bear pressure well. It is only used with this object and not with that for which it was originally introduced, viz. the closure of the medullary cavity against sepsis. When the bone is being divided the saw should be first drawn lightly from heel to point several times




FIG. 26. STEADYING THE SAW WHEN DIVIDING A BONE. The surgeon's left thumb in the position shown in the figure forms a firm buttress against which the saw can be rested without any risk of the latter slipping upwards. If the thumb be bent in the particular manner shown in the figure it is impossible to damage it with the saw.

across it, in order to cut a groove for it to work in ; Fig. 26 shows how the saw is steadied by means of the left thumb while this is being done. The limb is grasped in the left hand above the line of division, and an assistant holds the distal end firmly and quite horizontal while the surgeon divides the bone with rapid light strokes ; undue pressure must be avoided, as it helps to lock the saw and to break the bone. The assistant must not raise the limb, or the saw will be locked, nor depress it too forcibly, or the bone will be fractured prematurely. With care it

is easy to saw the bone cleanly through without leaving spicules on the cut end ; if any be left, however, they can be clipped away with suitable cutting-pliers. A bone should always be divided with a saw, and not with cutting-pliers ; however sharp and powerful the latter may be, they tend to split the bone to some extent instead of dividing it cleanly as a saw does.

In certain cases the end of the bone has a tendency to protrude beneath



FIG. 27. BEVELLING OFF THE BONE IN AMPUTATIONS. Examination of the figure will show that the oblique cut has already been made and the saw is in the act of making the transverse section of the bone. As the transverse section meets the oblique one a small triangular piece of bone is dislodged, and when the bone has been entirely divided its sharp margin is found to be bevelled off.

one of the flaps, and, if it possesses a sharp edge, this may become adherent to or actually ulcerate through the flap. To avoid this it is usual to bevel off any sharp edges of the bone, especially in the case of the tibia, and Fig. 27 shows how this is done. The oblique cut to remove the sharp edge is made first, and is carried through about a third of the thickness of the bone ; the transverse incision to remove the limb is then made, and the distal portion of the bone and the small bevelled-off portion come away together.

The arrest of hæmorrhage and closure of the wound. When the bone has been sawn and the limb removed, the flaps are held wide apart, and the main vessels are identified and secured with pressure forceps. Large vessels, such as the femoral or brachial, should be pulled well out of their sheaths by dissecting forceps and the pressure forceps applied transversely to their long axes ; otherwise, only part of their circumference may be caught, and dangerous bleeding may follow removal of the tourniquet. Moreover, this plan obviates all danger of including the companion nerves in the ligature—an exceedingly unpleasant complication. The main veins are thus temporarily secured as well as the arteries. Immediately before the tourniquet is removed it is well to pack swabs or sponges tightly between the flaps, so as to keep down the bleeding when the pressure is taken off, and allow the surgeon to pick up the bleeding points *seriatim*, first in one flap and then in the other. The oozing following removal of the tourniquet is usually free, particularly from the cut muscles, and may last for some time ; it is best controlled either by douching the surface with sterilized water at a temperature of 115° F., or, in weakly subjects, by the application of a sterilized solution of adrenalin. All oozing points are caught up in clamp forceps without waiting to tie any of them, and to facilitate this the limb must be held well up and the flaps fully displayed by an assistant. After all the definitely bleeding points have been secured thus, the wound is douched with hot water, and ligatures are applied ; these should be of medium thickness for the main vessels, but of the smallest size for the others.

In this manner the bleeding can be usually controlled satisfactorily, with the possible exception of that from the bone, which may cause much inconvenience, especially if the bone has been divided near the nutrient artery. Should there be unduly free bleeding from any particular portion, an attempt may be made to stop it by crushing up the bony tissue from which the bleeding comes with a blunt bradawl or a steel director ; failing this, Horsley's wax forced into the cut bony surface will be successful.

The more cleanly the parts are cut and the less the flaps are handled the better is the result likely to be, and in arresting hæmorrhage particular care must be taken that the cut surfaces are not infected by accidental contact with non-sterilized portions of clothing, &c., as the surgeon and his assistant lean over the stump.

Drainage should be provided in every amputation except the small ones, such as the fingers. Oozing after the operation is inevitable, partly as a result of the use of the tourniquet, partly from the irregular contraction of the divided muscles which always occurs after amputation ; this renders it impossible to approximate the soft parts so accurately

that there shall be no space left in which blood can collect. A drainage tube is therefore essential to avoid the risk of the flaps being separated by clots and giving way subsequently. The tube should be large, so that it may carry off the blood rapidly; it should be inserted at the most dependent spot. It is best not to carry it across from one angle of the flaps to the other; should it be deemed advisable to drain both sides of the stump, this should be done by separate tubes.

The flaps are brought together by *sutures*, which are inserted so as to approximate the deeper tissues, as well as the edges of the skin. Sutures of silkworm-gut or stout silk should be inserted at some distance from the edge of the stump, so as to bring the opposing surfaces of the flaps equally into contact throughout; buried sutures of catgut may also be used if desired. The approximation is completed by a continuous suture which brings the skin edges into accurate apposition everywhere. There are few more important predisposing causes of sepsis than badly approximated flaps, as infection easily reaches the interior of the stump from raw areas on its surface.

The drainage tube should be sutured to the flaps, as otherwise it may be pulled out of or pushed into the stump. It should be removed within three days, and, at the time of the operation, it is a good plan to insert a suture at the spot at which the drainage tube is, and to knot it loosely in a loop instead of tying it; this can be tied when the drainage tube is removed, and thus the interior of the stump is protected from the risk of contamination. When there is much pain following the operation, and a dressing for removal of the tube on the third day would distress the patient, the tube may quite well be left *in situ* for some days longer.

The *method of immobilizing the limb* after the operation is of importance, as the patient's comfort depends largely upon the absence of spasmodic contractions of the muscles of the stump. In order to prevent this it has long been the custom to apply the bandage fastening on the dressings in a circular manner round the limb, and to carry it from above downwards instead of from below upwards. This exerts uniform compression upon the muscles and tends to steady them. A splint or splints should always be applied, as otherwise a good deal of starting pain is likely to be experienced.

The future of the stump. No amputation can be looked upon as really successful unless it leaves the patient with a perfectly sound, painless, well-nourished stump which can be fitted with an artificial limb that will restore the functions of the lost extremity to the greatest extent possible, and the amputation should not be performed unless the surgeon has clearly in his mind the form of stump that he wishes to produce. The

after-history of the amputation should be uneventful, as, if the amputation has been carried out above the level of the disease for which it was performed, and through tissues with an efficient vascular and nerve supply, healing by primary union should occur throughout. The deep sutures can be removed in about a fortnight's time, and the superficial ones a week later. The period of time that must elapse before a patient can bear his weight upon the limb will vary with the particular amputation, but speaking generally it will be from a month to six weeks.

Mortality. It must always be difficult to estimate the mortality of any given form of amputation, as the operations are done for such widely diverse conditions. If, however, amputations be divided into those performed for cases in which there is septic infection and those in which there is none, the mortality of the latter group should consist of only those cases in which death is due directly to the severity of the operation or to the presence of some intercurrent disease. This risk is greater in the old than in the young, and is much increased when it is done for accident, probably because the shock of the accident is added to the shock of the operation. We are still in need of carefully compiled statistics of the various forms of amputation performed with full aseptic precautions. It is probable that the mortality of all except amputations high up in the thigh, disarticulations at the hip and shoulder joints, and Berger's 'fore-quarter' amputation, will prove to be practically *nil*, while of the other forms mentioned, the statistics quoted by Hasbrouck (*Surg. Gyn. & Obstet.*, vol. vi, p. 289) as the mortality of Berger's interscapulo-thoracic amputation may be taken as a fair sample. He quotes Schultz as giving the death-rate for 1875-96 as 13.04%. Berger gives 5%, and Fowler (1900) gives 11.1%. Douglas for 1887-1906 gives the rate as 7.84% for 153 cases, which should be a fair average. The previous figures embrace many cases done under faulty aseptic technique.

AMPUTATIONS IN THE UPPER EXTREMITY

CHAPTER II

AMPUTATIONS OF THE HAND AND WRIST

AMPUTATIONS OF THE FINGERS

THE rule that as much of the limb as possible should be preserved is of special importance in the cases of the fingers. The smallest portion of a finger that can be saved is of value to the patient, and therefore an irregular operation suitable to the particular needs of the individual will often be chosen in preference to any set amputation.

Surgical Anatomy. Certain points must be borne in mind in all these amputations. In the first place, a knowledge of the level of the inter-phalangeal joints is important, as the operation of disarticulating is much facilitated thereby. The prominences of the finger-joints are formed, not by the bases of the distal, but by the heads of the proximal phalanges, and the levels of the joints are one-twelfth, one-sixth, and one-third of an inch respectively below these prominences, counting from the last inter-phalangeal joint upwards to the metacarpo-phalangeal articulation.

In the second place, the arrangement of the tendons in long rigid tendon sheaths, which gape widely after section, must be remembered. This is not a matter of importance in the ordinary aseptic operations done for recent injury or for growth, but it becomes important when the amputation is performed for suppurative affections, such as whitlow or an old injury. Sepsis can spread with great rapidity along the open tendon sheaths into the palm and above the wrist after an operation through infected tissues, and proper precautions must be taken to guard against its doing so.

The mode of attachment of the flexor tendons has an important bearing upon the usefulness of the stump resulting from the amputation. The flexor profundus sends back accessory ligamentous bands which are attached to the middle phalanx, nearly as far up as its centre, and therefore this attachment is retained when the amputation is performed below that spot, and a useful movable stump results. When, however, the amputation is done above this point, neither the flexor nor the extensor tendons have any attachment to the phalanx, and they retract for

some distance up their sheath when they are divided, so that the stump of the finger is rendered useless. When amputating above the centre of the middle phalanx, therefore, the flexor tendons should be seized in forceps before they are divided, and cut as long as possible; the divided ends can then either be brought across the end of the bone and sutured to the extensor tendon, which is treated in a similar manner, or sutured to the edge of the sheath or the soft parts in its immediate vicinity. If this precaution be taken, the old rule, that amputation should not be performed between the centre of the middle phalanx and the metacarpo-phalangeal articulation for fear of obtaining a useless stump, may be safely discarded in favour of the more useful rule of retaining as much of the finger as possible.

An important practical point in connexion with all amputations of the fingers is that the cicatrix should be properly situated. After these amputations the pressure falls partly upon the palmar surface and partly upon the extreme end of the stump, and therefore the scar should never



FIG. 28. FINGER BISTOURY. The blade is very narrow in proportion to its length and the cutting edge is horizontal.

lie in either of these regions; consequently the amputation should be always performed by unequal flaps, preferably antero-posterior ones, the palmar being the longer; the cicatrix will then fall well above the mid-point of the end of the stump. A cicatrix exposed to pressure is a very troublesome matter in the finger.

DISARTICULATION AT THE TERMINAL INTER-PHALANGEAL JOINT

This amputation should always be performed by means of a single palmar flap, which gives a firm covering, preserves good tactile sensation, and places the scar well on the dorsal aspect of the finger. It is frequently required for a crush of the finger, and it is more difficult to perform neatly and quickly than a description of it would lead one to think.

The disarticulation is performed with a narrow-bladed bistoury, called a 'finger knife' (see Fig. 28), the special features of which are that its blade is narrow in comparison with its length, and has not a belly as a scalpel has. This particular form is to enable the knife to be turned easily behind the base of the phalanx when cutting the palmar flap. In length the knife should be about three times the breadth of the finger to be operated upon.

Operation. An assistant pulls the adjacent fingers as widely apart

as possible with strips of bandage (see Fig. 29), and the surgeon, placing the pulp of his left index finger upon the palmar surface and his left thumb upon the tip of the nail of the finger to be operated upon, flexes the joint to a right angle, and then cuts into the inter-phalangeal articulation by drawing the knife across the extensor surface one-twelfth of an inch

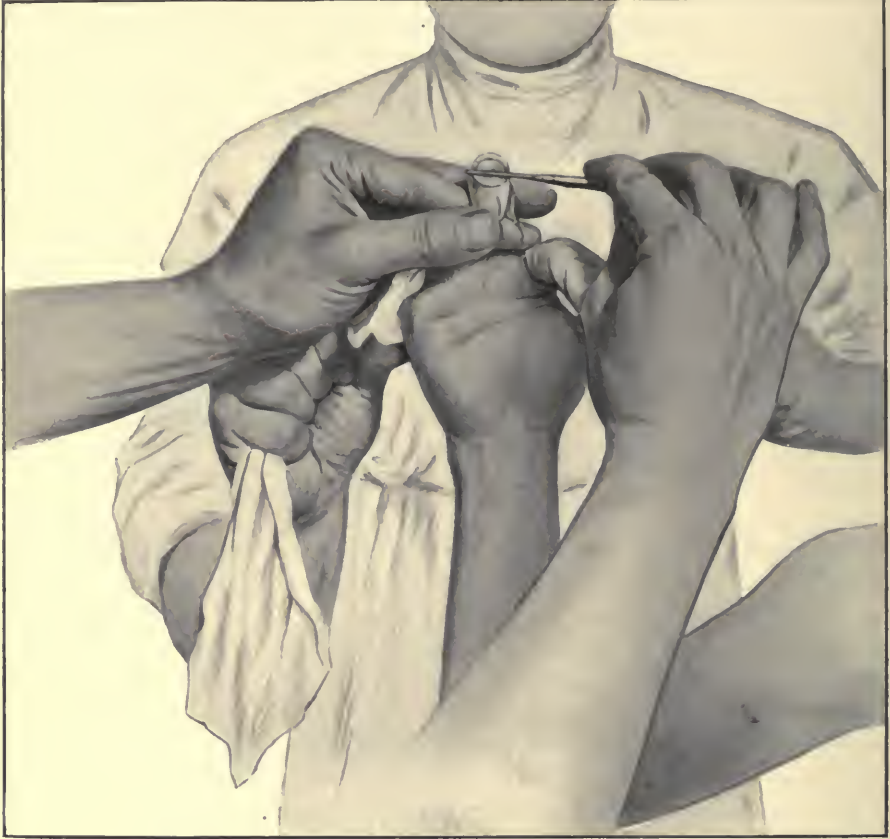

FIG. 29. AMPUTATION AT THE TERMINAL INTER-PHALANGEAL JOINT BY THE LONG PALMAR FLAP. *Making the dorsal incision.* The fingers are held out of the way with bandages by the assistant, who stands behind. The figure shows how the surgeon grasps the tip of the finger and opens the joint. For the sake of clearness the surgeon's hands have been figured as much to one side as possible.

below the prominence formed by the joint (see Fig. 29). In doing this the knife should be held strictly at right angles to the surface of the skin, as otherwise this will be bevelled and its extreme edge may slough. The first incision should divide the extensor tendon and open the joint; the usual mistake is to cut above the line of the joint when trying to do this.

The finger is flexed still further, and the knife divides the lateral liga-

ments by light sawing movements from side to side without being withdrawn from the wound. The base of the terminal phalanx is then pushed firmly forwards by the surgeon's left index finger behind it, and the knife is carried across the joint, dividing the glenoid ligament and the insertion of the flexor digitorum profundus. When the anterior margin of the base of the phalanx is reached, the blade of the knife, which has hitherto

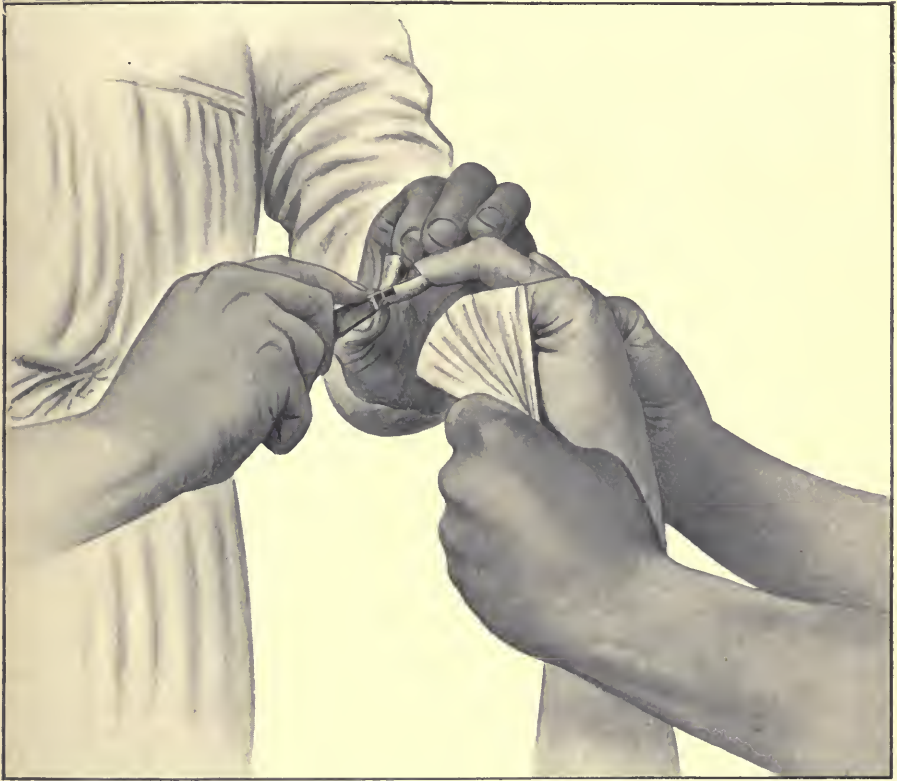

FIG. 30. AMPUTATION AT THE TERMINAL INTER-PHALANGEAL JOINT BY THE LONG PALMAR FLAP. *Completing the palmar incision.* The figure is intended to show how the surgeon holds the terminal phalanx when he finishes cutting the palmar flap so as to avoid wounding his own fingers.

been kept horizontal, is turned so that it is parallel to the palmar surface of the terminal phalanx, down which it is carried by gentle sawing movements until it reaches the point at which the finger begins to taper to its end; this is nearly on a level with the base of the free edge of the nail. The knife is now turned sharply at right angles to its previous direction, and cuts through to the palmar surface with one sawing sweep. As the knife cuts the end of the flap the phalanx is grasped between

the thumb and forefinger by its base and tip (see Fig. 30), so as to avoid the risk of the surgeon wounding his own index finger when the knife is made to cut out. The whole operation should be done without removing the knife from the incision.

This operation fashions a rectangular flap containing all the palmar structures, and of ample length to envelop the head of the middle phalanx and place the cicatrix just on the dorsal aspect of the finger. No tourniquet is needed, and as a rule it is not necessary to ligature any vessels, as only the terminations of the digital arteries are divided, and the bleed-

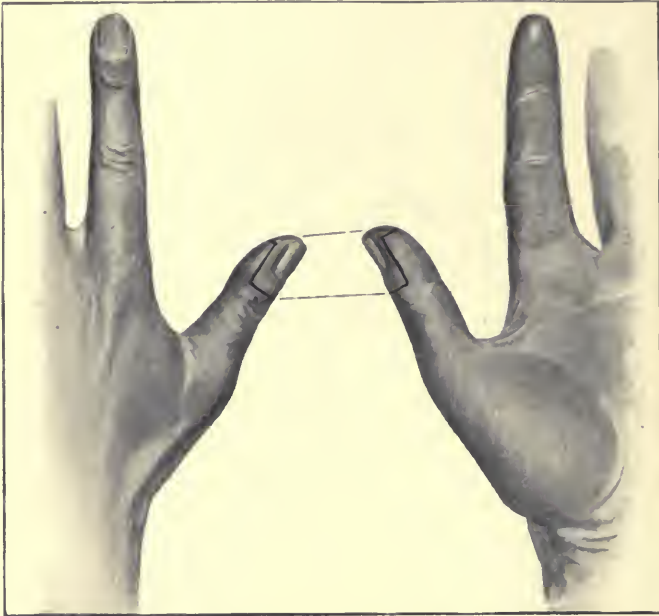


FIG. 31. AMPUTATION OF THE TIP OF THE THUMB BY A LONG PALMAR FLAP. The drawing shows the distance down the thumb in relation to the nail that the palmar incision extends.

ing stops readily on pressure. Two deep sutures of silk or silkworm-gut are required to keep the heavy flap in position, and these may be reinforced by more superficial sutures if necessary. The dressing should be brought round over the end of the stump from the palmar to the dorsal surface. A small splint is put on to steady the finger and to fix the wrist and finger joints. No drainage tube is required, and the articular surface of the head of the middle phalanx need not be interfered with.

This is also a most excellent amputation in the case of the thumb (see Fig. 31), as it gives a stump full of tactile sensation and capable of bearing pressure well.

AMPUTATION THROUGH ONE OF THE PHALANGES

This may be done by a *single long palmar flap*, which, however, should not be cut as in the preceding operation. It is marked out by carrying an incision vertically down the middle of each lateral surface of the finger, far enough to give a flap of sufficient length; the lower ends of these incisions are joined by a transverse cut across the palmar surface of the finger, and the flap thus marked out is raised, the flexor tendons being divided on a level with the lower edge of the flap after having been secured by catch-forceps to prevent them from retracting up their sheath. The upper ends of the two lateral incisions are then joined by a transverse cut across the dorsum, and the bone is cleared and divided with a fine saw, at or just above this level.

By performing this amputation by *antero-posterior flaps*, the anterior or palmar flap being about three times as long as the dorsal, the bone can be divided relatively lower down. This gives a good stump with the cicatrix placed transversely just below the dorsal aspect of the bone.

In all amputations of the fingers above the centre of the middle phalanx the practice of uniting the cut flexor tendons, either to the extensor or to the soft parts in the region of the divided end of the bone, must be adhered to if the patient is to have a useful movable stump; this is a point of the highest importance, the neglect of which will vitiate an otherwise excellent result.

Numerous other forms of amputation have been adopted. Concerning them it may be remarked that those by equal antero-posterior or *lateral flaps* both possess the serious objection that the cicatrix is terminal, and therefore the patient must carefully avoid pressure upon it—a difficult matter in the case of the fingers. Similarly, amputation by a *large internal or external flap* is not perfectly satisfactory, as some part of the resulting cicatrix must be upon the palmar surface and therefore exposed to pressure. Amputation by a *single dorsal flap* is practically out of the question, partly because of the difficulty of fashioning a satisfactory one, and partly because the covering resulting from it is not calculated to stand pressure well.

DISARTICULATION AT THE METACARPO-PHALANGEAL ARTICULATIONS

A large number of amputations have been practised in this situation, the more important types of which, namely, the circular and the oblique racket and the elliptical incisions, and the single large lateral flap, are illustrated in Fig. 32. The cases for which each variety is most suitable will be indicated when each particular operation is described.

Surgical Anatomy. There are certain points to be remembered in connexion with all amputations in this situation. There is not the same objection to a terminal cicatrix in these operations as there is in the case of the fingers. After an amputation of the middle and ring fingers, the pressure falls upon the palmar surface, and the head of the bone is so protected by the adjacent metacarpals that it is not exposed to direct pressure ; therefore the cicatrix may safely be terminal,

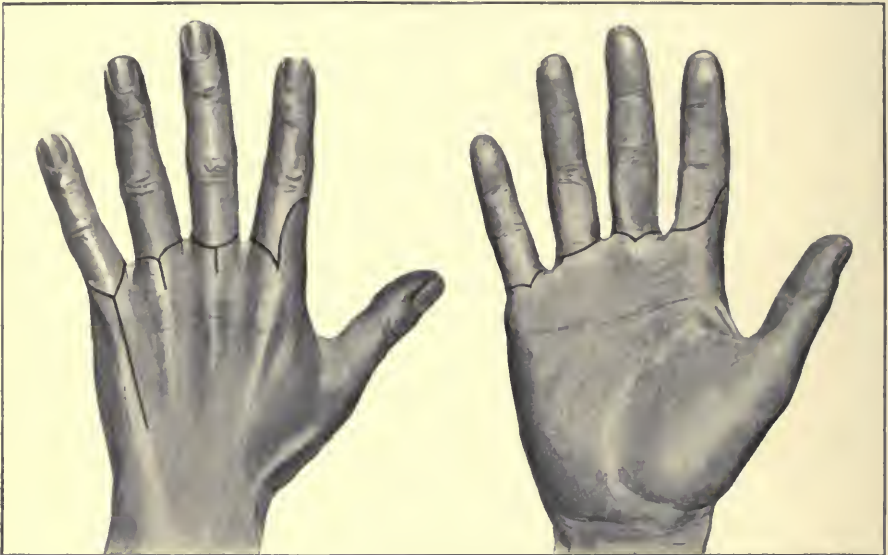

FIG. 32. AMPUTATIONS AT THE METACARPO-PHALANGEAL ARTICULATIONS. The amputation of the index finger is Farabeuf's large radial flap ; that of the middle is the ordinary transverse circular racket ; that of the ring finger is similar to the middle, except that it shows the method of slightly rounding off the flaps to make the cicatrix more sightly (by an oversight the corresponding palmar portions of these incisions have been transposed ; that on the middle finger should be on the ring finger and *vice versa*). The amputation of the little finger is the oblique racket and is meant for use when the head of the metacarpal bone is removed with the finger.

and indeed is so in the most popular forms of this operation. There are, however, three situations in which a terminal cicatrix may be of disadvantage to the patient ; they are the thumb, the index and the little finger joints. In the thumb the pressure falls upon the palmar and the radial aspects of the head of the metacarpal, and disarticulation at the first metacarpo-phalangeal joint therefore should be done by an external or by a palmar flap if possible. In the case of the index finger the pressure falls upon the palmar and radial aspects also, and the form of flap most

suitable to these cases, therefore, is a large external or radial flap, while in the case of the little finger the ulnar aspect bears most of the pressure and a large ulnar flap is therefore preferable.

An important practical point to remember is the large size of the head of the metacarpal, and a common mistake made in performing any of these amputations is to commence the incision too high above the joint line, when, if the form of amputation be one by incisions that diverge from one another, insufficient soft parts are left to cover the head of the bone. The incision for a simple disarticulation should never be begun much above the level of the joint line, which in the case under discussion is one-third of an inch below the prominence of the knuckle. The flexor and extensor tendons are divided at the upper limit of the incision and are allowed to retract. There is no need to close the flexor sheath when the amputation is being done for a whitlow, as it collapses spontaneously instead of remaining widely open, as it does after amputations below the metacarpo-phalangeal articulation.

Amputation by the circular racket incision. By a circular racket is meant one consisting of two incisions, a vertical and a circular one, the plane of the latter being at right angles to that of the former (see Fig. 32).

Indications. This is perhaps the most generally useful method for disarticulation at those metacarpo-phalangeal joints in which the cicatrix is not likely to be exposed to direct pressure: *e.g.* those of the middle or ring fingers, in which the neighbouring fingers protect the cicatrix from undue pressure. It is easy to perform and gives a good covering to the head of the metacarpal, but it is apt to leave a projection on the palmar surface (see Fig. 33) which, although it may impair the æsthetic result, is of no consequence as far as the usefulness of the hand is concerned. The amputation is particularly suited for labouring men.

Operation. The surgeon faces the tips of the fingers and seizes the particular finger to be operated upon in his left hand, while the assistant draws the other fingers away from it with bandage retractors (see Fig. 29). A circular sweep is made around the finger on the level of the free margin of the inter-phalangeal web, dividing only the skin and deep fascia. A vertical incision is then made in the middle line of the dorsum from the level of the metacarpo-phalangeal articulation (*vide supra*) down to the circular incision (see Fig. 32). The flaps thus marked out are raised with knife and forceps, the extensor tendon is divided at the level of the articulation, the edges of the flap are hooked back by an assistant, and the surgeon, taking the finger in his hand, hyper-extends it and bends it from side to side as may be necessary, while he divides the soft parts from the phalanx, cuts across the flexor tendon at the level of the base

of the proximal phalanx, divides the glenoid and lateral ligaments, and disarticulates. No tourniquet is needed, as the vessels can be picked up as they are divided.

The wound is sewn up without a drainage tube, and gives a scar running across the head of the metacarpal bone from the palmar to the dorsal surface. The somewhat ugly projection left on the palmar surface when sewing up this incision may be obviated by taking out a small V-shaped piece of the flap in front (see Fig. 33); this makes the operation somewhat similar to one by lateral flaps.

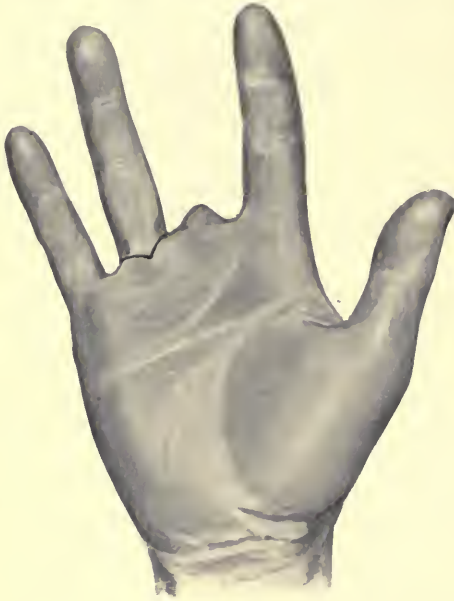

FIG. 33. THE PROJECTION LEFT AFTER DISARTICULATION AT THE METACARPO-PHALANGEAL JOINT BY THE CIRCULAR RACKET METHOD. The incision shown at the base of the ring finger is the modification of the ordinary transverse incision necessary to prevent the formation of the rather unsightly projection formed when the wound is sewn up, as is shown in the case of the middle finger.

Amputation by an oblique racket incision. By an oblique racket is meant one in which the plane of the head of the racket is inclined at an obtuse angle to that of the handle. In the case of the metacarpo-phalangeal joints, this particular form of amputation is only suitable for those cases in which the head of the metacarpal bone is to be removed as well as the finger; in other words, the operation is not a true disarticulation.

Indications. Removal of the head of the metacarpal bone along with the finger is practised for the sake of symmetry only, and possesses no other advantages. The strength of the grasp and the utility of the hand are impaired if the head of any of the metacarpal bones be removed,

and therefore in labourers and in all those who are desirous of preserving a strong grasp, the head of the bone should not be taken away. In women, however, the removal of the head of the metacarpal bone gives such a good æsthetic result that the fact of the finger having been amputated may actually escape notice; it gives a particularly good result in the index and little fingers.

Operation. The surgeon stands facing the limb, as before, and grasps

the finger to be operated upon in his left hand, while his assistant keeps the other fingers out of the way, either with his fingers or with bandage retractors. The incision is commenced nearly half-way along the dorsal aspect of the metacarpal bone, and is carried vertically down it as far as the neck of the bone. Here it diverges to the right and is carried to the free margin of the web, then transversely across the palmar surface of the finger on a level with the highest crease at its base, and back again from the free margin of the web on the left side to the point at which it diverged from the vertical incision. This marks out a racket incision with an oval head (see Fig. 32). The flaps are dissected up as before, but in this case the dissection is carried further back and without opening the metacarpo-phalangeal joint. The transverse ligaments uniting the head of the metacarpal to the adjacent bones are divided, and the head and neck of the bone are cleared with a raspator. The neck of the bone is then sawn obliquely from above downwards, from the dorsal to the palmar surface in the case of the third or fourth metacarpals; in the case of the index finger the line of section will be from above downwards from the radial to the ulnar side, while in that of the little finger the obliquity will be from the ulnar to the radial side.

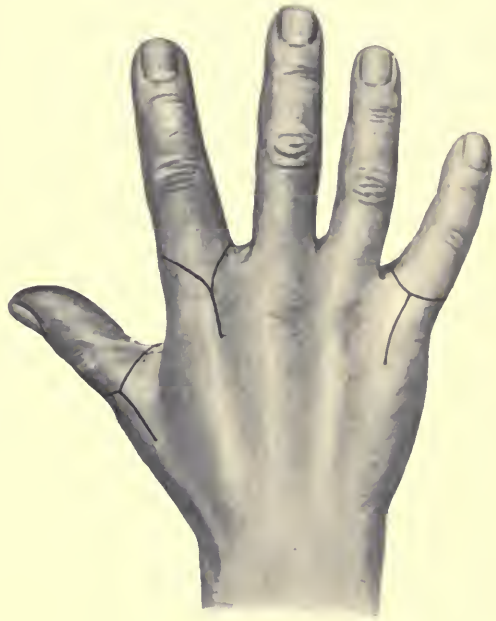

FIG. 34. RACKET INCISIONS FOR DISARTICULATION AT THE METACARPO-PHALANGEAL JOINTS OF THE THUMB, INDEX AND LITTLE FINGERS. The drawing shows the way in which the handles of the racket are placed so as to be out of the way of pressure. It also shows the slight prolongation of the lateral flap on the side from which pressure is to be expected.

Fig. 34 shows the various modifications that may have to be made in these different forms of racket incisions. If either the thumb, index or little fingers are to be amputated by the circular racket method, the incision should always be planned so that the scar does not lie near the line of pressure. Thus, in the thumb or index finger the handle of the racket should be placed well on the ulnar side of the extensor tendon,

and it is well also to make the circular incision around the phalanx not quite at right angles to the long axis of the finger, but somewhat oblique, so that the skin flap on the radial side is longer than on the opposite side. This allows the cicatrix to be drawn over to the ulnar side, out of the way of pressure. In the little finger the vertical incision should be on the radial side of the extensor tendon, and the flap should be longer on the ulnar side, so as to throw the cicatrix over towards the ring finger.

Amputation by a single large lateral flap (Farabeuf's amputation). **Indications.** This amputation is particularly suitable for the thumb, the index or the little finger. In the case of the thumb or the index finger, the flap is cut from the radial and palmar surfaces, whilst in the case of the little finger it is fashioned from the ulnar and palmar surfaces. The incision for the flaps is identical in the two cases, and the operation is similar to that for the great toe (see p. 160). The stump in each case is very good, as the large flap covers the head of the bone easily, and the cicatrix lies well out of the way of pressure.

Operation. The surgeon stands facing the tips of the fingers and seizes the one to be operated upon in his left hand, dorsal surface uppermost, his assistant meanwhile keeping the adjacent fingers out of the way with a suitable bandage retractor (see Fig. 29). When operating upon *the right index finger* the incision is begun exactly on a level with the line of the joint just to the radial side of the extensor tendon, and is carried vertically down until it is just below the level of the free margin of the interdigital web; this will be nearly half-way down the proximal phalanx. It is then sloped outwards over the radial side of the finger with a slight convexity downwards until it reaches the junction of the inner with the palmar surface; thence it is carried upwards across the palmar surface to the junction of the finger with the interdigital web just below the highest transverse palmar crease. From this point it passes back across the dorsal aspect of the web by the shortest possible route to the point from which it started. This incision may be made in one sweep, the left hand raising and manipulating the finger meanwhile, but it is easier to do it in two.

In the case of *the left index finger* (see Fig. 32) the incision is marked out in the reverse direction, passing from the same starting-point as before to the interdigital web, then across the palmar surface of the finger, and finally back to the commencement of the incision. The edges of the skin are seized in forceps, and the flap is raised right up to its base. The extensor tendon is divided on a level with the joint, and the surgeon then takes the finger and disarticulates in the usual manner, the large flap being well retracted meanwhile. The easiest plan is to open the joint from

the ulnar side and to complete the disarticulation by the division of the glenoid ligament and the flexor tendon.

Amputation of the thumb is done in almost exactly the same manner; that of the little finger is also similar, except that the flap is an internal instead of an external one (see Fig. 35).

Amputation by an elliptical incision. **Indications.** This amputation is particularly useful in the thumb, and really fashions a long palmar flap which is admirably calculated to bear pressure. In amputating the thumb the surgeon should always endeavour to save as much bone as possible, for, as Farabeuf remarks, the thumb is more

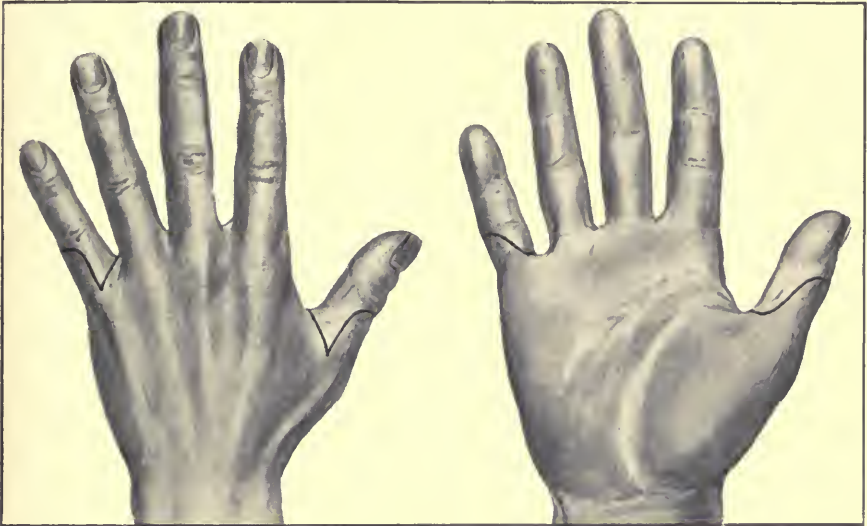

FIG. 35. FARABEUFS AMPUTATION AT THE METACARPO-PHALANGEAL JOINTS OF THE THUMB AND LITTLE FINGER.

valuable than all the other fingers put together, and even the smallest amount of bone saved is of the greatest importance, and therefore the surgeon should never disarticulate unless he is driven to do so, and should never choose that operation in preference to one that will retain a portion of the proximal phalanx merely for the sake of making a neat and tidy job. When amputating the thumb it must be remembered that the pressure falls largely upon the palmar and to some extent on the radial surface, and if possible, therefore, the cicatrix should be placed so that it does not fall in either of these situations.

Operation. The thumb is seized and abducted fully with the left hand, and a U-shaped incision with its convexity directed upwards is made on the dorsal aspect of the thumb with its highest point immediately

below the line of the metacarpo-phalangeal joint. The lateral limbs of the incision run down the centre of the lateral aspect of the thumb (see Fig. 36). The best plan is to begin the incision almost on the level of the inter-phalangeal joint in the middle of the left-hand side of the thumb as it faces the surgeon with its dorsal aspect upwards, carry it up to just below the level of the metacarpo-phalangeal joint, then almost transversely across the dorsal aspect and down again on the right-hand

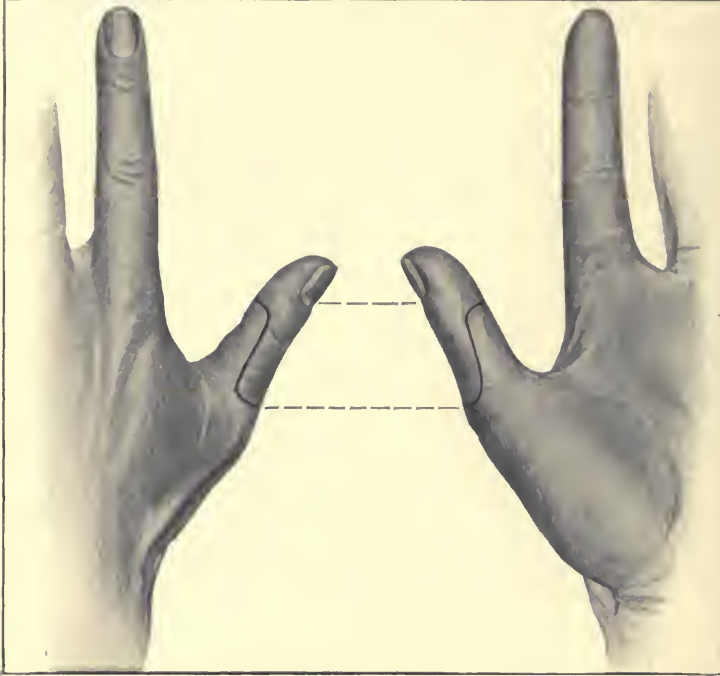


FIG. 36. DISARTICULATION AT THE METACARPO-PHALANGEAL JOINT OF THE THUMB BY AN ELLIPTICAL INCISION.

side to the level of the commencement of the incision on the opposite side. The thumb is then raised so that the palmar surface is exposed, and the two lower ends of the incision are joined by a curved incision convex downwards across the palmar aspect of the thumb from left to right just above the level of the transverse crease. The palmar flap is raised down to the tendon sheath, and the flexor tendon is divided opposite the base of the first phalanx. The surgeon then hyper-extends the thumb forcibly with his left hand and opens the joint by dividing the glenoid ligament with the point of his knife, the assistant meanwhile retracting

the flap and fixing the metacarpal bone. A few touches of the point of the knife complete the disarticulation, the thumb being twisted from side to side as may be necessary.

Amputation of a digit with its metacarpal bone.

Indications. Removal of a finger together with the whole of its corresponding metacarpal bone is rarely required except for severe crushes of the thumb; it is rare to find the entire metacarpal crushed in the case of the other fingers except when several are damaged. In septic cases it is generally possible to save a portion of the base of the bone, whilst in tuberculous cases it may be possible to excise the metacarpal bone alone without removing its corresponding finger; either of these procedures is preferable to removal of the finger and the entire metacarpal. In the case of the thumb it is important to remember that some portion of the metacarpal bone should always be left if this can be done safely, as the least part remaining gives a certain steadiness and mobility to the stump, which it would otherwise lack.

Amputation of the thumb with its metacarpal bone. At the present day this amputation is almost always performed by means of an oblique racket incision with a short handle and a long oval racket (see Fig. 37).

Operation. The surgeon stands facing the hand, which is held midway between pronation and supination, and seizes the thumb between his left thumb and index finger, holding it either horizontal or slightly flexed with the dorsal surface upwards. The point of the knife is inserted a finger's breadth below the radial styloid process over the tendons of the extensor ossis metacarpi (abductor pollicis longus) and primi internodii pollicis (extensor pollicis brevis) and carried along the metacarpal bone for an inch. The incision must not commence further out on the dorsal surface than the tendons mentioned, otherwise the radial artery will be damaged as it lies in the 'anatomical snuff-box'. The incision is now made to diverge to the surgeon's right hand so as to encircle the neck of the metacarpal bone, and it is carried round across the palmar surface to the free edge of the interdigital web quite close to its junction with the thumb. As the palmar portion of the incision is being traced out the thumb is hyper-extended. This is as far as the incision can be carried at one sweep, and the surgeon then flexes the thumb, and, passing his knife over the dorsal surface, continues the incision from the last point back around the neck of the bone, on the same level as on the opposite side, to the point at which the divergence from the middle line commenced, namely, an inch from the commencement of the incision.

In order to get satisfactory covering for the stump it is necessary to carry the racket sufficiently close to the neck of the bone, and for this

purpose the line of what Farabeuf calls 'the opposition crease' should be followed. This is the crease seen on the palmar and radial aspects of the thumb just above the metacarpo-phalangeal articulation, which is brought into special prominence when that joint is flexed and the thumb adducted; it can always be made out.

The incision is deepened all round, and the extensor tendons are divided as they are met with in the wound; they will be divided at the commencement of the incision in the left hand, but at the end of it in

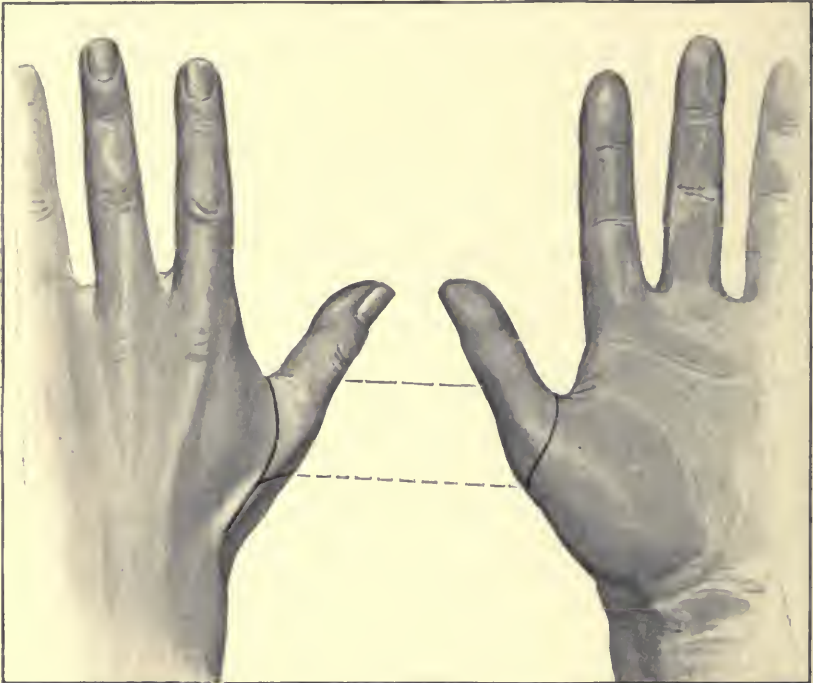


FIG. 37. AMPUTATION OF THE THUMB WITH ITS METACARPAL BONE BY THE OBLIQUE RACKET INCISION.

the right. The thumb is now grasped by the left hand and forcibly hyper-extended, and the knife is drawn across the palmar aspect of the neck of the bone, dividing the flexor tendon and all the soft parts. The muscles are dissected cleanly off the metacarpal bone right back to its base, the knife being kept very close to the bone throughout. The line of the carpo-metacarpal articulation may be identified by abducting and adducting or flexing and extending the thumb; as soon as it is evident, the point of the knife is inserted into the joint from the dorsal aspect and the ligaments on the outer side are divided. Care must be

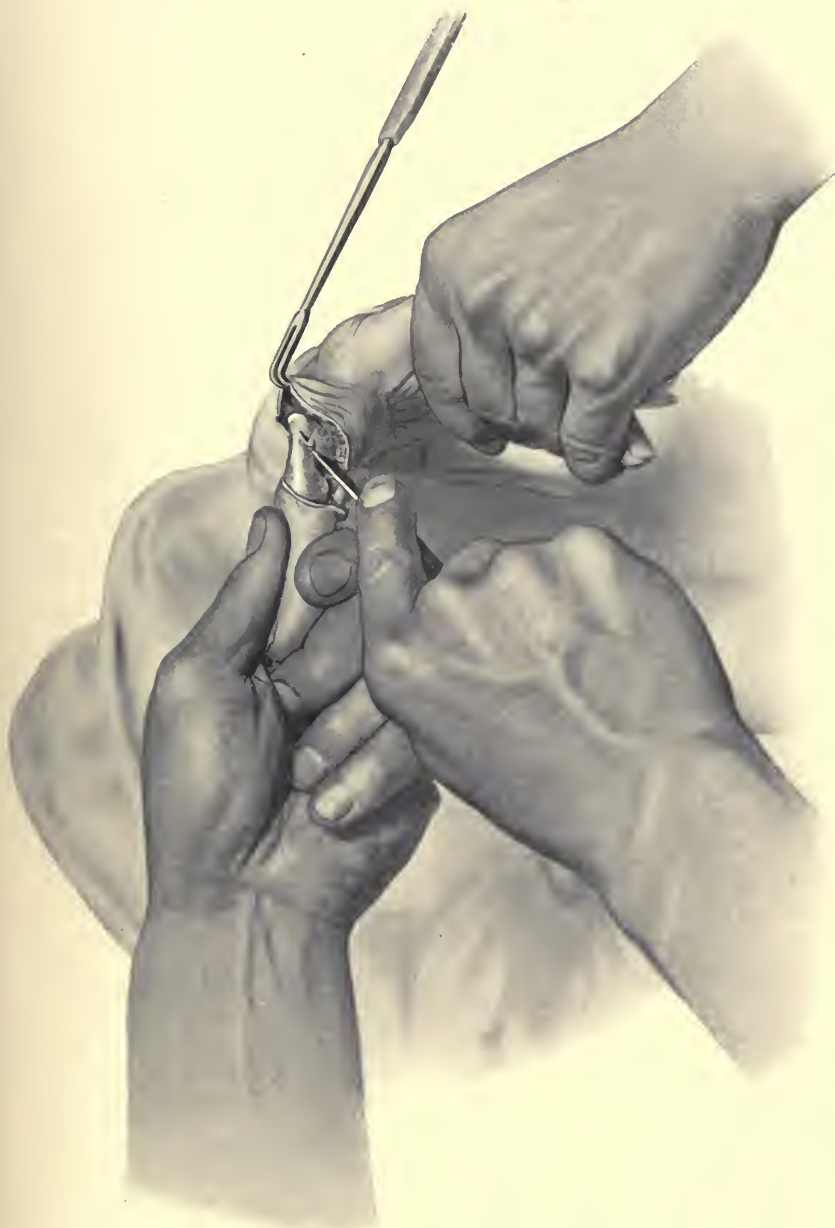

FIG. 38. METHOD OF MANIPULATING THE THUMB DURING ITS REMOVAL. By grasping the thumb as shown in the figure the surgeon has perfect control over it and can twist it in any direction he pleases. The drawing shows the last few touches of the knife necessary to separate the ligaments on the inner side of the joint.

taken not to damage the radial artery, which passes between the first and second metacarpal bones at the upper end of the first interosseous space ; the head of the bone should be twisted out as much as possible, and, as disarticulation proceeds, only the point of the knife is used to divide the ligamentous structures (see Fig. 38). The soft parts in the first interosseous space must be protected from injury during disarticulation by a suitable retractor.

Amputation of a finger with its corresponding metacarpal bone.

The only finger for which this operation is really useful is the little finger. When disease affects the metacarpal bone as well as the finger, complete removal of the little finger with its metacarpal gives a neat appearance to the resulting hand, which is not materially weakened thereby. The peculiar manner in which the other metacarpal bones are wedged in between each other, however, renders their complete removal difficult, and therefore, if it be feasible, it is advisable to stop short of complete disarticulation and to divide the shaft of the bone before its base is reached. This renders the operation easier as well as safer, since it diminishes the chance of wounding the deep palmar arch, an accident of some importance owing to the difficulty of securing the wounded vessel ; moreover, it avoids opening the general synovial cavity of the wrist, which would be a matter of importance were the mischief, for which the amputation is being performed, either septic or tuberculous.

When removing the little finger with its corresponding metacarpal bone, the only point of importance is to see that the cicatrix does not lie along the ulnar border of the hand, as in that case it will be exposed to injurious pressure ; therefore the incision should be well on the dorsal surface.

Operation. The incision commences over the base of the fifth metacarpal well up on its dorsal aspect ; it then runs down over its subcutaneous surface to just below its centre, whence it diverges to the ulnar side of the little finger just below the level of the free margin of the web ; then it passes around the palmar aspect of the finger, nearly parallel to but just below the transverse crease at the base of the finger, to the junction of the little finger with the web, and from this point back to the point at which it diverged from the middle line (see Fig. 39). The incision, which is cut in an almost exactly similar manner to that for the thumb (see p. 109), is now deepened all round, and the soft parts are dissected up from the bone on the inner aspect of the wound. The flap is held aside by the operator's left thumb or forefinger, while the knife is passed around the neck of the bone, dividing the flexor tendon and the transverse ligament uniting the heads of the fifth and fourth metacarpals. This allows the former bone to be pulled inwards away from the latter, so

that the interossei can be separated from the radial side of the bone right down to its base. Disarticulation is not easy; to facilitate it the surgeon may either make a transverse incision across the commencement of the handle of the racket, or he may prolong the incision inwards in a curved manner as recommended by Farabeuf (see Fig. 39). After the soft parts have been dissected up a little more, the interosseous ligaments uniting the base of the fifth to that of the fourth metacarpal

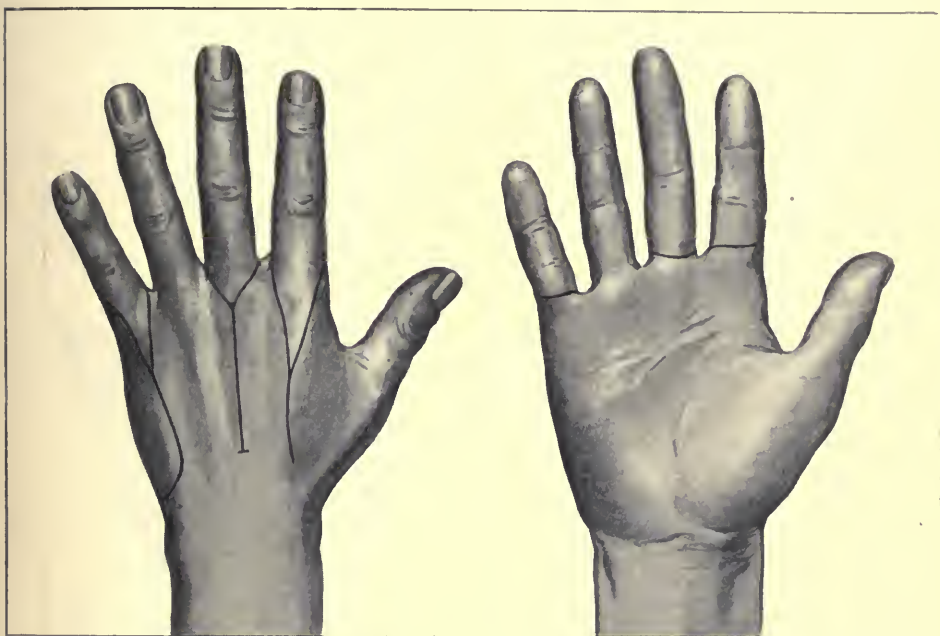


FIG. 39. INCISIONS FOR REMOVAL OF A FINGER WITH ITS CORRESPONDING METACARPAL BONE. The incisions shown are those appropriate for the particular fingers to which they are allotted. In the little finger the handle of the racket is curved away to the inner border of the hand, and the flap on the ulnar side reaches rather lower down than its fellow in order to get the cicatrix out of the way of pressure. In the case of the index finger the reverse is the case. In the middle finger the removal of the metacarpal bone is facilitated by the transverse incision at the upper end of the incision.

are divided by a few touches of the knife, the finger being twisted in any desired direction in order to facilitate this.

The resulting stump is very good. No drainage tube is necessary either in this case or for the similar amputation in the thumb, as the dressing will keep the parts in good position if it be firmly wound round the hand after the sutures have been applied, and this suffices to prevent blood from accumulating between the flaps. The hand should be placed

on a straight palmar splint, which fixes the wrist-joint ; the forearm is carried in a sling.

Amputation of more than one finger with their corresponding metacarpal bones. The operations of this kind that may be called for are so diverse that it is useless to attempt a full description of the various procedures that may be employed ; in every case the flaps must be planned so that as little as possible of the bone is removed. The nature of the injury itself will generally preclude any set operation, as the soft parts will probably be damaged very irregularly and in various directions, and the surgeon will often be able to patch his flaps together so as to save a larger

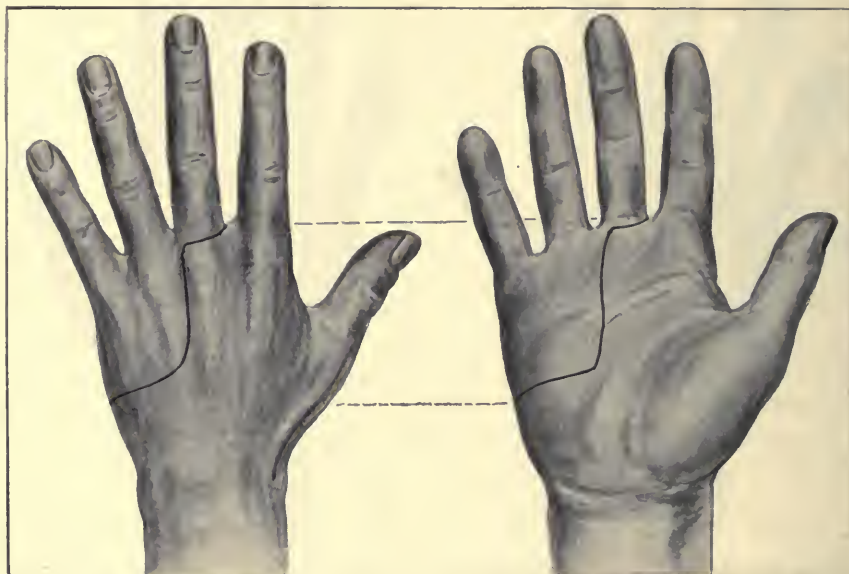


FIG. 40. INCISIONS SUITABLE FOR REMOVAL OF THREE FINGERS WITH THEIR CORRESPONDING METACARPAL BONES.

amount of bone than he would be able to do with a set amputation. Fig. 40 shows a useful incision when two or three fingers are crushed and require removal. Occasionally it happens that all four fingers are crushed, as in machinery accidents, when Fig. 41 shows a good method of amputating. This is really a series of amputations by antero-postero flaps, the anterior being cut along the level of the palmar crease, whilst the dorsal flaps reach well below the level of the interdigital web to allow for retraction.

Fig. 42 shows an incision for the removal of the four fingers and their respective metacarpal bones by a somewhat elliptical incision. In a case

like this the metacarpals would not be disarticulated, but would be sawn across near their bases.

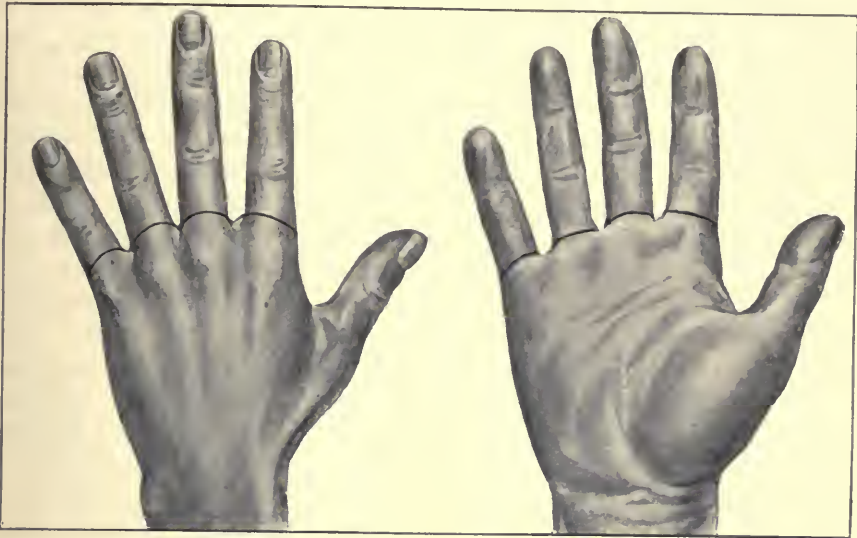


FIG. 41. INCISIONS FOR REMOVAL OF ALL THE FINGERS. These are really a series of separate incisions for each disarticulation.

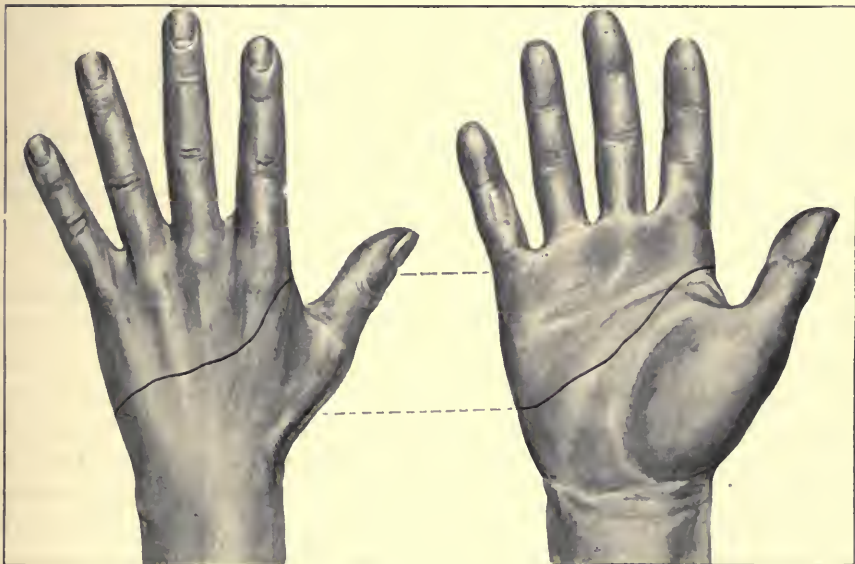


FIG. 42. INCISION FOR REMOVAL OF ALL THE FINGERS WITH THEIR CORRESPONDING METACARPAL BONES. This may be modified when it is desired to retain portions of the metacarpal bones.

DISARTICULATION AT THE WRIST-JOINT

This amputation should be practised in preference to one through the lower third of the forearm whenever the condition of the soft parts allows of it ; the resulting stump is greatly superior owing to the preservation of the inferior radio-ulnar joint, the insertion of the supinator longus (brachio-radialis) muscle, and the styloid processes, which provide good purchase for the artificial limb and preserve the movements of pronation and supination. It is not suited for tuberculous disease of the wrist, however, owing to the early implication of the tendon sheaths in the neighbourhood of the joint that occurs in that affection.

The artificial hand is generally fixed to the end of the stump by a firm band around the wrist, and therefore the cicatrix should not lie over the expanded ends of the bones, as in that case it will be compressed by the apparatus. A terminal cicatrix is not open to this objection, however, as it falls into the hollow space between the styloid processes of the radius and ulna and so escapes pressure. If a single flap be employed, it should be a long anterior one, as the integument of the palm is well adapted to bear pressure, and the cicatrix is drawn high up on to the dorsal surface of the forearm afterwards, where it is fairly well out of the way of undue friction. There are three methods of disarticulating at the wrist-joint, all of which are good : they are :—

(i) The Circular Amputation, (ii) By an Elliptical Incision, (iii) By a Single Anterior Flap. Of these the circular amputation is the best on the whole. It is done as follows :—

Amputation by a circular incision. A tourniquet is applied to the brachial artery around the middle of the upper arm, the forearm is drawn well away from the side and held horizontal by an assistant, whilst the surgeon stands facing the trunk with the patient's hand grasped in his left hand. The hand is now rotated over towards the surgeon's right, i. e. if it be the right hand it will be fully supinated, if the left, fully pronated. The knife is entered about an inch and a half vertically below the tip of the styloid process on the surgeon's left, and is carried across the upper aspect of the hand with a slight convexity downwards, and then round across the opposite side to meet the commencement of the incision, the hand being rotated meanwhile to meet the knife, so that its original position is exactly reversed when the incision is completed. This incision forms a circular sweep around the limb a full inch below the level of the wrist-joint (see Fig. 43) and should be deepened sufficiently to allow the skin to retract fully. The hand is then given to an assistant, and the surgeon raises the cuff of soft parts that the incision has marked out by pinching up the cut edge and dividing the cellular tissue with

a few touches of the knife ; the skin is raised until the tips of the styloid processes are exposed, and is kept well out of the way by an assistant.

The surgeon now takes the hand again, pronates it, flexes it firmly, feels for the styloid process on his left-hand side, and divides the lateral ligaments with the point of the knife, which is then drawn across the dorsal aspect of the joint, dividing the posterior ligament together with the extensor tendons, and finally the lateral ligament on the right-hand side (see Fig. 46). This opens the joint, which is then fully flexed, whilst the surgeon proceeds to separate from left to right the soft parts from the arch formed by the pisiform and unciform bones, twisting the hand and pulling it away from the forearm meanwhile, so as to define accurately the structures he is dividing. When this has been done, the sole connexion

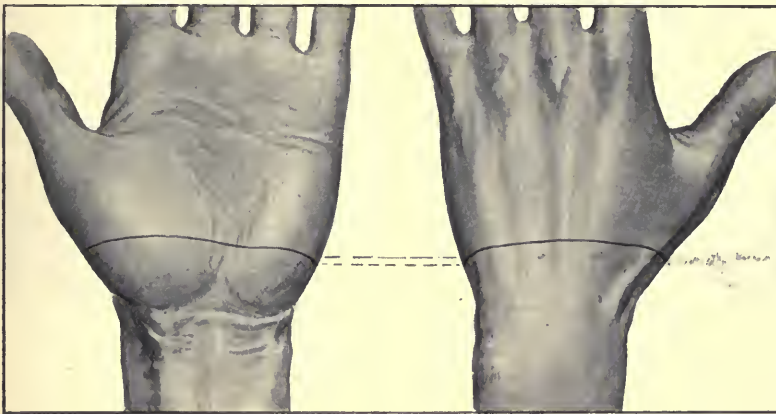


FIG. 43. DISARTICULATION AT THE WRIST BY A CIRCULAR INCISION.

between the forearm and the hand is the flexor tendons, which are divided by a single clean downward cut.

The tourniquet is now removed, and the radial and ulnar arteries are ligatured ; the median nerve is looked for and a portion removed. The wound is sutured so that the scar is transverse, and a small drainage tube is inserted at one end of it ; this is removed in two days' time. The arm is put up on an internal angular splint midway between pronation and supination, and the forearm is carried in a sling.

Amputation by an elliptical incision. This operation is practically a modification of that by the long palmar flap (see p. 118), and will be only rarely used because, owing to the variable retractility of the skin about the wrist, it is rather difficult to cut the flap satisfactorily. As, however, the incision does not descend so far on the anterior surface as it does in the long palmar flap operation, the surgeon may be able occasionally to perform disarticulation by its means when the long palmar

flap is inadmissible. The incision is an ellipse with its highest point on the dorsal aspect of the limb, half an inch below the level of the radio-carpal joint and slightly to the ulnar side of the middle line ; its lowest point is on the palmar surface over the third metacarpal bone, three inches below the level of the radio-carpal joint (see Fig. 44).

The positions of the patient and the surgeon are the same as in the preceding operation ; a tourniquet is applied to the brachial artery. The hand is fully supinated and held in the left hand, and the incision is commenced on the left side of the hand with a fairly long-bladed knife marking out the anterior or lower portion of the ellipse. This crosses the radial border of the hand on a level with the first carpo-metacarpal joint, and the ulnar border between the

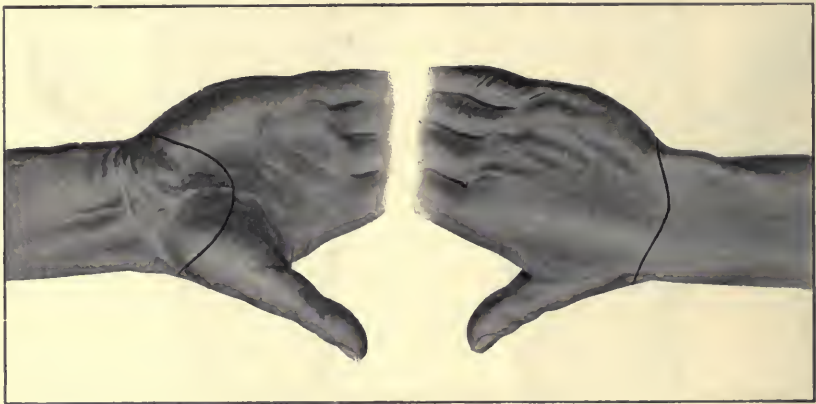


FIG. 44. DISARTICULATION AT THE WRIST BY AN ELLIPTICAL INCISION.

pisiform bone and the base of the fifth metacarpal ; between these two points it takes a gently rounded sweep down to its lowest limit (*vide supra*). The incision goes down through the palmar fascia only in the centre of the palm, but down to the bones on each side. The hand is next pronated and the dorsal incision is marked out (see Fig. 44), the assistant pulling the skin well upwards before this is done. This part of the incision is carried down through the tendons until the posterior ligament of the wrist is divided and the joint is opened. Then the hand is fully flexed, and the lateral ligaments are divided from left to right as in the circular amputation (see p. 117), with which the remaining steps of the operation are similar.

Amputation by a long palmar flap. This is a U-shaped flap, the incision for which commences immediately below the tip of the radial styloid process, and ends half an inch below the tip of that of the ulna.

The flap is rather more than three fingers' breadth in length, and is almost square, the edges being slightly rounded off. There is no dorsal flap, the horns of the palmar incision being joined by a cut across the dorsum without any convexity downwards, so that it is actually a little concave downwards after the skin has retracted (see Fig. 45).

The flap is somewhat difficult to shape nicely, owing to the projection of the thenar eminence, but it may help the surgeon in marking it out to remember that the outer or radial border of the flap, if prolonged downwards, would strike the interval between the index and middle fingers when the hand is fully extended and the fingers are close together, while the ulnar border of the flap if similarly prolonged would hit the interval

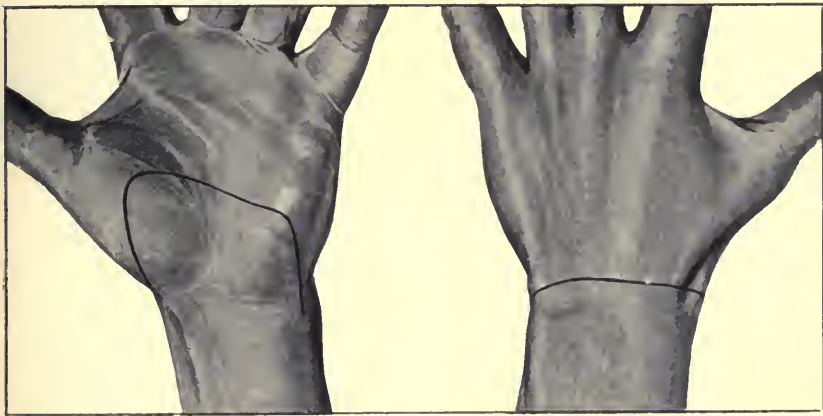


FIG. 45. DISARTICULATION AT THE WRIST BY A LONG PALMAR FLAP. Owing to the position of the hand from which the drawing was made the palmar flap appears to be somewhat oblique; it is, however, really almost rectangular.

between the ring and the little fingers. The two commonest mistakes made in this operation are to make the flap too long, and to fashion it so that its base is its narrowest part; it should taper very slightly from base to apex. The lower extremity of the flap does not reach quite as far down as the superficial palmar arch.

All the soft parts down to the flexor tendons are raised with the flap; they comprise the muscles in the thenar and hypo-thenar eminences, the median nerve, the palmaris longus tendon, and the termination of the ulnar artery and nerve. It is also well to raise the pisiform bone in the flap so as to avoid the risk of damage to the ulnar artery, which might occur were an attempt made to dissect the flap from it.

When the flap has been dissected up to the level of the styloid processes, it is folded back upon the flexor surface of the forearm and given in charge of an assistant, whilst the surgeon, pronating the hand fully,

joins the terminations of the palmar incision across the dorsum by a transverse cut through skin and fascia only, which are allowed to retract fully. By a second sweep of the knife the extensor tendons are divided on the level of the edge of the retracted skin, and the knife is then applied to the left-hand side of the joint and made to divide first one lateral ligament, then the dorsal ligament of the wrist, and finally the lateral ligament on the opposite side, so that the joint is fully opened from

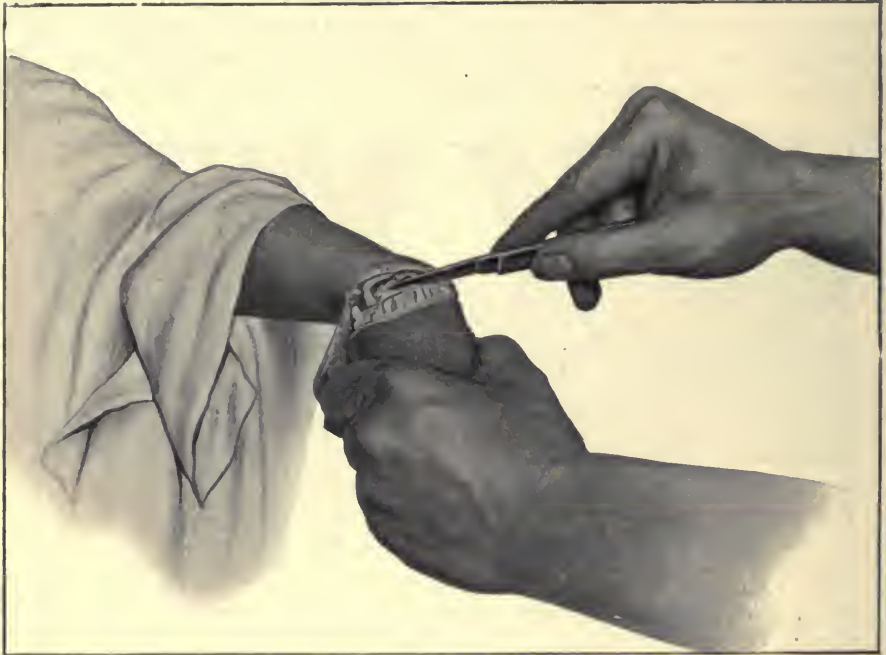

FIG. 46. THE METHOD OF DISARTICULATING AT THE WRIST. The drawing shows how the hand is grasped by the surgeon's left hand so that he is able to manipulate it during the disarticulation. It shows the knife being drawn across from the surgeon's left to right, dividing the ligamentous structures from the dorsal surface.

the dorsal surface (see Fig. 46). With the wrist fully flexed, a few touches of the knife will divide the anterior ligaments, and nothing remains but to sever the hand from the forearm by dividing the mass of flexor tendons. This is done by straightening the wrist, pulling the hand well away from the forearm, passing the knife into the wrist-joint, and cutting firmly downwards with a few quick sweeps; during this procedure the palmar flap remains folded up against the flexor surface of the forearm, and must be carefully protected from damage by the assistant.

The ulnar and the superficialis volæ arteries require ligature, and the end of the median nerve should be dissected out of the flap and an inch of it removed. The pisiform bone is also dissected out without injuring the ulnar artery. The limb is put up as in the previous operations, the dressing being carried over the end of the stump from the flexor to the extensor aspect, so as to keep the hinge-like flap in place. Two stout sutures taking a deep hold of the flap will be required to take tension off the more superficial stitches. A small drainage tube should be employed. The cartilage of the radio-ulnar arch is not interfered with

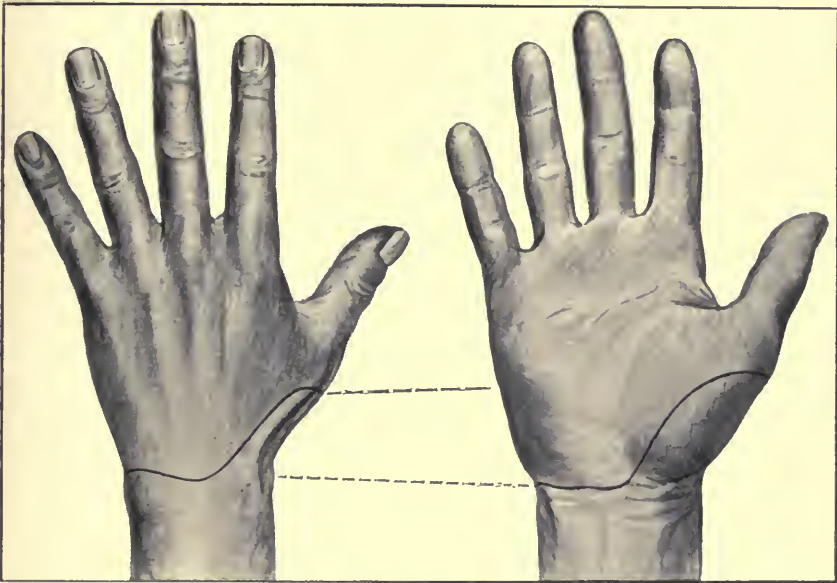


FIG. 47. DISARTICULATION AT THE WRIST-JOINT BY A LARGE EXTERNAL FLAP.

unless it be the seat of disease, in which case it is removed with a gouge or chisel.

Amputation by a single external flap. This method may sometimes be adopted when the hand is crushed obliquely in machinery accidents, leaving only the tissues over the thumb intact. These structures make a useful covering for the stump. The incision is seen in Fig. 47, and commences at the junction of the outer with the middle third of the posterior aspect of the wrist immediately below the line of the joint. It is carried down, as shown in the figure, as far as the middle of the metacarpal bone of the thumb, when it crosses the radial border of that bone and is carried upwards on the thenar aspect to terminate at a point on the front of the wrist opposite to that at

which it commenced. There is no flap on the inner side ; the knife is drawn transversely round from the dorsal to the palmar termination of the first incision. In dissecting up the external flap all the muscles of the thenar eminence are included, and disarticulation is effected from the inner side. The method, although a satisfactory one, is inferior to the others previously described, and should only be used when the nature of the injury renders it necessary.

CHAPTER III

AMPUTATIONS OF THE FOREARM AND ELBOW

AMPUTATION THROUGH THE FOREARM

WHEN an amputation is done in the forearm it is very important to have the stump as long as possible, so as to provide sufficient leverage for the artificial limb. Even when only a small fraction of the bones of the forearm have been preserved, flexion and extension of the elbow can be practised, but the power over the artificial limb increases in direct proportion to the length of the stump, and therefore the bones should always be divided as low down as possible. The pressure to which the stump is exposed from an artificial limb falls upon its anterior and posterior aspects and not on its termination. After an amputation the bones of the forearm lose the mutual support derived from the inferior radio-ulnar joint; their lower ends approach one another somewhat, and finally occupy a position nearly midway between pronation and supination, the radius being thrust somewhat forwards and lying upon a plane anterior to that of the ulna. During flexion of the elbow the pressure exerted by any artificial limb falls upon the anterior surface of the limb over the end of the radius, whilst during extension it comes against the posterior surface of the ulna. From these considerations it follows that an amputation of the forearm by the circular method, or some modification of it, is peculiarly suitable, as it gives a terminal cicatrix and allows the bones to be divided on a lower level than any other form of amputation.

Owing to the tapering shape of the forearm, the ordinary circular amputation, as performed typically in the upper arm (see p. 142), is not suitable, at any rate below the middle of the forearm; in this situation it has to be modified very considerably, since the muscular tissue has largely given place to tendons, and special means have to be adopted to divide these neatly and upon the same level.

In the upper third of the forearm the circular amputation is not so suitable because so many of the muscles of the forearm arise from the upper third of the radius or ulna, and therefore it is difficult to get sufficient retraction of the muscular fibres after a circular amputation to allow the bone to be cleared and divided sufficiently high up, and in this situation, therefore, a flap amputation will be preferable.

The only methods that will be described here are the modified circular method and that by equal antero-posterior flaps. Many other methods are applicable in the forearm, but since it is of the highest importance



FIG. 48. THE CIRCULAR AMPUTATION. Commencing the Incision.

to sacrifice as little of the bones as possible, only the two most economical methods are really the methods of choice, and such amputations as those by long anterior, posterior, or lateral flaps will only be justifiable

when the surgeon has to deal with a limb in which the soft parts are

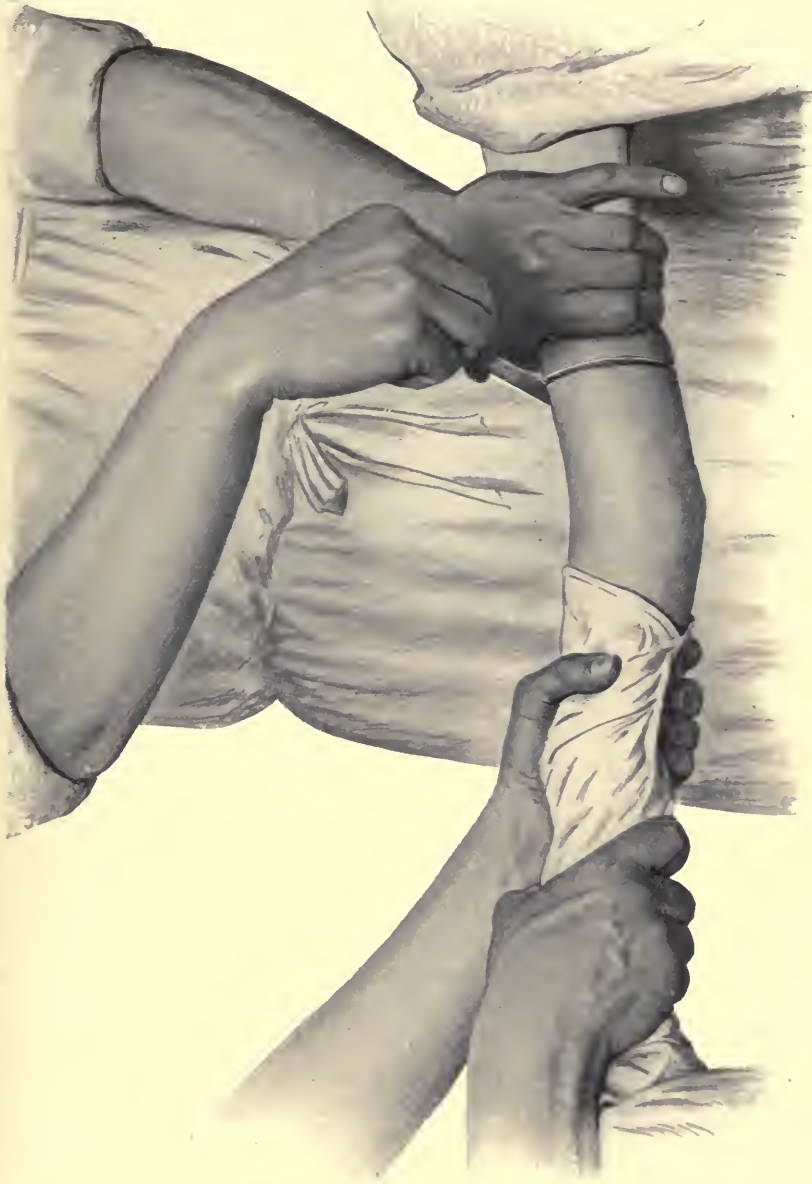

FIG. 49. THE CIRCULAR AMPUTATION. *Finishing the Incision.*

destroyed on one side whilst on the opposite side there are sufficient sound tissues to furnish a single large flap ; here, of course, it will be

more economical to amputate by a single large flap than to use equal flaps which must entail division of the bone on a higher level.

The circular amputation by the cuff method. This is the ordinary circular amputation slightly modified to meet local conditions, and is suited for amputation at or below the middle of the forearm.

Operation. The arm is abducted, the forearm is held horizontal by an assistant with its flexor surface upwards, a tourniquet is applied to the brachial artery, and the surgeon stands on the patient's right of the limb to be operated upon and determines the point at which he is going to divide the bones, at the same time estimating the antero-posterior

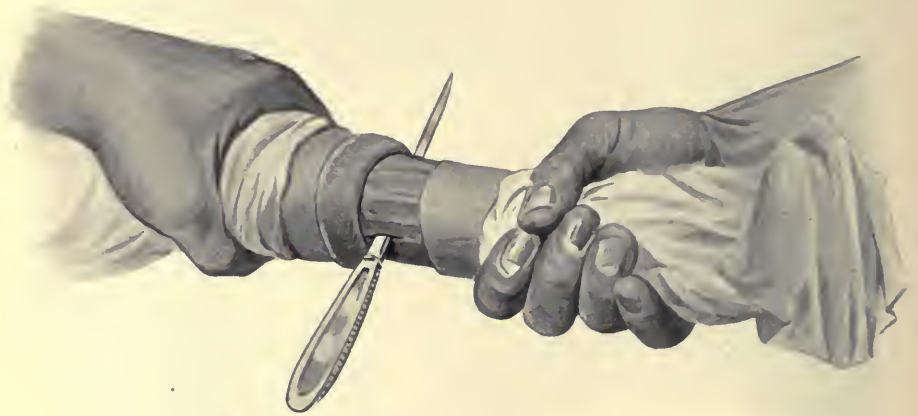

FIG. 50. THE CIRCULAR AMPUTATION BY THE CUFF METHOD. The knife is shown traversing the musculo-tendinous structures in the lower third of the forearm. The skin and subcutaneous tissues are turned back above as a regular cuff.

diameter of the forearm at that level. With a knife having a blade about six inches long, a circular sweep is made around the forearm at a distance below the proposed point of bone section rather more than half this diameter; the extra length is given in order to allow for the retraction of the skin when cut. The knife is grasped as shown in Fig. 48, and the surgeon passes his hand and forearm beneath the limb, reaching round as far on to the flexor surface as possible, and pulling up the skin forcibly with his left hand meanwhile. The knife is drawn transversely round the limb with a light sawing motion until the circle is completed, when the knife will be held as shown in Fig. 49. Should there be any difficulty in completing the circular incision in one single sweep, it is finished by drawing the knife in the reverse direction, from the end of the first incision to its beginning.

The incision should only go down through the deep fascia, and after it has been marked out it is gone over again carefully with the knife, so as to deepen it equally all round. The upper edge of the incision is now pinched up between the left thumb and forefinger, and the flap is raised from the muscles by a few touches of the knife held strictly at right angles to the surface and dividing the bands of cellular tissue connecting the skin with the deeper structures. The assistant pronates and supinates the forearm as the surgeon requires, and the skin is turned back in a regular cuff upon the forearm (see Fig. 50). This skin-cuff is raised until its lower margin is about an inch from the level of the proposed bone

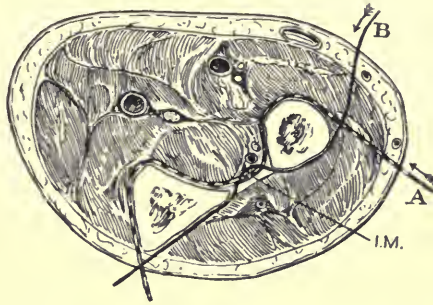


FIG. 51. A DIAGRAM ILLUSTRATING THE METHOD OF DIVIDING THE PERIOSTEUM AND INTEROSSEOUS MEMBRANE. (After Farabeuf.) The diagram shows the course of the point of the knife as it is drawn across the bones for the purpose of dividing the remaining fibres of muscles, periosteum, and interosseous membrane (I.M.) previous to sawing the bones. Its path crosses the anterior aspect of the limb as denoted by the dotted line A; across the posterior aspect it is shown by the heavy black one B. The arrow indicates the direction in which the knife is drawn.

section, when the forearm is fully supinated, and the surgeon proceeds to divide the muscles and tendons.

A narrow-bladed knife, half as long again as the transverse diameter of the limb, is insinuated flatwise between the bones of the forearm and the soft structures in front of them until its point emerges from the opposite side. In introducing the knife its edge is downwards towards the extremity of the limb, and care is taken to keep its point as closely in contact with the anterior surface of the bones as possible, so as to get it well beneath all the muscles and soft parts; it should pass close across the face of the interosseous membrane as it is carried across from one bone to the other. When the limb has thus been transfixed, the edge of the knife is turned upwards and, with a steady sawing cut, all the structures in front of it are cleanly divided on the same level. The knife is now introduced between the bones

and the muscles on the posterior surface, the assistant maintaining the forearm in the same position meanwhile, and all the structures on the posterior surface are divided in a similar manner by turning the edge of the knife downwards towards the floor. The interosseous membrane, the periosteum, and possibly a few remaining muscular fibres are then divided (see Fig. 51), and the soft structures are pushed up

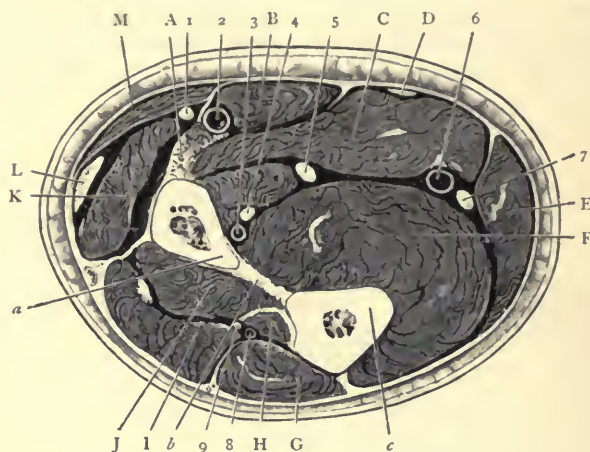


FIG. 52. SECTION ACROSS THE MIDDLE THIRD OF THE FOREARM (Cunningham's *Anatomy*). A, Pronator radii teres (insertion); B, Flexor carpi radialis; c, Flexor sublimis digitorum; D, Palmaris longus; E, Flexor carpi ulnaris; F, Flexor profundus digitorum; G, Extensor carpi ulnaris; H, Extensor longus pollicis; I, Extensor communis digitorum and Extensor minimi digiti; J, Extensor ossis metacarpi pollicis; K, Extensor carpi radialis brevis; L, Extensor carpi radialis longior; M, Brachio-radialis; a, Radius; b, Interosseous membrane; c, Ulna; 1, Radial nerve; 2, Radial artery; 3, Anterior interosseous artery; 4, Anterior interosseous nerve (underneath flexor longus pollicis); 5, Median nerve; 6, Ulnar artery; 7, Ulnar nerve; 8, Posterior interosseous artery; 9, Posterior interosseous nerve

with a rugine for about an inch. These should be retracted well above the point at which the bones are to be sawn, so as to allow this to be done easily. A three-tailed linen retractor (see p. 89) is employed to keep the soft tissues out of the way of the saw; the middle limb of the bandage is passed through the interosseous space and the lateral limbs are applied outside the bones. The saw is applied first to the ulna, which is the more fixed bone; when it has cut a groove in

that bone it is made to saw the radius, the division of which is completed before that of the ulna.

The radial, ulnar, and interosseous arteries will require ligaturing (see Fig. 52); any tendons that are unduly long should be seized with forceps and cut short with scissors. It is always well to dissect out and remove a short portion of the median nerve; the ulnar nerve may be treated similarly if it is seen. The skin-cuff is now drawn down and its anterior and posterior surfaces are approximated so as to give a transverse scar. Two deep sutures of stout silkworm-gut will keep them in apposition, and their edges should be united by a continuous silk or silkworm-gut suture. A small drainage tube is inserted at the ulnar end of the incision, and moderate compression in the antero-posterior direction should be applied to the flaps by means of the dressings in order to keep them firmly in apposition. The limb is put upon an internal rectangular splint in a position midway between pronation and supination; the forearm is carried in a large sling.

Amputation by equal antero-posterior flaps. This method is most suitable above the middle of the forearm. The preliminaries are the same as before. The antero-posterior diameter of the limb at the proposed point of bone section is estimated, and the length of each flap should be about an inch longer than half this measurement, so as to allow for the retraction of the skin.

Operation. The incision is U-shaped, not semilunar, and the terminations of the incision will lie over the external border of the radius on the one side and in front of the ulna on the other. The incision commences a little below the proposed point of bone section, as a vertical cut to form one of the limbs of the U, at the lower end of which the knife is drawn transversely across the front of the limb, slightly rounding the corners, and finally up the opposite side of the limb to a point opposite that from which it started (see Fig. 53). While the anterior incision is being traced out, the forearm is held horizontal and fully supinated, and the incision is deepened all round through the fascia so as to allow the skin to retract properly before the posterior flap is cut; to do this the elbow is flexed and the forearm held vertical by an assistant. The shape of the flap is similar to that of its fellow.

The operation may be finished by transfixing the muscles, or by dissecting up the skin flaps for about two inches, and then performing a circular division of the muscles down to the bone. The former method is preferable when the amputation is done in the upper third of the forearm, as the muscles are thereby enabled to retract sufficiently; when, however, the amputation is below this point, a circular division of muscles

answers equally well, as the muscles then retract sufficiently to enable the bones to be sawn at the desired spot.

In order to transfix the muscles the knife is thrust between them and the anterior aspect of the bone at the upper extremity of the incision, while the limb is held horizontal and fully supinated by an assistant. The knife, with its edge downwards, is held nearly horizontal as it

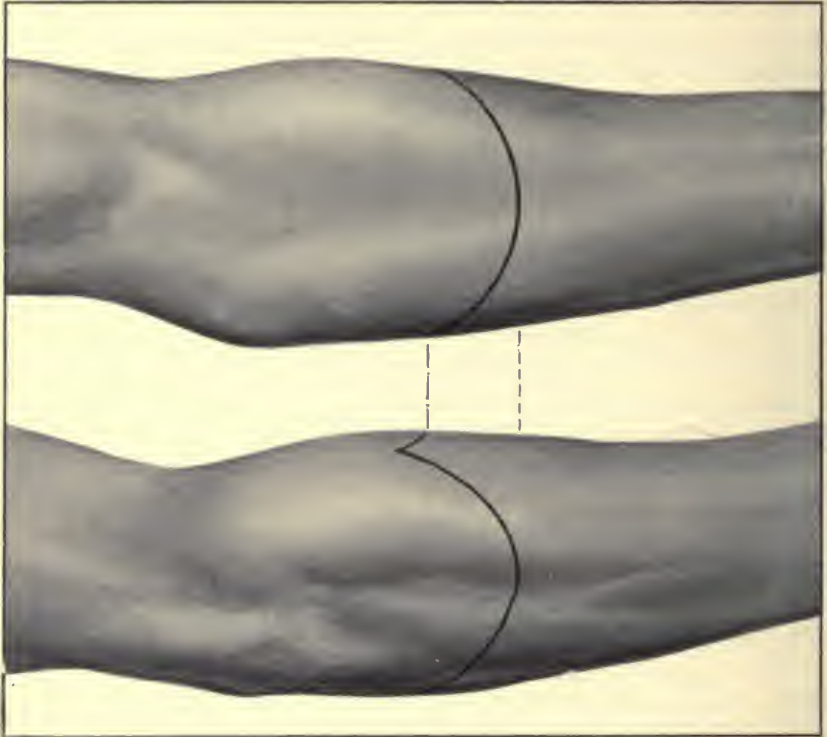


FIG. 53. AMPUTATION THROUGH THE FOREARM BY EQUAL ANTERO-POSTERIOR FLAPS. The level of bone section is nearly an inch above the angle of junction of the anterior with the posterior flap.

passes across the first bone; as it nears the interosseous membrane the handle is raised so that the point shall engage in this structure and divide it if possible. As the second bone is approached the handle is depressed, and the point coasts along the anterior surface of the bone between it and the muscles, when finally the handle is raised again and the point emerges from the opposite side. The muscles are now cut through somewhat obliquely downwards so as to form a muscular flap. The skin flap is pulled well up with the left hand as the knife cuts down-

wards and forwards, and an assistant puts the muscles on the stretch by extending the wrist ; the result is that the muscles are cut a good deal shorter than the skin and retract well out of the way, at the same time leaving sufficient covering for the ends of the bones. A similar procedure is carried out on the posterior surface of the limb, but is more difficult owing to the depth of the interosseous space. There still remain muscular fibres and portions of the interosseous membrane that have escaped division, and the complete clearance of the bones at the proposed line of section may be done on each side by a single sweep of the knife, as shown in Fig. 51. The soft parts are retracted, a three-tailed bandage retractor is applied, and the bones are sawn as in the previous operation. The subsequent steps are the same as in the previous operation.

When a circular division of muscle is practised, the skin flaps are raised to within an inch of the proposed level of bone section, when the muscles are divided by a series of circular sweeps down to the bone. This is the best method of amputating in the middle of the forearm, as the muscles are divided above the origin of the tendons, the presence of which interferes with the clean division of the soft parts on one level ; below this point the transfixion method already described for amputation in the lower third (see p. 127) should be adopted instead.

When the bones are divided above the insertion of the pronator (radii) teres in these operations, the action of the supinator (brevis) and the biceps is unbalanced, and therefore the upper end of the radius remains in a position of full supination. The after-treatment of the operation is similar to that for the previous case.

DISARTICULATION AT THE ELBOW-JOINT

This amputation is not practised as often as its merits deserve. Formerly it was rejected in favour of amputation through the upper arm, largely because of the fear of exfoliation of the cartilage, due to sepsis, which so often followed disarticulations, and which rendered the patient's convalescence long and dangerous. Nowadays, however, this risk need not be considered, and the superiority of the stump resulting from disarticulation over that following amputation through the upper arm is too great to admit of dispute. It is easy to cover the condyles of the humerus by suitable flaps, and the breadth thus given to the stump enables the artificial limb to be manipulated with much greater power and facility than it could be were it fitted to the round-ended stump resulting from amputation through the shaft of the bone.

Indications. Disarticulation should be performed, therefore, whenever

it is feasible, in preference to amputation through the upper arm. It is a useful procedure for sarcoma of one of the bones of the forearm necessitating complete removal of the bone affected, and it may be possible to make use of it in cases of injury, when the radius and ulna are crushed so high up as to render it impossible to save any portion of them with safety to the patient. It is not, however, a suitable operation for tuberculous disease of the elbow-joint.

Disarticulation by the circular method. The operation has been done by a number of methods of which the circular or the elliptical are the most economical, as far as the soft parts are concerned ; besides these methods, a single anterior or external flap, unequal flaps, or a modification of the racket incision have been used. The point of practical importance in doing the operation is that the condyles are somewhat difficult to cover, and it is well, therefore, to commence the incision some distance below the joint level, whatever flaps are to be employed ; two fingers' breadth on the inner side and three on the outer will ensure plenty of covering. The skin over the region of the outer condyle retracts much more freely than that over the inner, and hence the difference in the measurements on the two sides.

The circular amputation is most useful for cases in which the tissues are damaged so high up that it is impossible to save any portion of the radius or ulna ; it requires the least amount of sound soft parts of any operation in this region. It gives an excellent stump, the scar being transverse and drawn forwards upon the anterior surface of the humerus so that it is not exposed to pressure from the artificial limb. When only a single flap, usually cut either from the external or the anterior surface, is employed, its lower limit must reach almost as low as the middle of the forearm ; such an amputation, therefore, would only be employed very rarely in cases of injury, and will be used chiefly for cases of disease such as sarcoma of bones of the forearm, in which the surgeon has not to consider the amount of the soft parts at his disposal.

Operation. The upper extremity is held horizontal and at right angles to the trunk by an assistant, a tourniquet is applied above the middle of the upper arm, and the surgeon stands on the patient's right of the limb to be operated upon. He first ascertains the level of the elbow-joint, the best guide to this being the head of the radius ; the line of the joint is situated about a finger's breadth below the crease on the front of the elbow. A circular sweep is made around the limb, not exactly at right angles to the long axis of the forearm, but inclined so that it reaches a lower level on the flexor surface than on the extensor, and also lower on the radial than on the ulnar side (see Fig. 54). The incision will be about four fingers' breadth below the joint line in front and two

behind, whilst on the outer side it will be three fingers' breadth below the condyle, and two on the inner side ; this obliquity is to allow for differences in retraction of the skin. The incision goes through the deep fascia, which, with the skin, is raised to the level of the joint line by a few touches of the knife. The muscles arising from the inner condyle are divided as obliquely as possible, the soft parts are pushed up in

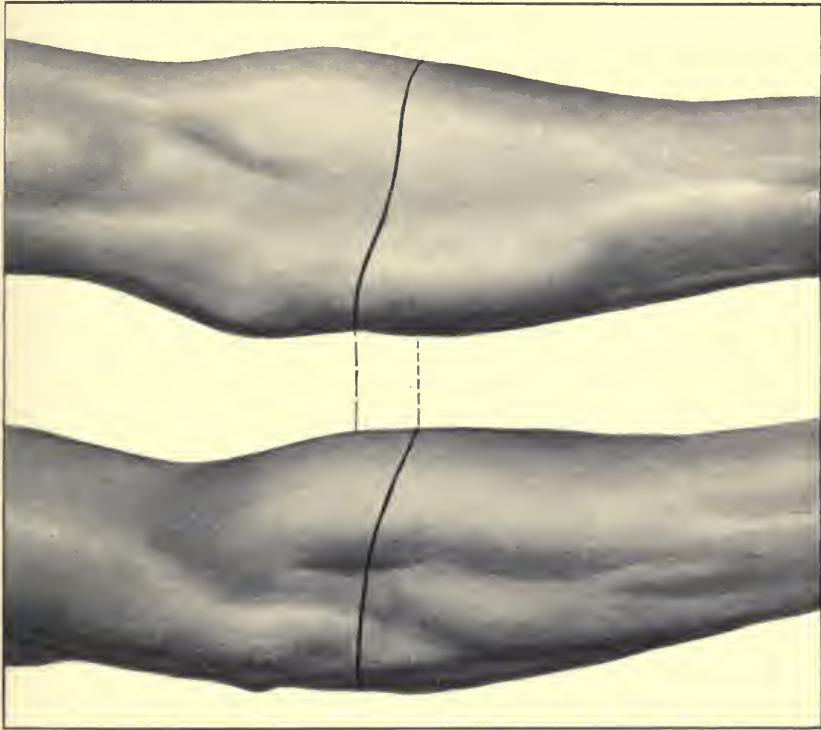


FIG. 54. DISARTICULATION AT THE ELBOW-JOINT BY A CIRCULAR INCISION. It will be noticed that the incision is not directly transverse, but inclined somewhat lower down on the outer side than on the inner ; this is to counterbalance the greater retractility of the soft parts in that situation.

front, the tendons of the biceps and the brachialis anticus are cut, and the anterior ligament of the elbow-joint is divided. The assistant now extends the elbow fully, and the surgeon opens the radio-humeral joint with a few touches of the point of his knife. The external lateral ligament and the muscles behind it are divided, and the knife is carried right up to the olecranon. By extending the elbow forcibly the coronoid process is made prominent, and the point of the knife can be swept around it and so through the internal lateral ligament and the ulnar nerve behind

it. This leaves nothing to divide but the tendon of the triceps, which is brought into view by pulling the forearm forcibly downwards and hyper-extending the elbow-joint, when it can be divided at its insertion into the olecranon and the disarticulation is complete.

It now only remains to tie the brachial artery and the various articular branches and to identify and remove portions of the median, ulnar, and musculo-spiral nerves. Fig. 55 shows the position of these structures. The flaps are sewn up so that the scar is transverse, and the retraction

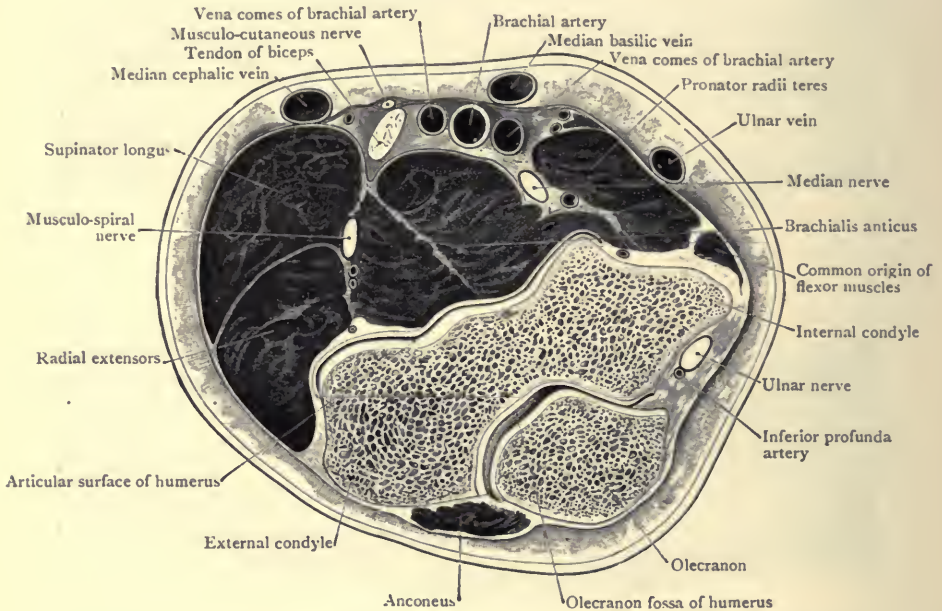


FIG. 55. TRANSVERSE SECTION THROUGH THE BEND OF THE ELBOW (Cunningham's *Anatomy*).

of the skin on the anterior surface brings this over the front of the condyles. A drainage tube is inserted at the inner angle of the wound and removed in two or three days. The arm is surrounded with a piece of Gooch's splinting and bound to the side.

Disarticulation by an elliptical incision. This is really equivalent to an amputation by a single long anterior flap, and it can only be employed advantageously when the tissues on the front of the forearm are undamaged, whilst those on the back are lacerated almost up to the elbow-joint. This condition of the soft parts, however, is occasionally met with in machinery accidents, and it is advisable, therefore, to describe

the method which gives a useful and slightly stump, and at the same time is fairly easy to perform.

The elliptical incision, marking out an anterior flap, has its highest limit behind, over the point of the olecranon, and its lowest in front, almost on a level with the centre of the forearm (see Fig. 56).

Operation. A tourniquet is applied to the upper arm, which is drawn away from the side, and the forearm is held by the surgeon, who stands

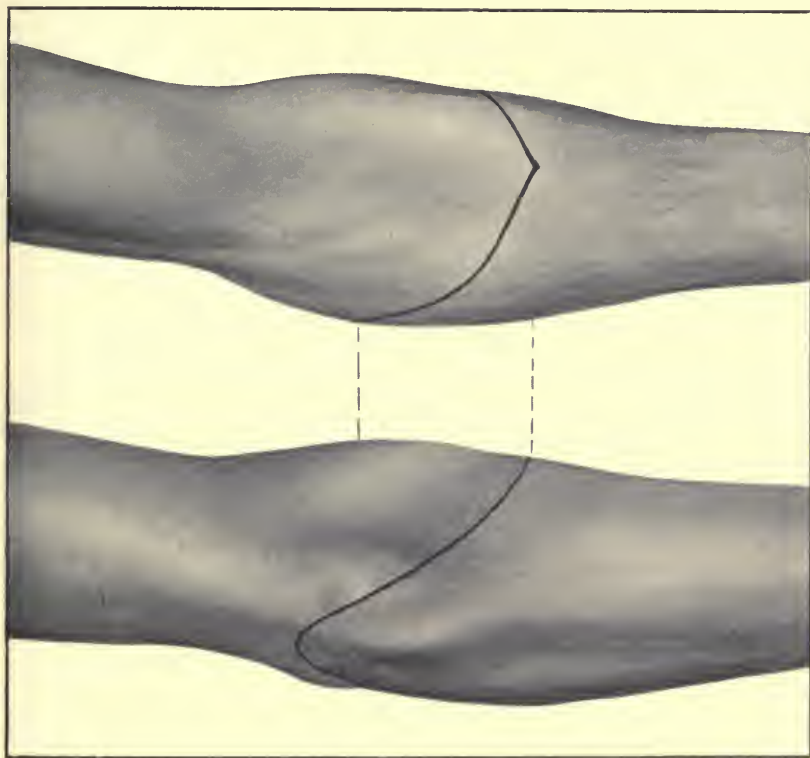


FIG. 56. DISARTICULATION AT THE ELBOW-JOINT BY AN ELLIPTICAL INCISION. The lowest point of the ellipse in front is slightly to the radial side of the middle line.

facing the elbow. The wrist is seized with the left hand so that the fingers grasp the flexor surface and the thumb is on the posterior or extensor surface. At the same time the elbow is flexed at an acute angle, and the arm is rotated so that the hand is turned over towards the surgeon's right and the tip of the olecranon is rendered accessible (see Fig. 57). At this spot the point of the amputating knife, which should be about four inches long, is sunk through the skin, and an incision is made

across the left-hand lateral aspect of the limb from behind forwards down to the lowest point of the ellipse, which is usually marked by the tip of the left little finger. As the incision proceeds from behind forwards the arm is supinated and extended so that the limb lies with its palmar surface uppermost when the knife is at the lowest point of the ellipse, which is rather to the radial side of the middle of the forearm.

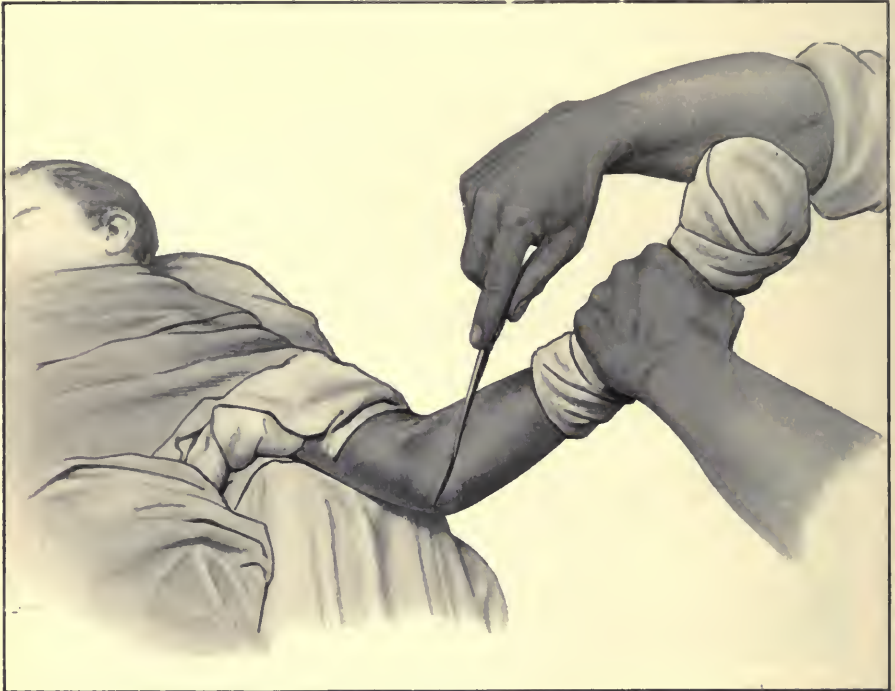

FIG. 57. COMMENCING THE ELLIPTICAL INCISION FOR DISARTICULATION AT THE ELBOW-JOINT. This shows the position of the patient's limb when commencing the incision. The limb is manipulated by the surgeon's left hand. If desired, the left little finger can be placed upon the lowest point of the ellipse on the front of the limb.

The knife changes its direction on reaching this point and is carried sharply upwards, whilst the elbow is again flexed and the forearm pronated and carried over to the surgeon's left, so as to expose the right-hand lateral surface of the forearm, and allow the knife to be carried up to the point from which it started (see Fig. 58).

The incision is now deepened through the fascia all round so that the skin may retract, and the soft parts on the front of the limb are divided by transfixion in the manner already described (see p. 130). The

skin should be retracted sufficiently to allow the knife to be passed across from one side of the joint to the other, and the muscles should be cut as short as possible. The wrist and fingers are hyper-extended while this is being done, in order to put the muscles fully on the stretch.

The anterior flap is now retracted and the front of the elbow-joint

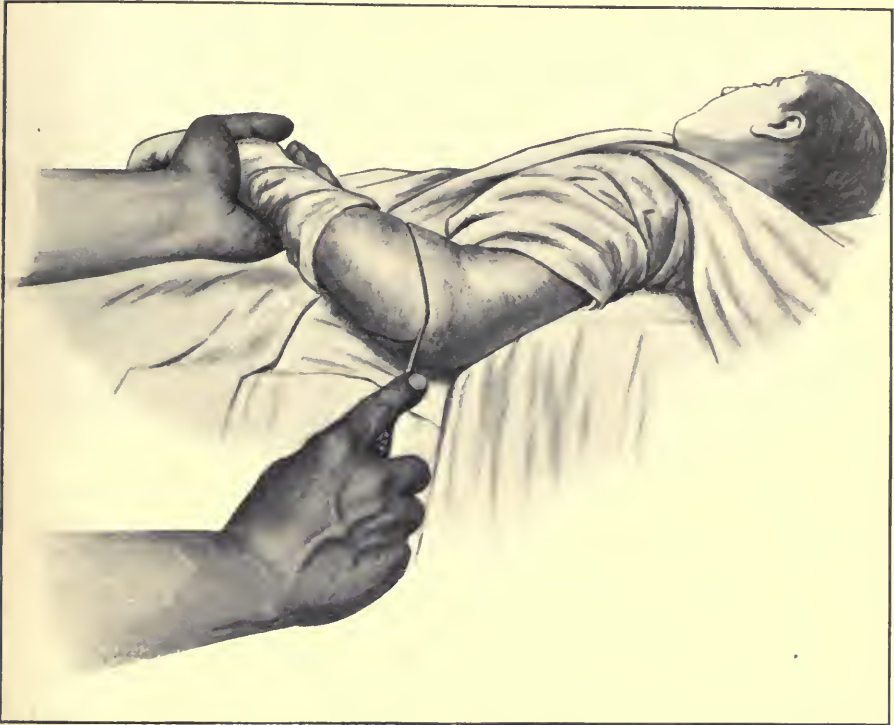

FIG. 58. METHOD OF TERMINATING THE ELLIPTICAL INCISION FOR DISARTICULATION AT THE ELBOW-JOINT. This shows how the limb is rotated across from the surgeon's right to his left by means of his left hand.

is exposed. It is easy to open the joint by a few touches with the point of the knife, to divide the lateral ligaments, and finally to complete the disarticulation just as in the circular amputation (see p. 133). All the subsequent steps are also similar to those of that amputation. The long anterior flap is brought round the end of the stump and the cicatrix falls over the posterior surface of the humeral condyles.

Among the other amputations that may be employed the most important is perhaps that done by a *single external flap*. The steps of the operation are very similar to those already described for the circular

and elliptical amputations, and Fig. 59 shows the incision employed. This amputation can only be called for very rarely, as it must be a rare accident that only leaves undamaged the particular area of soft parts

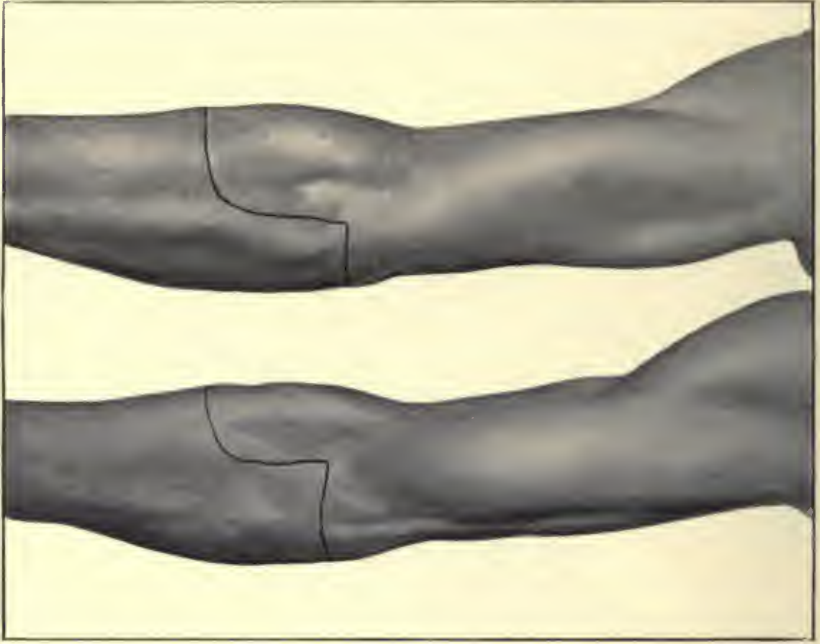


FIG. 59. DISARTICULATION AT THE ELBOW-JOINT BY A LARGE EXTERNAL FLAP.

required for the formation of this flap. The various other amputations that have been introduced offer no advantages over those already described and are not likely to be feasible when they are impossible; they will therefore not be described.

CHAPTER IV

AMPUTATIONS THROUGH THE UPPER ARM AND SHOULDER

AMPUTATIONS THROUGH THE UPPER ARM

WHEN amputating through the upper arm, the surgeon should remember the increased leverage and power imparted to the artificial limb by a long stump, and should therefore divide the bone as low down as the circumstances of the case will allow. The circular amputation, which enables the bone to be divided at the lowest possible point, is the amputation of choice, since the shape of the limb enables it to be done easily ; indeed, the middle of the upper arm is the spot for which it is typically suited. There is no objection to the cicatrix being terminal, as no direct pressure is borne on the end of the stump ; on the whole it is advisable to have the scar in this situation, as any pressure to which the stump is exposed falls upon its anterior and posterior margins, and not directly upon its end. Below the middle of the arm the soft parts retract nearly equally on the two surfaces of the limb, the retraction being slightly greater on the anterior surface owing to the pull of the biceps, but this is of little importance. Above the middle of the arm, however, the retraction of the soft parts is unequal on the two sides, and it is therefore easier to amputate by means of flaps or by some modification of the racket method.

A point of considerable practical importance is the ease with which large nerves may be caught in the scar and give rise to a painful stump ; therefore, their ends must always be dissected out in the later stages of the operation and a portion removed.

In amputations through the arm below its centre the brachial artery may be compressed by a tourniquet placed around the upper part of the limb, but when the amputation is done above the mid-point there is no room for a tourniquet which will control the circulation and at the same time allow of sufficient retraction of the soft parts. It is possible to use an Esmarch bandage even as high up as the middle of the axilla if Wyeth's pins (see p. 80) or some similar means are used to prevent it from slipping. If the pins are used, they should be thrust through the deltoid above and the posterior fold of the axilla below. Unless they are used, however, the artery must either be controlled by compression above the clavicle, or it must be isolated and tied before it is divided. The

latter course will probably be preferred by the majority of surgeons, as compression of the artery above the clavicle is always uncertain and demands a most trustworthy assistant. In all amputations in the upper



FIG. 60. THE CIRCULAR AMPUTATION. Commencing the Incision.

arm the limb is held horizontal and at right angles to the trunk. The surgeon stands on the patient's right of the limb to be operated upon and pulls up the skin and manages the flaps with his left hand.

Three amputations will be described : (i) The circular amputation,

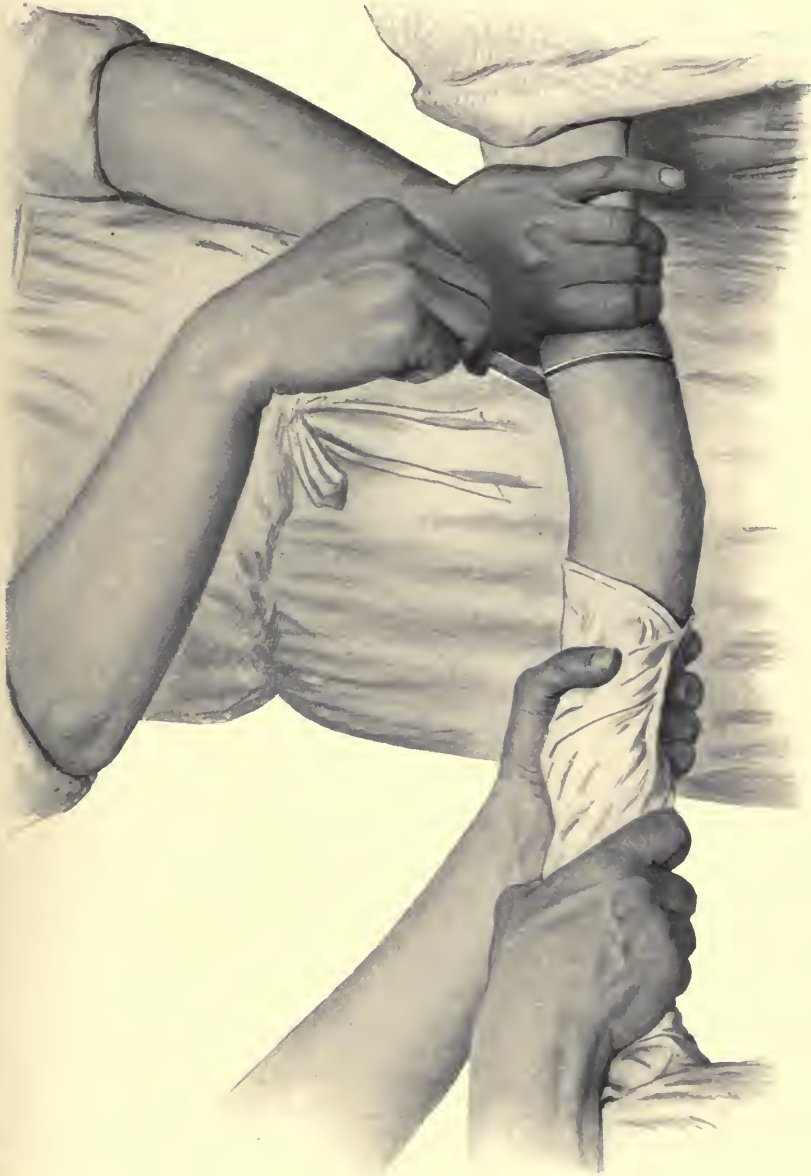

FIG. 61. THE CIRCULAR AMPUTATION. *Finishing the Incision.*

which is most suitable for the lower half of the arm ; (ii) The amputation by antero-posterior flaps, which is best adapted for amputations just above

the middle; and (iii) Amputation by a large external or deltoid flap, which is most suited for an amputation in which the bone is divided high up in the region of the surgical neck.

Circular amputation. The surgeon settles the point at which he is going to divide the bone, and then makes a circular incision through the skin at a distance below this point equal to nearly two-thirds of the antero-posterior diameter of the limb at the point of bone section. Before making his incision he grasps the limb with his left hand above the point at which he is going to divide the skin and pulls the latter forcibly upwards. The hand, holding the knife as shown in Fig. 60, is passed beneath the arm and commences the incision on the side of the limb opposite the operator and as far round it as possible. The knife is drawn round transversely to the long axis of the limb with a gentle sawing movement from heel to point, dividing the skin and deep fascia only (see Fig. 61); the entire circular incision may be completed in one sweep, but, if preferred, the direction of the knife is reversed after it has traced out about two-thirds of the incision, and is made to cut from the termination to the commencement of the first incision. The knife should pass very lightly over the inner aspect of the arm so as to avoid wounding the brachial artery, which lies immediately beneath the deep fascia.

When the circular incision has been deepened equally throughout down to the deep fascia, the skin is pulled up as firmly as possible by the left hand and the knife is drawn round the limb again on a level with the lower edge of the retracted skin, so as to divide the bands of cellular tissue uniting the skin to the deep fascia and to allow the former to be still further retracted by the grasp of the surgeon's left hand. This procedure is repeated two or three times until the skin has retracted for a good two fingers' breadth all round; the anatomical conformation of the parts allows this to be done without the necessity of turning up a cuff. Care is needed each time to avoid wounding the brachial artery.

The muscles, and with them the brachial artery (which is of course controlled by the tourniquet previously applied high up the arm), are now divided. This is usually effected by three circular sweeps of the knife round the limb as for division of the skin, each sweep going completely round and dividing about one-third of the thickness of the muscles. Each successive sweep is made on a level with the retracted edge of the muscles cut by the preceding one. Between each circular sweep the muscles are retracted either by an assistant or by the surgeon's left hand; the last incision goes down to the bone and divides the periosteum about an inch and a half below the point at which it is proposed to saw the bone. In this way a conical cavity is formed in the stump, at the apex of which lies the bone (see Fig. 62). The periosteum and the muscles

are pushed up with a rugine for an inch and a half, when the point is reached at which the bone is to be divided. The soft parts are retracted by means of a double-tailed retractor (see p. 88), and the saw is applied in the usual manner, the limb being held quite horizontal meanwhile.

The brachial artery and any of its branches that are visible on the face of the stump are ligatured before the tourniquet is taken off, and the median, ulnar, and musculo-spiral nerves are identified, and an inch or so of each is removed. The stump is sutured by approximating the edges antero-posteriorly so as to make the scar transverse; a drainage tube is inserted at its outer angle and is removed in two or three days.

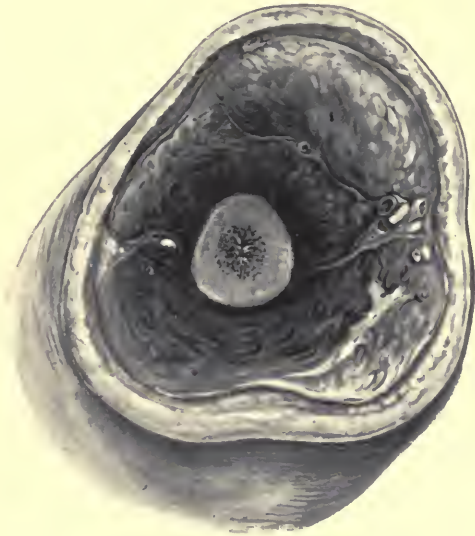


FIG. 62. APPEARANCE OF THE LIMB AFTER A CIRCULAR AMPUTATION. The figure shows the conicity of the stump, the skin projecting beyond the muscles and the cut edge of the bone forming the apex of the cone.

The limb is put up on a moulded splint of gutta-percha or Gooch's splinting, and fastened to the side.

Amputation by antero-posterior flaps. The flaps should be almost equal in length, the anterior being a trifle longer than the posterior, so as to allow for the greater retraction of the soft parts over the region of the biceps. The surgeon's position is the same as before, and, after determining the point at which he desires to divide the bone, he marks out a U-shaped flap half the length of the antero-posterior diameter of the limb at the point of bone section, beginning nearly an inch below that point (see Fig. 63); the anterior flap is cut first. It is of great importance that only the skin and fascia should be divided in this

first incision, and the brachial artery preserved from injury, unless a tourniquet has been placed around the arm; when the amputation is above the middle of the limb, it is probable that no tourniquet will be used (see p. 139). The incision is deepened through the fascia so that the skin can retract equally all round, and a posterior flap almost as long

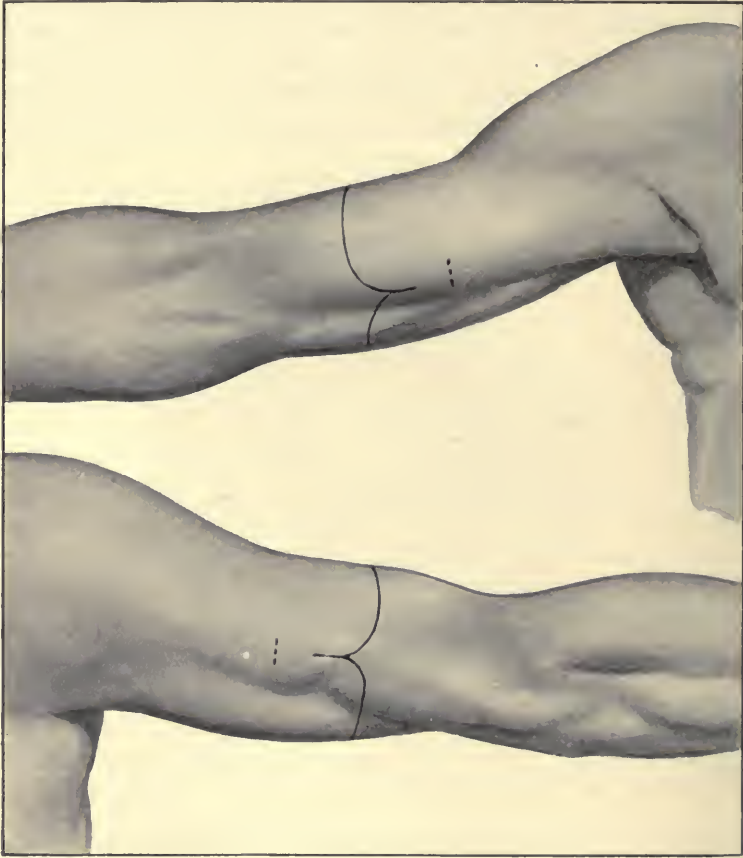


FIG. 63. AMPUTATION THROUGH THE ARM BY EQUAL ANTERO-POSTERIOR FLAPS. The dotted line marks the point of bone section, which is nearly an inch above the angle of junction of the flaps.

as the anterior is marked out by passing the arm beneath the limb and drawing the knife transversely across the back of the limb, with a slight rounding-off of the edges on each side; it is not necessary to raise the limb in doing this.

The next point is to secure the brachial artery, if the amputation is being done without a tourniquet. The deep fascia is incised freely over the inner edge of the biceps, and the artery, the pulsations of which

are easily felt, is secured in Spencer Wells's forceps, after which it may be divided; the venæ comites are treated similarly. The muscles are now divided either by a circular sweep or perhaps better by transfixion, taking care to cut them as short as possible, so as not to leave too large a mass in the stump. The method of performing transfixion has already been described (see p. 130).

The periosteum and any remaining soft parts are divided by a circular sweep down to the bone, and are pushed back with a rugine until the level of the bone section is reached, when the saw is applied and the bone divided. The arteries are secured, and portions of the musculo-spiral (radial), median, and ulnar nerves are resected; a drainage tube is inserted in the outer angle of the wound, the limb being put up as in the preceding operation.

There are several other methods for amputating in the arm, and some of them may be useful occasionally according to the necessities of the particular case; for instance, amputations by equal lateral flaps, by a single long anterior flap, and others; but they do not require detailed description here.

Amputation by a large external flap. Amputation is not very often done in the upper third of the arm, as the surgeon usually has no alternative but to disarticulate at the shoulder-joint. Owing to the insertion of the muscles into the upper end of the humerus, a mobile stump is left even after the humerus has been sawn below the surgical neck, and this is of importance to the patient, as it renders his artificial limb much more useful. Therefore disarticulation should not be practised if the head and surgical neck of the bone can be saved.

Operation. The best result is given by a large external flap, which should be equal in length to rather more than the lateral diameter of the limb at the point of bone section, viz. the level of the surgical neck of the bone. The incision commences a good two fingers' breadth below the seat of bone section and is of the usual U-shape. The surgeon stands on the outer side of the limb and must take care that the flap is equal in width to half the circumference of the arm at the point of bone section. No tourniquet is applied, and the inner incision, which joins the upper ends of that marking out the large external flap almost transversely across the inner side of the arm, must be made carefully in order to avoid damage to the vessels which lie just beneath the fascia. After the skin has been allowed to retract, the deltoid is picked up between the left thumb and forefinger, and is cut obliquely from without inwards and from below upwards until the level of the bone section is reached. The next step is to expose, secure, and divide the axillary vessels, in order to reach which comfortably the attachments of the pectoralis major

and the coraco-brachialis are picked up and either cut with a knife or stripped up from their insertion with a rugine. The nerves must also be divided, and this should be done as high up as possible. Finally the remaining structures, including the triceps, are divided by a clean sweep down to the bone, which is then sawn in the usual manner.

In order to increase the mobility of the stump, an attempt may be made to fasten the cut ends of the pectoralis major, coraco-brachialis, and latissimus dorsi to the portion of bone remaining.

Owing to the shortness of the stump it cannot be bound to the side, and movement will have to be restrained by the application of a moulded shoulder cap outside the dressings.

DISARTICULATION AT THE SHOULDER-JOINT

Indications. This type of operation is frequently called for both in civil and military practice. The limb may be torn off partially or entirely by machinery accidents, and in military practice the limb is often shattered right up to the shoulder-joint. In military practice, however, the operation is less common than formerly, owing to the facility with which conservative surgery can be practised. The same type of operation may be required for a malignant growth of the humerus; in these cases it will be possible to choose the most convenient and economical method of amputation, whereas in traumatic cases the condition of the soft parts at the disposal of the surgeon must largely influence his choice of method.

After this operation there is, strictly speaking, no stump left, and the attachment of the artificial limb is not always easy. The projection of the acromion, however, gives some sort of support, and it and the coracoid process should always be left intact if possible. The position of the scar is not of great consequence, but it is important that the large nerves should be cut as short as possible, as a painful scar from their implication in the cicatrix is not at all uncommon in this situation. Perhaps the amputations that give a vertical cicatrix are the best, as drainage is thereby facilitated.

The most important question in these amputations is the prevention of hæmorrhage, and, on the whole, it is best not to trust to compression of the vessels, but to expose the axillary artery and vein at an early stage in the operation, and secure and divide them before proceeding further with the operation. Compression of the subclavian by the fingers of an assistant is an uncertain method at best, and may be impracticable owing to the circumstances under which the surgeon has to work; a temporary ligature or a Crile's clamp (see Fig. 140) would be preferable.

A great number of methods of disarticulation have been practised, and Farabeuf in his *Manuel Opératoire* figures upwards of thirty. The vast majority of these, however, vary only in trifling and unimportant details and need not be considered; it will only be necessary to describe here two that are in common use, each of which is suited to a particular type of case. They are (i) Spence's amputation, and (ii) The modified racket operation. Spence's amputation (see Figs. 64-6) is best suited for cases in which the surgeon is at liberty to choose the method that pleases him best, and can obtain enough soft parts wherefrom to fashion his flaps; the modified racket method (see Fig. 67) is eminently suited for cases in which the surgeon desires to explore the parts and is uncertain whether he will eventually resect the joint or disarticulate. In special cases the surgeon will make use of whatever soft parts may be available for the fashioning of irregularly shaped flaps to cover the stump. This is particularly the case in machinery accidents where any tags or flaps of skin that are uninjured may have to be pressed into the service to cover in the stump, or flaps may even have to be reflected from the thorax for the purpose.

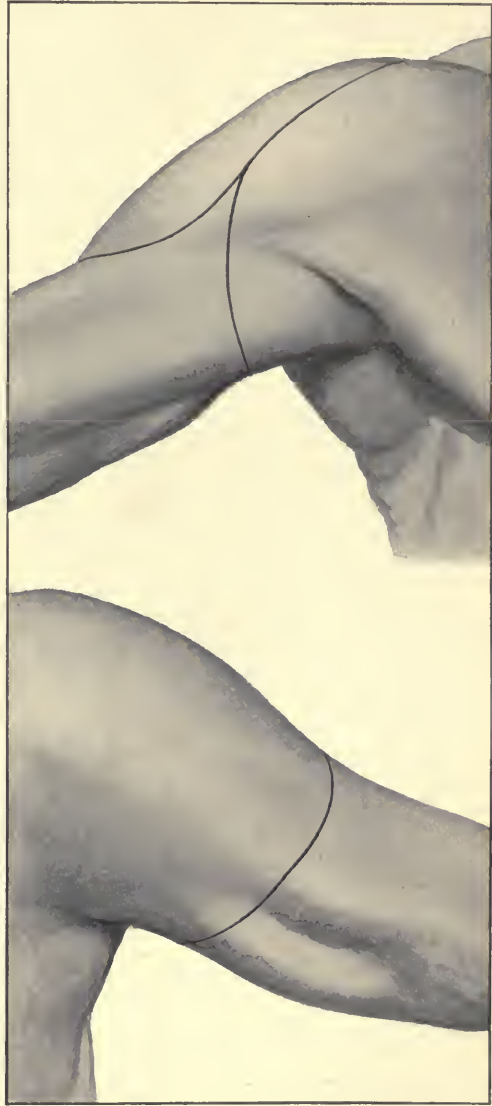


FIG. 64. INCISION FOR SPENCE'S DISARTICULATION AT THE SHOULDER-JOINT. The whole of this incision, except the inner limb seen in the upper figure, goes down to the bone.

Spence's amputation. Prof. Spence's own account of this operation will be found in his *Lectures on Surgery*, vol. ii, p. 662. It is done as follows:—

The arm is slightly abducted and rotated outwards. The surgeon stands on the outer side of the limb, in the case of the right arm facing the patient's feet, in the case of the left facing his head. The patient

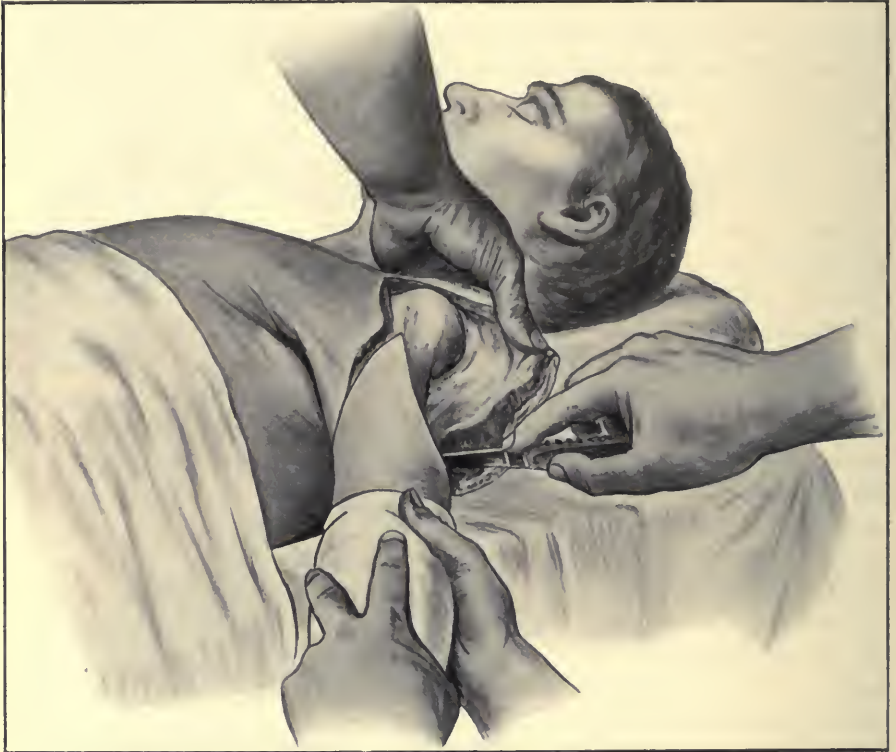

FIG. 65. RAISING THE OUTER FLAP IN SPENCE'S AMPUTATION. The deltoid is pulled away from the head of the bone with the left hand and is cut below obliquely from within outwards.

is brought to the extreme edge of the table. The incision is made with a broad, strong bistoury from a point just external to the coracoid process down through the clavicular fibres of the deltoid and pectoralis major, the humeral attachment of which is divided. The incision is now curved outwards and backwards as far as the posterior border of the axilla. Up to this point the knife is carried directly down to the bone. The incision is continued across the inner aspect of the arm through the skin and fat only to meet the original incision in a gentle curve (see Fig. 64).

The fingers of the left hand are now inserted into the incision and pushed down beneath the fibres of the deltoid, which are hooked up, pulled forcibly away from the capsule of the joint, and any remaining fibres divided obliquely from within outwards (see Fig. 65). With them comes the trunk of the posterior circumflex (humeral) artery, which is thus preserved uninjured.

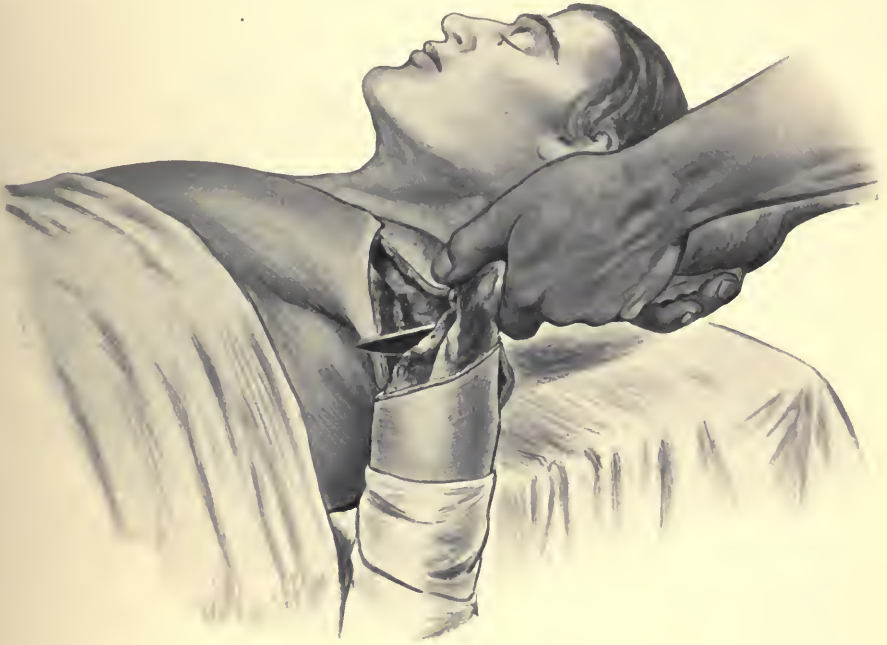


FIG. 66. DISARTICULATING IN SPENCE'S AMPUTATION. The surgeon takes the head of the bone in his left hand, and, allowing the limb to hang vertically down, cuts downwards and inwards, following the inner limb of the incision, and so removes the arm. The ligatured ends of the large vessels can be seen on either side of the knife.

The next step is to open the joint, which is done by cutting directly upon the tuberosities, and dividing the tendons inserted into them. With the point of the knife the remainder of the capsule and the broad tendon of the subscapularis are then divided, and the head of the bone falls away from the glenoid cavity. The surgeon then has the arm allowed to hang vertically, seizes the head of the bone in his left hand, and, introducing his knife across the joint, severs the remaining soft structures with a long sawing cut from within outwards (see Fig. 66). The large outer or deltoid flap is held out of the way by an assistant, and in

making the division of the soft parts the surgeon follows carefully the lower edge of the flap on the inner side.

Spence had the bleeding controlled by an assistant, who slipped both thumbs into the wound behind the knife as it divided the structures on the inner side, and compressed the vessels in the inner flap between them and his fingers outside the flap. It is needless to say that this is a dangerous method ; a far better plan is to deepen the incision carefully over the vessels as soon as the flaps have been marked out, and

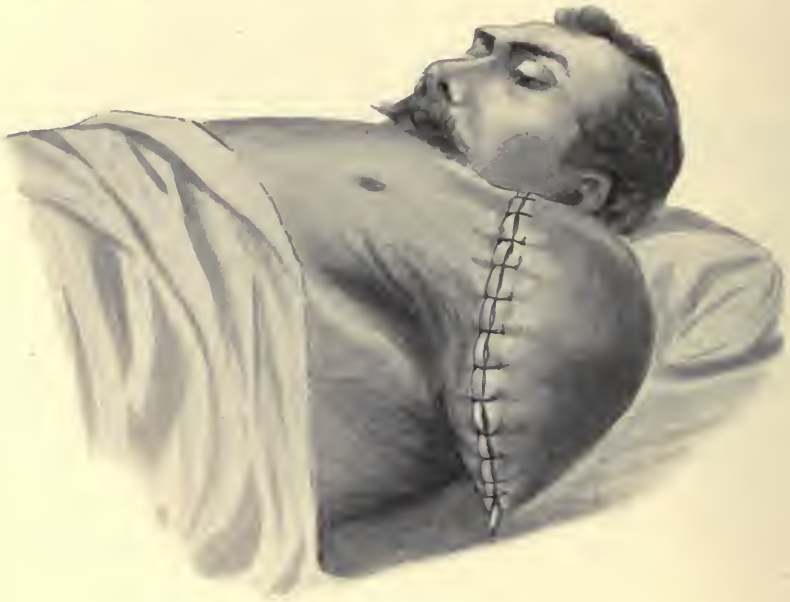

FIG. 67. STUMP OF SPENCE'S DISARTICULATION AT THE SHOULDER-JOINT.

secure and divide artery and veins between double ligatures. When finishing the operation, the knife should be carried through the gap between these divided ends.

The modified racket method. The thorax is well raised and the affected side drawn over the edge of the table. The surgeon stands on the outer side, facing the head when the amputation is on the right side, and facing the feet when it is on the left. As in the case of Spence's amputation (see p. 148), the artery may be controlled by compression above the clavicle, by direct compression in the flap by an assistant's fingers as the vessel is divided, or, preferably, by deepening the incision over the vessel and securing it before the operation is completed.

The point of the knife is entered just below and in front of the point of the acromion, and a vertical incision about four or five inches in length

is made down to the bone over the outer aspect of the arm. This exposes the head and neck of the humerus and opens the joint, and the surgeon is thereby able to gauge the extent of the mischief and to determine whether he will amputate or excise. Should he decide upon the former course, he enters his knife in the vertical incision at about its mid-point, and makes it pass obliquely downwards and inwards over the front and inner aspects of the arm until it is on the level of the insertion of the deltoid; it is then drawn transversely across the back of the limb and up over its outer side until it reaches a point in the vertical incision opposite to that at which it commences to diverge on the inner side (see Fig. 68). This incision should go through the skin and fascia everywhere, but care must be taken to avoid the axillary vessels as it crosses the inner side.

The muscles are divided in the following order:—The anterior fibres of the deltoid are seen in front, and these are raised and separated from the tendon of the pectoralis major; the latter is carefully divided at its insertion into the bicipital groove, the vessels beneath it being protected from injury meanwhile. The coraco-brachialis is then similarly isolated and divided. The inner or anterior flap is now retracted inwards, and the vessels are exposed lying upon the triceps, and surrounded by the cords of the brachial plexus which are isolated and divided as high up as possible; this exposes the axillary artery and vein, which are secured and divided just below the origin of the circumflex, and their ends retracted out of the way. The deltoid is divided down to the bone in

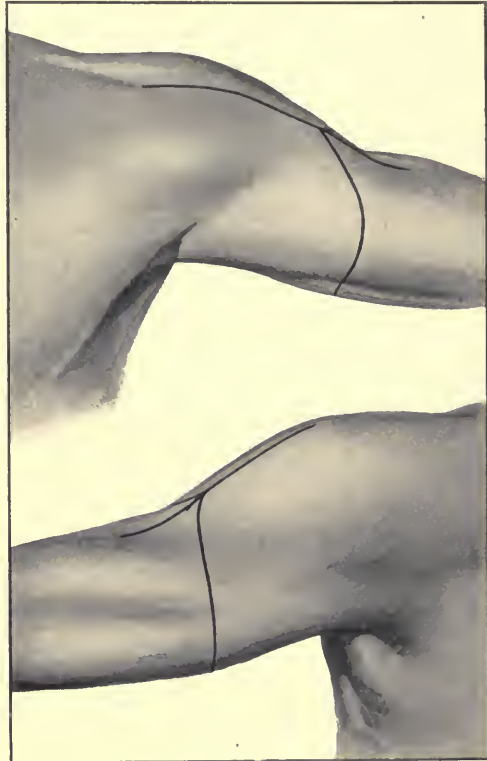

FIG. 68. DISARTICULATION AT THE SHOULDER BY THE MODIFIED RACKET METHOD. The prolongation of the vertical incision beyond the racket is only employed when a preliminary examination is desired.

the outer part of the wound on a level with the edge of the retracted skin, and the fingers are sunk in between its under surface and the head of the bone, and the posterior flap is pulled well away from the latter structure. The joint is now opened by dividing the muscles inserted into the great tuberosity in a direction transverse to the long axis to the limb, which is meanwhile brought down to the side of the trunk by the assistant. When they have been divided the joint is opened and the bone is rotated so that the remains of the capsule and the tendon of the subscapularis inserted into the lesser tuberosity, together with that of the biceps, may be divided in turn. The limb is now allowed to hang almost vertically, the elbow being inclined a little inwards beneath the table so as to thrust the head of the bone upwards and outwards from the cavity of the joint. The surgeon takes the head of the bone in his left hand and passes his knife between it and the glenoid cavity, so that it is easy to divide the remaining portions of the capsule; the head of the bone comes well away from the glenoid cavity, and the operation is completed by dividing the soft parts on the posterior aspect of the flap from within outwards, the knife cutting its way out on the level of the edge of the retracted skin. A good-sized drainage tube is inserted in the lower end of the wound and is kept in for three days. No splint is needed. The resulting scar is vertical.

CHAPTER V

INTERSCAPULO-THORACIC AMPUTATION

(REMOVAL OF THE UPPER EXTREMITY TOGETHER WITH THE SCAPULA AND A PORTION OF THE CLAVICLE)

THIS amputation, which is also known as the 'fore-quarter' amputation, removes not only the upper extremity, but also the shoulder and the contents of the axilla. It was introduced by Berger and often goes by his name.

Indications. (i) Extensive crushes in the region of the shoulder, such as machinery accidents, in which the upper extremity must be sacrificed and it is impossible to get a proper covering of soft parts without removing the scapula also. At the same time, every effort must be made to save the scapula if this can be done by means of plastic surgery. The patient is at a great disadvantage without it.

(ii) For sarcoma of the axilla or of the humerus which is too large or too widely infiltrating to be removed by any less severe procedure.

(iii) Occasionally it may be done for gangrene or spreading cellulitis affecting the shoulder-joint and the contents of the axilla.

It has been advocated for extensive recurrence following the usual operation for carcinoma of the breast, but it need not be discussed in this connexion, as disease that has recurred widely enough to render such an extensive operation necessary could hardly be dealt with satisfactorily by surgical measures.

The results of the amputation are excellent, and the risks appear to be little greater than those of disarticulation at the shoulder-joint. If the steps of the operation described below are carefully followed, the bleeding is only slight, and the shock is not greater than after amputation at the shoulder-joint.

Operation. Since a tourniquet cannot be applied, it is necessary to ligature the subclavian artery as a preliminary measure in order to control the bleeding, and this is perhaps the most difficult part of the operation. The affected shoulder is drawn well beyond the edge of the table and somewhat raised, while the arm is at the side and the head turned slightly to the opposite shoulder. An incision is made down to the bone along the upper surface of the clavicle from the sternal to

the acromial end, the soft parts dissected off, and the bone divided. Care must be taken to avoid damage to the subclavian while clearing the clavicle, and the rugine must be kept very close to the bone while stripping off the subclavius muscle. A simple and efficient means of dividing the clavicle is by Gigli's wire saw (see p. 90), which can be passed round the bone without any risk of damage and divides it rapidly. A very convenient plan is to divide the bone first at the junction of the outer with the middle third; the inner portion of the clavicle is then seized

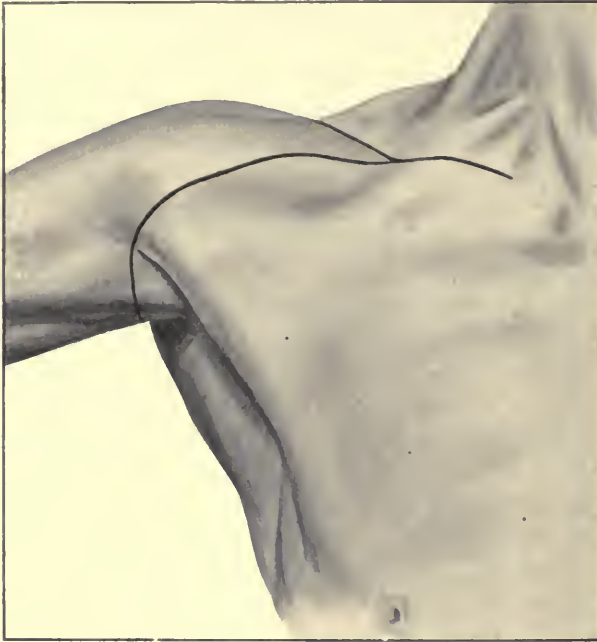

FIG. 69. THE ANTERIOR INCISION FOR THE INTERSCAPULO-THORACIC AMPUTATION.

in strong forceps and pulled upwards, the soft parts are carefully pressed away from beneath it, and two or three inches of it are removed.

After the subclavius muscle and its fascia have been divided, a little careful dissection will render evident the subclavian artery and its vein; each vessel is ligatured and then clamped about an inch below the ligature and divided between the two with scissors. It is a good plan also, as recommended by Kocher, to isolate and tie the ascending cervical, the superficial cervical, and the suprascapular (transverse scapular) arteries which arise from the subclavian artery and pass upwards or outwards in front of the scalenus muscle. The transverse cervical (transversalis

colli) artery, which runs outwards and backwards to the vertical border of the scapula, may also be identified and secured, and if this be done the remaining steps of the operation will be almost bloodless. The brachial plexus is divided at the same time, and the divided lower ends are pushed down out of the way. It is an excellent plan to inject a few minims of a 4% solution of B-eucaine into the sheath of each cord some minutes previous to division, which should be effected with a very sharp

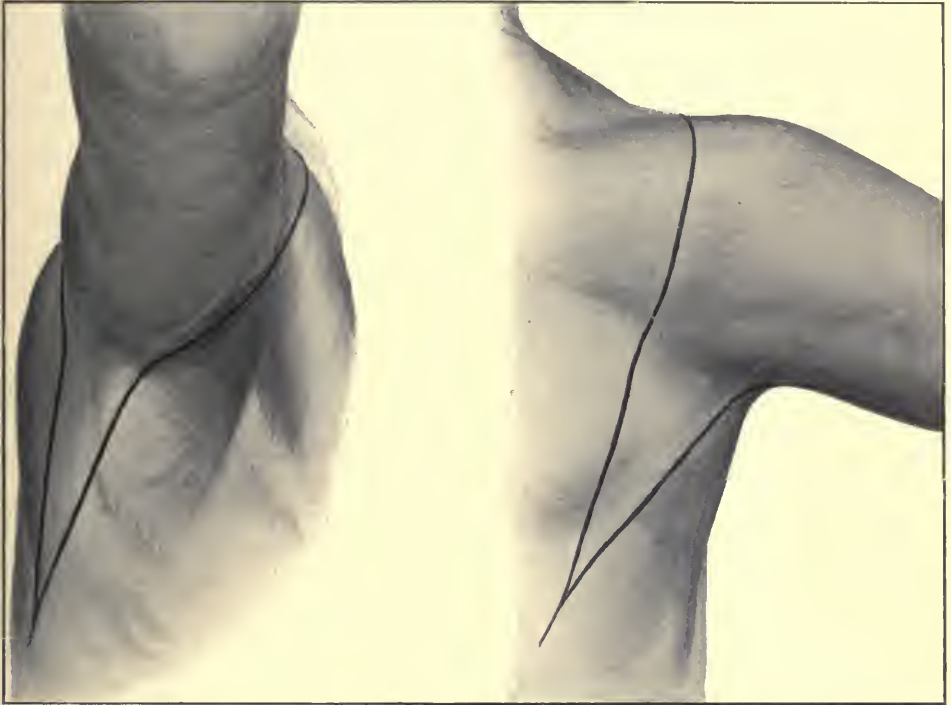


FIG. 70. THE POSTERIOR INCISION FOR THE INTERSCAPULO-THORACIC AMPUTATION. The left-hand figure shows how the anterior portion of the incision crosses the axilla.

knife and not with scissors, as there should be no crushing of the nerve elements. The artery should be tied before the vein, and, if it be desired to save as much blood as possible, the limb should be elevated for a few minutes after ligature of the artery and before the vein is secured.

The surgeon next proceeds to mark out his flaps. For this purpose he stands facing the patient and has the arm drawn well away from the side by his assistant. From about the centre of the incision along the clavicle the knife marks out a flap with its convexity towards the point of the shoulder, passing well on to the deltoid outside the tip of the

coracoid process, and curving down across the junction of the anterior fold of the axilla with the arm, transversely across the inner aspect of the arm to its junction with the posterior fold of the axilla (see Fig. 69). At this point the assistant raises the limb almost vertically and pulls it forcibly upwards, so as to expose the back of the thorax, and the knife is carried downwards and inwards to the inferior angle of the scapula.

The knife throughout should only go through the skin and deep fascia.

The pectoralis major is now divided in the line of the incision, and the fascia covering in the axilla is opened up, when the arm falls well away from the side and the axilla can be examined, and all its contents, consisting of glands, vessels, and nerves, can be stripped down out of the way. The incision is next deepened round to the back, and the latissimus dorsi is divided. This completes the formation of the anterior flap.

The assistant now draws the limb forcibly across the trunk to the opposite side, so as to roll the patient over somewhat on to the sound side and expose the back. The surgeon stands to the outer side of the limb and prolongs the clavicular incision from the tip of the acromion over the shoulder and almost vertically down to meet the end of the first incision at the inferior angle of the scapula (see Fig. 70). This incision, like the first, only goes through the skin and deep fascia, after which the

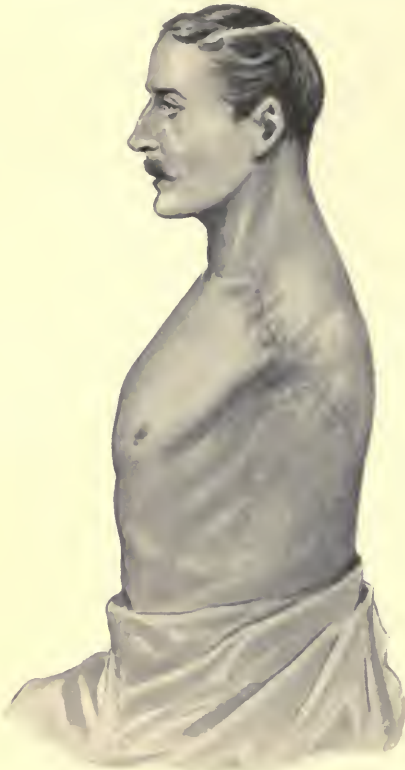

FIG. 71. THE CICATRIX LEFT AFTER AN INTERSCAPULO-THORACIC AMPUTATION. As a rule the flaps meet accurately and a neat cicatrix results.

trapezius is divided throughout its whole length, and the surgeon, dissecting up the inner lip of the posterior flap, exposes the vertical border of the scapula and divides the muscles attached to it, which are the last structures to maintain the connexion of the upper extremity to the chest. The fingers are hooked beneath the omo-hyoid, the levator scapulæ, the rhomboids, and the serratus magnus (serratus anterior) in

turn, and these muscles are divided as close to the border of the bone as possible. If the precaution mentioned above of securing the cervical branches of the subclavian be followed, little or no bleeding will accompany this step, otherwise there is generally free bleeding, which, however, is easily controlled by taking up each vessel as it is divided, and by practising the division of the muscles in successive stages.

After removal of the upper extremity entire in this way, the flaps come well together, and the scar runs obliquely downwards, outwards, and backwards (see Fig. 71). A drainage tube is placed in the lower angle of the wound, and the dressings are firmly bandaged on so as to obliterate all cavities in the region of the axilla. The patient should sit upright in bed, and should be carefully protected from cold, as pneumonia not infrequently follows the operation.

AMPUTATIONS IN THE LOWER EXTREMITY

CHAPTER VI

AMPUTATIONS OF THE FOOT

AMPUTATIONS OF THE TOES

THE amputations performed upon the toes are few in number. Except in the case of the great toe it is rarely necessary to do anything except a disarticulation at the metatarso-phalangeal joint, as the toes themselves are of little use, and removal of portions of them often only gives rise to a stump that gets in the way and is subjected to injurious pressure. The line of the metatarso-phalangeal joints lies about an inch behind (or above) the free margin of the web of the toes. The joint line of the great toe can be localized accurately by palpation, on flexing and extending the toe, and the prominence of the metatarso-phalangeal joints is formed by the head of the metatarsal bone. The ligaments of these joints consist of two lateral and an anterior or glenoid ligament.

AMPUTATIONS OF THE GREAT TOE

Disarticulation at the inter-phalangeal joint. The best amputation is by means of a single plantar flap, and the operation is similar in all respects to the corresponding operation on the terminal joints of the fingers (see p. 97). The toe is flexed and held between the left thumb and forefinger (see Fig. 72), and a transverse incision is made with a bistoury across the inter-phalangeal joint at right angles to the surface; the knife should enter the articulation at once. The lateral ligaments are divided by slight sawing movements, and the knife is carried on across the joint until it has divided the glenoid ligament, when its edge is turned downwards towards the tip of the toe, and it is made to cut downwards close behind the plantar surface of the phalanx until quite near the tip of the toe, when its edge is turned at right angles to the plantar surface and made to cut its way out. The flap thus cut should be quite square at the end, so as to fit accurately to the transverse incision on the dorsal aspect.

There will be few bleeding vessels to secure, as only the terminal

branches of the digital vessels are divided and they are easily controlled by firm pressure. The flap is secured in position by two deep sutures of silkworm-gut, while the margins of the skin are approximated by a continuous suture.

The plantar flap may be raised by cutting it from without inwards ; in this case the toe is hyper-extended, and the plantar flap is marked out first and then raised, taking up all the structures down to the bone. The flexor tendon and the glenoid ligament are cut together on the same level. When the plantar flap has been raised, the toe is flexed, and an incision is made transversely across the dorsal aspect exactly over the

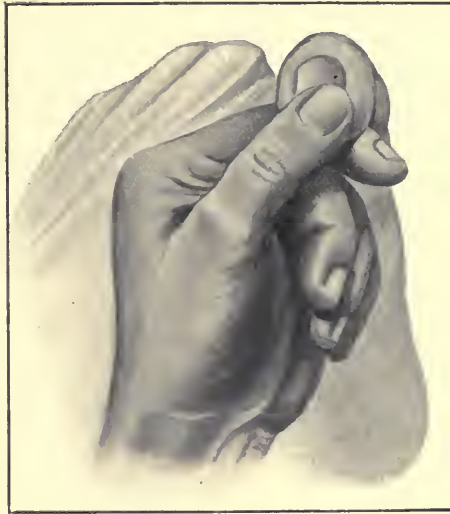

FIG. 72. DISARTICULATION OF THE GREAT TOE AT THE INTER-PHALANGEAL JOINT. This shows the method of holding the great toe. The steps of the operation are similar to those of the corresponding operation in the fingers.

joint on a level with the base of the plantar flap. This divides the extensor tendon and opens the joint, and disarticulation can be completed by a few touches with the point of the knife. This method is a little slower than the preceding one, which on the whole is preferable, except perhaps in cases in which there is much limitation of movement in the joint.

Disarticulation at the metatarso-phalangeal joint.

There are several operations for disarticulation at the great toe joint, and the surgeon will be largely guided by the particular affection for which the amputation is to be done, and the amount and distribution of the tissues at his disposal for the flaps. The most satisfactory method is probably

that by a large internal flap, which is known by the name of Farabeuf, although it is by no means the easiest to perform successfully.

Anatomical points. There are certain points that must be borne in mind in all disarticulations in this situation. In the first place the large size of the head of the first metatarsal bone renders it impossible to get the flaps to meet accurately over it, unless the incisions are so planned that they do not diverge from one another above the level of the joint. Thus, if a racket incision be employed, the lower end of the handle of the racket must be carried down to or even below the joint level before the circular incision is carried round the toe, and if a Farabeuf's amputation be performed the incision must start at or even below the joint line. Another point of some importance is that the weight of the body is chiefly transmitted through the heel and the heads of the metatarsal bones, and that most of the weight falls upon the head of the first metatarsal. Special efforts should be made to preserve this structure in all cases, as its removal is apt to alter the mechanics of the foot entirely and to interfere seriously with locomotion. It is also very important to place the scar resulting from the operation where it will not be exposed to the risk of pressure from the boot, as otherwise intolerable pain may ensue, and another amputation may be necessary. The sesamoid bones should always be left in the flap, as their removal will endanger the vitality of the flap and may interfere with easy locomotion.

By a large internal flap (Farabeuf's method). In this amputation the head of the first metatarsal is covered by a large flap, derived partly from the internal and partly from the plantar aspect of the great toe, which is folded across over the head of the bone and united to the adjacent lateral aspect of the second toe just at the base of the web; the result is that the cicatrix lies deep in the web between the first and second toes, and is out of the way of pressure.

Perhaps the most important practical point to remember when performing this operation is, that if the incision be commenced *above* the joint line, the large size of the head of the metatarsal will prevent the flaps coming properly together over it, and some portion of the articular surface will therefore have to be cut away; this should always be avoided because of the important part the articular end of the bone plays in supporting the weight of the body.

Operation. The surgeon stands facing the sole, and has the foot projecting beyond the end of the table. The great toe is taken between the left thumb and forefinger and is flexed somewhat towards the sole. The knife is entered on a level with the joint line at the point where an imaginary inner joins an imaginary dorsal surface, supposing that the

toe were mapped out into four surfaces, anterior, posterior, internal, and external; this point is slightly to the inner side of the tendon of the extensor hallucis longus. The incision is carried straight down the toe until the neck of the first phalanx is reached, and it is then curved inwards over the inner aspect of the toe until it reaches the junction of the imaginary internal and plantar surfaces. At this point the toe is firmly dorsi-flexed, and the incision is carried obliquely upwards to the web between the first and second toes across the plantar surface of the toe. The toe is finally plantar-flexed somewhat, and pulled away from the second toe, and the incision is carried from the web back by the shortest route to the point from which it started (see Fig. 73). The surgeon holds

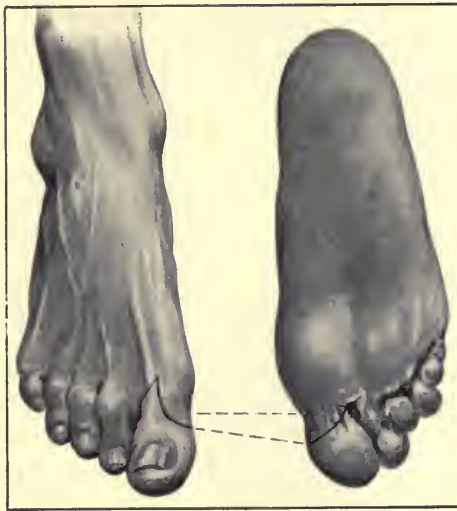

FIG. 73. FARABEUFS DISARTICULATION AT THE METACARPO-PHALANGEAL ARTICULATION OF THE GREAT TOE.

the toe in his left hand the whole time, changing its position as the knife is carried round. The first two-thirds of the incision are made with one sweep of the knife, the remaining portion, namely, the incision from the web to the starting-point, is usually made by a separate cut in the reverse direction of the first. The incision should go down to the bone so as to avoid damage to the blood-supply of the flap, and the extensor tendon should be divided on the level of the joint.

The toe is now taken charge of by the assistant, while the surgeon dissects back the large internal flap thus marked out; while the flap is being raised the toe should be dorsi-flexed. When the level of the joint is reached the toe is fully dorsi-flexed, and the glenoid ligament

is cut through just beyond the sesamoid bones, which are left behind in the flap. The lateral ligaments are divided by a few touches with the point of the knife, and then the phalanx can be twisted out and the extensor tendon divided, if this has not been done already (see Fig. 74).

There is little bleeding. Some of the digital branches may require ligature, but it is not necessary to use a tourniquet. The flexor sheath

need not be closed, and no drainage tube need be used; it is unnecessary to pay any attention to the divided flexor and extensor tendons.

By a large square internal flap. This method is suitable for the same cases as those to which the preceding method (to which it is very similar) is applicable, but it does not give such an artistic result. The incision is begun on a level with the joint line just internal to the extensor tendon, and is carried vertically down the toe as far as the base of the terminal phalanx. From this point a transverse incision is carried around the inner side of the great toe to a point on the plantar surface corresponding to that on the dorsum, and thence the incision is continued up the middle line of the plantar surface to the level of the web between the first

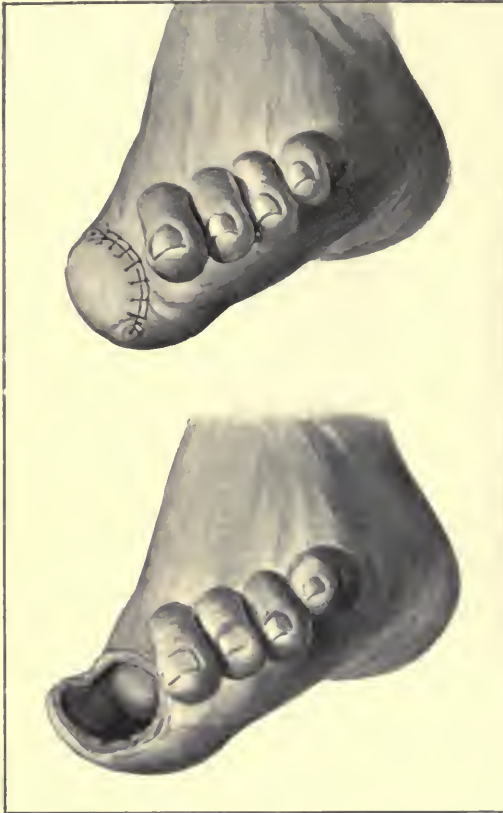


FIG. 74. THE STUMP LEFT AFTER FARABEUF'S AMPUTATION OF THE GREAT TOE. The figure shows how well the cicatrix is removed from all source of pressure.

and second toes. From the upper extremity of this incision a transverse cut is then carried round the outer side of the base of the great toe on a level with the free margin of the web, until it meets the dorsal incision, usually about one-third down its length (see Fig. 75). The flaps thus marked out are raised, and the bone is disarticulated as in the preceding operation.

The chief point of recommendation in favour of this operation is that it is easier for a beginner than Farabeuf's, which is apt to be performed clumsily until the surgeon has had some practice with it. Farabeuf's amputation, however, gives such an elegant and excellent stump that the extra study necessary for performing it with accuracy is well bestowed.

By the racket incision. The surgeon stands facing the sole as before, grasping the toe and plantar-flexing it between the left thumb and forefinger. The incision commences just above the line of the joint over the extensor tendon, and is carried vertically down to just beyond the level of the free margin of the web between the first and second toes,

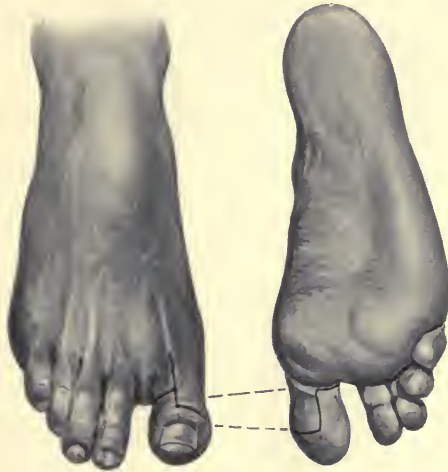

FIG. 75. DISARTICULATION OF THE GREAT TOE BY AN INTERNAL FLAP.

whence a transverse circular incision is made around the toe (see Fig. 76). The flaps thus marked out are raised from the bone, which is disarticulated as before. The sesamoid bones are left in the flap.

This operation, on the whole, is the simplest of all to perform, but nevertheless a good deal of attention must be paid to detail if the result is to be quite satisfactory. In the first place the flap is a clumsy one, and, when the soft parts are thick, it is somewhat difficult to dissect them back sufficiently to expose the line of the joint and disarticulate with ease. The result is that the beginner is apt to bury the point of his knife in the sole of the foot, and so to wound the arteries which are the main source of blood-supply to the flaps. The cicatrix, moreover, is not so completely removed from the risk of all pressure as it is in either of the preceding operations. But, on the other hand, there is never any difficulty in covering the head of the first metatarsal completely so long

as the transverse portion of the racket incision is not commenced until the vertical limb or racket handle has been carried down beyond the level of the free margin of the web.

After-treatment. No splint is required for amputations of the great toe, and no drainage tube need be inserted. The best plan is to put in two stout deep silkworm-gut sutures to hold the flaps together, and to complete the approximation of the skin edges with a continuous silk or silkworm-gut suture. The patient may be allowed to get up after the fourth day, and to put his foot to the ground after a fortnight, when

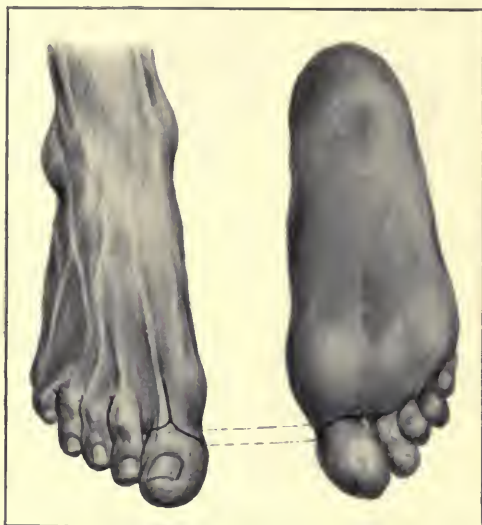

FIG. 76. DISARTICULATION OF THE GREAT TOE BY THE RACKET METHOD. This figure shows how the flaps on the two sides are unequal; that on the inner side extends somewhat further down in order to enable the large head of the metatarsal bone to be covered.

the sutures should be removed. The stump will probably be quite sound in three weeks.

DISARTICULATION OF THE OUTER TOES AT THE METATARSO-PHALANGEAL JOINTS

It is not worth while to attempt to preserve portions of the three outer toes, as any portion so retained is not only useless but may be actually in the way and exposed to injurious pressure. It is well, however, to retain as much of the second toe as possible, as its presence tends to prevent deflexion of the great toe and the occurrence of hallux valgus. Except in the case of the little toe, the best method of removal is by

the ordinary racket amputation already described for the great toe (see p. 163). The line of the metatarso-phalangeal articulation is one inch above the web, and the handle of the racket should commence just above this point directly over the extensor tendon. The vertical limb of the incision should be carried down beyond the level of the free margin of the web before the transverse circular cut is commenced. If this be done, there will be no difficulty in getting the flaps to meet satisfactorily.

Disarticulation at the metatarso-phalangeal joint of the little toe may be performed by any of the methods applicable to the great toe, employing an external flap, where an internal flap is employed for the latter. As a rule, however, the comparative small size of the parts and the possible distortion of the toe will render the racket method (see p. 163) the most suitable on the whole.

AMPUTATIONS OF THE FOOT

DISARTICULATION THROUGH THE TARSO-METATARSAL JOINTS

This is a very satisfactory form of operation, giving an excellent stump which is fit to bear the full weight of the body and is easily fitted with a suitable boot.

Indications. It is performed fairly frequently, and it may be required for

- (i) Severe crushes involving all the toes.
- (ii) Some cases of frost-bite limited to the toes, and not implicating the structures in the sole.

For tuberculous disease of the metatarsus, perforating ulcer of the foot, or sepsis limited to the front of the foot, it is, however, not really satisfactory. Tuberculous disease can be better treated either by free exposure and removal of the diseased area, or, if that be impossible, by amputation higher up the limb; a procedure which is certain to remove the entire area of disease, which the disarticulation in question is not certain to do. The same remarks apply to septic conditions about the front of the foot and toes, which can be cured either by properly planned drainage, or by an amputation above the level of the disease. In perforating ulcer of the foot, faulty nutrition of the parts is the primary cause of the ulcer, and this is likely to interfere with union if an amputation be done through the badly nourished tissues.

Three forms of amputation are performed in this situation, of which the true disarticulation is that known as Lisfranc's operation, or separation of the metatarsus from the tarsus, following its anatomical boundaries. The two other operations separate the two portions of the foot more arbitrarily. The operation known as Hey's is a disarticulation through

the four outer joints of the foot, followed by removal of the projecting end of the internal (first) cuneiform bone. The third form, known as Skey's, is done by disarticulating the inner and the three outer metatarsals as in Lisfranc's operation, and then sawing across the base of the second metatarsal instead of disarticulating it.

Lisfranc's operation. The operation most in vogue at the present time seems to be Lisfranc's, but the more symmetrical stump resulting from Hey's amputation is, in my opinion, much better than that following the true Lisfranc's, in which the internal (first) cuneiform forms a projection on the inner side of the foot; although this may be useful in bearing the weight of the limb, it nevertheless sometimes offers an obstacle to the proper union of the flaps.

When performing amputation of the metatarsus, I am in the habit of doing the true Lisfranc's operation and then sawing off that portion of the internal (first) cuneiform afterwards that projects beyond the line of the other bones. There is no objection to sawing across this bone; the reason for avoiding doing so in former years, namely, the fear of giving rise to septic osteitis, exists no longer.

Another modification of the amputation which is of practical value in some cases, and which is perhaps the simplest way of performing this operation, is to disarticulate the three outer joints, and then to cut across the base of the second metatarsal and the internal (first) cuneiform with a saw in the line of the three outer articulations. This is a very useful plan should the surgeon find that he has commenced his incisions too far back on the foot, and that he will be unable otherwise to cover the bones efficiently.

Surgical anatomy. The line of the tarso-metatarsal articulation is an irregular one. It commences on the inner side at the joint between the internal (first) cuneiform and the first metatarsal, and ends at that between the cuboid and the fifth metatarsal on the outer. The projection on the base of the latter bone is easily felt through the skin, and the incision should extend down to the tip of this. The articulation between the internal (first) cuneiform and the first metatarsal on the inner side, however, cannot always be felt, and the best way to localize it is to identify the prominent tubercle of the scaphoid and to take a point a full inch horizontally in front of this; the line of the incision can be determined without difficulty as the shaft of the first metatarsal is easily palpable.

Operation. The surgeon faces the sole of the affected foot and has the limb raised to a suitable height and held with the foot at right angles to the leg by an assistant, who grasps the toes and pulls them backwards. The surgeon defines the anatomical landmarks for his incision, and marks them with his left thumb and forefinger (see Fig. 77).

He then enters the point of the knife just below the tip of the forefinger, which will be on the outer side of the right limb and on the inner side

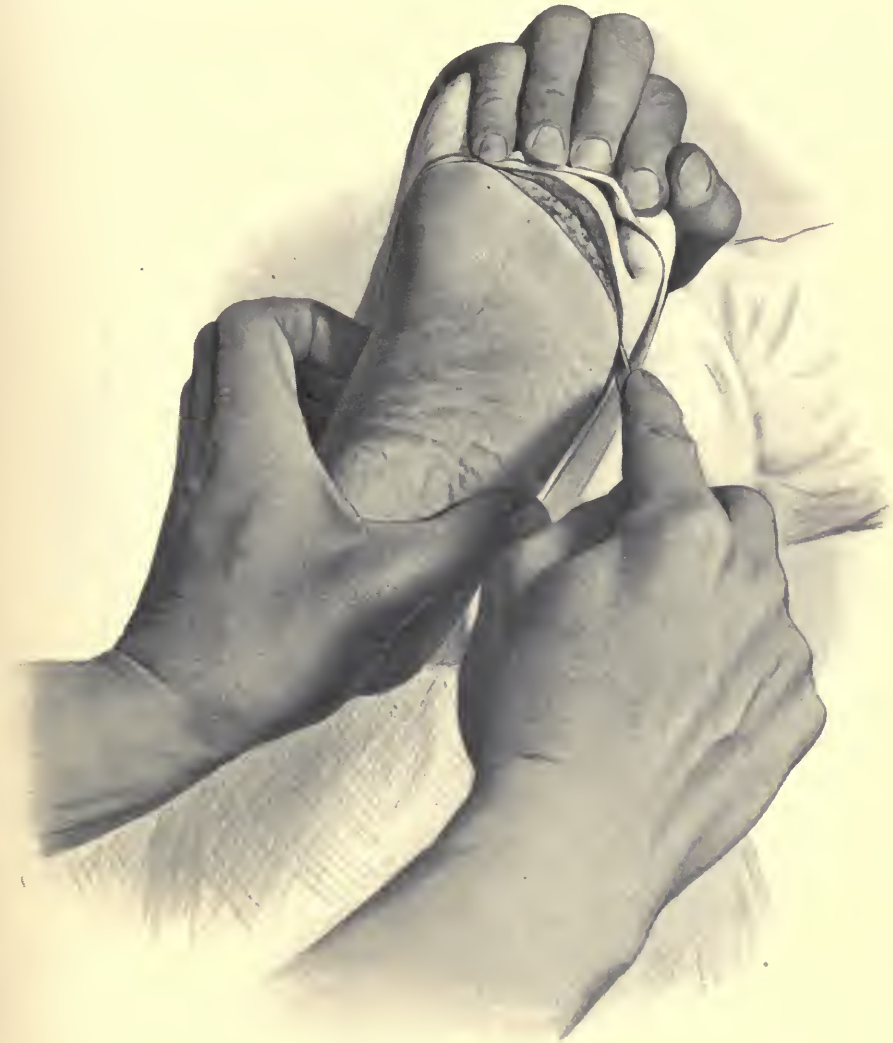

FIG. 77. CUTTING THE PLANTAR INCISION IN LISFRANC'S AMPUTATION. The figure shows the method of marking out the termination of the incision by the left thumb and index finger. It also shows how the foot is held during the incision.

of the left. From this point the incision is carried forward accurately along the border of the foot until the neck of the metatarsal bone is

reached. It is then carried across the sole of the foot over the prominent heads of the metatarsal bones parallel to the line of the web until the opposite border of the foot is reached, when it is carried along that border back to the surgeon's left thumb, which marks the termination of the incision (see Fig. 78).

This incision marks out a large flap on the plantar aspect of the foot which is rather longer on the inner side than on the outer, in order to allow for the due covering of the thicker bones on the inner side of the

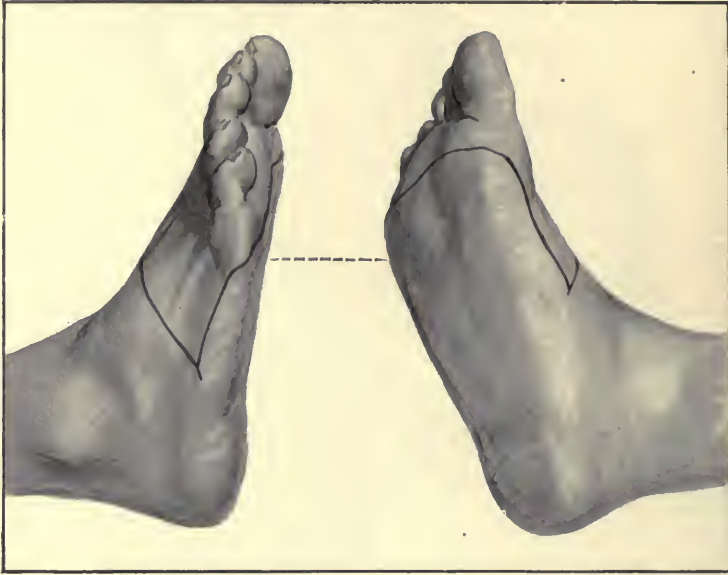


FIG. 78. INCISIONS FOR LISFRANC'S AMPUTATION. The left-hand figure shows the obliquity of the incision from the inner side to the outer side. Note that the horizontal portion of the plantar incision is well up along the respective metacarpal bone.

foot. In making the incision great care must be taken to commence the incision strictly from the anatomical landmarks, especially on the inner side, and to carry it well on the lateral aspect of the foot until the level of the necks of the metatarsals is reached. The tendency is to carry it from the centre of the lateral aspect of the internal (first) cuneiform obliquely into the sole instead of along the inner border of the foot. The knife must be held strictly at right angles to the skin throughout the incision, which should go through the skin and subcutaneous fat only. No tourniquet is needed.

In dissecting up the plantar flap the surgeon raises the skin and fat

only for the first inch or so ; for this purpose forceps may be used. When the level of the necks of the metatarsal bones is reached, however, the

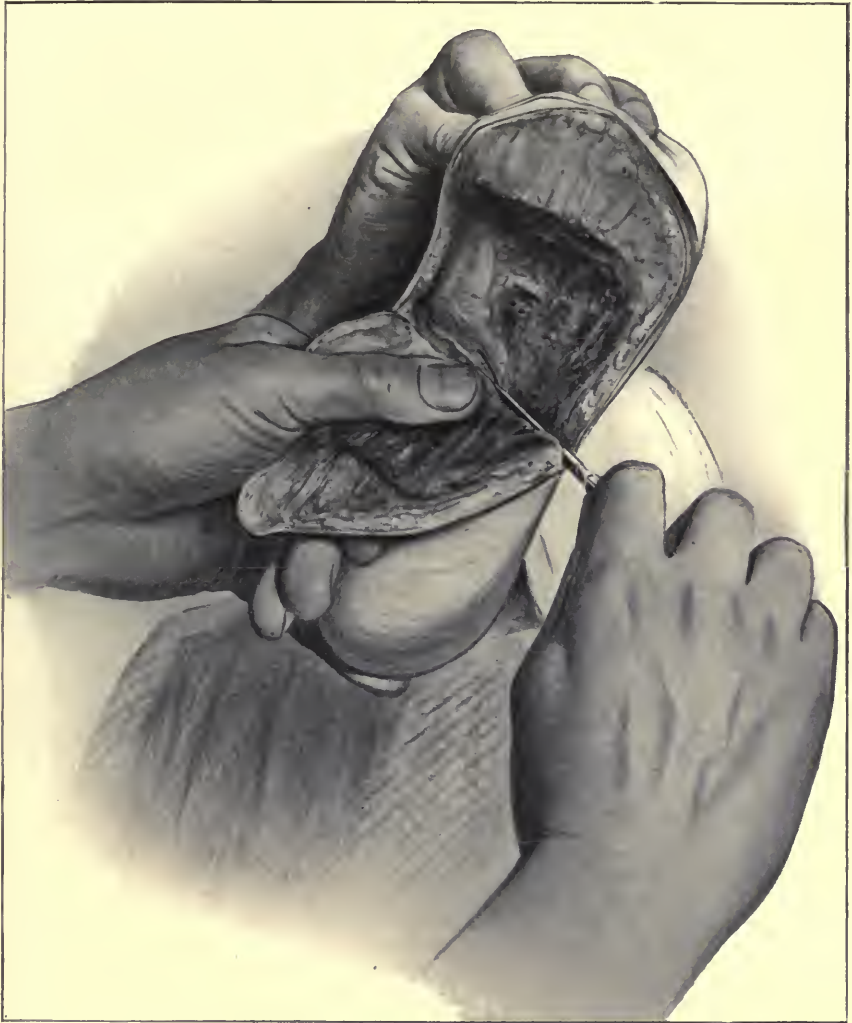


FIG. 79. RAISING THE PLANTAR FLAP IN LISFRANC'S AMPUTATION. All the structures are taken up down to the bone. The large tendon of the peroneus longus can be seen crossing the sole obliquely forwards and inwards from the outer side.

edge of the flap is grasped in the fingers and all the structures are taken up down to the metatarsal bones. This gives a large, thick, well-nourished flap which is dissected back to the level of the horns of the incision,

when the tendon of the peroneus longus will be seen in its sheath crossing the bones obliquely forwards and inwards (see Fig. 79).

When the plantar flap has been raised sufficiently the surgeon grasps

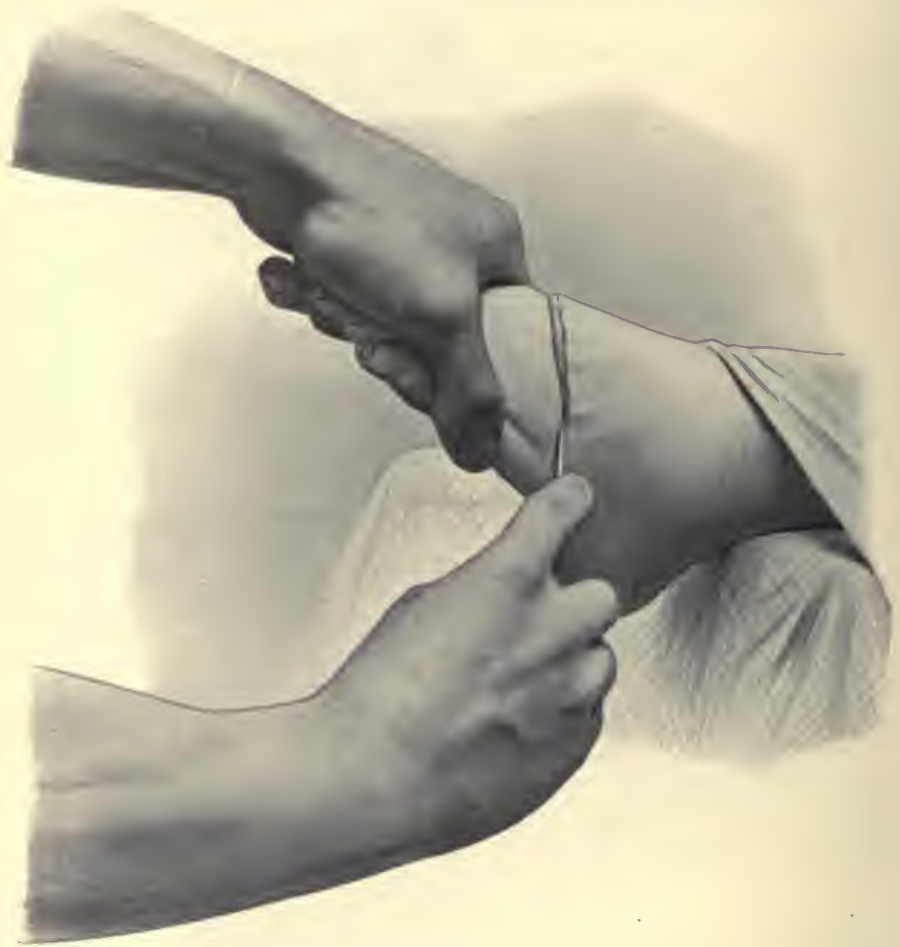

FIG. 80. METHOD OF GRASPING THE FOOT WHEN CUTTING THE DORSAL INCISION IN LISFRANC'S AMPUTATION. If the surgeon's left hand grasps the foot in this manner it retains perfect control over the front of the foot during the subsequent stages of the operation.

the forepart of the foot with his left hand across the dorsum (see Fig. 80), and joins the two extremities of the plantar incision by a cut across the dorsum slightly convex downwards, extending only through the skin and fascia. When the skin has retracted, the tendons, vessels, and nerves are severed down to the bone on the level of the edge of the retracted

skin, and the surgeon proceeds to disarticulate the metatarsus from the tarsus. In the right foot he commences on the outer side, in the left foot on the inner. It is easier to begin from the outer side, as the prominent tuberosity of the fifth metatarsal bone is a landmark that cannot be missed. The knife is slipped in behind it, and, by using the point only, the tarso-metatarsal ligaments are divided, and the two outer joints are opened up with ease as they lie on the same horizontal line.



FIG. 81. METHOD OF DISARTICULATING THE BASE OF THE SECOND METATARSAL BONE. The figure shows how the knife is held and introduced between the metatarsal and internal cuneiform.

The third joint is also easy to find, but it is a trifle nearer the toes than the two preceding ones.

When these three joints have been opened, the articulation between the first metatarsal and the internal (first) cuneiform must be located and opened. This is the chief stumbling-block of the operation, for, unless the landmarks have been accurately made out, the surgeon may mistake the joint between the scaphoid (navicular) and the cuneiform for that between the latter and the first metatarsal, and may therefore remove the

internal (first) cuneiform with the front of the foot. If, however, the three outer joints have been opened first, it is always easy to locate the joint required on the inner side, as it is nearly an inch in front of, viz. nearer to the toes than, the joints just mentioned. When this joint has been opened, all that remains in order to complete the disarticulation is to divide the ligaments of the second metatarsal bone, which is wedged in between the inner and outer cuneiform bones. In order to do this the knife, held as shown in Fig. 81, with its edge upwards, is introduced between the first and second metatarsals, and made to find its

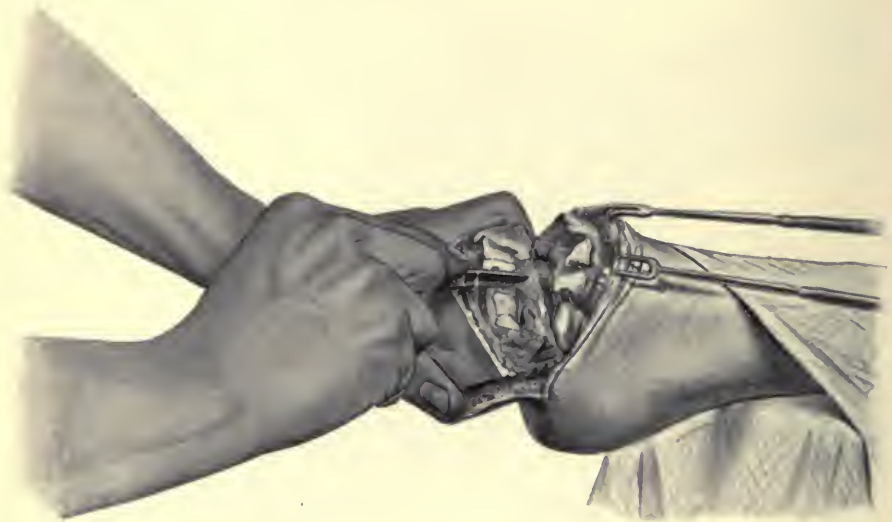


FIG. 82. DISARTICULATION OF THE FRONT HALF OF THE FOOT IN LISFRANC'S AMPUTATION. The knife is in the act of severing the peroneus longus tendon, thereby releasing the front half of the foot.

way into the interval between them and to cut upwards with a light sawing movement. It is then withdrawn and introduced between the second and third metatarsals, where the division of the ligaments is practised in a similar manner. Finally, the ligaments uniting the bone to the second cuneiform are put on the stretch and rendered prominent by pressing the toes downwards, and are divided by a few touches of the point of a knife (see Fig. 81). The foot is thus disarticulated.

Before sewing up the flaps it is advisable to pull out and cut short the tendons on the plantar and the dorsal aspects of the foot. The vessels, namely, the dorsalis pedis and the two plantar trunks, will have been picked up and secured as they were divided in the operation. Should

the surgeon desire it, he may finish the operation by sawing off the projecting portion of the internal cuneiform in order to make a neater stump.



FIG. 83. STUMP OF LISFRANC'S AMPUTATION SEEN FROM THE OUTER SIDE.

When the flaps are brought together their line of union falls upon

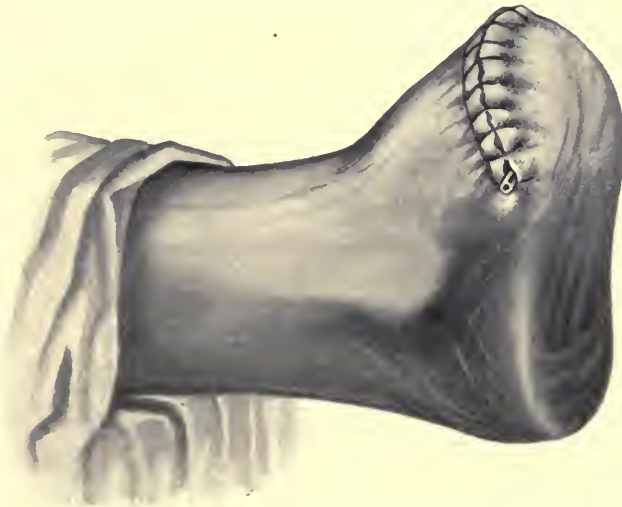

FIG. 84. LISFRANC'S AMPUTATION. STUMP SEEN FROM THE INNER SIDE WHEN THE INCISION HAS BEEN CORRECTLY PLANNED. The line of suture is drawn somewhat up to the dorsal aspect of the foot.

the dorsal aspect of the limb (see Figs. 83, 84), and the scar will be out of

the way of irritation from pressure owing to the retraction of the skin over the instep. It is important not to cut any dorsal flap; if one be made, the line of union will lie over the edge of the bones, and much distress may ensue from friction against the boot. The plantar flap, on the other hand, is admirably adapted for bearing pressure without trouble. Two drainage tubes should be inserted, one at the inner and one at the outer angle of the stump; this is better than passing a long single tube across from side to side. Stout silkworm-gut sutures will be required to hold the heavy flap in position, and the approximation of the skin-edges should

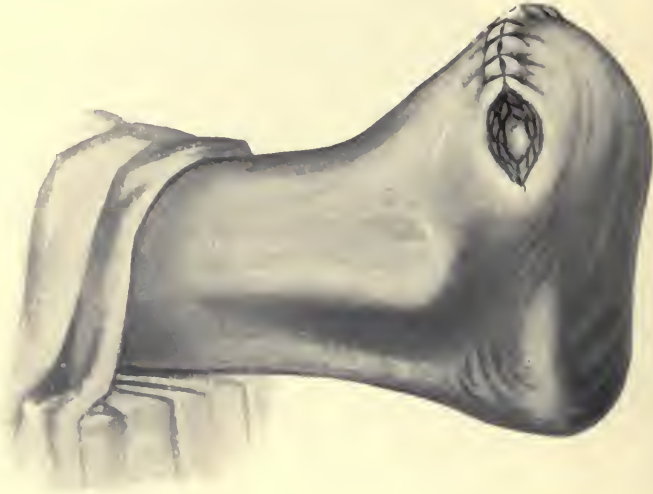

FIG. 85. THE APPEARANCE PRESENTED BY THE STUMP OF A LISFRANC'S AMPUTATION WHEN THE FLAPS HAVE BEEN IMPROPERLY PLANNED. In this case the incision has been begun rather behind the joint on the inner side. The large internal cuneiform is partly exposed and the flaps cannot be properly approximated.

be completed by means of a continuous silk or silkworm-gut suture. The limb should be put up on a splint with a foot-piece at right angles, and this should be elevated upon a pillow. The knee should be fixed.

After-treatment. The drainage tube should be removed on the third day, when it is an excellent plan to apply a collodion dressing in such a way as to support the heavy flap and prevent the stitches from cutting through (see Fig. 93). The continuous suture may be removed at the end of ten days, but the deep silkworm-gut sutures should not be dispensed with for at least a fortnight or three weeks from the time of operation. The patient is usually able to bear a fair amount of pressure upon the limb in about a month's time, and the stump should

be perfectly sound and useful in six weeks, as the skin covering the sole ought to bear any pressure thrown upon it without injury.

Difficulties. The most serious difficulty is a mistake in locating the landmarks when cutting the flaps; in operating upon the cadaver this mistake is constantly made. It is somewhat easier to define the points in the living subject, but even then there is a liability to go wrong, unless care be taken to place the thumb or forefinger on each point as it is identified, and to keep them in position until the incision marking out the plantar flap has been completed.

Another serious difficulty has already been referred to, namely, the inability to cover the inner aspect of the internal (first) cuneiform (see Fig. 85); this is due to the incision either being commenced well below the level of the centre of the lateral aspect of the first metatarsal, or else being carried down on to the sole too quickly, instead of running horizontally along the lateral aspect of the metatarsal.

The third difficulty, namely, the disarticulation of the second metatarsal bone, has also been referred to (see p. 171), and can be avoided by following the instructions there given. It is, however, chiefly a difficulty of the examination room, for, in actual practice, it makes no difference whatever whether the bone be cleanly disarticulated or its base sawn across and left behind.

DISARTICULATION AT THE MEDIO-TARSAL JOINT

Chopart's amputation. This operation, which is still a favourite at examinations and in the dissecting room, is of little value in practice; it does not compare for usefulness with Syme's or some form of the sub-astragaloid amputation. The objections to Chopart's amputation are numerous, the most important being that, owing to the removal of the front of the foot, the body weight ceases to be transmitted through the heads of the metatarsal bones, and so the astragalus (talus), through which the weight is transmitted, loses the support afforded it by the front of the foot in the normal state, and tends to be thrust forward beneath the tibia against the cicatrix, to which it becomes adherent, so that a painful ulcerated stump results. Moreover, the tendo Achillis causes tilting of the heel, since its action is unbalanced by the dorsi-flexors of the foot, such as the tibialis anticus (anterior) and the extensors. This tends to protrude the astragalus (talus) still further, and is practically impossible to remedy. Division of the tendo Achillis is only of temporary benefit, and even the suggested implantation of the dorsi-flexors of the foot into the plantar flap does not provide them with sufficient leverage to enable them to act satisfactorily.

Quite apart from the unsuitability of the stump, there is the further

objection that the scope of the operation must necessarily be very limited. In cases of injury it will generally be possible to preserve some portion of the cuneiform bones at any rate, and so to secure a foot that will be more mechanically useful; this means that some modification of Lisfranc's amputation (see p. 166) will be preferred. In tuberculous or septic disease Chopart's operation is wholly unsuitable; owing to the arrangement of the synovial membrane, tuberculous disease which has spread as far as the scaphoid (navicular) and the cuboid will have extended to the tendon sheaths in the vicinity, or to the joints on the

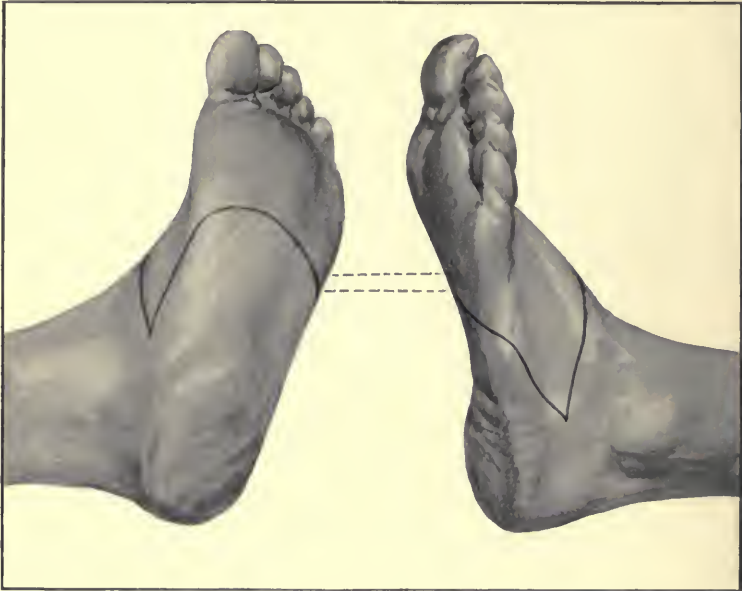


FIG. 86. INCISIONS FOR CHOPART'S AMPUTATION.

proximal side of the medio-tarsal articulation, and some more radical operation which will ensure removal well beyond the limit of the disease must be practised. The same remark applies to septic disease.

Surgical anatomy. The only prominent guide to the joints between the os calcis (calcaneus) and the astragalus (talus) behind and the cuboid and the scaphoid (navicular) in front, is the tubercle of the latter, which is about half an inch in front of the joint on its inner side. On the outer side the joint lies about midway between the tip of the external malleolus and the tuberosity of the fifth metatarsal bone. The line of the joint is almost transverse, the calcaneo-cuboid articulation being on a slightly posterior level to the astragalo-scaphoid (talo-navicular).

Operation. The foot is raised and somewhat dorsi-flexed by an assistant; the surgeon stands facing the sole. The left thumb and forefinger are placed upon the two anatomical landmarks mentioned above, and a plantar flap is marked out commencing on the outer side of the right foot and on the inner side of the left (see Fig. 86). The incision resembles that for Lisfranc's operation (see p. 166), except that it does not extend as far forward as the level of the necks of the metatarsal bones; as in Lisfranc's, it is longer on the inner side than on the outer, and the same care must be taken to keep it well up on the inner and outer borders of the foot respectively, or else it will be difficult to cover the bones at the junction of the flaps. The plantar flap is raised just as in Lisfranc's operation (see p. 166), the skin and subcutaneous fat being taken for the first inch, and after that all the soft parts down to the bones.

When the flap has been raised as far back as its base, the foot is grasped across the dorsum, depressed forcibly, and a dorsal incision marked out by joining the two ends of the plantar incision across the front of the instep. This incision should only have a very slight convexity downwards, as it is important that the cicatrix should lie upon the dorsum of the foot, so as to be well out of the way of injurious pressure; therefore no pronounced dorsal flap must be cut. At the first incision the skin alone is divided, and when this has retracted, the remaining soft parts, tendons, &c., are divided down to the bone at the level of the edge of the divided and retracted skin.

In order to disarticulate, the tubercle of the scaphoid (navicular) is identified, and the point of the knife is inserted into the joint immediately behind it. As the two joints forming the medio-tarsal articulation are nearly on the same level, disarticulation can usually be completed from the side upon which it was begun; if not, it must be remembered that the level of the calcaneo-cuboid articulation is slightly behind that of the astragalo-scaphoid (talo-navicular). The subsequent steps are similar to those of Lisfranc's operation (see p. 166). The operation should be concluded by fixing the extensor tendons to the front of the bone or to the large plantar flap by any form of suture that seems most suitable at the time.

Some surgeons complete the operation by dividing the tendo Achillis; this, however, can only be of temporary benefit, and it is hardly worth while performing it, provided that due care be taken to obviate pain and spasm by suturing the flaps securely and avoiding undue pressure on the end of the stump. A splint should be employed similar to that for Lisfranc's operation, and the foot should be put up and maintained strictly at right angles to the leg. A large pad of dressing may be put

beneath the front of the stump in order to tilt that end of the foot up, and several stout silkworm-gut sutures should be used to keep the flap in position, in addition to a continuous suture for apposition of the skin edges.

The operation gives an excellent looking stump, and does not shorten the limb, so that the immediate result is all that could be desired. In a short time, however, tilting of the stump occurs, and with it comes pain and irritation of the scar.

Tripier's operation. There is a modification of this operation that goes by the name of Tripier, which consists in removing the lower half of the os calcis (calcaneus), in addition to amputating at the medio-tarsal joint. There does not seem to be any practical advantage in this operation that is not to be found in other and better operations. Its chief object seems to be to provide horizontal under-surface to the os calcis (calcaneus) instead of an oblique one; thus, it resembles somewhat a sub-astragaloid amputation, which, however, has the great advantage over Tripier's that it cannot be spoiled by the baneful influence of the tendo Achillis. The difference in the amount of shortening after Tripier's operation and after a sub-astragaloid amputation is so slight as to be negligible. It will not be necessary to describe Tripier's operation in detail.

SUB-ASTRAGALOID DISARTICULATIONS

By this term is meant an amputation that removes all the bones of the foot below the astragalus, leaving that bone with its connexions to the tibio-fibular arch undisturbed. Several forms of this operation have been suggested, and they all have for their object the provision of a stump calculated to bear firm pressure, while shortening the limb less than Syme's amputation. The patient walks upon the part of the sole that he normally uses for locomotion, and bears his weight upon the whole width of it instead of upon the narrower surface furnished by Syme's amputation. The joint between the astragalus (talus) and the tibio-fibular arch is retained and is of distinct value. Lastly, there is less risk of damage to the blood-supply of the flap, a not inconsiderable advantage to those performing the operation for the first time. The stump thus provided has none of the inconveniences, such as tilting of the heel, that are so often met with after Chopart's amputation. The weight is borne upon the under-surface of the astragalus, which supports pressure well. In order to leave a perfectly level surface for the weight to be borne upon, some surgeons saw the astragalus horizontally; but, although theoretically good, this does not offer any practical advantage and is unnecessary, especially as it shortens the limb and prolongs the

operation. The stump is an excellent one, and is easy to fit with an artificial foot. The operation is becoming more popular than it was, but it still is not practised as often as its great merits entitle it to be. The steps of the operation are a little difficult to remember at first, but, once mastered, the operation will be favourably viewed by any one who practises it. Various modifications of the operations are given in the following pages, but the form that gives the best results on the whole, and the one that should be employed whenever the condition of the soft parts allows, is that associated with the name of Farabeuf. In order to

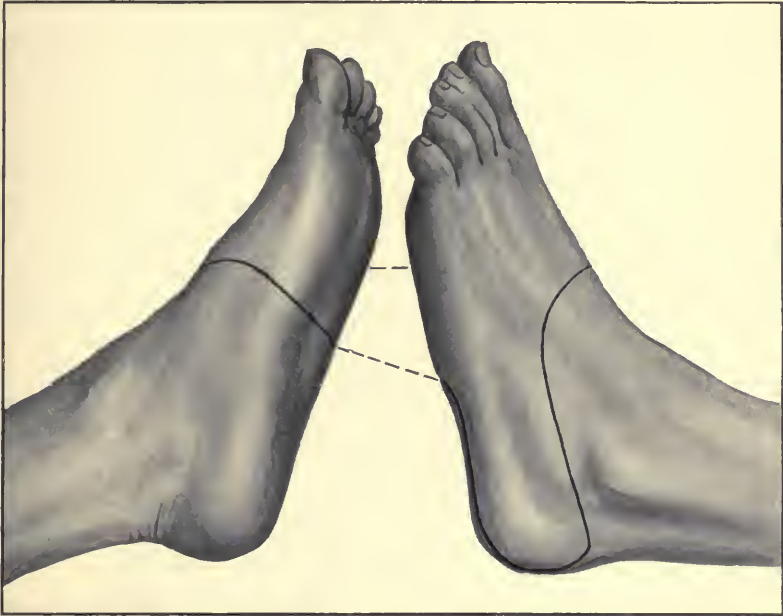


FIG. 87. INCISIONS FOR FARABEUFS SUB-ASTRAGALOID DISARTICULATION.

perform it safely the tissues of the foot must be sound as far forward as the level of the tarso-metatarsal articulations. It is done as follows :—

Farabeuf's operation. The limb is brought over the end of the table, raised and somewhat inverted. It is not absolutely essential to apply a tourniquet to the thigh, but it is wise to do so, as bleeding points are difficult to pick up as they are met with. The surgeon stands facing the sole and marks out a large internal flap by an incision which starts from the outer margin of the heel, runs parallel to the outer border of the foot, a finger's breadth below the tip of the external malleolus, and is carried horizontally forward to the level of the tuberosity of the fifth

metatarsal; it then curves sharply inwards across the dorsum just in front of the joint between the scaphoid and the three cuneiform bones until the tendon of the extensor hallucis longus is reached. The object of this curve in the flap is to cover the neck and head of the astragalus. From the extensor hallucis longus tendon the incision passes across the inner border of the foot, with a well-marked convexity forwards, beneath the arch of the instep to the centre of the sole. From this point the incision slopes gradually back to the outer border of the foot close behind the tuberosity of the fifth metatarsal, and from this point is carried back horizontally just above the outer border of the sole to the external tuberosity of the os calcis, where it curves upwards to join the commencement of the incision (see Fig. 87). These two incisions, the horizontal and the vertical one, meet nearly at a right angle near the outer border of the tendo Achillis, just at its insertion into the os calcis.

Farabeuf (*Manuel Opératoire*, 1895, p. 519) gives the following practical instructions as to cutting the flaps, which may be reproduced here with advantage in view of the great practical usefulness of the operation. The steps vary according as the left or right foot is to be operated upon.

Left Foot. The front of the foot is seized in the left hand, depressed, and rotated inwards. The incision is then begun over the prominence of the tendon of the extensor hallucis longus, just in front of the articulation of the scaphoid with the cuneiform bones. The incision, which should go down to the bone, is carried transversely outwards from this point for about five cm. (two inches) in the direction of the tuberosity of the fifth metatarsal. From this point it is carried backwards, parallel with the outer border of the foot and passing a full finger's breadth beneath the external malleolus to the outer border of the tendo Achillis just at its insertion into the os calcis.

The assistant now raises the limb so that the sole faces the operator. The front of the foot is raised and rotated outwards with the left hand, and the knife is made to enter the commencement of the dorsal incision over the tendon of the extensor longus hallucis. From this point the incision is brought downwards to the sole with a slight convexity forwards, so that it crosses the inner border of the foot just beyond the articulation between the first metatarsal and the internal (first) cuneiform. Thence the knife is drawn transversely across the sole to about its mid-point (see Fig. 88), and is then curved backwards to the outer border of the foot, which it follows backwards as far as the outer tuberosity of the os calcis, being finally carried upwards behind the heel to the outer border of the tendo Achillis to join the posterior end of the first incision. In doing this, the foot has to be raised considerably. The incision is carried down to the bone throughout, and is best made with a short

stout knife having a cutting blade of not more than two or three inches, so as to diminish the chance of the knife slipping.

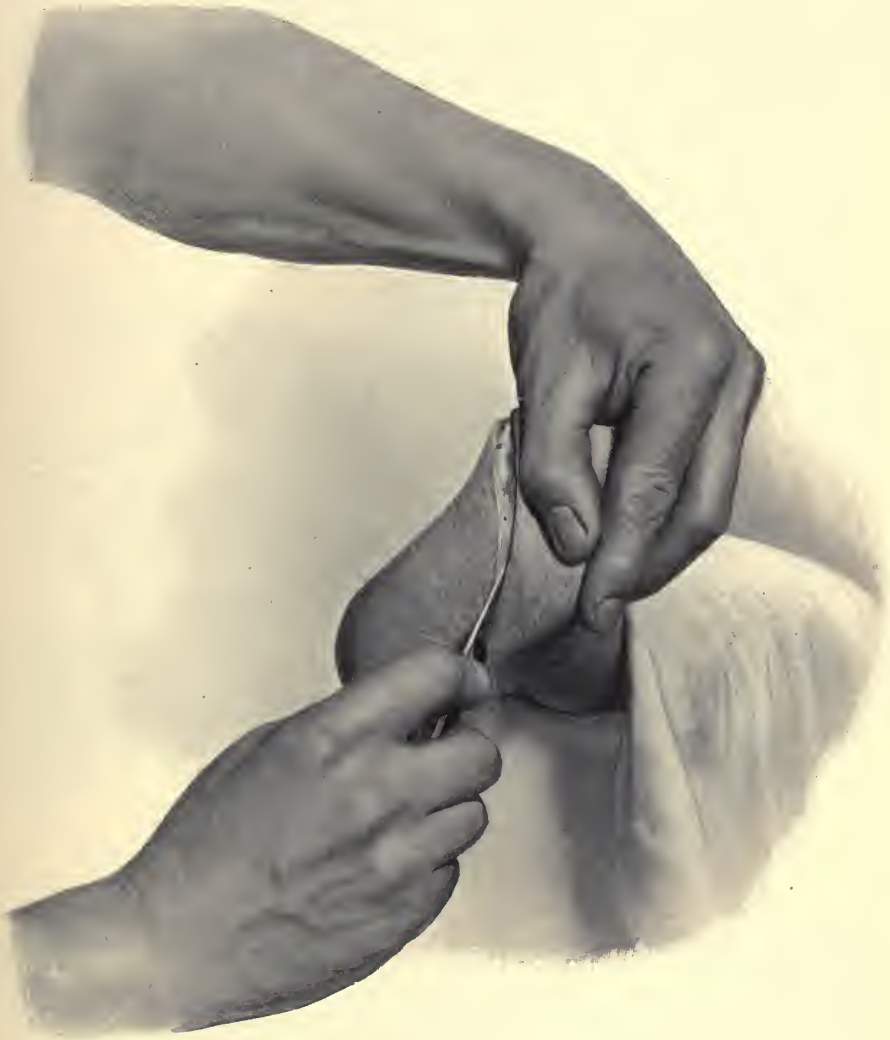

FIG. 88. CUTTING THE PLANTAR PORTION OF THE INCISION ON THE LEFT FOOT IN FARABEUF'S SUB-ASTRAGALOID DISARTICULATION. The figure shows how the foot is grasped in the surgeon's left hand and is rotated over towards his right so as to make the inner aspect of the foot accessible to the knife.

In order to perform disarticulation in the easiest manner, the assistant bends the knee at right angles and rotates the foot forcibly inwards, at

the same time fixing the lower end of the leg firmly upon the table. The upper part of the incision is now deepened down to the bone throughout, so as to divide all the tendons, and the short upper and outer flap is raised, cutting close to the bone throughout. This exposes the head of the astragalus, which is made more prominent by pressing the front of the foot downwards, and the articulation between the scaphoid and the

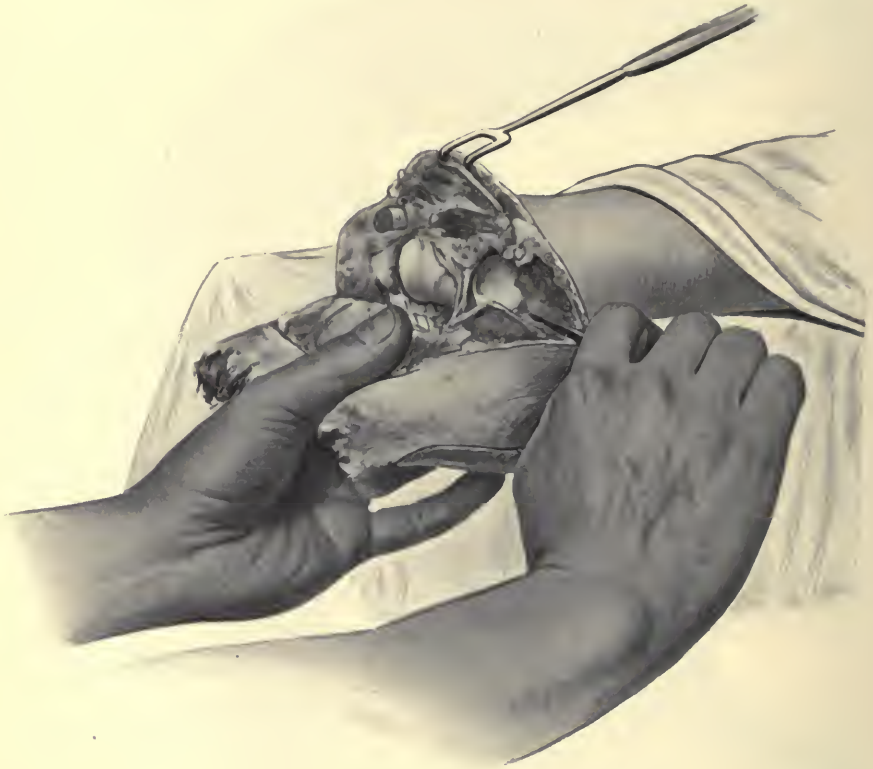

FIG. 89. SEPARATING THE OS CALCIS FROM THE ASTRAGALUS IN FARABEUF'S SUB-ASTRAGALOID DISARTICULATION. The knife is being drawn from left to right; it has divided the interosseous ligament between the os calcis and the astragalus and is proceeding to divide the tendo Achillis at the extreme right.

astragalus can be opened by a few touches of the knife. The point of the knife is now introduced beneath the head of the astragalus, and, cutting backwards, divides the interosseous ligament, a manœuvre that is aided by pressing firmly upon the outer surface of the os calcis. When the interosseous ligament has been divided, the parts become more accessible, and the foot is bent still further downwards, so that the upper

surface of the os calcis faces the operator. The knife is carried back, and, after dividing the remainder of the calcaneo-astragaloid (talo-calcaneal) ligaments, reaches the tendo Achillis, which is divided just above its insertion (see Fig. 89).

The more difficult part of the operation is now undertaken, viz.

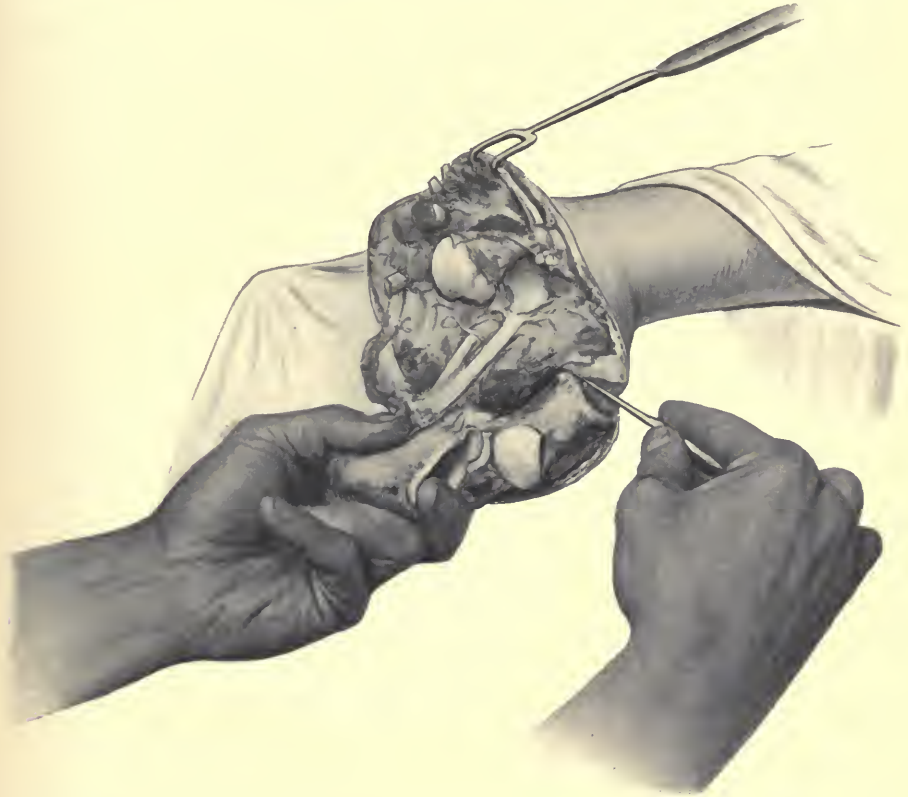

FIG. 90. THE FINAL STAGES OF CLEARING THE OS CALCIS IN FARABEUFS SUB-ASTRAGALOID DISARTICULATION. The os calcis and front of the foot are rotated so that the upper articular surface looks directly towards the operator and the inner surface looks vertically upwards. The structures have been turned out from beneath the sustentaculum tali and the knife is completing the removal of the foot by a few touches at the back of the os calcis.

separating the large internal flap from the inner side of the foot, as the irregular surface presented by the tuberosity of the scaphoid, the sustentaculum tali, and the hollow of the os calcis exposes the vessels and nerves which lie in close contact with them to some risk of damage. Only the point of the knife should be used, and it is important to keep the foot horizontal, and to cut as close to the bone as possible. As the

foot is freed it is pulled forwards horizontally from the leg. The first step is to divide the tibialis posticus from the scaphoid, and then, passing backwards, to cut the fibres of the internal lateral ligament attached to that bone and to the sustentaculum tali; this must be done with the point of the knife, and great care must be taken not to cut deeply into the flap beyond. The knife is then held very obliquely so as to be parallel to the course of the plantar vessels, and, with the cutting edge closely applied to the bone throughout, it is swept along the wound, from before backwards, until it is behind the os calcis. This is done several times, and, when the sustentaculum tali has been laid bare, the structures in the groove beneath it are turned out carefully, and finally the muscles attached to the tuberosity of the os calcis are divided. The division of the tendo Achillis is completed, and the foot is rotated more and more outwards around its antero-posterior axis until the outer border of the os calcis is cleared, and the flap is freed (see Fig. 90).

Right Foot. The front of the foot is seized with the left hand, depressed and the limb rotated inwards. The incision is commenced over the outer border of the tendo Achillis, and carried horizontally forwards a finger's breadth below the external malleolus as far as the level of the tuberosity of the fifth metatarsal, when it is curved inwards almost transversely across the front of the instep to the tendon of the extensor hallucis longus. The foot is now rotated outwards, and the dorsal incision is continued, with a convexity forwards, across the inner side of the foot, which it crosses about its centre. The assistant then raises the limb, the surgeon pushes up the front of the foot and the incision is carried across to the centre of the sole, whence it is curved back to the outer border, which it follows to the external tuberosity of the os calcis, where it is curved upwards to meet the commencement of the incision. I have always found it more convenient to trace out the last part of this incision in the reverse direction, *i.e.* from the outer tuberosity of the os calcis along the outer border of the foot, after rotating the foot inwards again.

The position for disarticulation is the same as in the preceding case, that is to say the knee is flexed to a right angle and rotated fully inwards and the assistant fixes the lower end of the tibia and fibula firmly on the table so that the outer border of the foot is horizontal. The calcaneo-astragaloid articulation is opened from behind forwards and the interosseous ligament divided. This is rather more difficult than on the opposite side, but firm pressure on the outer border of the foot will give room enough to allow the point of the knife to effect the division. The remainder of the operation is similar to that on the opposite side, except that the incision here has to be carried from behind forwards, namely, from the insertion of the tendo Achillis to the astragalo-scaphoid joint.

The same care must be taken of the structures beneath the sustentaculum tali.

After the operation any tendons showing in the flap are cut short, especially that of the tibialis posticus (posterior) (see Fig. 91). The posterior tibial nerve is similarly treated; in doing this, care must be taken not to damage the corresponding artery. Few vessels of importance require ligature; they are the dorsalis pedis and the two plantar arteries.

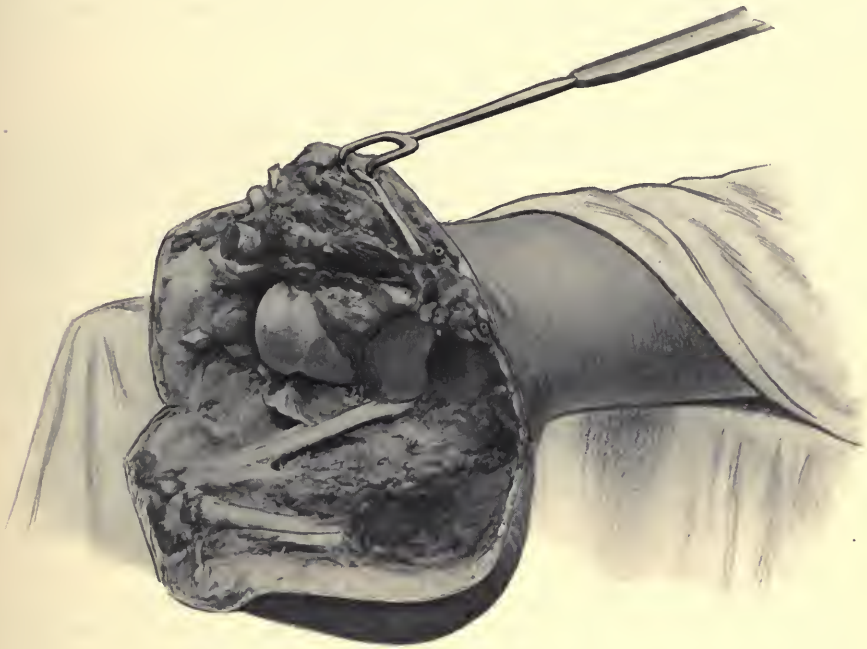


FIG. 91. THE APPEARANCE OF THE FLAPS AFTER FARABEUFS SUB-ASTRAGALOID DISARTICULATION. The inferior articular surfaces of the astragaloid are well seen, as is the tendon of the tibialis posticus; the cavity out of which the posterior part of the os calcis has been dissected also shows well.

When the flaps are brought together (see Fig. 92) they will cover the head of the astragalus satisfactorily, if attention has been paid to the instructions given above. The tendency, however, is to carry the incision across the inner side of the foot too obliquely backwards, and this may interfere with the proper covering of the head of the astragalus. If the flaps cannot be made to meet, it will be necessary to cut down the head of that bone until the flaps cover it satisfactorily. Farabeuf advises that the extensor tendons should be sutured to the flap, but this is not a point of great importance. Good drainage is necessary, and may be

effected by making a button-hole on the posterior aspect of the stump, and inserting a drainage tube about the size of the little finger. This drains the large cavity left by the os calcis; a good result can be obtained, however, by a large tube inserted in the posterior end of the incision. The flaps are coapted by six or eight stout silkworm-gut sutures inserted deeply through the tissues, and reinforced by a continuous suture of fairly stout silk or silkworm-gut.

An ordinary stump bandage should be applied, and fairly firm pressure exerted over the end of it so as to obliterate the cavity made by the flaps. Farabeuf recommends that the knee should be bent, and the

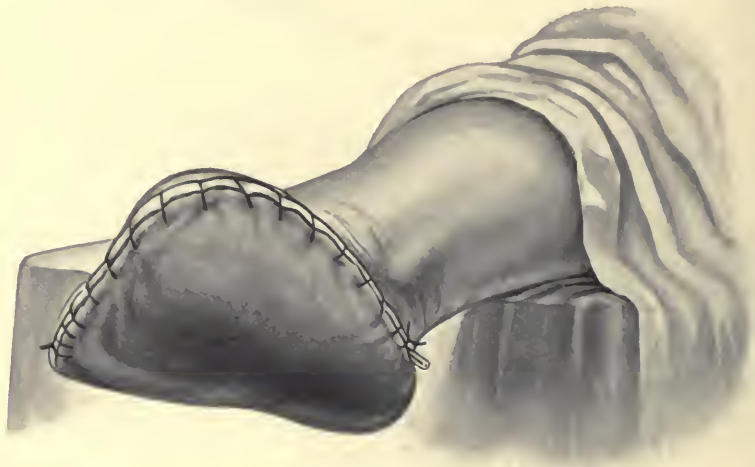

FIG. 92. STUMP LEFT AFTER FARABEUf'S SUB-ASTRAGALOID DISARTICULATION. In this instance the drainage tube has been inserted in the posterior end of the wound. For drainage in fat subjects it is certainly better to puncture the cavity left by the removal of the os calcis at its most dependent spot.

limb laid upon its outer side. If this be done, the limb should be immobilized by being laid between sand-bags, as otherwise painful startings of the stump are likely to occur. No splint is necessary.

The stump should be dressed at the end of three days, and the drainage tube removed. At this time it is well to fasten on the under dressings with collodion, which should be applied as shown in Fig. 93, so as to press the flaps firmly together. The deep sutures should remain undisturbed for a fortnight or three weeks, unless they cause irritation. The superficial continuous suture may be taken out on the tenth day. The flaps are supported by a firm bandage, and the patient may begin to bear pressure upon the stump in about a month, and may be fitted with an artificial foot in about six or eight weeks' time.

The advantage of Farabeuf's operation lies not only in the excellence of the resulting stump, an example of which is seen in Fig. 92, but in the ease with which disarticulation is performed. The chief difficulty for a beginner is to remember the incision, which, however, soon disappears when the operation has been practised a few times on the dead subject. The operation can be done rapidly and is not nearly so tedious as a Syme. It is easier to perform than any other sub-astragaloid disarticulation with which I am acquainted, and it should therefore be made use of whenever the condition of the soft parts permits. It may happen, however, that the tissues on the inner side of the foot are not

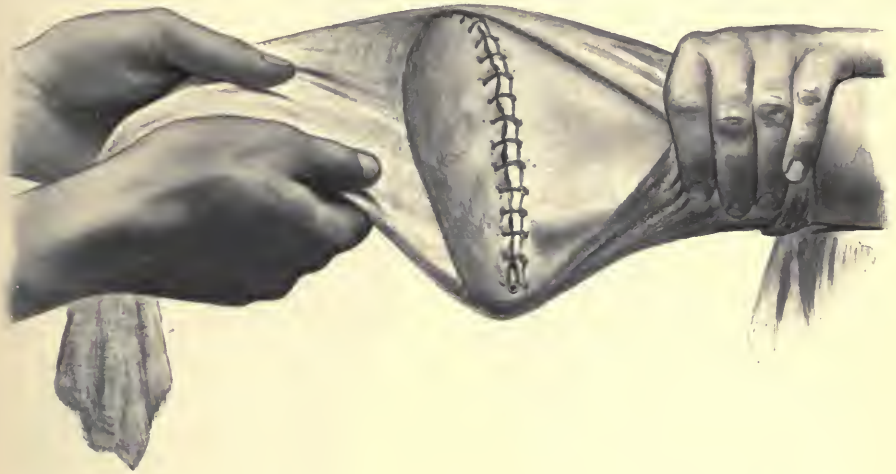

FIG. 93. METHOD OF APPLYING DRESSINGS TO THE STUMP OF FARABEU'S SUB-ASTRAGALOID DISARTICULATION. If the dressing be first applied to the hinge-side of the flap and brought firmly across it as shown in the drawing, it helps to keep the flap well in position.

sound enough to warrant it being done in all the cases in which a sub-astragaloid disarticulation is considered desirable, and therefore the reader should familiarize himself with modifications of this most useful operation. The following are the principal :—

Nélaton's operation. The incision is begun near the posterior end of the outer surface of the os calcis near its upper border, and carried forward a finger's breadth below the external malleolus nearly as far as the tuberosity of the fifth metatarsal bone. It then curves across the dorsum of the foot with its convexity forwards and runs somewhat backwards to the tuberosity of the scaphoid, whence it is carried downwards and forwards, crossing the inner border of the sole on a level with the fifth metatarsal bone, and is finally carried right across the sole on that level

so as to form a plantar flap with its convexity forwards. When it reaches the outer border of the foot it is carried back to its starting-point (see Fig. 94). The resulting flaps form a compromise between an antero-posterior flap and a racket amputation. Disarticulation is effected from the outer side, but is much hampered by the want of room, and the incision may have to be prolonged backwards over the tendo Achillis.

Roux's operation. This operation is hardly as satisfactory as the others, since it provides less suitable covering for the head of the astragalus. It commences at the outer tuberosity of the os calcis and is

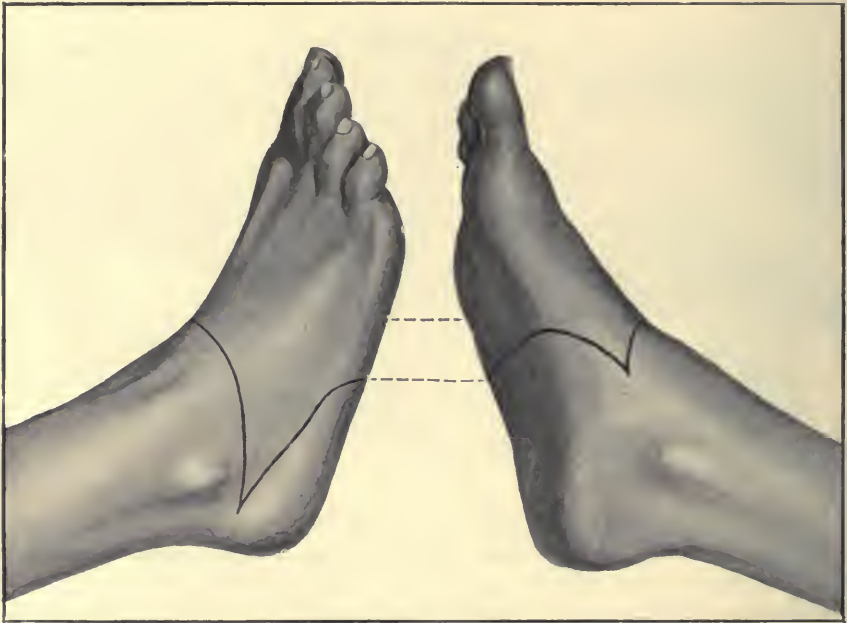


FIG. 94. INCISIONS FOR NÉLATON'S SUB-ASTRAGALOID DISARTICULATION.

carried horizontally forwards to the level of the base of the fifth metatarsal bone. Thence it runs across the instep with a slight convexity forwards to the middle of the inner surface of the internal cuneiform. From this point it curves backwards across the sole and round the outer border of the foot to its point of origin.

Racket incision. This is a simple and fairly satisfactory method, but the dissection required during disarticulation is more tedious than in Farabeuf's operation. The incision is carried horizontally forwards from the outer border of the insertion of the tendo Achillis, a full inch below the external malleolus, to the level of the prominence of the fifth

metatarsal bone. Thence it is carried across the instep with a slight convexity forwards and crosses the inner border of the foot on a level with the articulation between the first metatarsal and the internal cuneiform bones. It then traverses the sole with a slight convexity forwards, and is carried back to join the horizontal incision about one inch behind the base of the fifth metatarsal (see Fig. 95).

This incision facilitates the division of the tendo Achillis, but the flaps have to be raised very freely before disarticulation can be under-

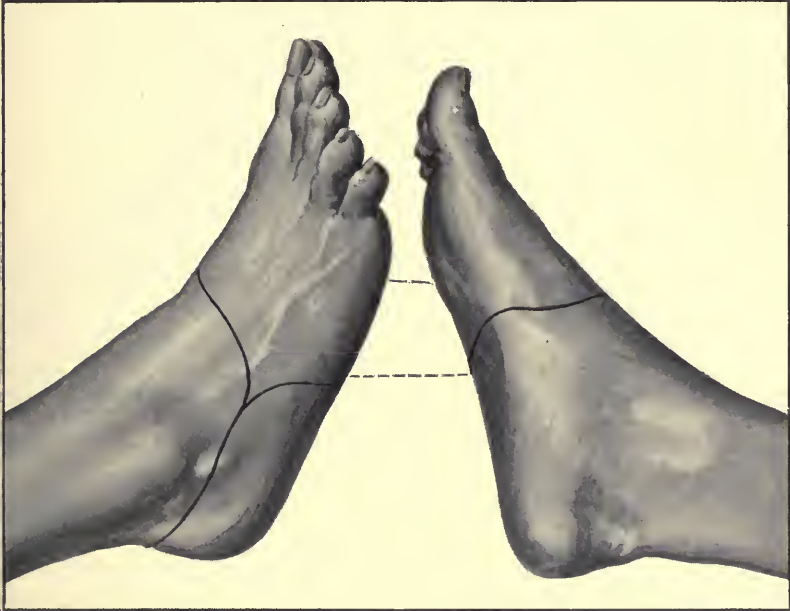


FIG. 95. RACKET INCISIONS FOR SUB-ASTRAGALOID DISARTICULATION.

taken, owing to the less free exposure of the parts. The important structures on the inner aspect of the foot are in greater danger of being wounded than in Farabeuf's method.

DISARTICULATION AT THE ANKLE-JOINT

Syme's amputation. The most useful type of this form of amputation is that known as Syme's, in which the amputation is done by means of a large heel flap. The operation is not a true disarticulation, inasmuch as the two malleoli are removed at the same time in order to obtain a level surface upon which the patient may bear his weight.

Indications. (i) The operation is an excellent one for an *injury* in

which the soft parts of the foot are damaged so far back that the sub-astragaloid disarticulation is not feasible.

(ii) For *disease* it will be rarely resorted to, the only affection for which it is likely to be really successful being a growth of the foot not involving the skin. In cases of tuberculous ankle-joint disease beyond the reach of cure by arthrectomy, the mischief will almost invariably have spread to the tendon sheaths, and the surgeon will be better advised, when he has decided that the disease is not likely to be cured by a careful and extensive arthrectomy accompanied by excision of the astragalus, to amputate above the ankle-joint. In gangrene of the lower extremity the defective blood-supply of the parts about the ankle will preclude its choice, whilst in septic infections that are not amenable to free incisions and drainage, amputation through the leg will probably also be the wiser course.

(iii) It may be used in cases of inveterate *talipes* due to infantile paralysis accompanied by trophic disturbances of the toes and front part of the foot. As this operation shortens the limb considerably and also provides a heel flap of doubtful vitality, some form of sub-astragaloid amputation or a trans-calcaneal operation is likely to prove more generally useful for these cases.

Operation. The foot is made to project well beyond the table and is held by an assistant with the toes pointing directly upwards so that the sole faces the operator ; the foot should be on a level with the surgeon's face whether he be sitting or standing. It is usual to do the operation sitting down, when the plantar flap is raised from below ; when, however, the flap is dissected up after disarticulation from above, it is done standing up, and on the whole it is better to perform the operation in that position. The surgeon faces the sole and places his left thumb and index finger upon the two ends of the incision for the heel flap, which extends from the tip of the external malleolus to a point about half an inch vertically below the tip of the internal malleolus ; when doing this the left hand is placed over the dorsum of the foot. In the left foot the incision commences on the outer side, whilst in the right foot it commences on the inner side. This incision runs down almost vertically across the sole (see Fig. 96) ; in ordinary subjects it should have a slight inclination backwards towards the point of the heel, but a marked one in those in whom the heel is large and prominent. It is important to see that the foot is strictly at right angles to the leg while the incision for the heel flap is being made. If this precaution be neglected and the toes be depressed, an incision, apparently running vertically downwards, really is directed obliquely forwards towards the toes, and the result is a large unwieldy heel flap that cannot be raised satisfactorily.

The incision is made by entering the point of the knife at the starting-point of the incision and carrying it down to the bone at once. The knife is then drawn across the sole with a steady sawing movement, and is made to divide all the soft structures right down to the os calcis at the

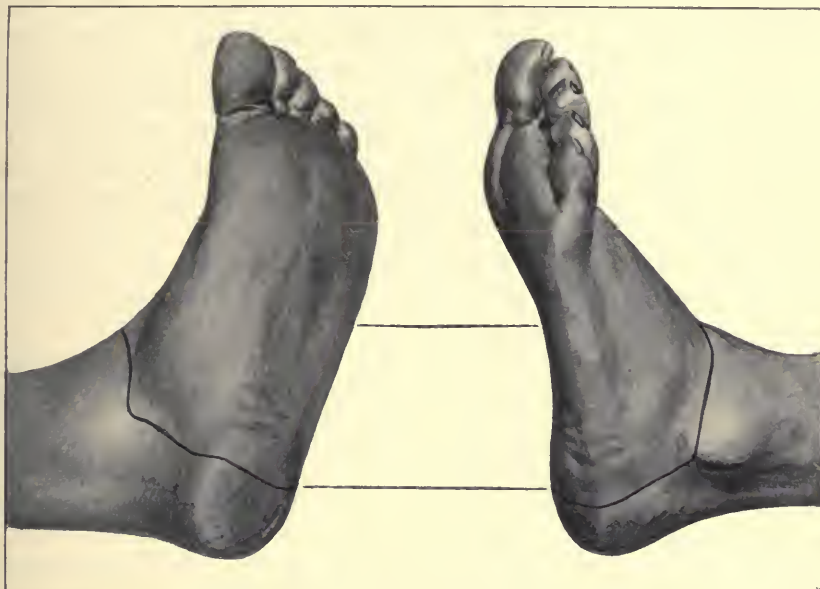


FIG. 96. INCISIONS FOR SYME'S DISARTICULATION AT THE ANKLE-JOINT.

first incision. As the knife nears the finishing point of the incision, great care must be taken that it does not slip, and it is well to use the special knife introduced by Syme, and known as Syme's foot knife (see Fig. 97). Unless the surgeon be very expert it is best to trace out only the first two-thirds of the incision and then to re-introduce the knife at



FIG. 97. SYME'S FOOT KNIFE.

the true point of termination, and cut downwards until the original incision is joined. A slip of the knife when terminating the incision is especially apt to be disastrous on the inner side, where the posterior tibial vessels may be wounded and the blood-supply of the flap seriously damaged.

The next step in the operation as recommended by Syme is to raise

the heel flap from the back of the os calcis (calcaneus) by dissection; this is a tedious and difficult procedure, and the operation can be much simplified by disarticulating from the front and dissecting the os calcis out of the flap instead of dissecting the flap off the os calcis.

Should the surgeon desire to raise the heel flap by dissection, however, he proceeds to do so by a series of short strokes, cutting steadily on the bone and using only the point and the terminal half-inch of the blade of the knife, commencing on the left-hand side of the limb as he faces it and working from left to right. As the flap is freed it is forced back by the left thumb, which serves to protect it from damage by the knife. Particular care must be taken to avoid damaging the posterior tibial vessels which lie in close proximity to the incision on the inner side. As soon as the flap has been freed in this situation it is a good plan to insert a flat retractor between the vessels and the bone, and to give this to an assistant, who thus keeps the vessels guarded from harm during the remainder of the operation.

The flap is gradually dissected up from the inferior and posterior surfaces of the os calcis as far as its upper border, the foot being raised by an assistant during the process. The tendo Achillis is not cut at this stage. It is practically imperative that the surgeon should sit during this very tedious part of the operation, but when the flap has been freed he stands up, grasps the foot in his left hand as shown in Fig. 80, and joins the two extremities of his first incision by a straight cut across the front of the ankle-joint, dividing the skin and fascia only. Before this incision is made, the line of the ankle-joint should be ascertained by flexing and extending the limb, as otherwise the incision may be too low and the astragalo-scaploid (talo-navicular) joint may be opened by mistake. The tendons and the anterior ligament of the ankle-joint are now divided on a level with the edge of the divided skin, and then the remaining fibres of the lateral ligaments are divided by the point of the knife, which should be inserted beneath them—namely, between them and the bone—and made to cut outwards. The heel flap is held back out of the way while this is being done. Disarticulation is completed by dividing the posterior ligament and the tendo Achillis.

A much less tedious method is to make the dorsal incision immediately after the plantar and to effect the disarticulation from the front. After the surgeon has made the dorsal incision with the precautions given above, he divides the extensor tendons and opens the ankle-joint. The toes are now depressed and the lateral ligaments divided, the internal first, by inserting the point of the knife between them and the bone and cutting outwards. As the ligaments are divided, the upper surface of the astragalus is rendered prominent by depressing the toes forcibly, and

the knife divides the posterior ligament of the ankle-joint and the tendo Achillis, and dissects the back part of the os calcis out of the soft parts forming the heel. This dissection must be done with every précaution against damaging the vessels and nerves on the inner side just behind the junction of the dorsal with the plantar flap. There is no risk of wounding these structures if only the point of the knife be used and every cut be made directly down upon the bone. The most difficult part of the operation is dissecting the back part of the os calcis out of the heel, owing to the intimate connexion of the soft parts with the underlying bone. It is facilitated by pushing the point of the heel firmly forward with the first two fingers of the left hand, which grasps and manipulates the foot throughout the disarticulation.

After disarticulation, the soft parts are dissected up for a short distance from the lower end of the tibio-fibular arch so as to facilitate the removal of the malleoli. The soft parts need only be detached for about a quarter of an inch up from the articular edge, but care must be taken to see that the heel flap is not doubled upon itself and button-holed while this is being done. The saw is applied to the base of the malleoli so as to remove them, and with them just enough of the cartilage-covered surface of the tibia to furnish a horizontal surface upon which the patient's weight can be borne. It is unnecessary to remove the whole of the cartilage of the tibio-fibular arch.

The final steps of the operation are ligature of the vessels, viz. the dorsalis pedis in the front flap and the two plantar arteries on the inner side of the heel flap, and the removal with scissors of any tendons visible on the stump; a portion of the posterior tibial nerve should also be removed. The heel flap is punctured about its centre and a small drainage tube is inserted through it. The flap is then secured in position by four stout silkworm-gut sutures introduced deeply and reinforced by a continuous stitch for the coaptation of the skin edges. The dressings are applied first along the back of the leg and then stretched across the end of the stump and carried up along the front of the leg so as to press the flap firmly in contact with the lower end of the bones. The method of dressing and after-treatment are practically identical with that for the sub-astragaloid disarticulation (see p. 186).

Results. The stump is one of the best known to surgeons. It is firm and will stand any reasonable amount of pressure, and the patient can run and jump without difficulty. He can generally begin to bear pressure on it in about six weeks, and may be fitted with an artificial foot in about two months after operation.

Difficulties. These have been already indicated in describing the operation. The first difficulty is planning the incisions properly. If

the foot be pointed and the fact pass unnoticed, both the dorsal and plantar incisions will be wrongly placed, the former being over the neck of the astragalus, whilst the latter will run too far forward and will make the heel flap so large that it cannot be retracted without great difficulty and much bruising. On no account should the incision on the inner side be carried behind the tip of the internal malleolus ; if this be done, the trunk of the posterior tibial artery will almost certainly be wounded.

The only other difficulties occur during disarticulation and are both avoided by keeping the knife close to the bone ; they are wounding the vessels in the inner side of the flap, and button-holing the skin at the back of the heel while the os calcis is being dissected out. During this part of the operation the foot should be kept pointing straight forward and not twisted from side to side as is commonly done ; any lateral displacement is likely to end in button-holing the skin.

When the soft parts over the back of the heel are damaged, it will be impossible to do Syme's amputation, and some other form of disarticulation must be used. Disarticulation is always preferable to an amputation through the lower end of the leg if it can be done, as the ability to bear his full weight upon the stump is a matter of great consideration to the patient.

There are two useful alternative operations to Syme's amputation. They are disarticulation by a large internal flap, and that known as Roux's operation, which is by means of a postero-internal flap. The incisions for both these operations are really only modifications of those for the sub-astragaloid amputations, the first resembling Farabeuf's, the second the racket method.

Operation by a large internal flap. This is really an improvement by Farabeuf upon the internal flap method of Sédillot, and the incision is practically identical with that of Farabeuf's sub-astragaloid disarticulation, except that it is not carried so far forward. It is a useful and simple method and is not so tedious to perform as Syme's amputation, and in this respect is undoubtedly superior to it. It is, moreover, hardly at all inferior to Syme's in the capability of the stump to bear any ordinary amount of pressure. The flap is thick and well nourished and the tendo Achillis is adherent to it ; it is easier to raise than the flap in Syme's amputation. It is described here as an alternative operation to Syme's as it is not likely to be suitable for cases in which it is essential to do the latter.

Operation. The position of the limb, &c., is the same as for the sub-astragaloid disarticulation (see p. 179). *On the left foot* the incision is commenced over the tendon of the extensor hallucis longus, just behind the tubercle of the scaphoid, and is carried out over the dorsum for about

two inches, when it curves back towards the external malleolus, immediately beneath which it passes horizontally back to the outer border of the tendo Achillis near its insertion into the os calcis. The knife is then entered again over the tendon of the extensor hallucis longus, and carried down across the inner border of the foot to the centre of the sole on a level with the articulation between the scaphoid and the internal cuneiform. Thence the incision curves backwards to the outer border of the foot, along which it is carried as far as the back of the heel, when it runs upwards to join the first incision (see Fig. 98).

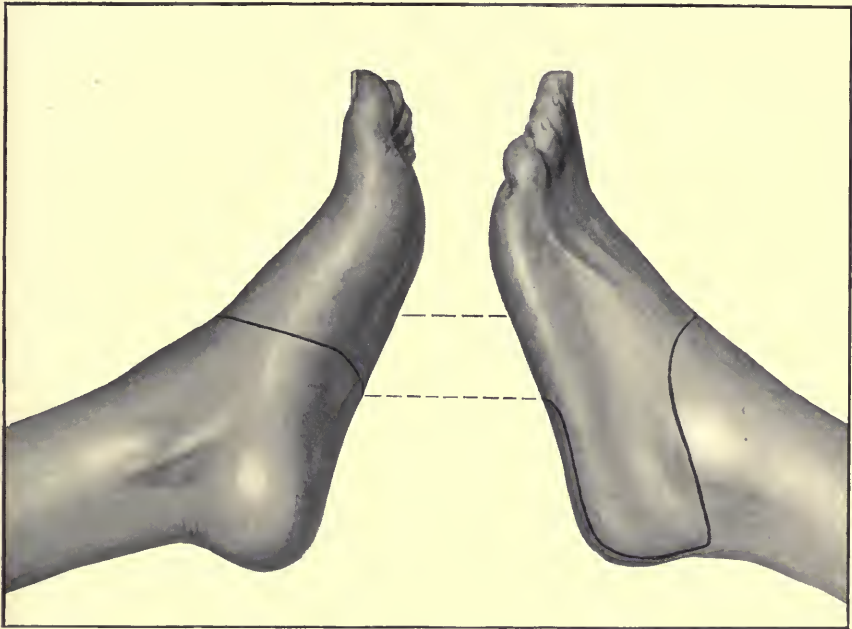


FIG. 98. DISARTICULATION AT THE ANKLE BY A POSTERO-INTERNAL FLAP.

The foot is now held in the same position as for the sub-astragaloid disarticulation (see p. 183). The parts in the dorsal incision are divided down to the bone, and the upper lip of the incision is raised until the external malleolus is seen and the ankle-joint is rendered accessible. The external lateral ligament is divided in front and behind it, while the foot is bent downwards so as to open up the joint freely; the tendo Achillis is also cut. The astragalus is forced well out of the tibio-fibular arch, and the internal lateral ligament is divided from the inner side. The final steps of the operation are identical with those of the sub-astragaloid amputation. After disarticulation the malleoli are cleared and sawn, as in Syme's amputation (see p. 193).

On the right side the incision commences at the outer border of the tendo Achillis, and runs parallel to the outer border of the foot and just beneath the tip of the external malleolus as far forward as the mid-point between the malleolus and the tip of the fifth metatarsal bone, when it curves inwards across the dorsum as far as the tendon of the extensor hallucis longus, about half an inch behind the tubercle of the scaphoid. The foot is then turned over to the left, and the incision is carried across the inner border of the foot with a slight convexity forwards on a level with the articulation between the scaphoid and the cuneiform bones. From this point it runs to the centre of the sole, and then curves back to the outer border, along which it runs as far as the external tuberosity of the os calcis, whence it is carried upwards to join the commencement of the first incision.

The Racket method (large postero-internal flap). This is the operation that is called by the name of Roux. The incision runs from the outer border of the tendo Achillis horizontally forwards about half an inch below the external malleolus until it reaches the mid-point between that structure and the base of the fifth metatarsal; then it curves forwards over the dorsum, crosses the inner side of the foot just in front of the tuberosity of the scaphoid, and thence runs transversely across the sole to the tuberosity of the fifth metatarsal. From this point it curves gradually backwards to join the commencement of the first incision. The incision goes down to bone throughout, and each edge of it is dissected up in turn as far back as possible; it is more difficult to raise the flaps sufficiently from the lateral surfaces of the os calcis in this operation than in the one just described. After the flaps have been raised as far as possible, the ankle-joint is opened from the front and outer side, and the removal of the foot is effected by a procedure similar to that just described (*vide supra*). The internal lateral ligament is divided from its inner aspect, and the edge of the knife is kept closely in contact with the bone while the latter is being dissected out of the flap.

A tourniquet round the middle of the thigh is used in Syme's and all similar operations.

TRANS-CALCANEAL AMPUTATIONS

Pirogoff's amputation. The only important objection to Syme's amputation is that it shortens the limb, and a number of operations have therefore been devised with the object of retaining some portion of the os calcis, which is subsequently united to the cut surfaces of the tibia and fibula, thereby reducing the shortening to a minimum; at the same

time this allows the patient to bear his weight upon the part of the heel that is intended to support it in the natural state. In the pre-antiseptic days Pirogoff's operation was strongly recommended in preference to Syme's because of the risk of septic infection followed by sloughing of the flap that so often accompanied the latter. Such an accident was very serious owing to bruising of the flap while it was being raised, the narrowness of its base, its indifferent blood-supply, and the cavity left in the stump in which the discharges collected. These risks, however, have no weight at the present day, and as the shortening of the limb after Syme's amputation is of little consequence when compared with

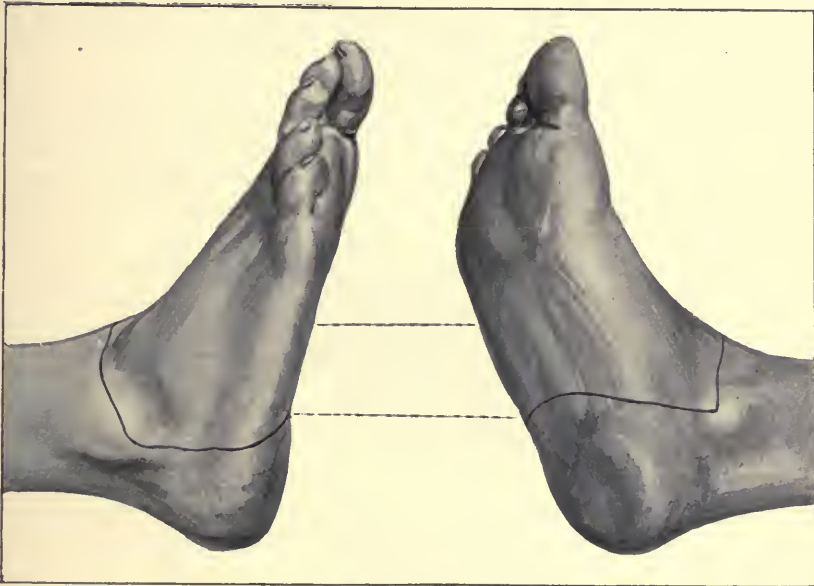


FIG. 99. INCISIONS FOR PIROGOFF'S AMPUTATION.

the excellence of the stump it provides, and as experience shows that the functional results of Pirogoff's amputation are not nearly so uniformly good as those after Syme's, the former operation has fallen steadily into disuse, and it is now rather a dissecting-room exercise than an operation of actual practice. It requires an exceptionally neat piece of carpentry to cut the bone surfaces so as to make sure that the patient shall bear his weight upon the tuberosities of the os calcis when the cut surfaces are put in apposition, and, even if the section has been accurately made, it is not always possible to secure bony union; if this fails, severe neuralgia and a painful stump are likely to occur. Moreover, neither Pirogoff's amputation nor any of its modifications is suitable

for cases of tuberculous disease, as recurrence would almost certainly take place.

Operation. The position of the limb is similar to that in Syme's amputation, and a tourniquet is applied to the thigh about its centre. The incisions also are similar, except that the one crossing the sole is directed forwards towards the toes instead of vertically down in the continuation of the long axis of the leg. The soft parts are incised down to the bone and the heel flap is dissected up for an inch and the skin allowed to retract. The joint is opened from the front by the incision across the dorsum (see Fig. 99), and the lateral ligaments are divided, the front of the foot being firmly depressed until the astragalus protrudes from beneath the tibio-fibular arch, and the upper surface of the os calcis behind it is brought into view.

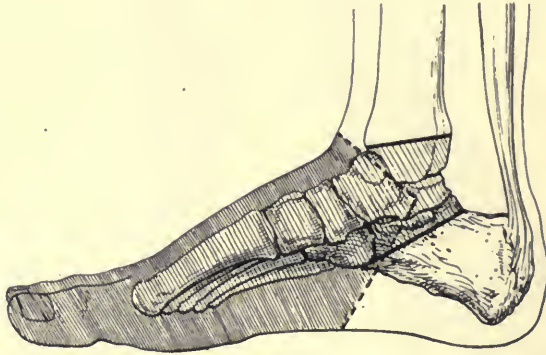


FIG. 100. LINES OF BONE SECTION IN PIROGOFF'S AMPUTATION. It will be seen that the two incisions through the bone are nearly parallel. The dotted lines represent the skin incision, and the shaded portion denotes the bones and soft parts that are removed in the amputation.

The saw is applied to the os calcis immediately behind the posterior articular surface, and the bone is divided from behind obliquely forwards and downwards along the line of the plantar incision through the soft parts. After the foot has been removed thus, the malleoli are cleared, and the lower end of the tibio-fibular arch is sawn through from the front obliquely upwards and backwards in a direction nearly parallel to the saw cut in the os calcis. Unless the two incisions are almost parallel the two bony surfaces will not fit accurately (see Fig. 100).

The cut surface of the os calcis is now applied to the cut surfaces of the tibia and fibula, and is kept in position either by a few stout sutures going through the periosteum of the two adjacent bony surfaces, or, if preferred, by mechanical means such as wires, pegs, tacks, or screws. No drainage tube is required, and the dressings are applied as in

Syme's amputation. The position of the posterior part of the os calcis in a properly performed amputation is shown in Fig. 101.

Other trans-calcaneal operations. Numerous modifications of this opera-

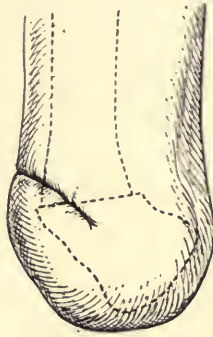


FIG. 101. THE STUMP AFTER PIROGOFF'S AMPUTATION. The dotted lines show the position of the bones after they are united. If this be compared with the preceding figure it will be seen that the patient walks nearly upon the same portion of the heel as before the operation.

tion have been devised with the object of replacing Pirogoff's oblique section through the os calcis by a horizontal or a vertical one. The latter is a very bad plan and needs no further description ; after the

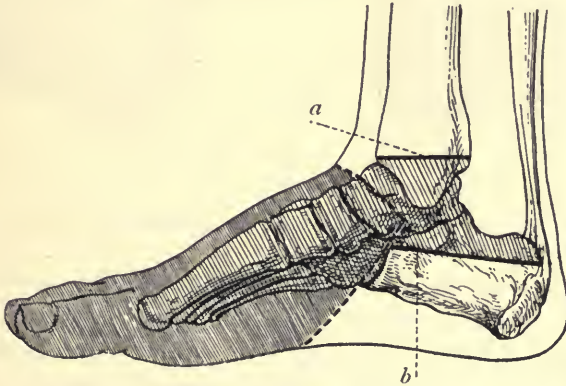


FIG. 102. LE FORT'S AMPUTATION. The thick dark lines *a* and *b* denote the lines of bone section ; the shaded portions are the parts of the foot removed in the amputation.

operation the patient would walk on the posterior surface of the os calcis, which is not calculated to bear weight and is likely to give rise to trouble.

Le Fort's operation. The best known trans-calcaneal amputation with horizontal division of the os calcis is the one that goes by the name

of Le Fort ; the line of bone section runs horizontally below the sustentaculum tali (see Fig. 102). Although theoretically this is a good operation, inasmuch as it does not oblige the surgeon to make an oblique bone section through both os calcis and tibia and fibula, and inasmuch also as it gives a wide bone surface for union, yet it is difficult to perform, and offers no points of importance justifying its description here.

Gordon Watson's modification. Mr. C. Gordon Watson showed at the Clinical Society on April 24, 1907, two cases on which he had performed a trans-calcaneal amputation of the foot, which is a considerable improvement upon Pirogoff's amputation and an advance upon that practised

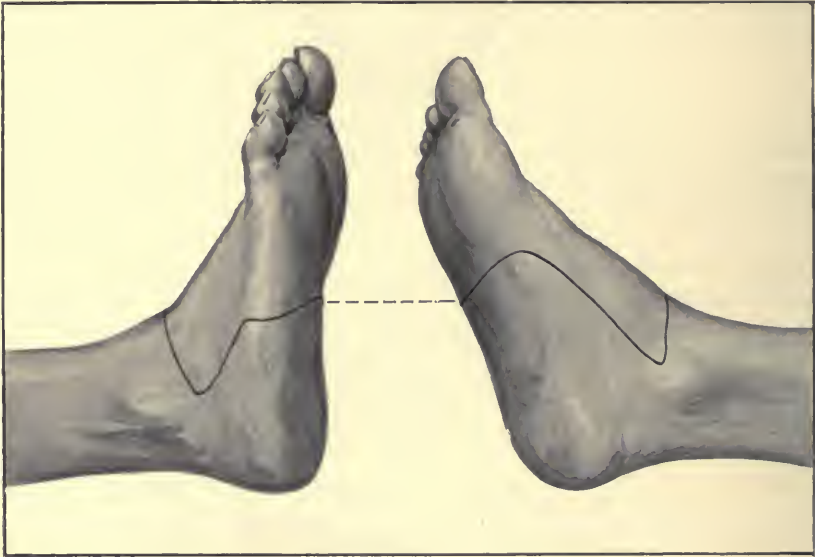


FIG. 103. INCISIONS FOR GORDON WATSON'S AMPUTATION.

by Le Fort. It provides the patient with a sound stump capable of bearing his full weight, while the shortening of the limb is reduced to a minimum. Moreover, the weight of the limb is borne upon the heel in its normal position—a result that cannot always be obtained in Pirogoff's amputation. Le Fort's operation aims at the same results, but it is easier to obtain them by Mr. Gordon Watson's amputation, and in the latter operation there is also less bone removed than in Le Fort's.

The operation is done as follows:—A dorsal flap, extending from a point half an inch below and behind the tip of the internal malleolus to the tip of the external malleolus, is made by a bold downward sweep an inch and a half below the line joining the tips of the two malleoli across the dorsum (see Fig. 103). The plantar flap is marked out by an

incision through the skin only, extending from one extremity of the dorsal flap downwards and forwards to half an inch in front of the prominence of the scaphoid on the inner side, or half an inch in front of the base of the fifth metatarsal on the outer side, and transversely across the sole of the foot between these two points.

The dorsal flap is dissected up, the soft parts are divided, and the ankle-joint is opened from the front as in doing Pirogoff's amputation. The foot is now firmly depressed, and the attachments of the internal lateral ligament to the astragalus are divided with the point of the knife, and the anterior fasciculi of the external ligament are similarly treated.

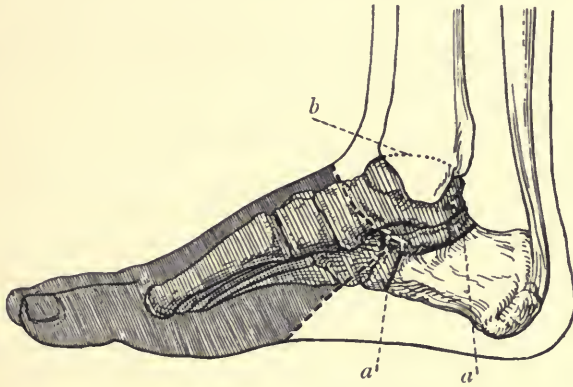


FIG. 104. GORDON WATSON'S TRANS-CALCANEAL AMPUTATION. The thick black line *a-a* is the section of the os calcis corresponding roughly to the articular surfaces. The dotted line *b* is intended to denote the level at which the articular cartilage is removed from the under surface of the tibio-fibular arch. The shaded portions are the parts removed.

The foot is next inverted forcibly and the point of the knife is passed between the os calcis and the astragalus, and divides the interosseous ligament and also opens the astragalo-scapoid joint, and frees the head of the astragalus from the scaphoid. This enables the astragalus to be seized in lion forceps and twisted so as to put on the stretch the posterior fasciculus of the external lateral ligament and the posterior ligament, both of which are divided; the astragalus is then removed.

The only thing that now prevents the os calcis from being brought up into contact with the under surface of the tibia is the projecting sustentaculum tali, which comes into contact with the internal malleolus. The former structure is cut away freely with a chisel or gouge until the upper surface of the os calcis lies close against the under surface of the tibio-fibular arch, and the next step is to clear the articular surfaces of the os calcis, tibia, and fibula of cartilage with a gouge or chisel.

The surfaces are so fashioned that the bony surfaces fit accurately when the foot is at right angles to the leg (see Fig. 104).

Up to this point the connexions of the front of the foot with the os calcis have been left undisturbed, so as to facilitate manipulation, but the operation is now completed by opening the calcaneo-cuboid articulation and separating the foot by cutting obliquely through the soft tissues of the sole from above downwards to the margin of the plantar flap already marked out. Finally, about half an inch of the anterior end of the os calcis is removed with a chisel, and this bone is brought up into apposition with the raw surfaces of the tibia and fibula, and fixed there by some suitable means, such as a long pin traversing the whole thickness of the os calcis and left projecting through the skin, to be removed when union has taken place. Any other means of fixation may of course be made use of.

In Mr. Gordon Watson's cases the amputation was done for severe long-standing talipes equinus due to infantile paralysis, and consequently it was impossible to bring the os calcis into position at right angles to the leg without dividing the tendo Achillis and the contracted tissues around it. When the flaps are brought together, the long plantar flap folds up over the anterior end of the os calcis, and the cicatrix is drawn up slightly upon the dorsal surface where it is out of reach of pressure.

The flaps are sutured in the ordinary way, and it is a good plan to put the limb up in plaster for a fortnight, when the stitches and the pins, if they are projecting as described above, may be removed. The plaster is then re-applied and kept on until firm bony union has occurred, the patient meanwhile walking upon the bent knee on a peg-leg. Neither of Mr. Gordon Watson's patients was allowed to put the foot to the ground for three months, but so long a period of rest will probably not be necessary when the nutrition of the parts is good.

The resulting stumps were excellent in all respects; the patients could walk, run, and jump upon them without the least inconvenience. The operation certainly deserves an extended trial.

CHAPTER VII

AMPUTATIONS OF THE LEG AND KNEE

AMPUTATIONS THROUGH THE LEG

WHEREAS formerly it was the custom not to amputate between the lower end of the tibia and 'the seat of election'—viz. a hand's breadth below the top of the tibia—it is now the custom to apply to the leg the same rule as to the arm, and to amputate as low down the limb as the condition of the parts permit. There are many reasons why this should be so. The lower the amputation is practised, the less are the risks, immediate and remote, that the patient runs, and the longer the leverage below the knee the more useful is the artificial limb; provided therefore that the latter can be fitted so as to cause neither pressure upon the end of the stump nor undue friction upon its anterior surface, the surgeon should amputate as low down the limb as possible.

There are cases, however, in which it is still preferable to amputate at 'the seat of election'. As its name implies, this is the spot at which the surgeon, with the whole length of the limb at his disposal for an amputation, elected to do the operation, and his preference for this particular spot was largely due to the manufacture of artificial limbs being so unsatisfactory that the patient always had to bear his weight upon the bent knee; it was therefore an advantage that the portion of the limb remaining below the knee-joint should be as short as possible, so as to prevent an unsightly projection from the artificial limb. Another reason for choosing this spot was that the blood-supply to the flaps was ample, and therefore there was less chance of sloughing if sepsis supervened. At the present day it is better to amputate at 'the seat of election' for labouring men and all those who have to follow laborious occupations and are unable to afford a well-fitting artificial limb. In such cases a peg-leg allows them to follow their employment, and the stump is little likely to be exposed to injury even under the most adverse conditions.

The performance of an amputation through the leg is accompanied by certain difficulties, largely attributable to the anatomical conformation of the parts. The flaps must be planned so that the cicatrix does not fall over the end of the bones, for, although the pressure is only rarely

borne directly upon the end of the stump in the artificial limb, yet the bone has a constant tendency to be pressed down against the end of the stump, and a painful and adherent cicatrix is likely to occur should the latter be terminal. Again, the sharp subcutaneous border of the tibia may give rise to irritation from pressure against the artificial limb, and must therefore always be bevelled off so as to avoid this. The tapering contour of the limb makes it important to exercise much care in cutting the flaps, as a conical stump due to short flaps is a dire misfortune in the lower extremity. Rectangular flaps, therefore, which measure half the circumference of the limb across their base ought, if properly cut, to measure more than half the circumference of the limb across their extremity, a point often forgotten when operating upon the dead subject, with the result that tapering and ill-fitting flaps are constantly produced. The flaps are somewhat difficult to raise when it is desired to take up the muscles with them, as the anterior muscles of the leg are wedged in deeply between the tibia and the fibula and cannot be cut by transfixion; moreover, the anterior tibial artery, which supplies the anterior flap, lies deeply down on the interosseous membrane, and is easily wounded when the anterior flap is being raised. The posterior muscles, however, can be cut by transfixion, and, since they retract much more freely than those on the anterior surface, they should be cut as low down as possible, in order that the amount of retraction on the two sides shall be equal. Owing to the greater power of the posterior muscles they always pull the posterior flap backwards, at any rate when the amputation is below the centre of the leg. Therefore the cicatrix must lie well up on the front of the leg if the amputation has been done by a long posterior flap; when possible, however, it is well to cover the end of the stump with a flap derived from the surface that is most calculated to bear pressure.

In an amputation through the leg below 'the seat of election' the weight is borne by the expanded upper end of the tibia, which fits into a conical socket accurately moulded to it. A certain amount of pressure can be borne directly upon the end of the stump when the amputation is quite low down in the leg, *e.g.* in the supra-malleolar amputation; in none of the other amputations, however, is any direct pressure upon the end of the stump allowable. Instrument makers still object somewhat to a long stump on the ground that its end is apt to get fretted against the front of the apparatus in flexion and extension of the limb; this, however, is entirely a matter of proper fitting and should not weigh against the great advantage given to the patient by the increased leverage and usefulness of the limb. More attention should be devoted to the choice of the amputation in the lower extremity than has hitherto been

the case, as patients begin to realize that inability to walk comfortably afterwards is largely due to a defect in the operation.

Out of the numerous amputations that have been introduced the following have been selected as being most applicable to the various conditions likely to be met with in practice. They may be divided into three large groups, namely :—

(i) *Supra-malleolar amputations*, or all the amputations between the level of Syme's amputation and the junction of the lower with the middle third of the leg.

(ii) *Amputations in the middle of the leg*.

(iii) *Amputations at 'the seat of election'*—i. e. a hand's breadth below the top of the tibia.

In all these amputations the circulation is best controlled by the application of Esmarch's rubber tubing horizontally around the middle of the thigh.

Indications. (i) *The supra-malleolar amputations* are suitable for cases of injury in which the foot is extensively destroyed but the tissues over the region of the heel are sound. In these cases, however, it is likely that the surgeon will often be able to perform a Syme's amputation, which of course is better, inasmuch as it gives a longer stump and one better able to stand pressure.

The supra-malleolar amputation, however, possesses advantages over Syme's when the amputation is performed for tuberculous or other disease of the ankle-joint. The serious objection to Syme's amputation for these conditions is that in it it is difficult to be sure that the incisions have been carried beyond the limits of the disease, owing to the conformation of the joint and the presence of the tendon sheaths in close connexion with it. By a supra-malleolar amputation, however, the whole of the synovial membrane is removed along with the foot, and any diseased tendons or tendon sheaths are probably removed also, owing to the higher division of the soft parts ; in any case they can be dissected out with rapidity and certainty at the end of the operation.

(ii) *Amputations through the middle of the leg* will usually be done only for injury, and are chiefly used for compound fractures of the lower third of both bones. This amputation is too high up for tuberculous disease, and too low down for a growth of the bones ; it is perhaps the most difficult form of amputation of the leg to perform satisfactorily.

(iii) *Amputation at 'the seat of election'* is most suited for the working man who does not desire an artificial limb and wishes to engage in heavy labour with the least inconvenience. It is also used for compound fractures high up the limb, for extensive chronic ulcers which have resisted treatment, and for certain cases of long-standing infantile para-

lysis, accompanied by wasting of the entire limb, in which the nutrition of the parts is so feeble that an amputation lower down would be precarious. It may be done occasionally for gangrene of the toes when the local blood-supply is good enough to justify the surgeon in trying to save some part of the leg; it will rarely be employed for this affection, however, as the collateral circulation is seldom good enough.

SUPRA-MALLEOLAR AMPUTATION

By the oblique elliptical incision. This amputation is attributed by Farabeuf to Guyon, and really differs but slightly from Syme's

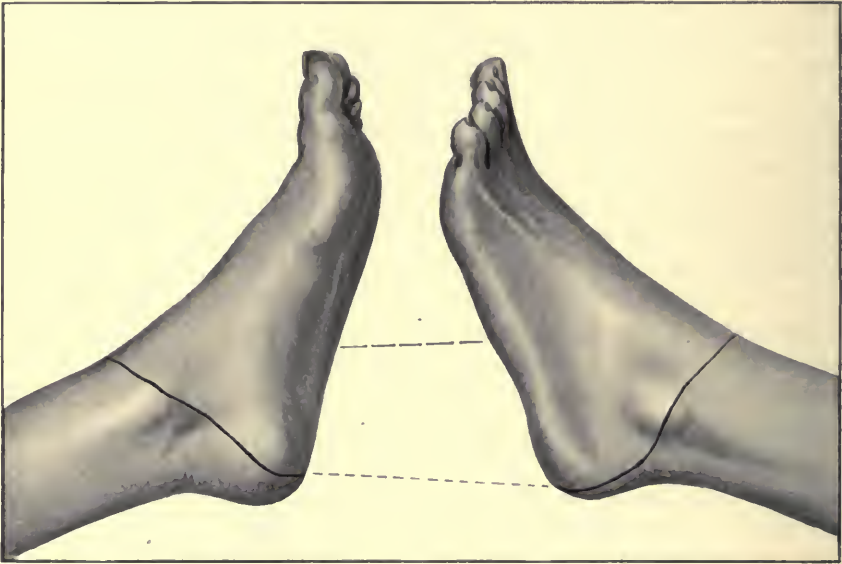


FIG. 105. SUPRA-MALLEOLAR AMPUTATION BY THE OBLIQUE INCISION.

amputation. The incision and the subsequent steps of the operation are very similar, the lower ends of the tibia and fibula being sawn an inch or more higher than in Syme's amputation. I have used the operation several times and can speak very highly of the excellence of the stump; the expanded end of the ends of the tibia and fibula furnish a firm base upon which the weight can be safely borne. The medullary canal is not opened unless the bone section be made considerably above the malleoli. The stump is covered by a flap taken from the posterior surface of the heel, which is well calculated to bear pressure.

Operation. The surgeon faces the sole of the foot, which should project well beyond the end of the table. He seizes the front part of the

foot in his left hand and turns it over to his right so as to commence the incision (see Fig. 105) at the convexity of the heel; this will therefore be begun on the outer side in the right foot, and on the inner in the left. From the point of the heel it is carried somewhat forwards and upwards until it is almost vertically below the tip of the internal malleolus on the left side, or the corresponding point half an inch in front of the outer malleolus on the right side. Thence it runs almost vertically up to the malleolus and then sweeps upwards and forwards across the front of the ankle-joint. The front of the foot is now turned over to the left, and a corresponding incision is traced on the opposite side of the foot

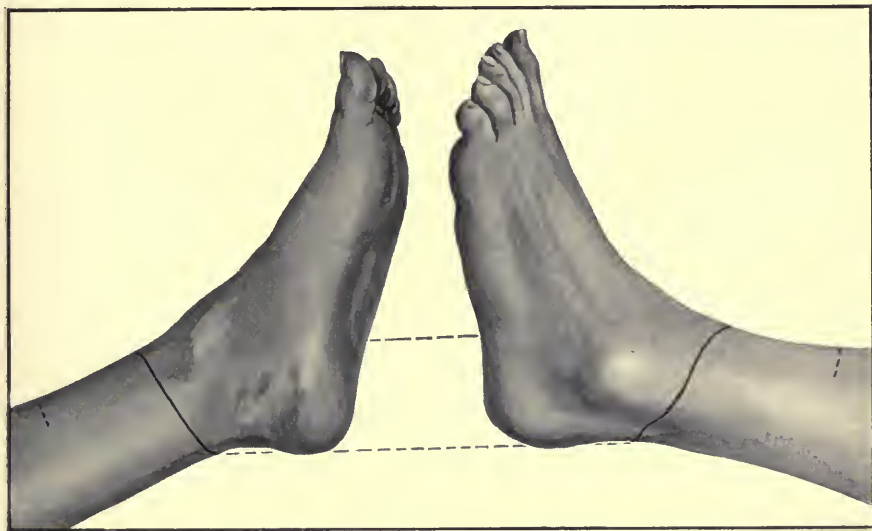


FIG. 106. MARCELLIN DUVAL'S AMPUTATION THROUGH THE LOWER THIRD OF THE LEG BY THE OBLIQUE INCISION. The dotted lines indicate the level upon which the bone is sawn.

until it meets the commencement of the previous one over the point of the heel. This gives an elliptical incision, the lateral appearance of which is somewhat like an italic letter *f*.

This incision goes through the skin only, which is allowed to retract, and the knife is then carried down to the bone all round on the level with the retracted skin. Instead of dissecting up the heel flap it is easier to open the ankle-joint and disarticulate from the front, as in Syme's amputation, and then to dissect out the os calcis from the flap (see p. 192). When this has been done, the lower ends of the tibia and fibula are cleared by dissecting up the soft parts for about two inches, making four subcutaneous incisions, one over each of the anterior and posterior surfaces

of the lower ends of the tibia and fibula, so as to raise the tendons and soft parts *en masse* from the bones, which are then cleaned and sawn transversely an inch or so above the level of the articulation. As a rule the bone section will be just where the bones are expanding to form the joint surfaces. The cicatrix will lie on the front of the limb above the line of the bone section. The after-treatment is the same as for Syme's amputation.

Another amputation by an oblique elliptical incision is that sometimes called by the name of Marcellin Duval, which is suitable for amputations rather higher up the limb than the one just mentioned. It is not such a good one as either this or the succeeding operation, as it gives a somewhat puckered cicatrix lying very near to the end of the bone; it is inapplicable to cases in which there is inflammatory matting of the soft parts.

The point of bone section is first fixed upon, and an oblique elliptical incision is traced out, the lowest level of which is at a distance below this point equal at least to the antero-posterior diameter of the limb at the level of bone section, and the upper limit of which is equal to half that distance below it. Looked at laterally, the line of incision crosses the vertical axis of the leg at an angle of about 45° (see Fig. 106). In estimating the distance which the incision should extend below the point of bone section, allowance has to be made for the retraction of the cut skin; therefore a full third must be added to allow for the shrinkage of the skin flap. The surgeon stands on the patient's right of the limb to be removed, viz. on the outer side of the right limb and on the inner side of the left. The leg is drawn well over the end of the table and is held horizontal by an assistant, who manipulates it as may be necessary during the course of the operation. The surgeon first marks out that portion of the incision which is on the side of the limb nearest to him, the foot being rotated away from him. He begins the incision from above downwards: when he has cut it on the side nearest him he bends over the limb (the foot being rotated towards him) and finishes the incision on the opposite side from below upwards.

After the skin has been allowed to retract, the cuff of skin is pulled well up and freed from the subcutaneous tissues by a few touches of the knife, the soft parts are divided right down to the bone close to the margin of the retracted skin, and the muscles are dissected up for a good half-inch or so beyond the proposed point of bone section. The bones are then divided and the projecting triangular subcutaneous edge of the tibia is removed (see Fig. 107), so as to avoid pressure against the flap. Any tendons are cut short, and an inch of the posterior tibial nerve is dissected out and removed. In bringing the flaps together one or two

of the deep tension sutures are made to penetrate the tendo Achillis, which is thereby assured of a firm hold upon the flap. A drainage tube should be put in the outer angle of the wound. The after-treatment is similar to that of Syme's amputation.

By a long posterior flap. This method presents advantages when the amputation has to be done rather higher up than in the previous cases, as the tapering contour of the limb renders it difficult to




FIG. 107. METHOD OF BEVELLING OFF THE SUBCUTANEOUS EDGE OF THE TIBIA. The oblique cut has been made, and the saw is dividing the bone transversely below it. As the latter crosses the oblique cut the small triangular portion is removed, and when the bone is severed it leaves the sharp subcutaneous margin of the tibia bevelled off.

get proper coaptation with an oblique elliptical incision. Moreover, when the amputation is done for inflammatory conditions the method of raising the flaps is superior to the sliding method employed in the elliptical incision.

There are many modifications of this operation, but the difference between them consists mainly of variations in the lengths of the anterior and posterior flaps respectively. If possible, an amputation by antero-

posterior flaps should have the posterior flap longer than the anterior, as the skin of the front of the leg is not so well calculated to bear pressure. The best form of amputation by unequal flaps, therefore, is that by a long posterior and short anterior.

Operation. The limb is brought well over the end of the table and the surgeon stands facing the foot. The left thumb and forefinger are placed respectively upon the centre of each lateral aspect of the limb opposite the point of bone section, and the incision begins just below this on the right side of the limb as the surgeon faces it. The knife is carried down the lateral aspect of the limb, on the one side just in front of the inner border of the tibia, and on the other immediately behind the fibula,

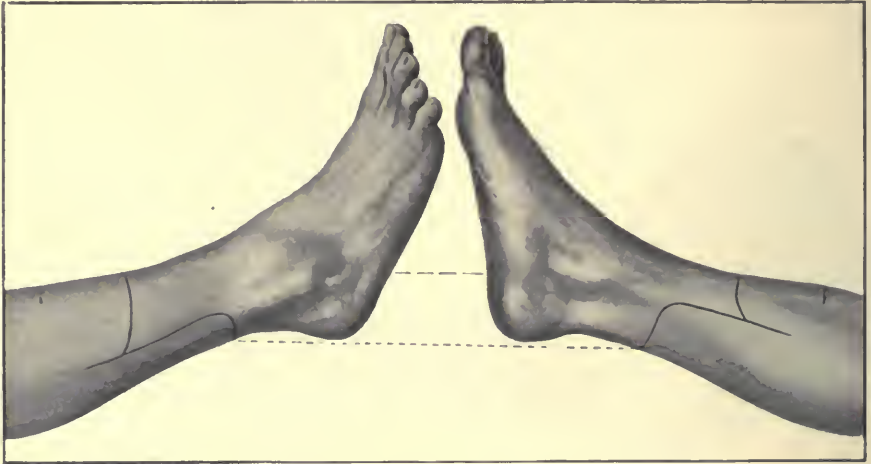

FIG. 108. AMPUTATION THROUGH THE LOWER THIRD OF THE LEG BY A LONG POSTERIOR FLAP. The level of the bone section is shown by the dotted line above.

for a distance corresponding to rather more than the antero-posterior diameter of the limb at the point of bone section. The incision must not be carried down the mid-line of the lateral aspect of the limb, as otherwise, owing to the tapering shape of the leg, the flap will be pointed instead of being rectangular; it must incline a little forwards. At the lower end of this incision the knife is carried transversely across the back of the limb for a distance equal to half the circumference of the limb at the point of bone section, and then vertically up on the opposite side of the limb to the point opposite that from which it started; the corners of the flap should be slightly rounded. It will be noticed that in cutting the flap in this operation the operator has to change his position; he first stands facing the sole, but, as the incision for the posterior flap

is traced out, he moves round until eventually he is on the side at which the incision ends; that is to say, he will eventually be on the patients' right of the limb operated upon. A large U-shaped flap is thus marked out on the back of the leg, and the incision is deepened all round so as to allow the skin to retract fully. The anterior incision is then marked out by drawing the knife transversely across the limb about two inches below the point of bone section (see Fig. 108).

The first step in raising the large posterior flap is to open the deep fascia throughout the posterior incision, and to insert the thumb and forefinger between the tendo Achillis and the bones, so that the former

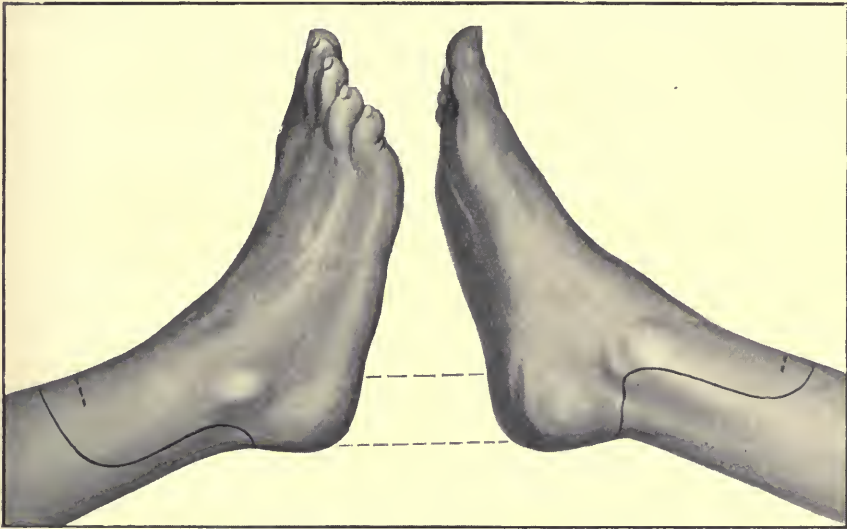


FIG. 109. AMPUTATION THROUGH THE LOWER THIRD OF THE LEG BY A SINGLE POSTERIOR FLAP. The level of the bone section is shown by the dotted line. In this case the cicatrix is placed so high up on the front of the bone that there is no risk of the pull of the calf muscles bringing it over the end of that structure.

structure can be pulled well away from them and divided from within outwards; the other muscles at the back of the leg are then treated similarly. The peronei muscles, however, should be divided down to the fibula close to the junction of the flaps. The anterior flap is then raised by dividing the deep fascia and the muscles down to the interosseous membrane on a level with the margin of the retracted skin, and raising all the muscles and the anterior tibial artery from the interosseous membrane and the bones. The flaps are well retracted, the interosseous membrane is divided and the bone sawn, the anterior margin of the tibia being bevelled off in the usual manner (see Fig. 107). The posterior

tibial nerve must be isolated and dissected out from the whole length of the flap, otherwise it will give rise to pain subsequently.

This operation has been modified by cutting the posterior flap still longer and providing no anterior flap at all (see Fig. 109). This method, by placing the scar well up on the front of the bone, guards against its being exposed to undue pressure, and may be called for when the tissues at the disposal of the operator are scanty in front; but otherwise the preceding method is preferable. Various other methods, such as a circular amputation or equal lateral flaps, have been practised, but should be avoided, as the cicatrix resulting therefrom falls directly over the end of the bones and a certain amount of pressure upon the scar is unavoidable. It is better to amputate higher up than to fashion a stump by these methods.

AMPUTATION THROUGH THE MIDDLE OF THE LEG

Amputations in this situation fell into disuse for a long time in favour of those at 'the seat of election', for the reasons already given (see p. 203). They are now becoming more popular, however, and should certainly be practised if occasion offers. In this situation, as in the supra-malleolar region, the flaps must be fashioned so that the cicatrix is not terminal, and therefore they must be unequal, the operation of choice being one with a long posterior and short anterior flap. The flaps should not consist merely of skin and the superficial structures, but should take up the muscles down to the bone together with the main vessels.

The operation that perhaps will be found best on the whole is that known as Hey's, consisting of a long posterior and a short anterior flap. The method of Teale, in which there is only a long anterior rectangular flap measuring half the circumference of the limb in length, is not to be recommended, as the extreme length of the flap entails division of the bone so high up that one of the methods previously recommended may well be applied, and the bone divided at a lower level. It will happen occasionally, however, that the covering for the stump must be obtained from the anterior surface of the limb, and in that case Lord Lister's modification of Teale's amputation gives a good result.

Amputation by a long posterior and short anterior flap (Hey's amputation). The limb is drawn over the end of the table as far as the knee, and the surgeon stands on the patient's right of the limb to be operated upon; the opposite limb is flexed at the knee and fastened down to the table. The point of bone section is fixed upon, and the antero-posterior diameter of the limb at that spot estimated, the incision beginning a good finger's breadth below this. The posterior

flap should be equal in length to this measurement, while the anterior will be one-third the length of the posterior. Both must be rectangular, and the transverse measurement at their lower extremities must be equal to that at their base. The flap is best cut by carrying down an incision on each side from a point a finger's breadth below the line of bone section and joining these by a transverse cut behind the limb, slightly rounding the corners in doing so. The anterior flap is marked out by

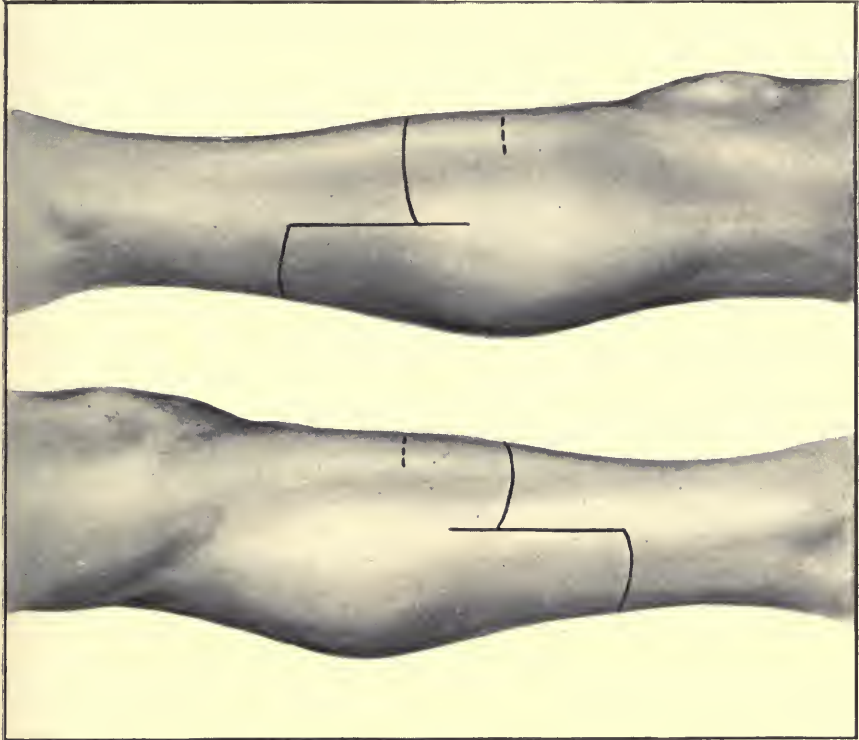


FIG. 110. HEY'S AMPUTATION THROUGH THE MIDDLE OF THE LEG. The dotted line indicates the level at which the bones are sawn.

drawing the knife across the front of the limb a third of the way down, slightly rounding the corners also (see Fig. 110).

The incision is carried through the deep fascia so as to allow the skin to retract freely, and the posterior flap is dissected up for about an inch and a half, taking skin and deep fascia only, before the muscles are divided. The easiest way to divide the muscles is to flex the knee almost to a right angle and rotate the limb away from the operator, so that it lies upon its side, and then to insert the thumb and forefinger between the gastrocnemius and the bone, pull the muscle away, and divide it by

oblique cuts from within outwards level with the margin of the retracted skin. Vertical incisions are then made through the deep fascia along the borders of the tibia and fibula, and the deep muscles on the back of the leg and the posterior tibial vessels are raised and pulled away from the bone with the fingers and the thumb, and cut at the same level from within outwards. All the soft parts are then raised to the level at which the bone is to be sawn, by means of the fingers and the handle of the knife. While this is being done, the foot should be raised so that the limb is nearly vertical. In the anterior flap the muscles and the anterior tibial artery are raised from the interosseous membrane and the bones by means of the fingers and handle of the knife, and are divided from within outwards and raised in one mass up to the level of the bone section.

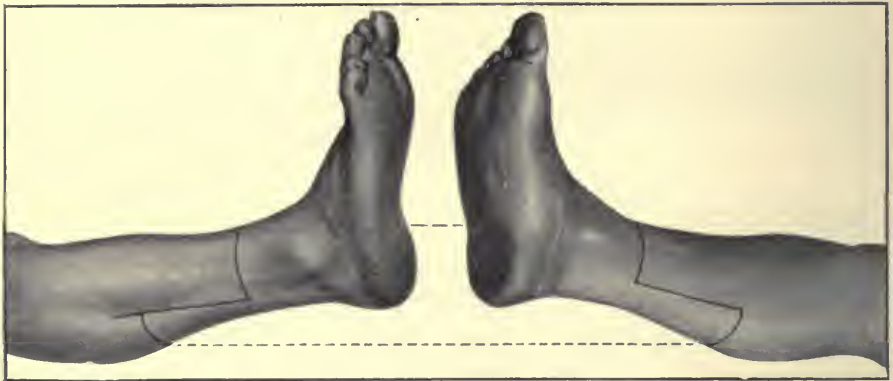

FIG. III. INCISIONS FOR LISTER'S AMPUTATION IN THE MIDDLE OF THE LEG.

The bones are then sawn, beginning and finishing as usual upon the tibia, the sharp anterior margin of which is bevelled in the usual manner (see Fig. 107).

The other operation by means of a large posterior flap in common use is that which goes by the name of Lee's operation, and which corresponds almost exactly to Teale's amputation, except that the long flap is on the posterior and not on the anterior aspect of the limb. The same objection applies to it as to Teale's amputation, viz. that it is unduly expensive, and that the adoption of some other amputation would enable the patient to preserve a longer stump.

Amputation by a single long anterior flap (Lister's operation). In order to overcome the objections to Teale's amputation, referred to above, Lord Lister devised the following operation (see Fig. III), which I have used on many occasions, and which provides

a very useful stump. His description of the operation is as follows (Holmes's *System of Surgery*, vol. iii, p. 717): 'Immediately above the ankle the operation is performed as follows. The diameter of the limb having been ascertained by spanning it, a straight longitudinal incision of that length is made on the inner side of the leg, and on the outer aspect another similar incision directly over the fibula and extending about an inch higher up. The lower ends of these incisions are connected by cutting across the front of the limb in a direction transverse in the main,

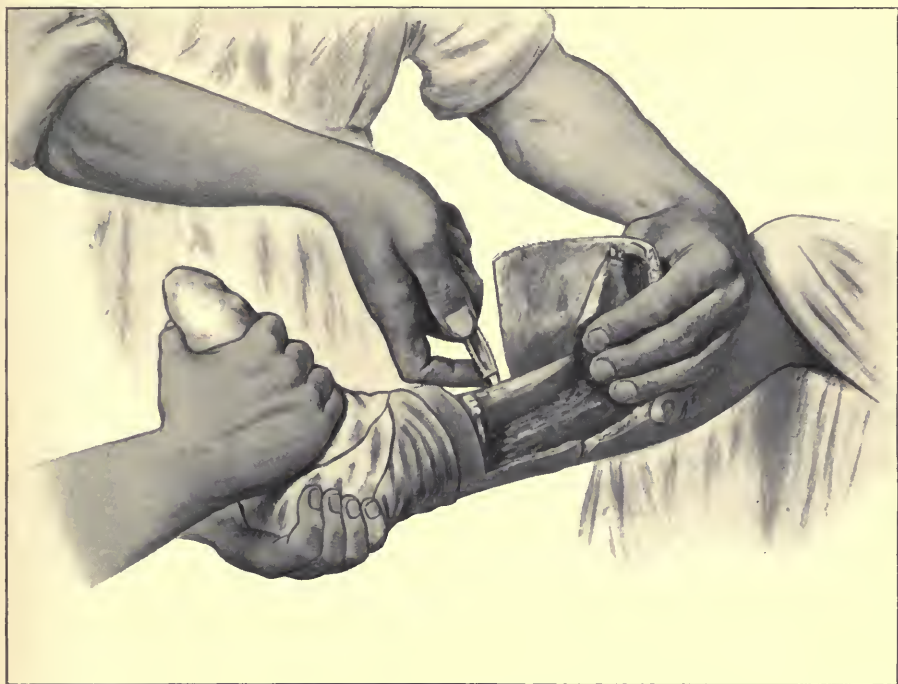

FIG. 112. LISTER'S AMPUTATION. CUTTING THE POSTERIOR FLAP. The figure shows the anterior flap raised with all the structures between the tibia and fibula right down to the interosseous membrane.

but rounded off where it joins the lateral lines. The knife is then carried round the back of the limb to the bones, from the upper end of the internal incision to a point exactly opposite on the outer side, which will be about an inch below the upper end of the outer incision; the instrument being carried in a line slightly convex downwards, so as to form a very short posterior flap. The anterior flap is then raised in the manner above mentioned, including everything in front of the bones and interosseous membrane, after which the tibia and fibula are cleared as high as the

level of the upper end of the outer incision, the finger-tip being still used in detaching the parts anterior to the interosseous membrane (see Fig. 112).

'In amputating through the calf on the same principle, the operation is similar, except that the anterior flap need not be longer than two-thirds of the diameter of the limb ; but, to compensate for its diminution, the posterior flap must be made at least half as long as the anterior, by carrying the knife round the back of the limb at an angle of forty-five degrees through the integuments, and dissecting them up to the level of the upper end of the inner part of the incision, before cutting towards the bones, so as to get rid of the heavy and contractile mass of the sural muscles.'

This amputation gives a good firm stump, although the flap is somewhat ungainly and difficult to suture. It is admirably adapted to bear pressure, and the cicatrix is pulled well up out of the way by the calf muscles, so that there is no fear of its adhesion to the ends of the bones. The drainage tube is inserted at the upper end of the outer incision. The outer incision is made to extend higher up than the inner in order to get over the difficulty of retracting the muscles from the fibula owing to their intimate attachment to it.

AMPUTATION AT 'THE SEAT OF ELECTION'

The explanation of this term has already been given (see p. 203). In these amputations 'the seat of election' refers to the line of bone section, which is a full hand's breadth below the top of the tibia ; in other words, nearly an inch below the tubercle of the tibia. This leaves a short portion of the leg below the knee-joint which can be moved freely, as the insertions of the quadriceps in front and the hamstrings and the popliteus behind are retained. Though flexion and extension of the joint are thus preserved, the stump is not long enough to cause any marked projection behind when the knee is flexed and the patient walks upon a peg-leg. It is perhaps the most useful stump for patients of the working class. Amputation in this situation has the further merit that it is not essential for the cicatrix to fall in any particular spot ; indeed, in one of the favourite methods, namely, that by equal lateral flaps, it is directly terminal, a matter of little or no importance if the patient bears his weight upon the bent knee. This amputation can thus be performed in cases in which the soft parts are damaged quite close up to the level of the proposed bone section. It possesses the further great advantage, that almost any method of amputation may be employed ; thus, equal or unequal antero-posterior or lateral flaps may be employed, or the

circular method may be used, or a single large flap may be fashioned either from the external or from the posterior surface. The three most generally useful methods are perhaps the circular method, that by equal lateral flaps, and that by the large external flap known by the name of Farabeuf.

The circular amputation. A tourniquet is applied round the middle of the thigh, the lower half of the thigh is made to project over the

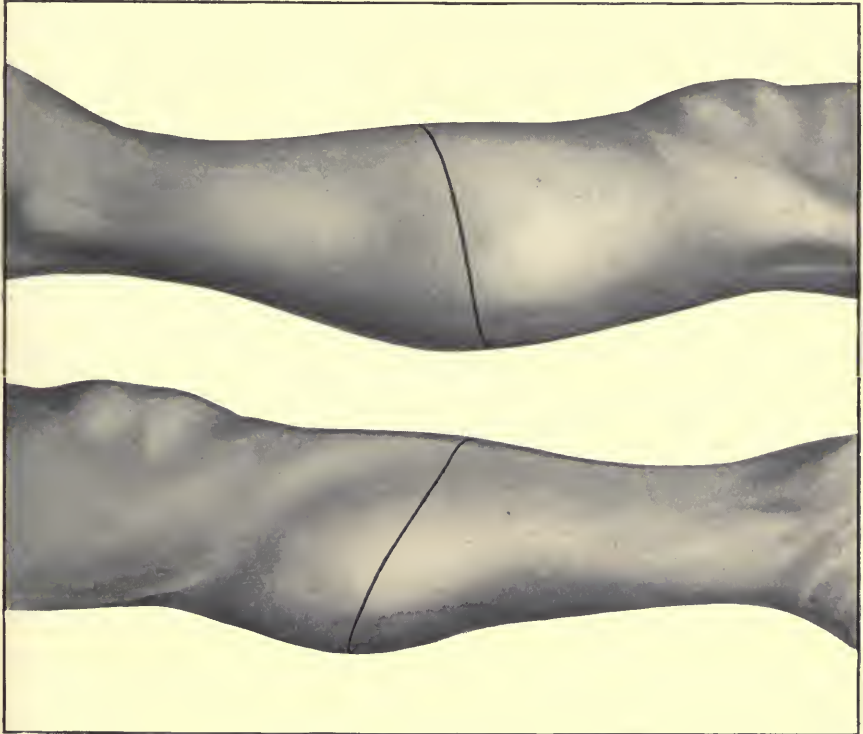


FIG. 113. AMPUTATION AT THE 'SEAT OF ELECTION' BY THE CIRCULAR INCISION. As will be seen, this incision is circular only in name; it is really an oblique one; extending lower down the limb in front in order to facilitate raising the flaps.

end of the table, the other leg is fastened down out of the way, and the surgeon stands on the patient's right of the limb to be operated upon; an assistant holds the limb horizontal. The amputating knife should be nearly half as long again as the transverse diameter of the limb. The surgeon places his left thumb upon the point at which he is going to saw the bone, and divides the skin by a circular sweep of his knife at a distance below this point rather more than half the diameter of the limb at the level of bone section, so as to allow for the retraction of the soft parts (see

Fig. 113). The arm is passed beneath the limb as in the ordinary circular amputation, and the knife is drawn round the limb with a slight sawing movement, passing lower down across the front of the leg than across the calf so that the incision is really an oblique one and not truly circular. If the incision cannot be completed in one sweep, it may be finished by making the knife traverse in the opposite direction from the commencement of the incision to its termination. The knife is again



FIG. 114. THE THREE-TAILED LINEN RETRACTOR IN USE FOR AMPUTATION THROUGH THE LEG. The middle limb of the bandage goes through the interosseous space and passes under the two outer limbs which retract the soft parts from the tibia and fibula respectively.

passed lightly around the limb so as to divide any bands of cellular tissue that might interfere with due retraction of the skin, and the skin flap is dissected up for about two inches. The connexion between the skin and the front of the tibia is more intimate than elsewhere, and it will require repeated touches with the point of the knife to separate the flap here.

The limb is now flexed slightly and the gastrocnemius is pinched up between the thumb and forefinger, pulled away from the deeper structures, and divided on a level with the retracted skin without injuring the main vessels. The limb is then extended, and the soft parts, including

the divided gastrocnemius but not the deep muscles on either the front or the back of the leg, are raised to about an inch below the proposed line of bone section. At this point an incision is made along the outer side of the crest of the tibia, and the fingers are sunk in between the bone and the tibialis anticus down to the interosseous membrane; the muscles and vessels are then divided transversely. The muscles on the posterior aspect of the limb are divided similarly, and the soft parts, back and front, are then raised from the interosseous membrane up to the point at which the bone is to be sawn. It is well to take the periosteum also for the last inch in cases of injury. Finally the interosseous membrane is divided, the soft parts are retracted by a three-tailed bandage (see Fig. 114), and the bones are sawn at 'the seat of election', the tibia being bevelled obliquely in front in the usual way (see p. 92). The section of the fibula should be completed first, and it is well, if time allows, to bevel off this bone obliquely from without downwards and inwards with a saw or a broad chisel.

The anterior and posterior tibial arteries, as well as the peroneal and some of the sural branches, will require ligation. There may be free bleeding from the nutrient artery to the bone, but this generally stops spontaneously; if not, the passage of a probe into the canal in which it lies will generally suffice to arrest it. Should this fail, Horsley's wax (see p. 437) should be pressed firmly into the orifice from which the bleeding comes, and will certainly succeed in stopping it. An inch of the posterior tibial nerve should be dissected out and removed before the flaps are sutured.

The flaps are approximated laterally so that the scar becomes antero-posterior. A drainage tube is inserted in the lower angle of the wound and removed in two days. The limb should be put upon a straight back splint with pads beneath the popliteal space so as to allow a little flexion, which greatly adds to the patient's comfort; a very useful form of splint is Gooch's, which encircles the limb completely. The limb should never be left without a splint, as spasmodic contractions of the hamstring muscles are certain to occur, and these are likely to give rise to permanent contractions which cannot be overcome easily.

Amputation by equal lateral skin flaps. This method is widely practised and is a very simple one, although it suffers from the liability to adherent cicatrix; the thinness of its flaps is also a drawback, and it is not uncommon for the end of the bone to project beneath and become adherent to the angle of the flaps in front.

Operation. The positions of the limb and of the surgeon are the same as in the preceding operation; a tourniquet is applied around the middle of the thigh. The level of the bone section is marked by the left thumb

on the crest of the tibia, and the index finger is placed upon the corresponding point in the centre of the limb behind. The surgeon leans over the limb and commences his incision from the latter point, making a crescentic incision with its convexity downwards on each side of the limb, terminating an inch below the bone section in front (see Fig. 115). Each flap should be about an inch longer than half the lateral diameter of the limb at the level of the bone section ; it is in order to obviate the

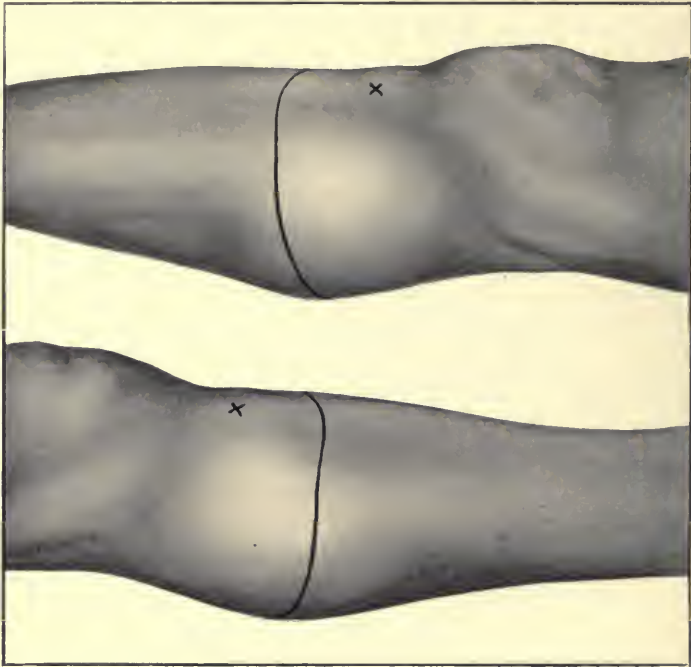


FIG. 115. AMPUTATION AT THE 'SEAT OF ELECTION' BY EQUAL LATERAL SKIN FLAPS. The x shows the level of bone section. Just below this point the muscles are divided by a circular sweep.

risk of the bone projecting between the flaps that the incisions are only made to extend up to within an inch of the line of bone section in front.

The knife is carried through the deep fascia, which is taken up with the skin until the level of the junction of the flaps in front is reached. At this point all the muscles are divided by circular sweeps of the knife, aided by the manœuvre already recommended for division of the deep muscles (see p. 218), and these structures are raised from the bone for the last inch, as there described ; the remaining stages of the operation are also exactly similar.

By a large external flap (Farabeuf's method). This method is suitable for cases in which the patient is to be fitted with an artificial limb furnished with a joint at the knee instead of wearing a peg-leg. It is a valuable amputation, but certain precautions must be observed if full success is to be attained. The large external flap was in common use before Farabeuf introduced the operation called by his name, but the merit of the latter lies in the fact that the anterior tibial

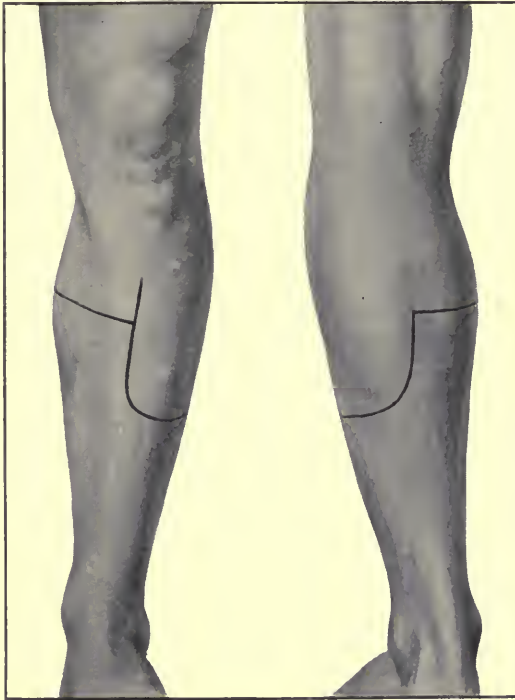


FIG. 116. INCISIONS FOR FARABEUFS AMPUTATION AT THE 'SEAT OF ELECTION'. The drawing shows the formation of the single large external flap, the level of bone section corresponding to the upper limit of the front limb of the incision.

artery and all the muscles are raised with the outer flap and therefore its nutrition is not interfered with, and there is no fear of the sloughing that frequently marred the older operations.

Operation. The patient is brought down until the buttocks are nearly level with the end of the table, and the assistant flexes the hip and knee joints, making the heel almost touch the buttocks, and supporting the sole of the foot on the end of the table. The surgeon stands on the patient's right of the limb to be operated upon, and marks the

point at which he is going to saw the bone with his left middle finger. On the right leg the incision is carried from this spot vertically down along the inner margin of the crest of the tibia, then across the outer aspect of the limb (which is rotated fully inwards), and vertically up the middle line of the limb behind to a point one inch short of the level from

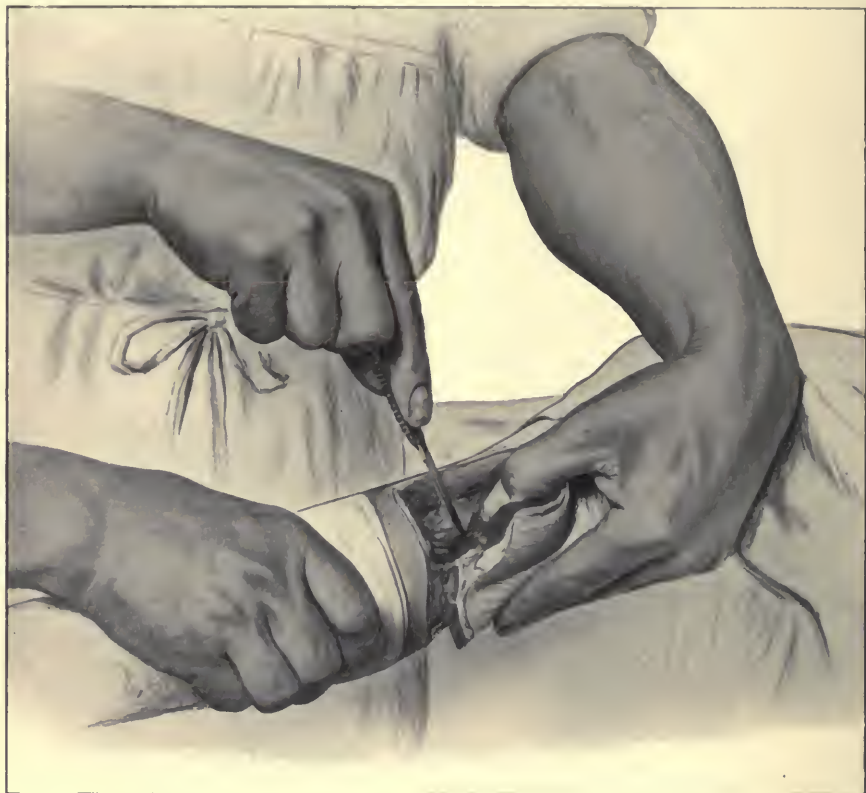

FIG. 117. DIVIDING THE STRUCTURES IN THE LARGE OUTER FLAP IN FARABEUF'S AMPUTATION AT THE 'SEAT OF ELECTION'. The soft parts are pulled away from the interosseous membrane by the left thumb, and the tissues are cut obliquely from within outwards.

which it started on the front of the leg. This incision marks out a U-shaped flap, which should be one-third longer than the lateral diameter of the limb at the level of bone section. The incision is gone over with the knife a second time so as to allow the skin to retract freely everywhere. As the last part of the incision, viz. that on the back of the leg, is being marked out, the assistant raises the limb until it is nearly horizontal.

On the left leg the procedure is different. The surgeon stands facing,

and somewhat to the outer side of, the foot, which he grasps in his left hand so that he can rotate the limb in whatever direction he pleases. The points between which the incision is to run should be marked out previously either by making small nicks in the skin or by an assistant's fingers. The leg is rotated inwards and the incision is begun from the anterior aspect of the limb, carrying it down just inside the crest of the tibia as before, then across its outer surface. The limb is raised with the left hand as this is done, and, as the incision is carried up the middle line behind to the point at which it is to cease (*vide supra*), the limb is raised



FIG. 118. FLAPS AFTER FARABEUFS AMPUTATION AT THE 'SEAT OF ELECTION'. The large external flap with its muscles and blood-supply intact is well shown. The edge of the tibia is bevelled off.

higher and higher until finally it is almost vertical. The limb is now transferred to the assistant, and the surgeon takes his place on the outer side of it to complete the remaining stages of the operation, which are the same on both sides. Bending over the limb, the knife is drawn transversely across its inner aspect from the upper extremity of the posterior incision to the corresponding point on the front of the limb, viz. one inch below the level of the upper extremity of the incision there (see Fig. 116). The skin is allowed to retract to its full extent.

The deep fascia is next incised along the crest of the tibia from above downwards, the fingers of the left hand are thrust between the muscles and the bone right down to the interosseous membrane, and the tibialis anticus (anterior) is pulled away from the tibia. The knife is inserted

between the bone and the muscles and the latter are divided from within outwards on a level with the retracted edge of the outer flap by a succession of cuts from the deep to the superficial surface carried as far outwards as the fibula (see Fig. 117). The peronei are then divided and peeled from the fibula up to the level of the bone section. The posterior muscles are divided either by transfixion or by cutting from without inwards ; in the former case the knife is entered behind the fibula and brought out through the transverse incision across the inner aspect of the limb, the

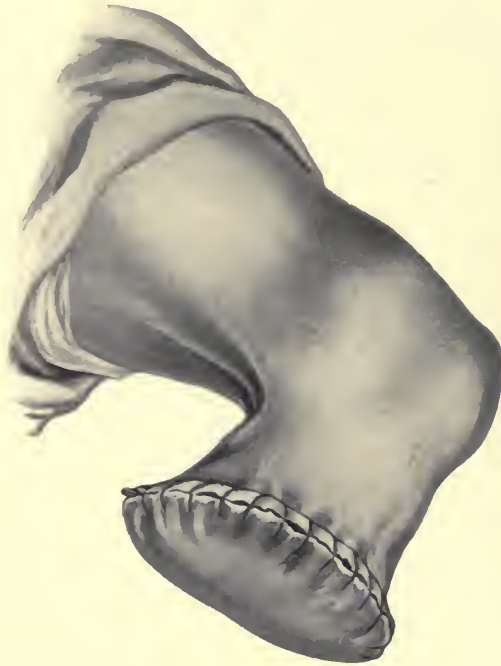

FIG. 119. STUMP AFTER FARABEUFS AMPUTATION AT THE 'SEAT OF ELECTION'.

large outer flap being raised and kept out of the way as the division of the muscles proceeds.

Finally all the soft parts, including the periosteum, are peeled up from the bone for about an inch, when the level of the proposed bone section is reached. The bones are now sawn, and, if possible, the fibula should be divided on a higher level than the tibia ; it should also be bevelled from without downwards and inwards, whilst the tibia should have its sharp anterior margin bevelled off in the usual way (see Fig. 118). It is rather difficult to bevel off the fibula properly, but the best way is to divide the bone transversely and reduce it subsequently to the proper

shape with a chisel. On the left leg the fibula will be sawn first, while on the right it is better to saw it after the tibia has been cut through. The posterior tibial nerve is dissected out and cut short, and the large external flap is brought across the ends of the bones and sutured (see Fig. 119).

DISARTICULATION AT THE KNEE-JOINT

There is still some difference of opinion as to the value of this particular form of amputation. While some authorities prefer it because it furnishes a stump with an expanded end upon which the full weight of the limb can be borne, others object to it because of its æsthetic drawbacks. The patient cannot wear an artificial limb with a false joint so comfortably or so naturally as he can when the amputation has been done through or above the condyles, because the false joint is on a lower level than the normal one, and although this is not noticeable when the patient is upright, it is unmistakable when he sits down. On the other hand there is no doubt that the large-ended stump resulting from a disarticulation allows the weight of the body to be borne directly upon its end with greater certainty and comfort than is always the case after amputation through or above the condyles. In the latter case the stump may be found to be incapable of bearing pressure at all, and the artificial limb may have to take its purchase from the pelvis. As a general rule, therefore, it may be suggested that disarticulation through the knee is more suited for the working classes, whereas amputation higher up should be done for those who can afford a more expensive apparatus, and whose chief desire is to secure the best æsthetic result.

Various methods may be employed for disarticulation. The one most used in England is that known by the name of Stephen Smith. The only other one that needs description is the elliptical method, which is very simple and gives a sound and useful stump; it is very similar to Stephen Smith's.

Stephen Smith's disarticulation at the knee-joint. The amputation originally introduced by Stephen Smith (*New York Journal of Medicine*, September, 1852) was by means of what he termed 'a hooded flap'; in other words, one marked out by an oblique racket incision. In order to make a neater stump, however, English surgeons are in the habit of slightly modifying the incision by cutting a V-shaped portion out of the front of the hooded flap, and thus converting the amputation into one by two lateral flaps of an irregular shape.

Operation. The lower half of the thigh projects well beyond the edge of the table. The surgeon stands on the patient's right of the limb to

be operated upon ; the other is fastened down to the table out of the way. The level of the knee-joint is defined by flexing and extending the limb, and the surgeon places his left forefinger in the middle line behind upon a level with the joint line. The thumb rests upon the lower part of the tubercle of the tibia. The incision is commenced behind by leaning over the limb and entering the point of the knife immediately below the tip of the forefinger, the limb being rotated towards

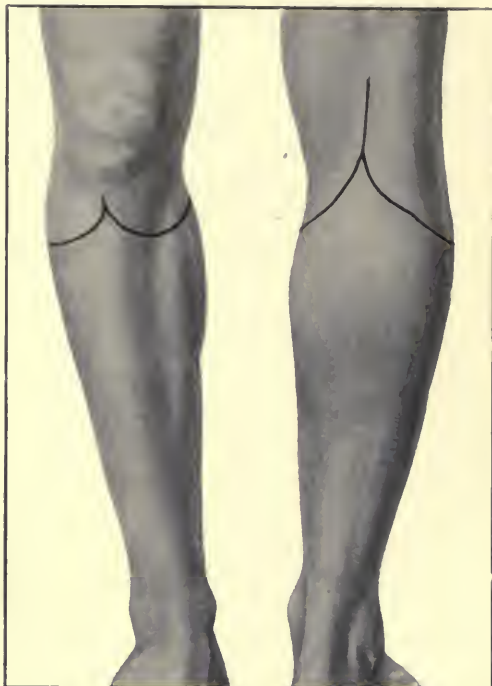


FIG. 120. INCISION FOR STEPHEN SMITH'S DISARTICULATION AT THE KNEE-JOINT. It will be noted that the incision extends slightly lower down on the inner than on the outer side.

the operator so as to bring the posterior surface as much into his view as possible. The knife is carried down vertically in the middle line for three inches, and is then made to cut a lateral flap with its convexity downwards, the lowest point being a full inch below the tubercle of the tibia. As it approaches the middle line in front the incision is carried just up to the point of the thumb, which is on the lower part of the tubercle of the tibia. The limb is then raised somewhat and rotated in the opposite direction, *i.e.* away from the surgeon, who cuts the other lateral flap from the tubercle back to the vertical median incision at the

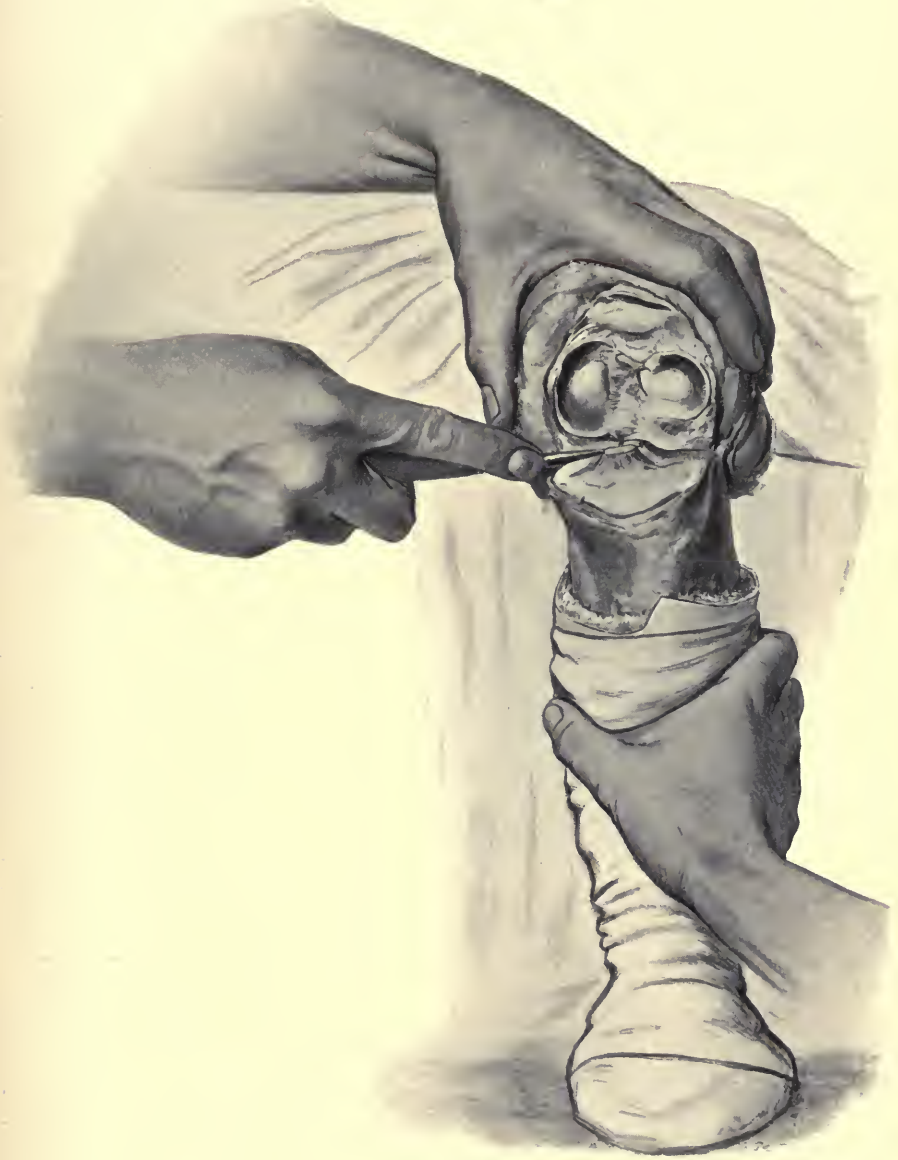

FIG. 121. DISARTICULATION AT THE KNEE-JOINT BY STEPHEN SMITH'S METHOD. The semilunar cartilages are seen in contact with the condyles of the femur. The knife is dividing the posterior ligament of the knee-joint and the popliteal vessels.

point where the opposite lateral incision began, namely, about three inches from its commencement (see Fig. 120). It is generally advised that the inner flap should be a little longer than the outer in order to cover the large inner condyle satisfactorily.

The skin is pinched up in the fingers, the incision is carried through the deep fascia, and the flap on each side is dissected up to the level of the ligamentum patellæ. When this level is reached, the knife is carried

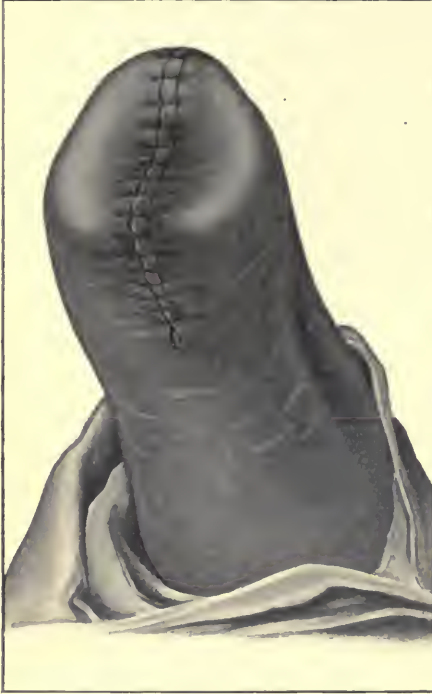


FIG. 122. STUMP LEFT AFTER STEPHEN SMITH'S DISARTICULATION AT THE KNEE-JOINT.

down to the bone all round and the ligamentum patellæ is divided; the assistant, who has previously held the limb horizontal, now flexes the knee, whilst the surgeon insinuates his knife between the semilunar cartilages and the tuberosities of the tibia so as to separate these two structures and leave the cartilages applied to the condyles of the femur. The knee is then bent still further, and the crucial ligaments are divided with a few touches of the knife. Disarticulation is completed by retracting the flaps fully, passing the knife across the joint, between the tibia and the femur, and then extending the limb almost completely and cutting down towards the floor. This divides the posterior ligaments and the structures in the popliteal space (see Fig. 121).

The only vessels of importance that require ligature are the popliteal vessels and some of the articular branches. The internal popliteal nerve should be isolated, and an inch of it excised. When brought together, the flaps form a vertical cicatrix in the hollow between the condyles (see Fig. 122), and are secured by a few coaptation sutures of silkworm-gut, with a continuous suture to unite the skin edges. A drainage tube is inserted at the upper end of the incision. The limb is placed upon a straight back-splint or in a roll of Gooch's splinting, and raised on pillows to an angle of 45°; it should be fastened between sandbags so as to prevent spasmodic jerkings of the stump. The bandage fastening on the dressings

should be a figure-of-eight round the pelvis; the splint should also be secured by a similar bandage, otherwise the splint and the dressing are very apt to slip off the stump. The drainage tube, which is in the most dependent part of the wound, should be removed at the end of forty-eight hours. The sutures may be taken out at the end of fourteen days, when the patient can also dispense with the splint. There is usually some pain referred to the sciatic nerve for the first few days after the operation, but this is easily relieved by opium. The stump can bear considerable pressure in about a month.

The operation furnishes a perfect stump; the cicatrix is vertical and gets drawn up into the inter-condyloid notch out of the way of all pressure, while the semilunar cartilages, which are left behind in contact with the condyles, serve to square off the end of the stump and fit it admirably for bearing the weight of the body. The only objection to the operation is that common to all disarticulations at the knee-joint, viz. that the instrument maker has to fit the patient with a limb in which the level of the artificial knee-joint is lower than that on the sound side and therefore he prefers an amputation through the condyles.

Difficulties. The chief mistake made in this operation is the very serious one of cutting the flaps so that they cannot be made to cover the condyles of the femur. It is a common fault when operating on the living, and more particularly on the dead subject, to begin too high up, and to trace out a racket incision of the lanceolate type rather than of the well-known crupper form (see Fig. 123). In the former the ends of the incision begin to diverge from one another above the level of the lower ends of the condyles, and the result is that the skin cannot be made to meet and to cover the condyles without too much tension. It is of the greatest importance to begin the incision at the level of the joint, and to make the first three inches of it vertically in the middle line behind, so as to form a definite handle to the racket; this ensures ample covering for the large condyles of the femur. If the flaps are found to be faulty in this respect at the end of the operation there is no alternative but to make a trans-condyloid section of the femur.

By an oblique elliptical incision. The positions of the patient and the surgeon are the same as before. The left thumb marks the lowest point of the elliptical incision, which should cross the anterior border of the tibia a full diameter below the level of the joint, which must be defined carefully (see p. 226). The highest point of the ellipse should cross the middle line of the calf half that distance below the joint line; in estimating these measurements it is well to err on the side of amplitude in order to allow for the retraction of the soft parts. An elliptical incision is made around the limb, its long axis being at an angle of

30° to the vertical (see Fig. 124). The skin is allowed to retract, and then the skin and fascia are freed from the deeper structures by a few touches of the knife, and the front part is turned up as a sort of cuff, its free edge being seized between the thumb and fingers of the left hand. The deep fascia should be taken up with the skin so as to maintain the

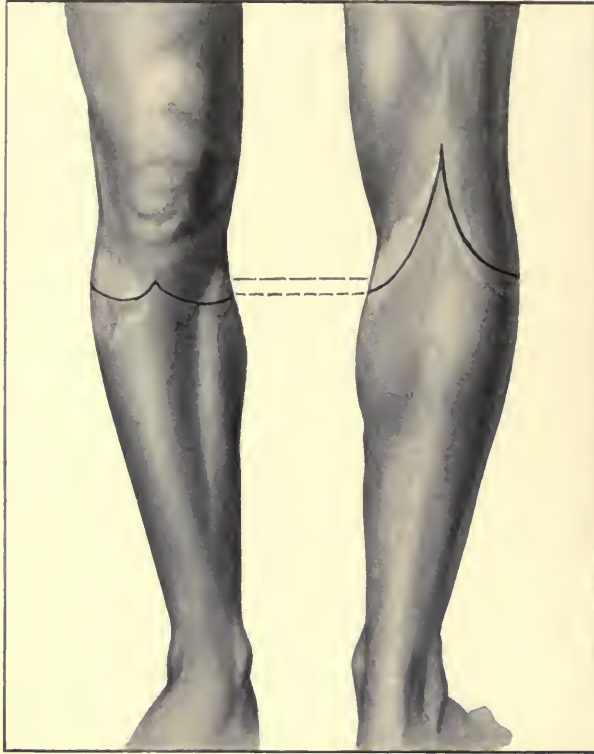


FIG. 123. FAULTY INCISIONS FOR STEPHEN SMITH'S DISARTICULATION. The incision behind begins to diverge at once, and the result of this is that there will not be enough covering for the condyles of the femur.

blood-supply of the flap intact. The anterior part of the flap is raised until the lower end of the patella is reached, and then the limb is moderately flexed, the ligamentum patellæ is cut across, and the joint opened. The remaining steps of the operation are similar to those of Stephen Smith's amputation, and the semilunar cartilages can be left in contact with the condyles of the femur as in that operation. The wound is sewn up so as to form a cicatrix which is parallel to the transverse diameter of the limb, so that the stump appears to have been fashioned with antero-posterior flaps.

There are many other methods of disarticulating, but the two given above will suffice for the cases usually met with. Of these Stephen Smith's is the better, but the elliptical incision method is described as being one in which there is less likelihood of a beginner cutting faulty flaps. The operations by a long anterior flap are more suited to the

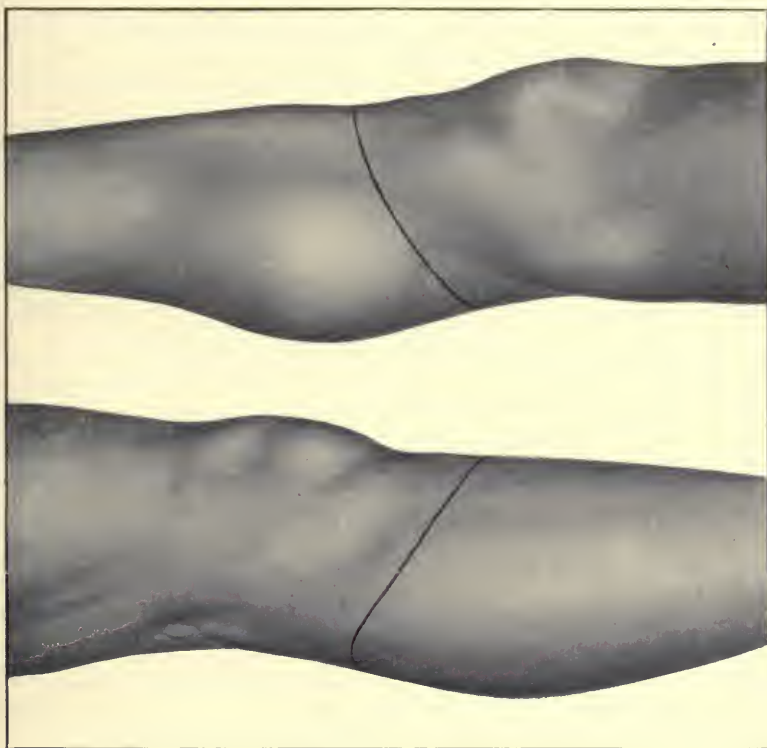


FIG. 124. DISARTICULATION THROUGH THE KNEE-JOINT BY AN OBLIQUE ELLIPTICAL INCISION. The cicatrix gets pulled well up into the inter-condyloid notch.

next group of cases, in which the amputation is practised through or above the condyles.

TRANS-CONDYLOID AND SUPRA-CONDYLOID AMPUTATIONS

The merits of these operations have been discussed already (see p. 225). The stump is shorter and the base of support is smaller, and therefore the chance of bearing the whole weight of the body directly on the end of the stump is not quite so good as it is in the case of disarticulations,

and the artificial limb may have to take its purchase from the pelvis. In order to facilitate weight-bearing the condyles should be divided as low down as possible ; when the femur is sawn through the base of the condyles the articular surface of the patella may be cut off and its cut surface turned up and made to unite with the cut surface of the femur so as to give a rounded end to the stump and one well calculated to bear pressure. In all cases every attempt should be made to save the adductor tubercle, as the maintenance of the functions of the adductors is an enormous gain to the patient. The action of the quadriceps should be also retained, either by saving the patella or by suturing its tendon to the bone. Of the amputations commonly practised in this situation only three will be described : (i) The operation by long anterior and short posterior flaps, (ii) Lister's modification of Carden's operation, and (iii) The Stokes-Gritti amputation. All three amputations are useful under certain circumstances.

Amputation by long anterior and short posterior flaps. The limb is drawn well over the table and the surgeon stands on the patient's right of it, the sound leg being fastened down out of the way. The limb being held almost horizontal, a long anterior flap is marked out commencing just behind the condyle on the side away from the surgeon and immediately above the level of the joint ; the limb is rotated towards the surgeon while this is being done. The incision is carried vertically down for rather more than the antero-posterior diameter of the limb at the point of bone section, and the leg is then rotated away from the surgeon, who draws the knife across the front of the limb and finally up along the lateral aspect of the limb facing him, until it reaches a point opposite that from which it started on the other side (see Fig. 125). A large U-shaped flap is thus marked out and is allowed to retract fully by deepening the incision uniformly through the deep fascia all round. A posterior flap is next marked out by passing the arm beneath the limb and cutting transversely across its posterior surface from one side of the anterior flap to the other, half-way between the point of bone section and the lower limit of the anterior flap. The edges of the latter are then seized between the left thumb and forefinger, and it is raised, along with the deep fascia, well above the patella. When the upper edge of this bone is reached a circular sweep is made around the limb, dividing the soft parts down to the bone and opening the knee-joint. A second sweep divides all the periosteal structures, and the saw is then applied to the condyles just above the upper limit of the cartilaginous surface. The saw should not be applied quite at right angles to the long axis of the bone, but at a slight angle, so as to cut a little lower on the inner side than the outer, and thus reproduce the normal obliquity of the condyles.

The long anterior flap folds over the end of the bone, and the cicatrix falls well on to the posterior aspect of the limb. The flaps are united by deep coaptation sutures of silkworm-gut reinforced by a continuous suture for the edges. A drainage tube is necessary for the first three days or more. The dressing is applied first on the anterior surface of the limb, then carried across the end of the stump, and finally up on the posterior surface.

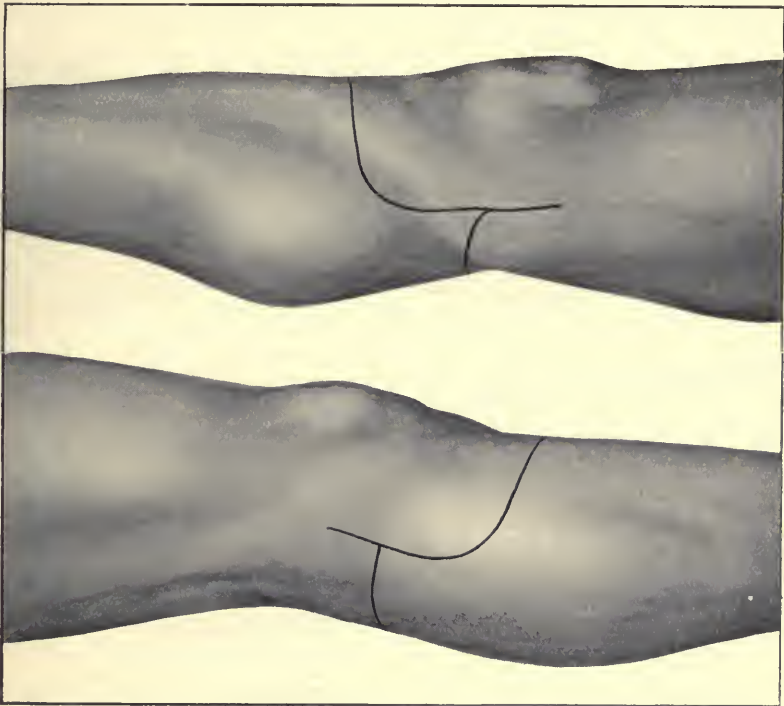


FIG. 125. TRANS-CONDYLOID AMPUTATION OF THE FEMUR BY LONG ANTERIOR AND SHORT POSTERIOR FLAPS.

The stump given by this operation is not so capable of bearing the patient's full weight for a long time as are those resulting from the preceding operations.

Lister's modification of Carden's operation. Lord Lister has devised the following useful modification of Carden's amputation in which only a long anterior flap was fashioned (Holmes's *System of Surgery*, vol. iii, p. 718). He describes it as follows:—

'The only objection to Carden's operation, as described by him, is the occasional occurrence of more or less sloughing of the long anterior

flap of the skin, in spite of faultless operating. It is plain that the risk of sloughing would be diminished if the flap could be made shorter by not carrying the horns of the incision, by which it is formed, so high up the limb; and I found that it is by no means difficult, when the parts are in their natural condition, to accomplish the operation without making any anterior flap at all, the integuments in front being divided transversely at the level of the lower end of Mr. Carden's flap. I also

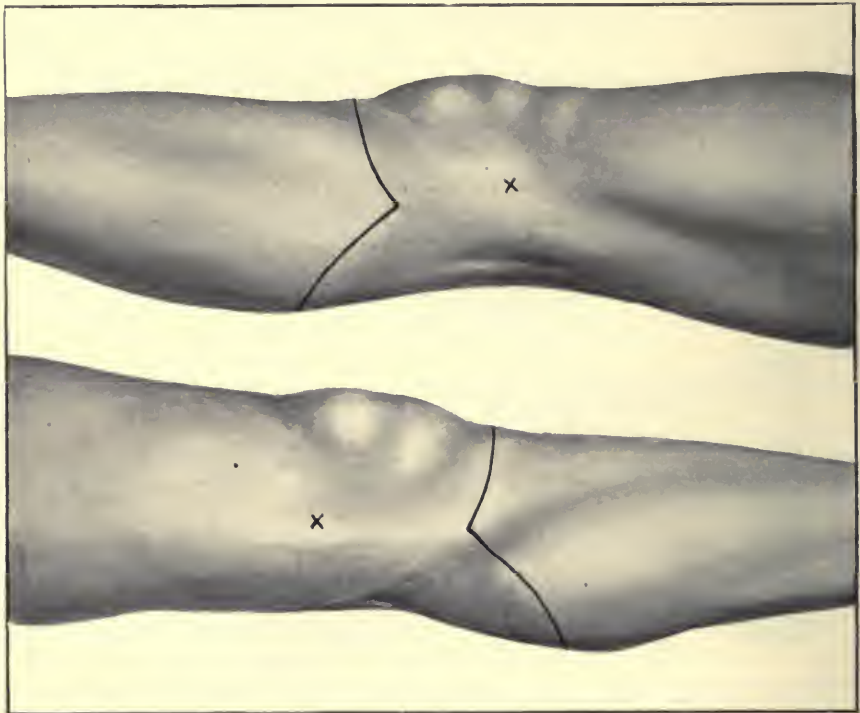


FIG. 126. INCISIONS FOR LISTER'S MODIFICATION OF CARDEN'S AMPUTATION.
The x shows where the condyles are divided.

found it advantageous to form a short posterior skin flap, both for the sake of coaptation of the cutaneous margins without puckering and as a useful addition to the covering for the end of the stump (see Fig. 126).

'The operation is performed as follows. The surgeon first cuts transversely across the front of the limb from side to side at the level of the anterior tuberosity of the tibia, and joins the horns of this incision posteriorly by carrying the knife at an angle of 45° to the axis of the leg through the skin and fat. The limb being elevated, he dissects up the posterior skin flap, and then proceeds to raise the ring

of integument as in a circular operation, taking good care to avoid scoring the subcutaneous tissue; and, dividing the hamstrings as soon as they are exposed, and bending the knee, he finds no difficulty in exposing the upper border of the patella. He then sinks his knife through the insertion of the quadriceps extensor, and having cleared the bone immediately above the articular cartilage and holding the limb horizontal, he applies the saw vertically and at the same time transversely to the axis of the limb (not of the bone), so as to ensure a horizontal surface for the patient to rest upon. The popliteal artery and vein are then secured, and any articular or other small branches that may require it.

‘When the soft parts are thickened and condensed by inflammation, the integuments cannot well be reflected above the patella with such incisions of the skin. But the difficulty may be got over by cutting into the joint as soon as the ligamentum patellæ is exposed, and at once removing the leg by dividing the ligaments and hamstrings; after which the soft parts can be retracted from the femur sufficiently to permit the application of the saw. The arteries having then been secured, the patella is dissected out at leisure.

‘As thus performed, Carden’s operation takes a little more time and pains than when the integument is divided in the form of an anterior flap; but these are well rewarded by the ample covering for the bone, the small external wound, and the perfect security against sloughing.’

The Stokes-Gritti amputation. The positions of the surgeon and the patient are the same as in the previous operation. A large rectangular anterior flap is marked out by an incision running from a point just above the base of the condyle on one side to the corresponding point on the opposite side, and reaching as low as the upper part of the tubercle of the tibia. The posterior flap is one-third the length of the anterior, and is made by drawing the knife transversely across the back of the limb. The anterior flap is raised, the ligamentum patellæ being cut across when it is met with, the knee-joint opened and the capsule divided so as to allow the patella to be raised with the flap. The tendons at the back of the joint are divided on a level with the edge of the retracted skin, and the posterior flap is raised to the level at which the bone is to be sawn, which is about an inch above the base of the condyles, through the expanded portion of the shaft of the femur and below the medullary cavity. A circular sweep is made with the knife around the bone at this spot, the periosteum is divided and the femur is sawn.

The surgeon now carries his knife around the circumference of the patella along the margin of the cartilage so as to cut a groove, and, grasping the flap firmly between the left thumb and forefinger, he stretches the subcutaneous surface of the bone against the dorsal aspect of the remaining

fingers of his hand (see Fig. 127), and removes the cartilaginous surface with a saw. The bony surface left will correspond closely in size to the cross section of the divided femur (see Fig. 128), and the two surfaces are placed in apposition and fastened together either by stout sutures passed through the soft parts or by some form of fixation pegs or pins; the patella thus furnishes a rounded end to the divided femur upon which the patient can bear his weight.

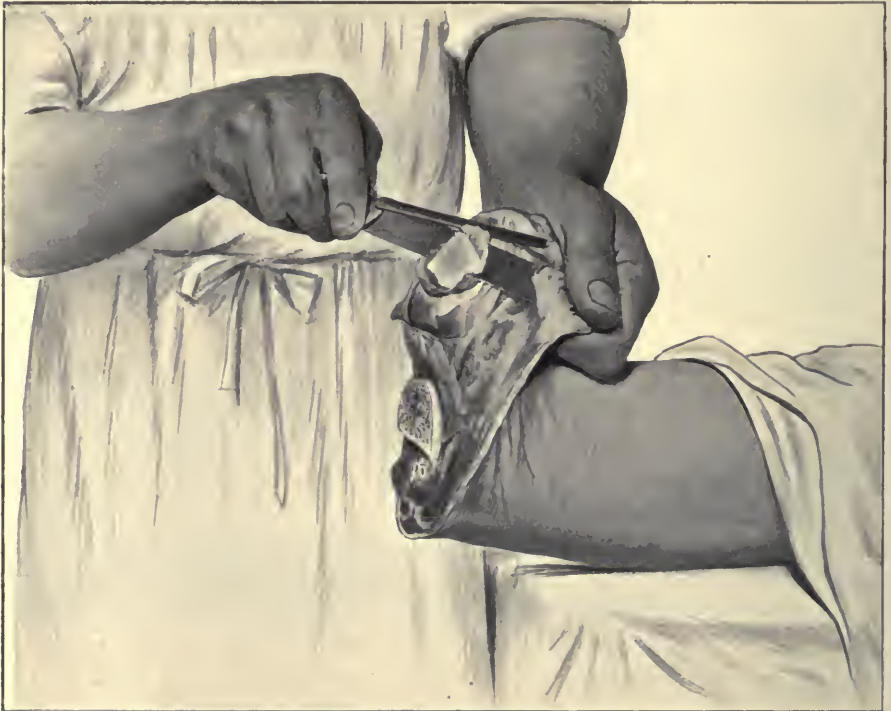

FIG. 127. REMOVING THE ARTICULAR SURFACE OF THE PATELLA IN THE STOKES-GRITTI AMPUTATION.

The anterior flap is turned down round the lower end of the femur; the cicatrix is transverse and lies just above the line of bone section. A drainage tube is inserted at each angle of the wound, and the dressings are applied to the front of the thigh first, then carried round the end of the stump and up the posterior aspect of the limb, so as to keep the patella firmly in apposition with the femur.

This amputation is really supra-condyloid, whereas both the preceding methods are trans-condyloid. The advantage of the amputation just described is that the two surfaces of bone correspond closely in size,

whereas in Gritti's original amputation the section was made through the condyles, where the cut surface of the femur is much larger than that of the patella, and, owing to this and to the increased length of the femur, it was difficult to get and maintain the patella in apposition with the end of the femur.

The Stokes-Gritti amputation is a valuable one, and should be preferred

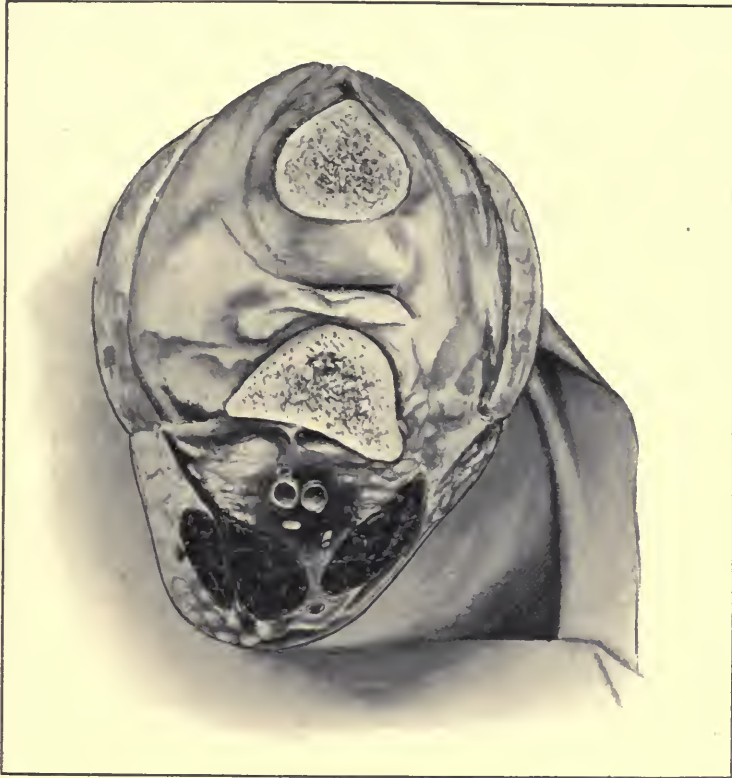


FIG. 128. THE FLAPS AFTER A STOKES-GRITTI AMPUTATION. It will be seen how nearly the sawn surface of the patella and the supra-condyloid region of the femur correspond in size.

to an amputation through the shaft of the bone whenever circumstances allow of its being done. In the majority of cases the stump will bear the body weight upon its end, whereas this is hardly ever the case in amputations through the shaft of the bone, the artificial limb taking its purchase from the pelvis in the latter cases. The medullary canal is not opened, the muscular attachments are disturbed very little, and the adductors retain their connexions and act satisfactorily. There is little

chance of a conical stump resulting, as so few of the muscles are severed from their attachments.

At the same time the stump is not always satisfactory. In former days especially, bony union did not always take place between the patella and the end of the femur, and the former became tilted and formed a projection that gave rise to pain when weight was borne on the end of the stump. This, however, is hardly likely to happen now, since the methods of fastening bone surfaces together have been greatly improved. The method that I have found most satisfactory on the whole is to drive a square ivory peg through the patella into the end of the femur, allowing its free end to protrude through a hole in the skin over the patella. This is surrounded by the dressings, and can be removed on the tenth day. The use of a removable peg is adopted because pressure is borne direct upon the anterior surface of the patella and any foreign body such as a wire, nail, or screw permanently embedded in that bone may give rise to irritation from pressure and require removal.

I have seen effusion occur in the prepatellar bursa after the patient has been getting about, necessitating excision of the bursa. Should the patella be larger than the cut end of the femur to which it is to be applied it should be pared down until it fits fairly accurately.

CHAPTER VIII

AMPUTATIONS THROUGH THE THIGH AND DISARTICULATIONS AT THE HIP-JOINT

AMPUTATIONS THROUGH THE THIGH

MANY methods are available for amputation in this region, the only thoroughly unsuitable one being that by a large posterior flap; this is objectionable because of the inveterate tendency of the hamstring muscles to retract. The stump never has to transmit the weight of the body directly through its end, and therefore the position of the cicatrix is not a matter of prime importance, although, as a conical stump is not an uncommon sequela of amputation through the thigh, it is well that the scar should be placed posteriorly if possible. The most satisfactory method on the whole is by long anterior and short posterior flaps consisting of skin and a gradually increasing amount of muscle. This, and the circular amputation, which is most suitable for cases in which it is imperative to divide the bone as near the level of the injured tissues as possible, are the only two that will be described here, although it must be understood that a large number of other amputations can be performed, and should even be preferred to the two described under varying circumstances, depending upon the seat of injury, the state of the tissues, &c.

The circular amputation. This is circular only in name; it is really an elliptical amputation, because the retraction of the hamstring muscles is so great that the incision must reach considerably further down on the posterior surface of the limb than on the anterior in order to make the cut edge of the skin horizontal all round the limb. It is only suitable for the lower third of the limb, where there are a number of tendons that retract well out of the way; higher up, the large muscular masses are more difficult to cut so as to ensure a good stump.

Operation. The patient is drawn down so that nearly the whole of the thigh projects beyond the end of the table, a tourniquet is applied transversely round the limb just below the fold of the groin, and the other leg is fastened down out of the way. The surgeon stands on the patient's right of the limb to be operated upon, and grasps the limb at the level of the bone section with one hand and makes an oblique circular

incision round the limb at such a distance below this point that the highest point of the incision in front is equal to a quarter of the circumference of the thigh at the point of bone section : this will be four to five inches in an ordinary limb. The hand is passed beneath the limb, which is rotated away from the surgeon as far round as possible, so that the heel of the knife is near the junction of the anterior with the outer surfaces. The incision is marked out by drawing the knife gently round the limb from heel to point until the circular cut is complete (see Fig. 48). This may be done in one single sweep, or in two, if necessary ; in the latter case the knife is carried in the reverse direction, joining the commencement of the first incision to its termination. After the incision has been made, it is deepened evenly through the fascia all round so that the skin can retract fully. From what has been said before, it will be remembered that the incision through the skin at the back of the thigh will be nearly two and a half inches lower down than that on the front.

The cut edge of the skin is seized in the left thumb and index finger and raised for about four inches all round by circular sweeps of the knife which divide the bands of subcutaneous fibrous tissue put on the stretch as the skin is raised. The knife should be kept strictly at right angles to the surface as this is done. This allows the skin to be pulled back for three or four inches.

The knife is now swept around the limb through the superficial muscles in close contact with the retracted skin, and after these have been thus divided and have retracted, the deeper ones are divided by another circular sweep of the knife as near the proposed point of bone section as possible ; finally the bone is cleared up to the point at which it is to be divided, and sawn in the usual way. It is well to bevel off the *linea aspera* with the saw or a chisel (see Fig. 129).

It is not always possible to do the operation exactly as it is described above. In muscular subjects and when there is inflammatory effusion or oedema in the neighbourhood of the operation, the soft parts cannot be retracted as easily as the above description would lead one to expect. In these cases, therefore, it will be necessary to raise and turn back the skin and deep fascia for the first three inches or more. This may be done in the form of a cuff, but if there be any difficulty in doing this it is better to make two short lateral vertical incisions upward from the circular incision, and thus convert the amputation into one by equal antero-posterior flaps.

The flaps are brought together and united as antero-posterior flaps, so that the cicatrix is transverse. A large drainage tube is inserted at the inner end of the incision. Few vessels will require to be secured besides the femoral artery and vein. When the amputation is performed

low down in the thigh the anastomotica magna (genū suprema) must be tied; when higher up, the profunda and the perforating arteries.

Amputation by long anterior and short posterior flaps. The positions of the patient and the surgeon are the same as in the



FIG. 129. BEVELLING THE LINEA ASPERA IN AMPUTATION THROUGH THE FEMUR. The soft parts are kept back with a two-tailed linen retractor, and the linea aspera is shown bevelled off.

previous operation. If the amputation is to be performed at or below the middle of the thigh, a tourniquet should be applied horizontally around the limb just below the groin; should it be necessary to amputate higher than this, however, the tourniquet should be put on as for disarticulation at the hip (see p. 246); if applied otherwise the parts cannot retract properly, owing to the compression of the tourniquet. In connexion with this form

of amputation it should be remembered that when the bone is sawn at or above the junction of the middle with the lower third, the femoral artery lies exactly beneath the junction of the anterior with the posterior flap, and that therefore it is liable to be split longitudinally by the knife. This is not a really serious objection provided that the surgeon makes a complete circular incision through the muscles down to the bone at the level at which he is going to saw the latter, but in order to avoid this difficulty the flaps are often raised from the antero-external and postero-internal aspects of the limb rather than from the true anterior and posterior surfaces ; that is to say, the point at which the knife is entered on the inner side of the limb is shifted outwards about an inch and a half, and the other extremity of the incision is correspondingly altered. It was not uncommon to slit the artery longitudinally when it was the fashion to cut the flaps by transfixion, but such an accident is hardly likely to happen with the present-day method of cutting the flaps from without inwards.

The left forefinger and thumb mark out the terminal points of the incision on a level with the point of bone section. A large U-shaped flap, in width equal to full half the circumference of the limb and in length the full antero-posterior diameter of the limb at the point of bone section, is now marked out through the skin and deep fascia in the usual way. When the amputation is to be done through the lower third of the femur this will bring the incision well down over the patella. The incision is commenced by leaning over the limb, which is rotated to expose its lateral aspect properly to the knife ; when finishing the incision, the limb is rotated away from the surgeon. It is best to use a comparatively short amputating knife, one of six inches being quite long enough, and to mark out the incision, not with the point of the knife, but by drawing it along the limb with a gentle sawing movement, using as much as possible of the cutting edge.

The short posterior flap is marked out by passing the arm beneath the thigh, which is raised by the assistant, and by cutting a flap rather more than one-third the length of the anterior (see Fig. 130). These incisions are carried down through the deep fascia, and the skin is allowed to retract fully. The edge of the anterior flap is now pinched up between the left thumb and forefinger, and is raised by a few gentle sweeps of the knife across the limb, at first taking up only the deep fascia, but afterwards, when the quadriceps muscle is reached, gradually taking up more of the muscle until the knife has been carried down to the bone when the level of the proposed bone section is reached (see Fig. 131). This flap is given to an assistant, who holds it back whilst the posterior one is raised. In this case the tissues are cut almost directly down to the bone

at the level of the retracted skin, the line of incision being obliquely upwards; while this is being done, the limb should be raised almost to the vertical. When the amputation is in the lower third of the femur the posterior flap may be cut by transfixion, as there are only tendons to be divided. The flaps are retracted by a two-tailed retractor (see Fig. 129), and the division of the soft parts is completed by a circular sweep of the knife down to the bone; the periosteum is retracted with

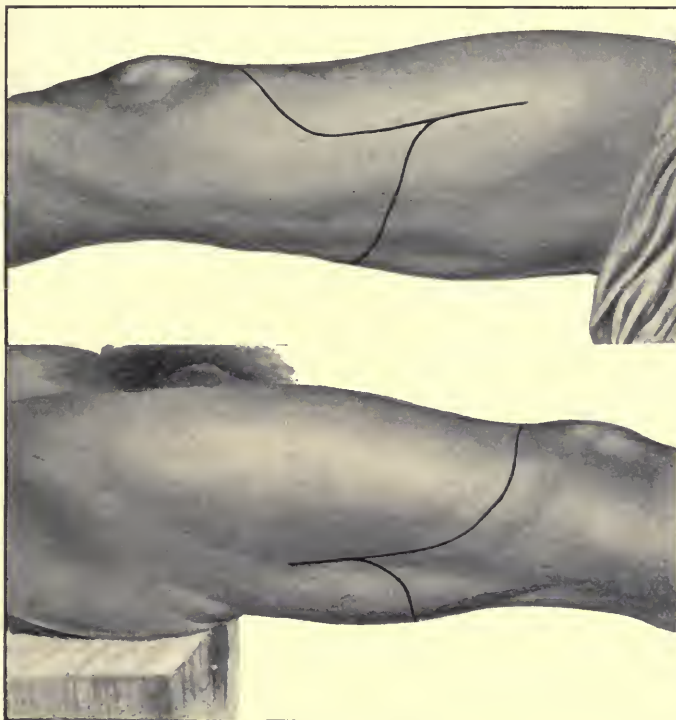


FIG. 130. AMPUTATION THROUGH THE MIDDLE OF THE THIGH BY UNEQUAL ANTERO-POSTERIOR FLAPS. These flaps are really antero-external and postero-internal in order to avoid slitting the femoral artery.

the muscles for half an inch or more and the bone sawn, the linea aspera being rounded off as already described (see Fig. 129).

After the operation the femoral artery will have to be ligatured, and will probably be found in the posterior flap, except when the amputation is done in the upper third of the thigh, when it will be in the anterior one. The other vessels divided are the same as those met with in the previous operation.

A large drainage tube should be inserted at the outer angle of the wound and removed at the end of three days. The limb should be

surrounded by Gooch's splinting, flexed at the hip and placed upon a pillow; the bandages securing the dressings and the splint must pass round the pelvis, as otherwise the limb may be drawn right out of the dressings. Deep stout silkworm-gut sutures will be required to keep the heavy flaps in position, and it is always well to retain these, if

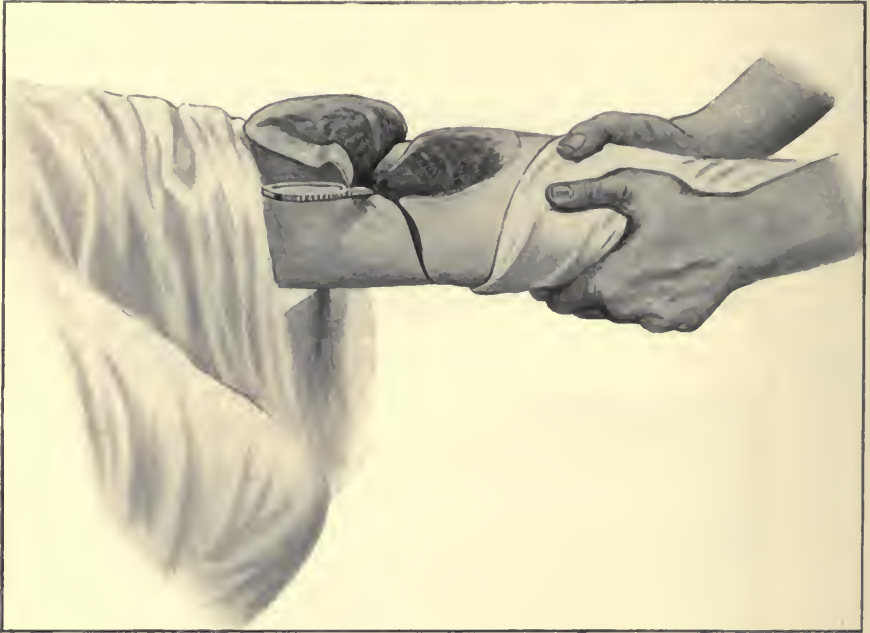

FIG. 131. CUTTING THE POSTERIOR FLAP BY TRANSFIXION IN AMPUTATION THROUGH THE LOWER THIRD OF THE THIGH. The anterior flap with its gradually increasing amount of muscle is shown reflected. The incision for the posterior flap has been made through the skin, and the knife is shown transfixing the tissues behind the femur.

possible, for at least a fortnight, the continuous suture being left in for about three weeks.

The result of this amputation is usually good if a fair amount of muscle has been left in the flap. A conical stump, however, is not uncommon after amputation of the thigh, especially when it is done low down. This is largely due to the great contraction of the posterior muscles.

DISARTICULATION AT THE HIP-JOINT

When a disarticulation at the hip-joint has to be performed, the immediate risks of the operation, namely death from shock and hæmorrhage, have always to be carefully considered. The lower the division of the main nerve trunks and vessels can be practised, the less do these risks become. Another point of importance not to be lost sight of is that the amputation should be so planned that the wound is removed as far as possible from the perineum and the anal region. It is always necessary to employ drainage in these cases, and when a drainage tube has to be inserted in regions so adjacent to sources of sepsis as they are here, the risk of infection is very great. Lastly, it is important to consider the question of the suitability of the future stump for bearing pressure. In all disarticulations at the hip-joint the weight is borne by the pelvis, but the longer the stump of soft parts left, the firmer the apparatus fits and the less likelihood there is of its slipping.

For all these reasons some form of the operation known in England as Furneaux Jordan's is to be preferred whenever it can be adopted. This operation consists essentially in amputating as low down as possible through the thigh, and then enucleating the upper end of the femur from the soft parts.

By adopting this method the shock is diminished, as the nerves are divided at a comparatively low level, the control of hæmorrhage is easier, as it is possible to maintain an elastic tourniquet in position until all the principal vessels have been secured, and the risk of subsequent sepsis is diminished, as the wound is well to the outer side of the limb, and the risk of septic contamination from the genital region is considerably lessened. The stump is good and is longer than that left after the other operations. Therefore it should always be performed, if possible.

Indications. Disarticulation at the hip-joint may be required for the following conditions :—

(i) *For injury*, generally in the form of gunshot wounds or very extensive crushes, such as those resulting from machinery accidents. In most cases of injury it is possible to save a certain amount of the femur, and this should always be done, if possible, as it adds greatly to the strength of the resulting stump and an artificial limb is more easily worn. Disarticulation will be required, however, in these injuries when the neck of the bone is shattered.

(ii) *For growths of the femur*. All sarcomata of the femur, with the exception of myeloid tumours of the lower end of the bone, call for complete removal of the femur, and a disarticulation at the hip-joint is therefore necessary.

(iii) *After failure of excision of the hip for tuberculous disease.* It is not uncommon for profuse suppuration, with commencing lardaceous disease, to persist in spite of excision of the hip. In these cases removal of the limb not only favours satisfactory drainage, but enables the surgeon to get freer access to the tuberculous mischief in the acetabulum or the pelvis, and a cure not infrequently results.

Choice of operation. In all cases in which it can be practised the operation known as Furneaux Jordan's, or some modification of it, should be employed. The diminution in the immediate mortality from shock and hæmorrhage is very striking. It is only when the soft parts are too much damaged or when they are encroached upon by a growth that any of the other amputations should be adopted.

Methods of controlling hæmorrhage during the operation. The sources of bleeding in these amputations are numerous; in front are the superficial and deep femoral vessels, while behind are the large gluteal artery and the smaller sciatic, as well as the considerable circumflex vessels on the inner and outer sides. It is this free arterial supply that makes the risk of hæmorrhage so great, and it is therefore a matter of importance to adopt the best way of preventing it. In Furneaux Jordan's amputation it is possible, should the surgeon desire it, to command the circulation during the first part of the operation by means of a circular india-rubber bandage applied horizontally round the thigh below the groin; but this only suffices until the vessels have been secured after the circular part of the amputation, and has to be removed while enucleation of the upper end of the bone is proceeding. A number of methods have been employed, of which the following are the most useful:—

(a) **Compression of the vessels by a figure-of-eight elastic tourniquet.** For the proper application of this method an assistant should be told off specially to look after it, but if the surgeon be short-handed, it is possible to use it without the aid of an assistant. It is used as follows: a piece of india-rubber tubing, the same thickness as that used for the horizontal elastic band in Esmarch's tourniquet and about four feet long, is put firmly on the stretch and its centre applied over the tendon of the adductor longus just at the fold of the groin; thence it is carried forwards nearly parallel to Poupert's ligament and backwards across the great sacro-sciatic notch, the two limbs meeting and crossing immediately above the crest of the ilium about two inches outside the anterior superior spine. To make the compression of the vessels more certain a firm sterilized pad may be applied over the line of the common femoral in front and the gluteal behind (see Fig. 132). The ends of the tourniquet, which should be sterilized by boiling, are then twisted round one another and pulled

forcibly upwards by the assistant whose duty it is to see that neither the anterior nor the posterior pad slips during the operation, and to increase the tension on the tourniquet if necessary. If no assistant be available a large pad should be placed across the crest of the ilium, and the two limbs of the tourniquet made to cross over it, and the ends should then be carried horizontally round the trunk and tied together firmly over another large pad on the opposite side in the interval between the trochanter and the crest of the ilium. A tourniquet applied in this way controls the sources of bleeding front and back quite satisfactorily.

In all cases the limb should be elevated for five minutes before the

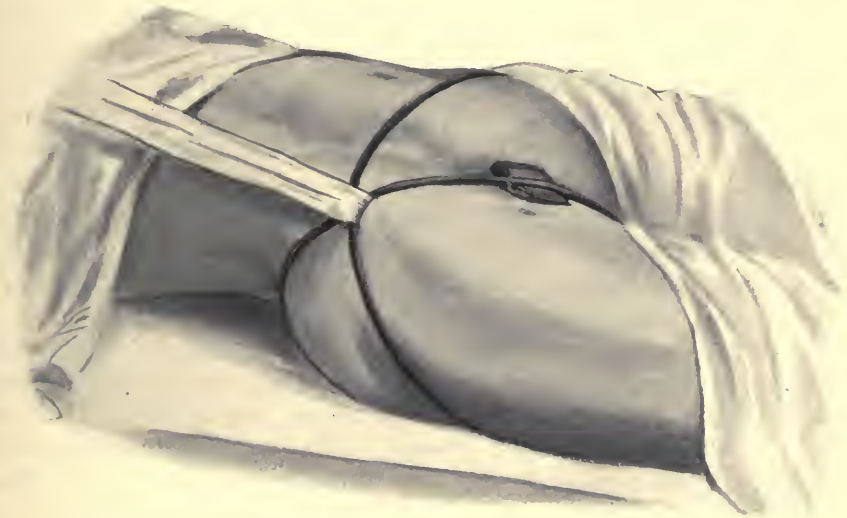

FIG. 132. INDIA-RUBBER TOURNIQUET APPLIED FOR DISARTICULATION AT THE HIP-JOINT. . A pad is applied over the femoral artery and a loop of bandage is passed beneath the crossing of the cord in order to prevent its slipping; one limb of the loop should pass behind the thorax, the other in front of it.

tourniquet is applied, in order to empty it of blood; after the tourniquet has been put on, the amount of compression may be gauged by feeling for the pulse in the arteries of the foot. If there be no assistant to whom the management of the tourniquet can be specially delegated, or if the patient be fat and there be a risk of its slipping, a simple way of keeping it in place is to take a long loop of bandage, pass it beneath the tourniquet, and to carry the two ends, one behind the back and the other across the chest, and to tie them together over the opposite shoulder so as to form a loop or sling which prevents the tourniquet from becoming displaced. Another way to prevent displacement when an assistant is available is to apply the tourniquet in the figure-of-eight already described, and

then to pass sterilized strips of bandage beneath the tourniquet over the femoral and gluteal vessels, which the assistant can pull upon and so prevent the tourniquet from slipping down. There is a constant tendency for the rubber bandage to slip during the latter part of the operation, as the disarticulation tends to displace it.

The chief drawbacks to this really excellent plan of controlling bleeding in these severe operations are three in number. Firstly, it requires an assistant specially told off to look after it. Secondly, there is the well-known persistent paralytic oozing after its removal; objectionable as this feature is in any operation, it becomes doubly dangerous at the hip when we remember the great size of the oozing surfaces. Thirdly, the rubber tubing is apt to perish unless it is kept in water and in the dark, and at the last moment the surgeon may be deceived by the tourniquet upon which he has been relying.

(b) **Compression of the abdominal aorta.** This is a simple and effective method in children. In adults, however, it can only be satisfactorily employed in very spare subjects, and is difficult in those who cough or strain under the anæsthetic. It may be effected according to either Macewen's or Lister's method. In the former the assistant stands on the left side of the patient on a level with the umbilicus with his back to the patient's head, and thrusts his closed fist down upon the aorta, so as to compress it against the spine just to the left of the middle line and immediately below the umbilicus. It is well for the assistant to stand upon a stool on his left foot so that he can exert any amount of pressure required with ease by simply leaning more of his weight on his right hand; he can easily gauge the pressure he is exerting by feeling for pulsation at Poupart's ligament. This method is applicable to adults.

Another very useful plan is Lister's method, which is most suitable for children or for very spare subjects. A piece of stout board, which should project nearly a foot beyond the trunk on each side, is passed beneath the back on a level with the umbilicus, a firm pad is placed over the aorta a little to the left of the middle line and just below the umbilicus, and stout india-rubber tubing is then stretched across the pad on the front of the patient's abdomen like the string of the bow from one end of the board to the other. Suitable notches or holes are cut in the ends of the board to secure the tubing.

Neither of these methods is likely to cause damage to the soft parts if the pressure be judiciously exerted. Both are therefore preferable to compression by any unyielding instrument such as Lister's abdominal tourniquet or digital compression reinforced by heavy weights.

(c) **Preliminary ligation of the common femoral artery.** When the incision for the disarticulation is begun in the immediate vicinity of

Poupart's ligament attempts to control the vessel by pressure directly over it would be futile. The best plan, then, is to cut down upon the common femoral vessels at the commencement of the operation, divide them between ligatures, and push the ends well out of the way; the remaining steps of the operation can then be completed without fear of bleeding from these vessels or their branches. The only arteries likely to give rise to trouble will be the gluteal and sciatic, but it is easy to pick up these as they are divided if a watch be kept for them.

These are the chief methods of controlling the hæmorrhage, and one or other will generally suffice.

FURNEAUX JORDAN'S OPERATION

The following method will, on the whole, be found the best for performing this amputation. There are several ways of doing what is known as Furneaux Jordan's amputation; Mr. F. Jordan's original description will be found in his *Surgical Enquiries*.

Operation. The surgeon in each case stands on the outer side of the limb. After the figure-of-eight india-rubber tourniquet or some other suitable hæmostatic means has been applied, the patient is drawn right down the table, so that nearly the whole of the pelvis projects beyond its end, and is turned half over on to the opposite side. Care must be taken that the patient does not slip off the table during the various manipulations incident to the operation, and in order to prevent this it is a good plan to pass a sterilized roller towel round the perineum and secure it to the head of the table.

I have found it an excellent plan to elevate the lower end of the table in these cases until the patient is almost in the Trendelenburg position. This serves a double purpose; it prevents the patient from slipping off the table and also tends to minimize the loss of blood and mitigate the severity of the shock. If the operating table is adjustable in height it is lowered as much as possible so as to bring the pelvis on a level with the surgeon's elbows, but if not the surgeon will have to stand upon a stool of suitable height.

Every possible precaution must be taken against shock; the temperature of the operating theatre must not be less than 70° F., all bleeding vessels should be picked up as they are seen, and the steps of the operation should be performed as rapidly as possible. The question of making use of spinal analgesia (see p. 40) must be carefully considered in all these cases. There seems to be evidence accumulating to the effect that it lessens the shock in these very grave cases. It should certainly be used for traumatic cases.

The surgeon passes his arm beneath the affected limb and divides

the skin as low down the thigh as he deems advisable by a circular sweep ; if possible this should be at least eight inches below the top of the great trochanter. The first incision only goes through the skin and deep fascia, which are raised for about two inches by a few touches of the knife. The skin is then retracted as firmly as possible, and the muscles are divided down to the bone by a circular sweep of the knife, the femoral vessels being cut at the same time. The vessels are secured either in forceps or by ligatures before the remaining stages of the operation are proceeded




FIG. 133. INCISION FOR FURNEAUX JORDAN'S DISARTICULATION AT THE HIP. The two dots are placed respectively upon the level of the crest of the ilium and the top of the great trochanter.

with ; they are easily visible, and can be picked up without difficulty. When this has been done, a vertical incision (see Fig. 133) from the circular incision up to the mid-point between the great trochanter and the crest of the ilium is made over the outer surface of the femur, and the soft parts are rapidly stripped off the bone up to the level of the lesser trochanter. These stages of the operation may be done with the long knife which will be necessary for the circular division of the muscles. A few touches suffice for the separation, except behind, where the muscles arise from the linea aspera ; the knife may be used freely here. The advantage of marking out the skin incision first is that this structure is allowed

to retract to its full extent, and the incision through the muscles is made on a higher level than it would otherwise be; this enables the flaps to be brought together more neatly.

The amputating knife is now exchanged for a short-bladed stout scalpel, with which the remaining steps of the operation are performed. The best way to disarticulate is to have the limb abducted, rotated somewhat outwards and slightly depressed, when the psoas and iliacus can be divided at their insertion into the lesser trochanter, and the front of the neck of the femur and the capsule of the hip-joint are readily exposed. The latter is incised and the cotyloid ligament is divided by cutting firmly

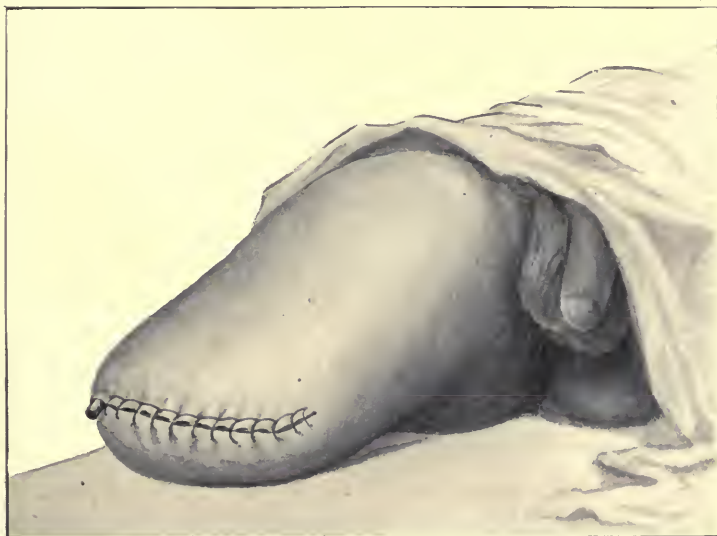

FIG. 134. STUMP LEFT AFTER FURNEAUX JORDAN'S AMPUTATION.

down to the bone with the point of the knife, the long axis of which is kept strictly parallel to the long axis of the neck of the femur (see Fig. 137). The assistant is now instructed to depress the limb still further and rotate it forcibly outwards, when the head of the bone comes out of the acetabulum, and the ligamentum teres can be divided. The head of the bone should be grasped in the left hand and the muscles attached to the great tuberosity divided by the knife passed behind it.

The raw surfaces of the large wound thus left are approximated as well as possible by deep sutures of stout silkworm-gut. One or two large drainage tubes are inserted according to the nature of the mischief for which the amputation is performed, and the edges of the flaps are brought together with continuous sutures (see Fig. 134). One large

drainage tube at the lower end of the wound suffices for cases of growth or injury, but in a septic case a second large tube should be inserted at the upper end, passing horizontally to the region of the acetabulum.

There are certain special points in connexion with this operation which require mention.

When amputating on the right side the vertical limb of the incision is best made from above downwards, the point of the knife being sunk down to the bone midway between the top of the great trochanter and the crest of the ilium. Upon the left side, however, the vertical incision

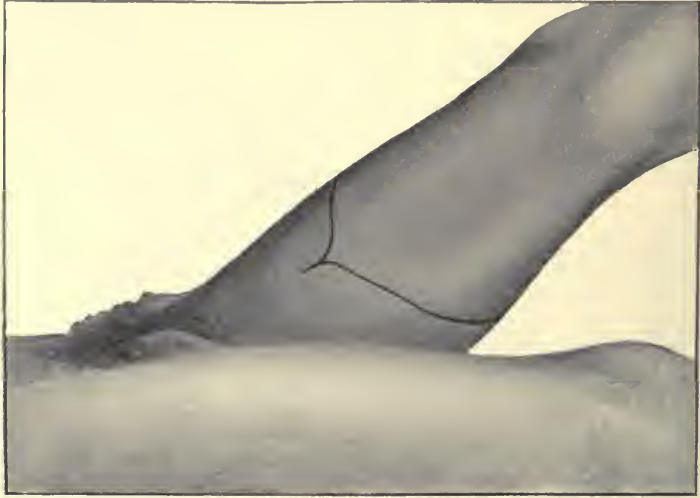

FIG. 135. IMPROVED METHOD OF MARKING OUT THE FLAPS IN FURNEAUX JORDAN'S AMPUTATION. This, taken in conjunction with Fig. 133, is the method of incision described in the text.

should be carried upwards from the circular amputation to the same point.

If the instructions for the amputation given above are followed out strictly, the resulting stump is a little clumsy, as the muscles tend to protrude through the edges of the skin and render suturing difficult. I find it preferable to modify the operation somewhat in order to obtain a more satisfactory stump. For instance, when operating upon the right side the arm is passed beneath the limb and an incision is made across the back of the thigh from the mid-point on the inner aspect of the limb to the corresponding point on the outer; this incision is boldly convex downwards and marks out a curved posterior flap, but it only goes through the skin and deep fascia. When the mid-point on the outer aspect of the thigh is reached, the incision is carried vertically up the limb and

ends midway between the top of the great trochanter and the iliac crest. Then, by bending over the thigh, an anterior flap is marked out similar to the one behind and joining it at the commencement of the vertical incision along the outer surface of the thigh. This gives a better racket-shaped incision than the other (see Fig. 135), and a much neater stump results if these antero-posterior flaps, consisting of skin and subcutaneous tissues, be raised for the first two inches, and the muscles then divided by a circular sweep. When operating upon the left limb it is easier to cut the anterior flap first and then prolong this up into the vertical incision, and finally to cut the posterior flap. The remaining stages of the operation are similar to those already described (see p. 251).

In amputations done for a failed excision of the hip the operation is easier, as the head of the bone does not require to be disarticulated; this is the difficult part of the ordinary operation for the beginner. In these cases, however, the operation is often a very long one, as it is necessary to cut away all sinuses and foci of disease, and the acetabulum will require to be gouged out, while any intra-pelvic abscess must be opened up and drained. If there be extensive disease that cannot be got cleanly away, undiluted carbolic acid may be applied to the diseased surfaces and the wound left widely open and stuffed with iodoformed¹ gauze. It is useless merely to put in large drainage tubes and trust to the disease subsiding.

The difficulty of opening the capsule of the hip-joint and disarticulating rapidly is best got over by keeping the long axis of the knife parallel to that of the neck of the femur; this divides the cotyloid ligament transversely, and a slight depression of the limb will then cause the head of the bone to start out of its socket.

If the patient be obviously suffering seriously from shock during the operation, the final stages should be carried out in the Trendelenburg position, while at the same time an injection of two pints of normal saline solution should be given *per rectum*; if necessary this quantity or more may be administered subcutaneously or even intra-venously.

AMPUTATION BY LATERAL FLAPS—THE SO-CALLED ANTERIOR RACKET METHOD

This is an excellent amputation for cases in which the conditions do not allow of Furneaux Jordan's amputation being done; for example, cases in which there is extensive damage to the soft parts, or those of growth implicating the tissues of the thigh too high up to allow

¹ By this term is understood cyanide gauze impregnated with sterilized iodoform. The iodoform is sterilized by prolonged submersion in 1 in 20 carbolic lotion and is then powdered freely over the moistened cyanide gauze.

Furneaux Jordan's long flaps to be cut. The operation is accompanied by more shock than the preceding one, and special precautions must be taken to minimize this ; it is well to do it under spinal analgesia in most cases, certainly in those where the operation is done for an injury.

The first stage of the operation is exposure of the common femoral vessels and their division between ligatures, the two ends being pushed aside out of the way of damage during the later stages of the operation ; for the steps of this see p. 322. The patient is then brought down the

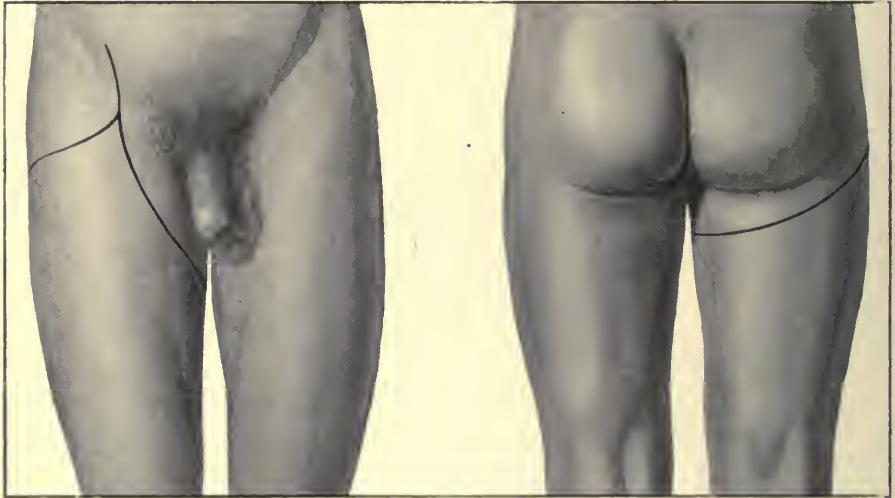


FIG. 136. INCISIONS FOR THE ANTERIOR RACKET DISARTICULATION AT THE HIP.

table so that the buttocks project well beyond it, and the surgeon, standing on the patient's right of the limb to be operated upon, prolongs the incision for ligature of the femoral vertically downwards for a short distance and then carries the knife across the inner aspect of the thigh a good four inches below the fold of the groin, and makes it traverse the posterior surface of the thigh obliquely upwards and outwards until it reaches the outer aspect of the limb, across which it passes on a level with the base of the great trochanter to reach the vertical incision made for ligature of the common femoral about an inch below Poupart's ligament (see Fig. 136).

The incision is carried through the deep fascia all round so as to allow the skin to retract, and the surgeon then takes a shorter knife and divides the muscles. The sartorius, rectus, and tensor fasciæ femoris are divided

in turn, and then the assistant flexes the thigh, rotates it inwards and adducts it, whilst the surgeon divides the insertion of the gluteus maximus. The limb is then adducted and rotated inwards still more forcibly, the outer flap is pulled well up behind the great trochanter, and the knife is passed behind this process, dividing the muscles attached to it.

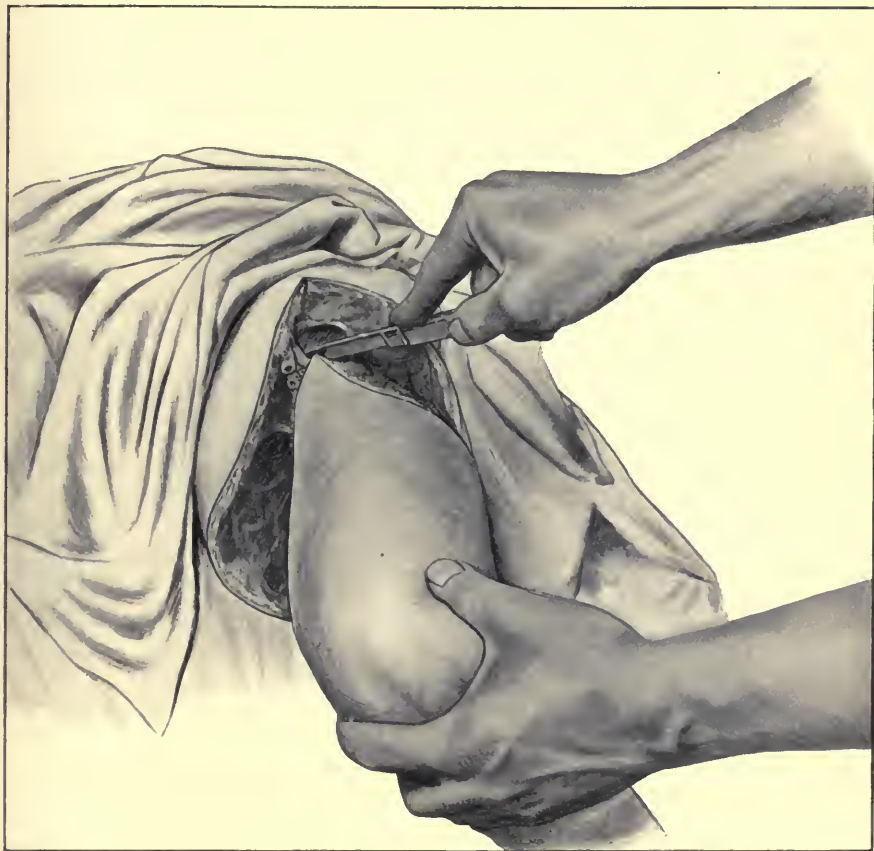

FIG. 137. DISARTICULATION AT THE HIP BY THE ANTERIOR RACKET METHOD. The knife is dividing the cotyloid ligament so as to allow the head of the bone to escape from the acetabulum. It will be noticed that its long axis is kept parallel with the neck of the femur.

The muscles of the inner flap are next divided down to the bone, and the limb is abducted and rotated outwards, so as to expose the lesser trochanter, from which the ilio-psoas is detached. The assistant abducts the limb still more firmly and depresses it somewhat, whilst the surgeon divides the cotyloid ligament with the point of his knife, the long axis of

which is kept parallel with the long axis of the neck of the bone (see Fig. 137). If the limb be depressed still further, the head of the bone will now start out of the joint, and the surgeon can seize it in his left hand, pass his knife behind it, and divide the capsule sufficiently to let it come well forward. He then takes a long knife, passes it behind the head of the bone, and divides from within outwards all the structures that have

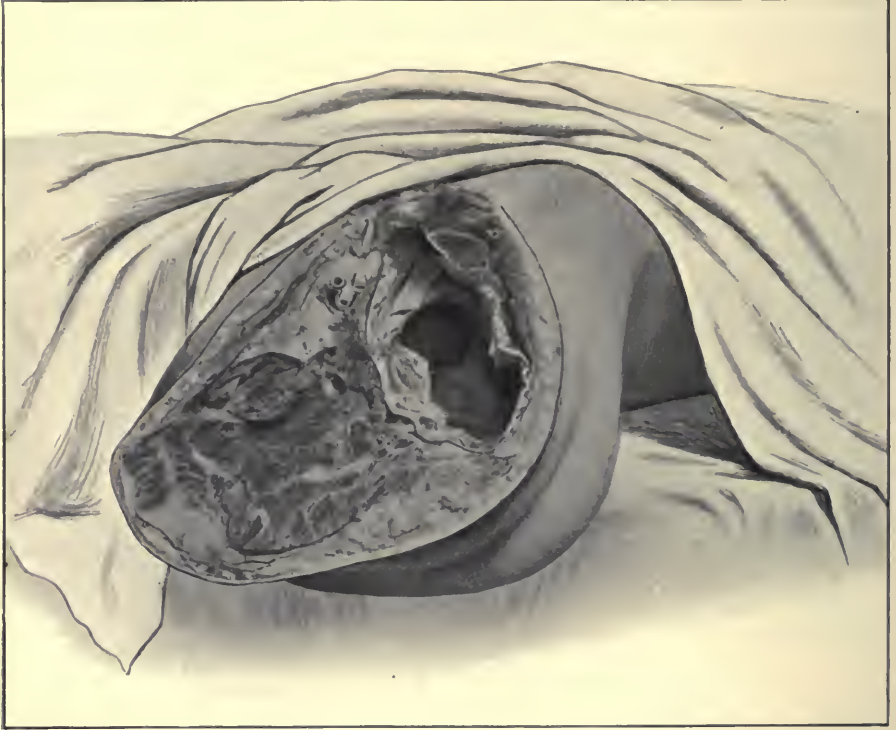


FIG. 138. FLAPS LEFT AFTER DISARTICULATION AT THE HIP BY THE ANTERIOR RACKET METHOD. It will be noticed that the flaps on the inner side are much longer than those on the outer, and the result when sewn up is shown in Fig. 139.

escaped division on the posterior surface. There will be some bleeding here from the branches of the gluteal and sciatic vessels, which must be arrested by picking up the vessels as they are divided.

When the flaps are brought together the cicatrix is well to the outer side and away from the genital region (see Fig. 139). A large drainage tube is inserted at the extreme outer end of the wound, and the flaps are kept together by deep sutures of stout silkworm-gut, reinforced by a continuous skin suture.

The only other disarticulation in this situation that requires mention is that by *transfixion* ; in this operation the flaps are antero-posterior. This method offers no advantage over the others save that of rapidity, and, as it has many disadvantages, such as bleeding and the increased risk of

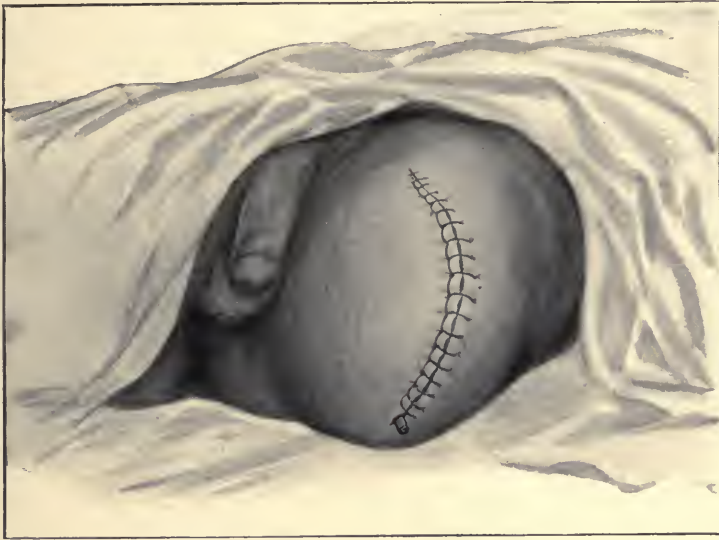

FIG. 139. STUMP AFTER DISARTICULATION AT THE HIP-JOINT BY THE ANTERIOR RACKET METHOD. The line of the cicatrix is well away from the genital region.

sepsis, it is not to be recommended and will not be described. It can only be called for upon the field of battle, and then, except in the hands of a surgeon who has practised it exclusively, would probably prove far more dangerous than either of the methods already described.

SECTION IV
OPERATIONS UPON ARTERIES,
VEINS, AND LYMPHATICS

BY

FRED^c. F. BURGHARD, M.S. (Lond.), F.R.C.S. (Eng.)

Teacher of Operative Surgery in King's College, London; Surgeon to King's
College Hospital; and Senior Surgeon to the Children's Hospital,
Paddington Green

CHAPTER I

ARTERIORRHAPHY

THE work of Senn upon suture of blood-vessels first drew the attention of surgeons prominently to the fact that it might be possible to suture a wound in the wall of an artery with a good prospect of maintaining the circulation through the vessel unimpaired, and without giving rise subsequently to an aneurysmal dilatation of the vessel wall. The old view that a cicatrix in the wall of an artery must lead to the production of an aneurysm was therefore proved to be fallacious ; the explanation of the frequency with which wounds of an artery are followed by aneurysm is probably to be found in the fact that when the edges of the wound are not brought together healing cannot occur.

Indications. It is obvious that arteriorrhaphy can be only rarely required, but under certain circumstances it would be most advantageous to be able to sew up a wound in the wall of an artery, and thereby avoid the risk of gangrene which occlusion of a large artery may entail. The chief conditions under which operation may be called for are :—

(i) *Wounds of the large arterial trunks.* These are not very common, and will probably be accidental wounds occurring in the course of surgical operations, such as a wound of the common carotid in operations for removal of glands in the neck, wounds of the axillary artery in breast operations, &c. Occasionally it may be possible to suture punctured wounds of one of the big vessels when compression has been applied to the bleeding point in time to prevent the patient from dying before help can be obtained. Under these circumstances the operation should find one of its most valuable applications.

(ii) *For the removal of an embolus* blocking one of the large arterial trunks, in order to remove the clot, re-establish the circulation, and obviate the embolic gangrene that is otherwise sure to follow. This operation has been done more than once, but hitherto with very little success (Sampson Handley,¹ *Brit. Med. Journ.*, 1907, vol. ii, p. 702). The

¹ Mr. Handley narrates an interesting case in which he attempted to unblock the femoral artery, which was filled with an embolus derived from the seat of an operation for strangulated hernia. In order to do this the aorta was compressed, and a stream of saline solution was injected through the profunda, which was cut across, by means of a ureteral catheter passed as high up as the aorta. Free bleeding from the profunda followed, but, as the superficial femoral remained blocked, the popliteal was opened, the common femoral compressed, and the superficial femoral washed out from the profunda. Unfortunately the patient's condition did not allow this part of the operation to be completed. Mr. Handley did not incise the artery directly, but this would be a quicker and probably a more effective method.

weak point in the procedure is that the embolus is usually infective and due to infective endocarditis, so that, even when the anatomical conditions allow of free access to and easy removal of the clot, the arterial wall will have become infected and septic thrombosis will follow the removal of the embolus. It is, however, possible that, even when this is the case, the time gained might allow the collateral circulation to become established and the gangrene therefore averted, or its progress arrested.

(iii) If the recently introduced method of treating *incipient gangrene* from defective arterial supply by reversal of the circulation of the limb (see p. 280) prove of practical service, arteriorrhaphy will become an important operation of surgery.

Various plans have been adopted for suturing incisions in arteries, and also for their end-to-end anastomosis after division. Of these the earliest methods were the through-and-through suture for closing wounds, taking up all the coats of the vessel on each side of the incision, and the invagination method of Murphy for end-to-end union; in this the proximal was invaginated into the distal end so as to get a firm joint, and the overlapping distal end was sewn to the wall of the invaginated part, taking up the two outer coats only. This method, however, is not only tedious and difficult to perform, but the rough divided end of the proximal invaginated portion projects into the lumen of the vessel, and allows fibrin ferment to escape into the circulation, with the result that thrombosis follows. It has been evident for some time that the earlier plan of introducing foreign bodies into the lumen of the artery for the purpose of supporting the suture is quite inadmissible, as coagulation is almost certain to follow.

As an improvement upon this method a suture was used in which the thread did not project into the blood-stream and so act as a foreign body promoting coagulation; it closely resembled Lembert's and penetrated only the outer and middle coats of the vessel, thus invaginating its walls somewhat. This method, however, was soon found to have two definite risks. The first was that the blood was apt to find its way between the coats of the artery and cause a dissecting aneurysm; the second was that the rough edge of the divided intima allowed the discharge of fibrin ferment into the circulation and promoted coagulation. The results were therefore generally poor. Dorrance, however (*Annals of Surgery*, 1906, vol. xlv, p. 409), improving upon the work of Carrel and others, has introduced a method of suture which is devoid of all the drawbacks above mentioned, and is the best with which the writer is acquainted. It is done as follows:—

Operation. The vessel is exposed for a distance of an inch or more on each side of the wound in it, and is clamped with suitable artery

clamps, such as Crile's (see Fig. 140), the blades of which are covered with rubber tubing. Only the right amount of pressure required to arrest the circulation should be exerted, and to ensure this the clamps should be screwed down until the bleeding from the wound in the vessel just stops. If Crile's clamps are not at hand a satisfactory substitute is a piece of sterilized tape about a quarter of an inch broad, which is passed under the vessel whilst the assistant places the pulp of his forefinger upon the upper surface of the artery and pulls the tape loop gently tight against it; this will arrest the circulation without damaging the arterial wall. Silk may be used instead of tape, but the latter exerts pressure over a wider area, and so is less liable to cause local damage to the arterial wall. It has been

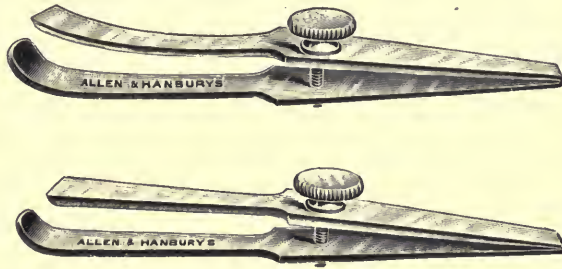


FIG. 140. CRILE'S ARTERY COMPRESSION CLAMPS. These are of two shapes, straight and curved, so as to facilitate application to different arteries; it is usual to sheath the limbs of the clamp with rubber tubing. The lower arm passes beneath the artery, the upper one acts as the compressor. The drawing is full size, and it will therefore be seen that the clamp does not get in the way; indeed, when it is employed for the temporary compression of the carotid artery for removal of growths in connexion with the buccal cavity, the entire instrument can be sewn up temporarily in the wound, which can then be covered with the dressing and is not liable to become infected.

amply proved by experiment that after a temporary compression of this kind exerted either by forceps or by ligature there are no permanent changes produced in the vessel wall.

When the circulation has been thus commanded, the wound is sutured with the finest spring-eyed round intestinal needle bearing the finest silk or celluloid thread obtainable. The method of suturing is very similar whether the operation be suture of an incision in the vessel or end-to-end union; it is explained in Figs. 141, 142.

When suturing a longitudinal incision the thread is first entered about an eighth of an inch from one end of the incision, made to penetrate only the outer and middle coats, brought out again and tied, the free end being left long. The needle is now made to penetrate all the coats of the vessel from without inwards on one side of the rent and as near

the edge as possible ; it is then carried through the walls of the vessel on the opposite side of the rent from within outwards. It then re-enters the arterial wall from without inwards, passes across the incision and penetrates the opposite side from within outwards, thus making a mattress stitch. This suture, however, is not tied in the usual way, but is continued as shown in the diagram throughout the length of the wound ; at every third loop the suture is carried back a stitch's breadth, as shown in the diagram, in order to maintain the steadiness of the approximation.

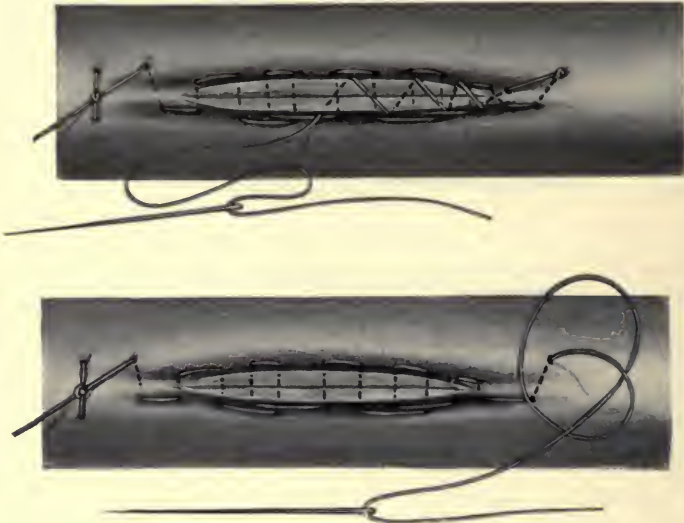


FIG. 141. DORRANCE'S ARTERY SUTURE. The suture is employed for the repair of a longitudinal wound of an artery. The lower figure shows the continuous mattress suture with the ' throw-back ' in every third loop. It also shows the method of commencing and fastening off these sutures. The upper figure shows the suture continued from right to left to unite the superficial edges of the wound ; when it is finished, its free end is fastened to the free end of the knot on the left-hand end.

On emerging at the other end of the incision the thread is passed through the two outer coats of the vessel an eighth of an inch from the end of the incision, and is there tied in a single knot. The continuous mattress suture thus formed is reinforced by a second continuous running stitch taking up the edges of the incision between the loops of the mattress suture (see Fig. 141) ; when this reaches the point at which the original suture commenced, the two ends are tied together and the suture is complete. This method of suture approximates the intima on the two sides and at the same time buries the suture deeply so that it is out of the blood-stream, and there is neither any foreign body nor any cut

vessel wall in contact with the blood-stream anywhere; the result is that little if any coagulation occurs at the seat of union.

After the suture has been completed, the clamps are removed, first from the distal and then from the proximal end, and, after having ascertained that the wound is blood-tight, it is a good plan to surround the artery by the deep fascia, which is sutured over it so as to make a loose cellular envelope.

When an end-to-end suture has to be made, it is done as shown in




FIG. 142. END-TO-END UNION OF AN ARTERY BY DORRANCE'S SUTURE. The suture is similar to the one in the previous figure, and the diagram shows how the cut ends of the vessels are everted into a sort of flange.

Fig. 142. The first suture is a mattress suture, the needle being passed through all the coats of the vessel from without inwards on the proximal side, and from within outwards on the distal side and back in the reverse direction. This gives a mattress suture with the ends projecting from the distal end; these are firmly fastened together so as to evert the ends of both segments. The remainder of the suture is completed by the continuous mattress stitch already described with the 'throw-back' at every third stitch. When this has completely encircled the vessel the end of the suture is fastened to the free end of the first mattress stitch. A continuous running stitch is carried all round, joining together the lips of the wound outside the suture as for a simple incision (see p. 263).

CHAPTER II

ENDO-ANEURYSMORRHAPHY

THIS term is used to designate an operation described by Dr. Rudolph Matas of New Orleans in a paper entitled 'An Operation for the Radical Cure of Aneurysm based upon Arteriorrhaphy' (*Annals of Surgery*, 1903, vol. xxxvii, p. 161), which has opened up a wide field for speculation and has created much enthusiasm, especially among American surgeons. Matas's operation is founded upon the two following assumptions:—

(i) That arterial suture or arteriorrhaphy is now a procedure of proved value, inasmuch as it is capable of securing permanent union between the opposed walls of the vessel.

(ii) That the intima of an artery is always prolonged from the lumen of the vessel for a certain distance at least along the wall of the aneurysmal sac, and that it is through the medium of changes occurring in the intima that union occurs when the two layers are brought into apposition by suture.

The object of the operation is to effect the radical cure of an aneurysm without any of the drawbacks inseparable from the older methods. Up to the date of publication of Matas's paper a radical cure could only be obtained by ligaturing the artery on both sides of the sac quite close to the latter, and then either extirpating the sac completely or leaving it *in situ* after incising it freely, evacuating all the clot and providing proper drainage. Under certain circumstances extirpation of the sac of an aneurysm is often hazardous and sometimes impossible without doing serious damage to important surrounding structures, whilst simple incision and drainage of the sac may lead to tedious healing or septic infection.

In certain suitable cases, moreover, Matas's operation aims at doing more than effecting a radical cure of the aneurysm. As will be seen later, it may be possible to reconstitute the lumen of the parent artery, and thus cure the aneurysm while maintaining the circulation unimpaired. This may be of the highest practical importance in certain cases which are referred to later.

Indications. By its author this operation is said to be 'applicable to all aneurysms in which there is a distinct sac and in which the cardiac end of the main artery can be provisionally controlled'. While this

statement is no doubt correct, it does not, however, follow that one would be well advised to resort to its performance for the radical cure of every aneurysm that fulfils these conditions. For example, it would certainly be an unnecessarily laborious mode of treating small aneurysms of the extremities below the knee or the elbow; in cases such as these the size and situation of the parent vessels render it more convenient to apply a ligature above and below the aneurysmal sac and to excise the latter completely.

When dealing with aneurysms of the larger arteries, and particularly those situated in the groin, the axilla, the popliteal space, or the bend of the elbow, however, the position is different, and here Matas's operation is likely to prove a real advance in surgery. It may be taken for granted that, as long as the collateral circulation is not interfered with unduly, the ideal method of treating aneurysms wherever situated is to excise the sac completely, if possible, and, if not, to turn out all the clot and to secure rapid healing after having cut off the aneurysm from the circulation. In the situations just mentioned Matas's operation offers a better chance of attaining this ideal than does an attempt to apply a ligature on each side of the sac followed by partial or complete extirpation of the latter, for the anatomical condition of affairs in the axilla, the popliteal space, and the bend of the elbow is such as to preclude all idea of an extensive operation of this kind being done with any approach to safety. Matas's operation, on the other hand, does not disturb any important parts, while it effects a complete obliteration of the aneurysm.

It is, however, in connexion with the treatment of aneurysm of the aorta and its main branches that this operation bids fair to be of the greatest importance in the immediate future, should experience show that the good results of arterial suture obtained up to now prove to be permanent. Provided that compression can be applied on both sides of the aneurysm in these cases, there seems to be reason to think that the method may successfully effect a radical cure in these grave and important cases either by causing obliteration of the vessel as it enters and leaves the aneurysmal sac, or even by reconstituting the lumen of the artery, so that the great danger of gangrene from want of collateral circulation may be overcome. Even in the case of the aorta itself this method seems to offer a better chance of success than the application of a ligature.

A consideration of the comparatively few published cases leads to the conclusion that Matas's operation is most suited for the following cases:—

(i) Aneurysms of the extremities in which it is difficult to extirpate the sac wall after securing the vessel on each side of the sac. The

chief of these are aneurysms in the groin, popliteal space, axilla, and bend of the elbow.

(ii) Aneurysms of the aorta or its main branches in which compression can be effectually employed on both sides of the aneurysm ; effectual compression is a *sine qua non* and may be impossible here (*vide infra*). This question is discussed more fully in connexion with ligature of the abdominal aorta (see p. 339).

The 'restorative' operation of Matas is useless for a fusiform aneurysm ; if any plastic operation could be done for an ordinary fusiform case it would be a resection of the diseased artery followed by end-to-end anastomosis or some plastic operation with a portion of a vein as an intermediate connexion. This will scarcely ever be advisable, however, even if it be possible (see p. 398). 'Reconstructive' operations are of use in fusiform aneurysms where the lumen of the artery is very large (*vide infra*) and sufficient healthy arterial wall is present to allow it to be brought together to form a fresh lumen.

Matas's operation is not always the best method of treating cases of arterio-venous aneurysm or traumatic diffuse hæmatoma ; for these, simple arteriorrhaphy (see p. 263) suffices if the vessel be of sufficient size to make the operation worth while. In small vessels a ligature above and below the opening in the artery will be the best method of treatment. In bad cases, however, it may be found simpler to incise the vein, suture the orifice as in endo-aneurysmorrhaphy, and then suture the opening in the vein.

Operation. What is usually called 'Matas's operation' really embraces two distinct operations. In the one the object is to obliterate the lumen of the main artery altogether, whilst in the other an attempt is made to maintain the circulation through the main vessel unimpaired after effecting a radical cure of the aneurysm. These variations of the operation may be called the 'obliterative' and the 'restorative' methods respectively, and their applicability to any given case is governed by the pathological conditions present. Thus, except in certain cases referred to later (see p. 275), there is no chance of restoring the lumen of the vessel when its whole circumference is involved in a fusiform aneurysm ; here the obliterative method must be employed. In a sacculated aneurysm, however, the orifice of communication between the artery and the sac involves only a small part of the vessel wall and there is an opportunity not only of curing the aneurysm, but also of reconstructing the artery afterwards ; in other words, of employing the restorative method.

The first step in the operation is to control the circulation through the aneurysm effectually ; unless this be done the operation is one of

great difficulty and danger, although a case has been recorded by Abbé¹ in which a gluteal aneurysm was treated in this manner without effective compression of the parent artery. For a popliteal aneurysm or one at the bend of the elbow an Esmarch bandage is the simplest and most effectual method, as it cuts off the blood-supply from both sides, and, moreover, there is no bleeding from the sac even if vessels are given off from its wall, as is often the case in popliteal aneurysm. When the aneurysm is in the axilla or the groin it will be necessary to expose the main vessel well above and below it and to compress it with a temporary ligature (see p. 77) or with Crile's clamp (see Fig. 140). The latter is perhaps the most useful method of effecting temporary compression of the main artery alone, as it is easy to apply and its pressure is uniform, whereas a temporary ligature held by an assistant may be either too tight or too loose. The blades of the forceps should be sheathed with rubber, and when they are in position they should be screwed down very slowly until the pulse in the vessel below disappears. For an aneurysm of the aorta or the iliac vessels it would be necessary to have the vessel digitally compressed on both sides of the aneurysm, after having secured thorough exposure.

Dr. Matas, in a most interesting personal communication with which he has courteously furnished me since the above lines were written, lays special stress upon this question of 'effectual' control of the circulation. I cannot do better than quote the actual words of one who is not only personally familiar with the operative details to such an exceptional extent, but who is also *au courant* with what has been done in this line throughout the surgical world. He says:

'The problem increases in complexity and difficulty as the aneurisms to be attacked approach the root of the limbs, the neck, or regions where constriction is impracticable. This preliminary control of the circulation by obtaining a mastery of the great regional trunks in order not only to control the direct circulation in the aneurism, but that which is supplied by the collateral vessels, still remains, in the treatment of aneurisms by the intrasaccular methods, as good and thorough a test of the training and resources of a surgeon as it ever was in the days of the ligature and of extirpation. To illustrate what is meant I need only consider the difficulties in completely controlling the circulation

¹ Abbé (Annals of Surgery, vol. xlviii, 1908, p. 10) records a case of aneurysm of the gluteal artery treated by Matas's method of continuous oblitative suture. He states that he attempted to control the circulation in the artery by employing a temporary silk ligature on the external iliac. On cutting into the aneurysm, however, he found that it bled freely, which is not surprising if it be correctly reported that he put the ligature round the external and not the common or internal iliac vessel; there is, however, probably a mistake in the report. The finger plugged the orifice of communication with the sac while the suture was carried out.

in high femoral, ilio-femoral, and iliac aneurisms in which the opening of the sac may be followed by the most formidable and even fatal hæmorrhage if the inexperienced operator has trusted to the compression or temporary ligation of the parent artery immediately above and below the sac. The difficulty lies in the fact that numerous and large collateral branches open into the parent trunk at its junction with the sac, or empty into the sac itself in the intermediary space between the inlet and the outlet of the aneurism. In femoral, ilio-femoral, and iliac aneurisms of large size and of the fusiform type, the control of the parent trunk immediately above and below the sac is of no avail; the great vessel commanding the entire collateral supply of the limb must be compressed. In these cases it is only by compression and control of the common iliac through an abdominal incision that the collateral hæmorrhage from the obturator, sciatic, pudic, and gluteals can be controlled.

‘In a very recent case of ilio-femoral aneurism even the compression of the common iliac and of the abdominal aorta at the bifurcation was not sufficient to secure an absolutely dry field. On opening the sac which had apparently collapsed, blood spurted out in a considerable stream, which was found to come from a well-developed epigastric which could not be controlled by the direct compression of the common iliac or of the abdominal aorta. It was only by direct pressure on the bleeding orifice in the sac and its direct occlusion with a clamp that the bleeding was arrested and that the technic was carried out to completion with deliberation. However, the temporary compression of the common iliac which controls all the branches of collateral importance given by its internal or hypogastric branches is sufficient, as a rule, to secure a safe, if not an absolutely ischemic field in the majority of cases.

‘In the upper extremity, the hemostatic problem increases in gravity as we approach the axilla and the subclavian areas. In axillary aneurisms the third subclavian should be controlled, while an elastic bandage applied to the arm as near as possible to the lower pole of the sac prevents the lower collaterals from feeding the aneurism after it is opened. The circulation in the right subclavian should be controlled by a preliminary compression of the innominate, and on the left side by the first division of the subclavian.’

The sac of the aneurysm should be exposed with the least possible amount of dissection; generally a vertical incision in the line of the artery will be employed. It is essential that the soft parts should not be separated from the sac, and only important anatomical structures should be avoided as the sac is exposed. The latter is then incised from end to end in the long axis of the tumour. The clot is turned out and the cut edges of the sac are fully retracted so as to get a good view of the interior of the aneurysm. The surgeon notes the number of openings into the sac, whether there be a single one, as in the case of a sacculated aneurysm, or two, as in a fusiform aneurysm, or more, as will be the case when branches are given off from the part of the artery

involved in the sac. In a fusiform aneurysm two circular orifices are seen, one above and one below, connected together by a shallow vertical groove. In the sacculated aneurysm the orifice of connexion is usually ovoid. The number of orifices usually decides the nature of the operation to be performed; for fusiform aneurysms the obliterative method, and for sacculated aneurysms the restorative, are the operations of choice.

(a) **The obliterative suture.** Any laminated clot adhering to the intima is rubbed away with a piece of sponge or gauze from the neighbourhood of the orifices of communication between the sac and the vessel. Each

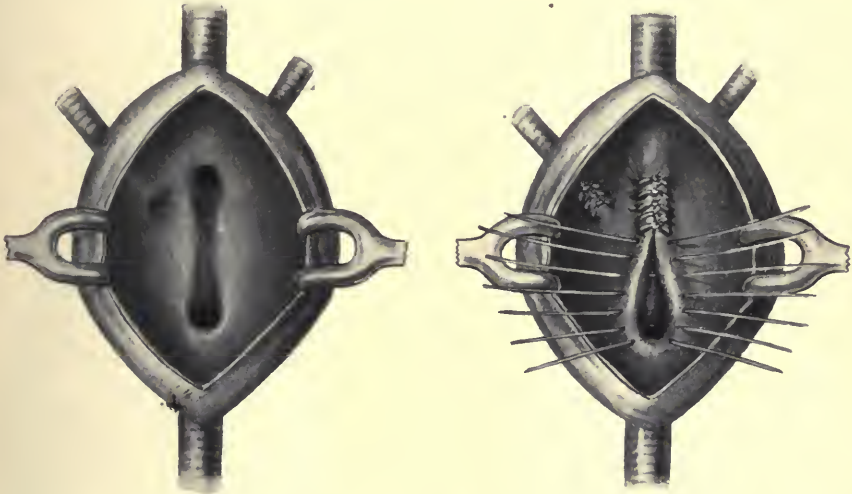


FIG. 143. THE OBLITERATIVE SUTURE IN ENDO-ANEURYSMORRHAPHY. (After *Matas.*) The figure shows the method of passing the sutures, which are here represented as interrupted ones. A branch coming off from the aneurysmal sac is shown secured in a similar manner.

orifice is then closed by a series of sutures inserted as shown in Fig. 143. These sutures may be of any material, but on the whole chromicized catgut is the best, as it holds firmly and long enough for union to occur, while it is eventually absorbed. The suture should be threaded in a fully curved, spring-eyed, round intestinal needle (see Fig. 144), and should be as stout as the needle will carry, so that it fills the hole in the tissues made by the penetration of the needle. Both needle and suture will vary with the size of the artery to be sutured, but the walls of the vessel are generally tough and the surgeon therefore may use a comparatively large size. The needle will need to be introduced by means of a needle-holder. Either interrupted or continuous sutures may be employed; perhaps a continuous running suture is the best. Each

suture should be about one-eighth of an inch from its predecessor and should take a firm hold upon the tissues. It should be inserted through the inner wall of the sac about a quarter to a sixth of an inch from the edge of the communication with the artery, and should then pick up the



FIG. 144. SPRING-EYED NEEDLES. These are most useful in Matas's operation. They are easily threaded by springing the catgut into the eye, and, by being round and not triangular, they do not tend to enlarge the opening in the tissues as they pass through. The spring eye is most useful, as it enables them to be easily threaded with a suture that would only pass with difficulty through an eye of the ordinary shape.

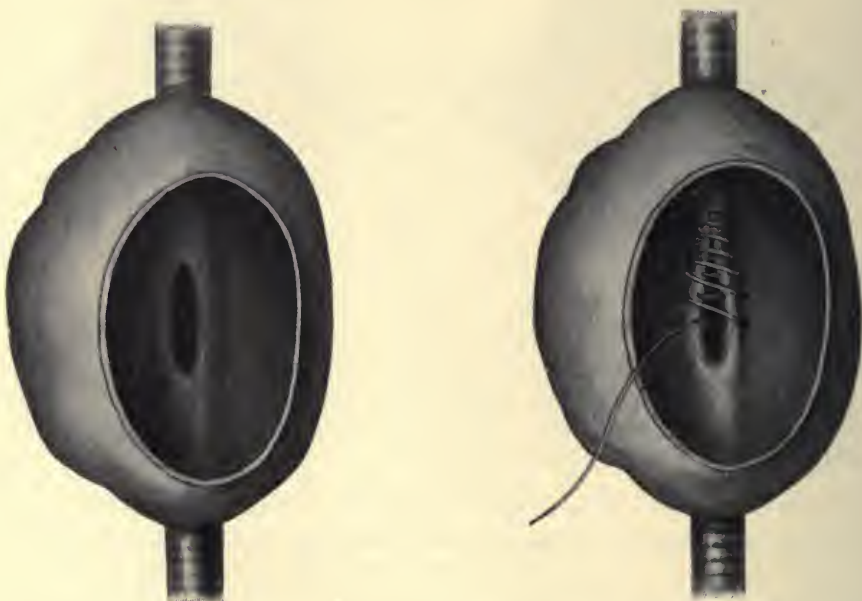


FIG. 145. THE RESTORATIVE SUTURE IN ENDO-ANEURYSMORRHAPHY. (*After Matas.*) In the left-hand figure the orifice of connexion between the artery and the aneurysmal sac is seen. In the right-hand one this orifice is closed by a continuous suture in the manner recommended by Matas.

floor of the latter as it enters the sac; it is finally passed through the opposite margin of the aperture of communication (see Fig. 143). Enough sutures are introduced to occlude the opening completely. The sulcus formed in the floor of the aneurysmal sac by the remains of the arterial

wall stretching between the two orifices of communication may be quilted up by running the suture along it from one opening to the other if desired. This, however, is not necessary; it suffices to suture separately the orifices of communication with the sac. The orifice of any branch given off from the aneurysmal sac should be sutured in a similar manner. Matas advises a second layer of sutures in order to bury the first; this, no doubt, makes a stronger union, but is not absolutely necessary. The later stages of the operation are common to the two methods (*vide infra*).

(b) **The restorative suture.** In a case suitable for this method

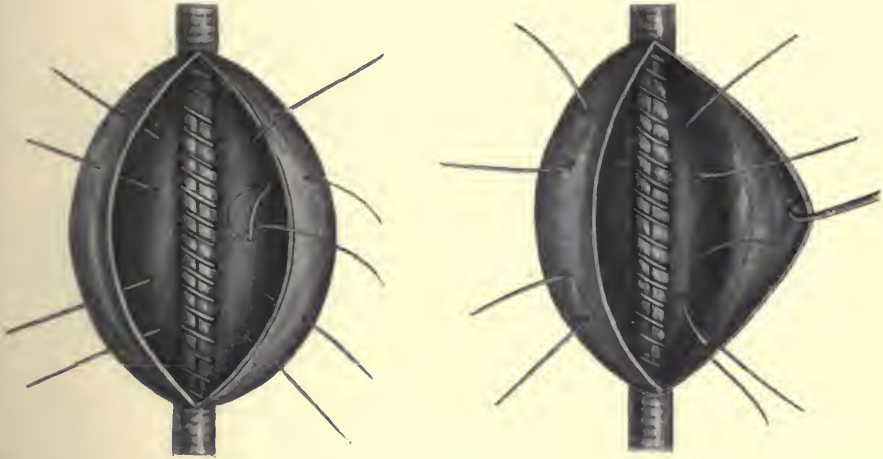


FIG. 146. OBLITERATION OF THE WALL OF THE SAC IN ENDO-ANEURYSMORRHAPHY. (*After Matas.*) The oblitative suture has been employed and the second suture layer, consisting of a continuous running stitch, has been applied as recommended by Matas. The various stages of introducing the sutures by which the superficial wall of the aneurysm is brought into close contact with the deep wall are shown. These sutures penetrate the skin over the superficial sac wall, as is shown in the following figure.

the aperture of communication between the aneurysm and the artery is single, and the object of the suture is to approximate its edges so as to cut off communication between the aneurysm and the artery without obliterating the lumen of the latter. Similar needles and sutures are used, and the needle is entered well outside the edge of the aperture, but is brought out through its margin (see Fig. 145). It is then introduced through the margin on the opposite side and brought out some distance from the edge. This gives a firm hold and does not diminish the lumen of the vessel. A continuous suture is best. A second layer of sutures external to this may be used in order to secure still firmer apposition; this suture of course takes up the sac wall only. It will be

seen that in this method the suture must lie in the blood-stream unless the approximation be carried out with great nicety. Therefore the risk of thrombosis after the operation should be considerable.

Obliteration of the sac. The final stages of the operation are similar in both cases. When the suture has been completed, the pressure on the artery is relaxed in order to see if the suture be blood-tight; if it be found to leak, the pressure is reapplied and more sutures are inserted. The most important part of this stage of the operation is the obliteration

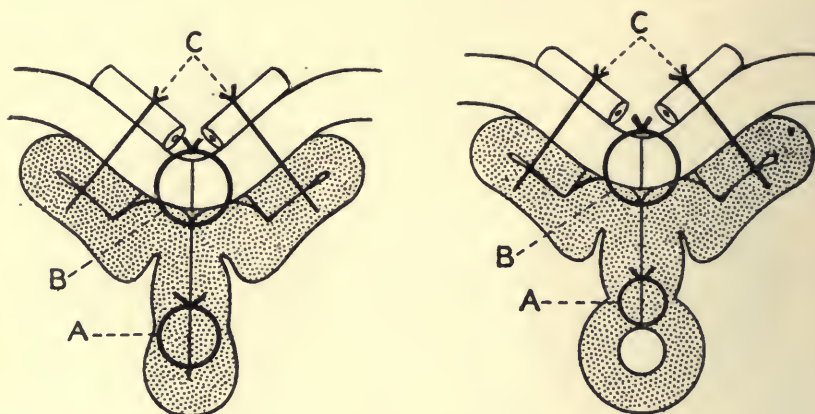


FIG. 147. DIAGRAM ILLUSTRATING A TRANSVERSE SECTION THROUGH AN ANEURYSM OBLITERATED BY MATAS'S METHOD. (After Matas.) In the left-hand figure the obliterative suture has been employed, whilst in the right the restorative form has been adopted. In both cases, in order to avoid confusion, only one layer of sutures in this region has been depicted.

A is the suture shutting off connexion with the artery; in the left-hand figure this is the obliterative, in the right the restorative form.

B is the suture fastening the skin to the wall of the sac in the middle line, while c are the sutures coapting the superficial and deep walls of the aneurysmal sac passing through the skin and tied over a roll of gauze or piece of india-rubber tube.

of the sac. Matas folds the walls of the sac upon themselves, and thereby avoids leaving a cavity which would require drainage. The sac walls are approximated by stout catgut or silkworm-gut sutures which take up the deep wall of the sac and are then passed through the superficial wall of the sac and the skin over it together and are tied over a pad of dressing; Figs. 146 and 147 show how this is done. It may be possible to clip away the superficial portions of the sac wall, leaving only the deeper parts to be brought into contact with the skin, which is sutured down to them.

Matas suggests in his paper (*loc. cit.*) that in large fusiform aneurysms, when the wall of the vessel is not too much diseased, it may be possible to perform a 'reconstructive' operation instead of the obliterative one.

This can only be done in the case of a very large vessel, such as the common femoral or the iliacs, and Matas proposes to do it by suturing the walls of the vessel over a piece of drainage-tube of suitable size, which acts as a splint or mould for the newly-constructed lumen and which is pulled out after all but the last two or three sutures have been inserted and tied over it (see Fig. 148). It will thus be seen that there are really three distinct operations: (i) the obliterative, (ii) the restorative, and (iii) the reconstructive. The last two differ in the fact that whereas in the former the lumen of the artery is intact but for the orifice of com-

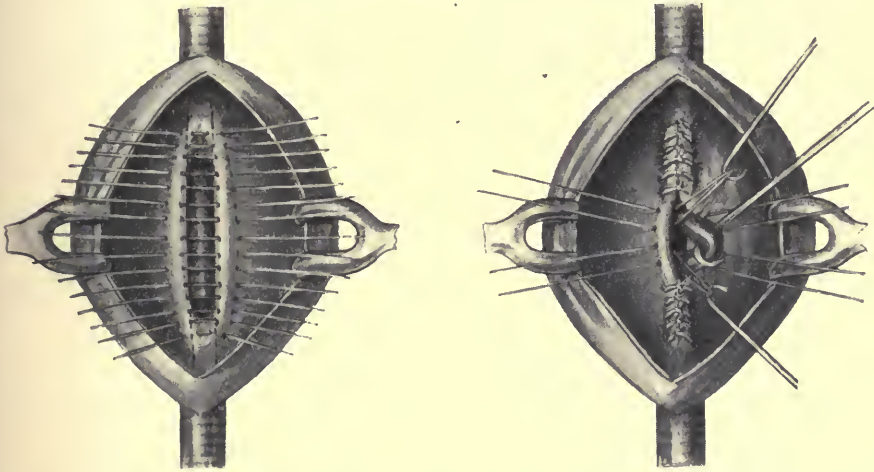


FIG. 148. THE RECONSTRUCTIVE METHOD AS APPLIED TO LARGE ARTERIES. (*After Matas.*) The figure shows a piece of rubber tubing laid into the lumen of the parent artery and the walls of the aneurysmal sac brought together by interrupted sutures over it so as to reconstruct the lumen of the artery. The right-hand figure shows the tube being hooked out after the majority of the sutures have been tied over it but before the last four are fastened.

munication, in the latter the lumen has to be almost entirely reconstructed out of the wall of the sac. This last operation is probably more valuable theoretically than practically; it would probably only be suitable for aneurysm of the abdominal aorta or the upper part of the common iliac, as it is almost certain to be followed by thrombosis, and it is hardly worth while to take the trouble of doing what is a very difficult operation except for cases such as those mentioned in which it is of great importance to stave off thrombosis, even though it only be for a short time, in order to allow the collateral circulation to establish itself to some extent.

Results. In this connexion it may be well to quote from an abstract

of a paper read before the Surgical Section of the American Medical Association on June 3, 1908, by Dr. Matas, which I owe to his kindness.

Dr. Matas informs me that up to the present time the number of cases reported has reached 101. In a summary of those reported up to June 1, 1908, he enumerates eighty-five treated by fifty-two surgeons, of whom forty-nine were American. His summary is appended, and is probably the most complete and accurate in existence.

' NUMBER OF CASES OF ENDO-ANEURISMORRHAPHY REPORTED UP TO
JUNE 1, 1908

(Arterio-venous aneurisms excluded.)

Total number of cases	85
„ „ operators	52
<hr/>	
Typical operations	77
Atypical „	8
<hr/>	
American operators	49
Foreign „	3

ANATOMICAL DISTRIBUTION (TYPICAL AND ATYPICAL)

Abdominal Aorta	2
External Iliac	1
Gluteal	1
Ilio-femoral	5
Femoral	18
Popliteal	50
Posterior Tibial	1
External Carotid	1
Subclavian	1
Subclavio-axillary	2
Axillary	1
Brachial	2
Total	85

Over 58 % Popliteal.

Over 21 % Femoral.

Total obliterative	59	69.2 %
„ reconstructive	13	15.4 %
„ restorative	13	15.4 %
	85	100.0

Results : Total, 85 cases ; 78 recoveries ; and 7 post-operative deaths.

Secondary hæmorrhages, 2 ; gangrenes, 4 ; relapses, 4 (all in reconstructive cases).

' To sum up our review of the mortality, if we eliminate the two aortic cases of Lozano and Munro, the popliteal of Stafford (tetanus), the femoral of Stafford (rupture of secondary aneurism, ligature of iliac, gangrene and sepsis), the external iliac of Levi Old (pulmonary embolism), five would be eliminated out of the list, leaving two which can be directly charged to the operative

procedure, or at least as direct post-operative sequence. The legitimate mortality, thus reduced from seven to two deaths in eighty-five cases, would be equivalent to 2.3%. Secondary hæmorrhage, two in eighty-five cases, or 2.3%. Gangrene, four in eighty-five cases, or 4.6%. If we eliminate Lozano's, Stafford's popliteal cases, in which the vein was simultaneously injured and ligated, and Levi Old's ilio-femoral, in which gangrene followed the secondary ligation of the external iliac, the percentage of gangrenes legitimately attributable to the intra-saccular operation would be one in eighty-five, or 1.1%.

'*Relapses*: Occurred only in the reconstructive operation; four in thirteen, or 28.9%; to the total, 4.7%. It is to be noted that, in one of these cases, the aneurism was cured permanently after the relapse by a secondary obliterative operation (popliteal, Danna); and from a previous knowledge of the conditions existing in the sac in two other cases, one popliteal (Morris) and one ilio-femoral (Danna), there is every reason to believe that a similar cure could have been effected if an obliterative operation had been performed after the relapse had been recognized.

'In only one case (Binnie's popliteal), the local conditions would have been apparently unfavourable to any local intervention.

'Without attempting to discuss with Binnie the special types of fusiform aneurism in which the reconstruction of an artery is more or less indicated, I will simply state that in the vast majority of cases of aneurisms of the extremities, and especially of the popliteal and femoral, which furnish the most crucial test of the efficiency and safety of any radical method, the obliterative method proved thoroughly satisfactory in accomplishing its purpose without interfering with the vitality of the distal parts.

'The evidence which has accumulated and which I have gathered in my tables is quite sufficient to prove that in this respect the obliterative operation accomplishes the cure of the aneurism with less risk to the distal parts than either the ligation or the method of extirpation. This is now a proven clinical fact. The indications which must determine in any given instance whether an obliterative operation can be performed with absolute safety or not, will never be answered satisfactorily until an unerring clinical test of the adequacy of the collateral circulation after the preliminary compression of the main trunk which feeds the aneurism will be at our command. If the peripheral blood-pressure is shown by the manometer to be more or less sustained after the compression of the main trunk above the aneurism, then the obliterative operation may be safely applied (see Von Opperl, *Deutsch. Archiv für Chirurg.*, Bd. lxxxv, 1908). If, on the other hand, the blood-pressure falls to zero, it is evident that the collateral circulation is inadequate, and that no chances should be taken with an obliterative operation or with any procedure whatever (ligature, extirpation, &c.) which would permanently obliterate the parent artery. In these rare cases—as a rule, aged or advanced sclerotic subjects—it may be the safer plan to limit the intervention to a partial, gradual occlusion of the main trunk on the proximal side of the aneurism.'

CHAPTER III

OPERATIONS FOR ANEURYSMAL VARIX AND VARICOSE ANEURYSM

ANEURYSMAL VARIX

IN connexion with the operative treatment of this affection, the possibilities that the work of Senn, Murphy, Matas, and others upon methods of suture of the arteries has opened up may be usefully borne in mind. While in the case of the smaller vessels there is no objection to removing the portions of the artery and vein concerned in the aneurysmal varix, this might possibly endanger the circulation in the limb when the affection occurs high up, as, for instance, in Scarpa's triangle. In these cases there seems reason to think that the best operation is to expose the seat of the varix by careful dissection, and, after the anatomy of the affection has been made out accurately, to clamp both vessels temporarily above and below the communication, which is then obliterated.

Operation. The simplest plan is to cut across the connexion between the artery and the vein and to suture the wound left in the artery and in the vein separately whenever this is possible. The opening in the vein should be closed by a lateral continuous suture applied as described on p. 398, while that in the artery is brought together by a continuous mattress suture similar to that shown on p. 264, which brings together the intima on each side of the incision and does not allow either the cut edge of the artery or the suture material to project into the blood-stream. It would probably not be necessary to encroach upon the lumen of the artery to any extent, as the connexion between the artery and the vein would probably be sufficiently extensive to allow of the arterial walls being coapted without any considerable diminution of its calibre. As a rule, the dilatation of the vein present will allow the incision separating the two vessels to be made somewhat at the expense of the vein wall without running any risk of unduly narrowing the calibre of that vessel when it is sutured. This has the advantage that it will leave enough tissue outside the opening into the artery to bury the suture layer closing it.

It is not to be expected, however, that this method will be always applicable. The opening into the artery may be so placed or of such a size and shape that arteriorrhaphy will not be practicable without

running a great risk of occluding the lumen of the vessel. Even in this case, however, there is no valid reason why the attempt should not be made, as the only alternative is to apply a ligature to the artery above and below the orifice of communication and thereby cut off the circulation. The common femoral artery is large enough to enable the necessary manipulations to be carried out, and even some narrowing of its lumen is presumably preferable to its complete occlusion. Should thrombosis occur subsequently at the seat of operation a certain amount of time may be gained in which the collateral circulation will have a chance of establishing itself.

The treatment of the communication in the vein will offer little difficulty. The vessel will be so large that the opening in it can be closed easily by suture without much risk of thrombosis occurring.

VARICOSE ANEURYSM

Operation. This will either take the form of a modified endo-aneurysmorrhaphy (Matas's operation) or the application of a ligature to the vessel above and below the sac, leaving the untouched aneurysm to empty out into the vein, the circulation through which will be unaffected.

On comparing the merits of the two operations the balance of advantage seems to lie with Matas's operation, since it ought to be able to secure not only a radical cure of the aneurysm but probably also a reconstitution of both artery and vein. Simple ligature of the main artery above and below the communication will not necessarily cure the condition. Should there be a branch coming off from the sac, this may escape notice at the time of operation and may cause the condition to persist and necessitate ligature of the vein above and below the communication at a later date. Matas's operation, however, has the advantage that by means of it any branches given off from the sac wall can be secured if present, and all danger of reflux through the aneurysm into the vein by means of collaterals between the ligatures on the parent vessel would be done away with. It is essential for its successful performance, however, that it shall be possible to control the circulation effectively on both sides of the aneurysm both in the artery and the vein, and therefore the modified Matas operation will not always be possible. For an interesting paper on this difficult subject see Bickham (*Annals of Surgery*, May, 1904).

The steps of the operation have been already described in full (see p. 268). In these cases it would be necessary to control the circulation through both artery and vein, and, at the end of the operation on the artery, to close the opening into the vein by similar sutures.

CHAPTER IV

REVERSAL OF THE SYSTEMIC CIRCULATION IN A LIMB

IN gangrene due to deficient arterial blood-supply the tissues die because their natural source of nourishment is withheld from them, and there is something very attractive in the idea that, if the blood could be supplied to the parts through some other channel than the occluded arteries, gangrene might be either obviated altogether or its progress arrested. The simplest way of doing this is to cause arterial blood to pass from the artery above the site of occlusion through its companion vein whose tributaries serve the same area. The first step in this direction was made by Carrel and Morel, who, in 1902, joined the carotid artery to the external jugular vein in an animal that survived for several months, the vein apparently playing the part of an artery. In order, however, to make the test more conclusive Carrel and Guthrie (*Annals of Surgery*, 1906, vol. xliii, p. 203) divided the femoral artery and vein in a dog and anastomosed the proximal end of the artery to the distal end of the vein and *vice versa*, with the object of directing the arterial blood through the femoral vein, along its tributaries, through the capillaries, and eventually returning it as venous blood along the smaller branches of the femoral artery, until it reached the anastomosis with the proximal portion of the femoral vein in the thigh, when it should resume its normal course through the systemic venous channels. The chief difficulty in reversing the blood-stream in the lower extremity in this manner is to be found in the presence of the valves, and Carrel and Guthrie found that they acted as a definite hindrance, but not as a complete bar to reversal of the blood-stream. The first effect of the anastomosis was to cause distension of the vein with arterial blood as far down as the nearest set of valves, and this dilatation was soon accompanied by pulsation and a further distension of the vessel, which in its turn led to gradual overcoming of the valves, and a further dilatation of the vein with arterial blood. In the dog upon which they operated they found that almost complete reversal of the blood-stream had occurred in about three hours' time, and that the red blood filled the vein, passed the reverse way through the capillaries, and issued as dark blood into the artery, whence it was conveyed back to the venous system through the first anastomosis. In order to get the best results they found that an end-to-end union of

artery to vein should be made in preference to a lateral anastomosis, as in the latter case much of the blood found its way back direct to the heart from the proximal portion of the vein, and the pressure was not sufficient to force the valves.

This interesting and promising laboratory result has been put to the test of actual practice more than once. Thus, Hubbard (*Annals of Surgery*, 1906, vol. xlv, p. 559) reports a case of dry gangrene of the toes in a man of eighty with a loud systolic murmur, upon whom he performed the operation for reversal of the circulation. The superficial femoral artery and vein were exposed in Scarpa's triangle, and bared for about two and a half inches, various branches being ligatured to enable this

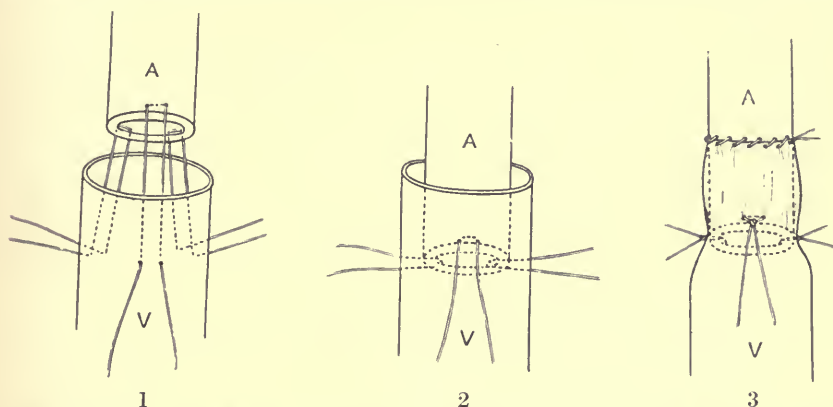


FIG. 149. DIAGRAM ILLUSTRATING THE METHOD OF REVERSING THE SYSTEMIC CIRCULATION. A is the artery and V the vein, the latter being larger than its companion vessel. 1 shows the mattress sutures inserted through the coats of the artery, passed into the lumen of the vein, and brought out through its walls. In 2 the artery has been drawn down inside the vein by traction on these mattress sutures, which are shown tied in 3, the cut edge of the vein being secured to the outer coat of the artery.

to be done. Each vessel was then clamped on the proximal side with a special Crile's artery clamp (see Fig. 140), and on the distal side by a piece of supple rubber tubing. They were then cut across, the artery being divided on a lower level than the vein in order to facilitate the first anastomosis; this step, however, rendered the second anastomosis unnecessarily difficult. The divided proximal end of the artery was then drawn into the open distal end of the vein by three mattress sutures introduced as shown in Fig. 149, so as to make an overlapping joint; the overlapping edges of the vein were then secured to the outer coat of the artery by a few fine catgut sutures. When the clamp was removed from the anastomosed vessels the vein partly filled and began to pulsate freely before the wound was closed. A second similar anastomosis was

then practised between the proximal end of the vein and the distal end of the artery, but in this case the operation was rendered much more difficult by the separation between the ends due to the division of the vessels on different levels.

After the operation no immediate change was noticed, the limb remaining as warm as its fellow and without œdema ; the veins did not pulsate, although they were rather fuller than on the opposite side. The gangrene spread slowly in spite of the operation, and amputation was therefore performed at the 'seat of election' about a month after the anastomosis. The veins did not contain any arterial blood, but both the anterior and posterior tibial arteries did, and spurted 'with fairly good force'.

Mr. C. A. Ballance operated, on September 20, 1907, at St. Thomas's Hospital, on a patient for senile gangrene of the right toes. Pulsation was felt in the femoral artery at Poupart's ligament, but not in the popliteal space. The gangrene was spreading, and it was therefore determined to attempt to limit it by reversal of the systemic circulation. As it was taken for granted that the femoral was probably patent from the popliteal upwards, an incision was made over it in Hunter's canal with the object of dividing both artery and vein, the latter on a somewhat higher level than the former so as to enable the vein to be drawn over the divided proximal end of the artery like a sleeve and sutured in position. When, however, the artery was divided, it was found that there was a thrombus in its interior, and the artery had to be slit up for a distance of nearly three-quarters of an inch before its lumen was found to be clear. This made it impossible to invaginate the artery into the vein, and an end-to-end suture had to be employed ; this was done with the finest silk and the smallest needles available. Immediately after the anastomosis had been effected, no pulsation occurred on removing the clamp from the artery. After an ineffectual attempt to unblock the vessel by removing a ligature on a small branch below the anastomosis, and passing up a small scoop into the lumen of the vessel, a vertical slit was made in the arterial wall above the anastomosis and a thrombus was removed. This incision was sutured, and, on removing the clamp, the vein at once distended and pulsated freely. There was some little leakage from the line of the incision in the artery, but none from the anastomosis.

After the operation it was noted that, while there was no pulsation in the arteries of the leg and foot, the vein pulsated freely right down to the dorsum of the foot. This, however, did not persist, and had disappeared by the third day. The patient died suddenly in February, 1908, apparently from thrombosis of the mesenteric vessels, but in the meanwhile

the apparent effect of the reversal of the circulation had been the production of increased warmth in the affected limb, together with diminution of the pain and a marked arrest of the gangrene with the formation of a line of demarcation.

This operation has been repeated since, and, although I am not aware of any more published results, it has been unsuccessful in arresting gangrene in more than one instance. It is, however, a method that is probably worth a more extended trial, and it would seem that the earlier in the disease that it is performed, the better is the chance of securing a good result. It would of course only be employed for those cases in which the gangrene is dependent on the want of arterial blood-supply, and it is therefore most applicable to cases of senile gangrene. It will hardly be appropriate to conditions of an embolic nature, as in them the embolus is generally septic and is better treated by direct incision, removal of the clot, and suture of the incision in the artery (see p. 262). It is also just possible that it may be of service in alleviating those distressing cases of spreading gangrene due to progressive arterio-sclerosis in young subjects.

Since the above was written, Professor Wieting has published a case of what he claims to be the first completely successful reversal of the circulation (*Deutsch. Med. Woch.*, July 9, 1908) for a case of gangrene due to arterio-sclerosis. The patient had already had one leg amputated for gangrene, and the other foot and leg were cold and livid. Under spinal analgesia the femoral artery was divided and invaginated into the vein through a lateral opening, a ligature being applied to the vein above the seat of anastomosis and the free end of the artery being made to project into the lumen of the vein. The sutures did not penetrate all the coats of the artery. The foot became warm and of normal colour; all the signs of impending gangrene disappeared.

CHAPTER V

LIGATURE OF ARTERIES

GENERAL CONSIDERATIONS

LIGATURE of an artery in continuity is an operation that at the present time does not receive as much attention as was devoted to it in former years. With the introduction of asepsis the good effects of the improvement in surgical methods were shown in a striking manner in the results of the ligature of arteries. Up to that time there were two great risks attached to these operations which were peculiar to them ; they were secondary hæmorrhage and gangrene of the limb. The most gratifying results followed the use of aseptic precautions, and secondary hæmorrhage practically disappeared from the complications of the operation. It is true that secondary hæmorrhage may still occur after ligature of the largest arteries, in spite of all precautions to the contrary, but it has become evident that in the vast majority of cases the cause of secondary hæmorrhage was really sepsis, and that if this can be avoided many of the elaborate precautions laid down by former writers on the subject are unnecessary. Similarly, it was soon discovered that the occurrence of gangrene in the limb is far less frequent when asepsis is attained, and it became clear that sepsis plays an important part as an exciting cause of gangrene. The septic inflammatory swelling that often followed ligature of a main vessel was sufficient to embarrass the circulation and precipitate gangrene. Since the introduction of aseptic methods it has been found that not only the main artery but also the main vein may be ligatured without risk of gangrene, and the two vessels may even be tied simultaneously with a fair chance of gangrene being avoided, provided that the wound remains aseptic.

Moreover, the treatment of aneurysm has undergone a considerable revolution, mainly as a result of the introduction of aseptic methods, and the more radical methods of dealing with the aneurysm by cutting directly down upon it and either extirpating the sac entirely or dealing with it by some such method as Matas's operation (see p. 266) make ligature in continuity less frequently done than it was in former times. Finally, the application of aseptic methods to wounds has largely banished that form of secondary hæmorrhage accompanying fractures or wounds

of vessels which necessitated ligature of the main trunk before it could be controlled; the surgeon's confidence in his aseptic methods is now so great that he would never think of trying to treat a wound of a large vessel by pressure in preference to a careful exploration of the parts under the control of an Esmarch bandage in order to identify and ligature the bleeding points.

For all these reasons ligature of arteries in continuity has come to occupy quite a secondary position in modern surgery. The operations still have to be done under certain circumstances, however, and many of them have to be performed under circumstances of peculiar danger and difficulty. Owing to various exigencies connected with the supply and preservation of subjects, these operations still form the bulk of those set at examinations, and their consideration must therefore be gone into fully. Before dealing with the exposure and ligature of the individual vessels, it will be well to enumerate a few important principles applicable to the ligature of vessels in general.

Exposure of the artery. In many instances the artery is exposed by an incision which lies directly over its anatomical line, and there are many cases—such, for instance, as ligature of the upper third of the anterior tibial—in which accurate definition of this line makes all the difference between an easy and a difficult operation. In other cases, such as the posterior tibial, the anatomical line is disregarded by the surgeon and a set incision is made which experience has shown to be the easiest for the purpose. In all cases great importance should be attached to the proper placing of the incision, as it is difficult to rectify a mistake made in this respect without doing unnecessary damage.

The length of the incision should always be directly proportionate to the depth from the surface at which the vessel lies. This will therefore vary not only with the particular artery to be tied, but with the fatness or muscularity of the individual patient, and is a point that must always be taken into due consideration. An artery that can be exposed quite easily through an incision two inches long in a spare person would probably be quite inaccessible through a similar incision in a very fat or muscular one. In all cases the incision should be sufficiently long to enable the surgeon to carry out his manipulations with ease, but it must not be unduly long, as this is not only unskilful but may expose important structures to injury. The length of the incisions given in the following chapters are approximate only and apply to subjects of medium development.

The line of incision may, if the surgeon likes, be planned very accurately by marking upon the patient's skin the anatomical landmarks by which it is determined. This, however, is not necessary, as it is usually sufficient

to make an assistant place his fingers upon these landmarks ; the surgeon then draws an imaginary line between them and can thus plan his incision very accurately. It is essential, also, that, when taking the anatomical line, the limb should be in the position in which it is to lie when the operation is performed. Thus the line for the femoral artery (see p. 314) varies considerably according to whether the limb is flexed, abducted, and rotated outwards, or whether it lies flat upon the table.

There are a few points to be attended to in actually making the incision down to the artery. The knife, which should be held as shown in Fig. 150, should be made to cut strictly at right angles to the surface of the skin, so that its edges are not bevelled, and every incision of the deeper structures should be exactly the same length as the cutaneous one. This ensures the surgeon ample room if the skin incision is long enough



FIG. 150. CORRECT METHOD OF HOLDING THE KNIFE WHEN CUTTING DOWN UPON AN ARTERY.

originally, and he will therefore not fall into the error of making a conical pit in which he will find it extremely difficult to work. All incisions should be made with as clean a cut as possible and without any displacement of parts. Should it be desirable to retract the edges of the wound, this should be done equally on the two sides, unless there be some definite reason for pulling the wound to one side rather than to the other. There is no more fertile source of error in operating upon the dead subject than retraction of the wound to one side ; it leads the operator to work towards that side until he eventually travels hopelessly away from the line of the vessel he is seeking.

No director or tearing instrument should be employed, the point of the knife being used to divide the tissues, which should be picked up in fine-toothed forceps and damaged as little as possible. Intermuscular septa must be looked for and identified with the greatest care and gentleness. In the living subject they are not so difficult to find as they are in the cadaver. The unequal contraction of the different muscles and

the presence of fat and emergent vessels generally render the identification of intermuscular septa in the living a comparatively easy matter if due search be made for them. In the dead subject, however, there is nothing easier than to make an artificial intermuscular septum at any particular point, especially in the bodies preserved with formalin, in which the pallor of the muscular fibres and their friability are very misleading and tempt the operator to find or to make intermuscular septa where none exist. When the desired intermuscular septum has been reached, the knife should be no longer used, but the septum opened up with a blunt instrument, such as a fine spatula or dissector, until the finger can be inserted, when the latter is swept up and down and forms a most effectual muscular separator. When the septum has been opened up, the limb should be arranged so as to relax the muscles concerned to the utmost extent, and these should be kept out of the way by broad spatulæ used as retractors, which keep the muscles back better than the usual fenestrated retractors and at the same time are useful in reflecting light from outside into the depths of the wound, a point of considerable importance when such a vessel as the anterior tibial has to be picked up deep down on the interosseous membrane. It is in cases like this that a powerful forehead-light is of the greatest assistance; in some of the deeper-seated arteries the operation is most difficult without its help.

The identification of the artery is, or should be, quite easy in the living subject; it pulsates, and that should suffice for its identification anywhere. If not, its characteristic yellow elastic appearance cannot be well mistaken for anything else. In the dead subject, however, the identification is more difficult, but here its dead white colour, with the characteristic flat groove along the centre of its anterior surface, and its tough feel are sufficient to make a mistake improbable.

Ligature of the artery. Before the artery can be tied, certain steps must be taken to ensure that only the vessel is included in the ligature. There are nearly always important structures in intimate relation with the various vessels, such as veins, nerves, muscles, and other structures, and these have to be separated from the artery and pulled aside before the ligature is passed. Appropriate directions will be given in the following pages for each individual case. Here it is sufficient to make the general remark, that when there are venæ comites which closely surround the artery and anastomose across it, as is the case with the arteries below the knee and the bend of the elbow, it is best to pass the ligature around both artery and veins; attempts to separate the two structures invariably end in the most troublesome oozing, owing to the free anastomosis of the veins across the artery, and

there is no increased risk of gangrene occurring from the obliteration of the venæ comites with the main artery.

When, however, the artery possesses a well-defined sheath, as it does from the popliteal and brachial arteries upwards, this must be opened and the artery within it properly cleared before the ligature can be passed successfully. The sheath of the artery is a well-defined structure and there is a definite loose cellular interval between it and the wall of the vessel. In this the needle can be easily introduced close to the wall of the artery without the risk of any other structure being included, provided always that the point of the needle be kept well within the sheath. Important structures, such as the vein or nerve, usually lie outside the sheath, and this precaution alone, if properly adhered to, is sufficient to save them from inclusion in the ligature. At the same time, clearing the artery must be done carefully if it is to be done successfully. The classical way is to pinch up a small fold of the sheath with forceps parallel with the long axis of the vessel. The knife, held quite horizontal, is made to cut this small elliptical piece out of the sheath. One edge of this opening is now seized in fine-toothed forceps, and the point of the aneurysm needle is insinuated by gentle lateral movements between it and the adjacent wall of the artery until it has been passed half-way round the vessel on that side. It is then withdrawn, the opposite side of the incision in the sheath is seized and steadied, and the aneurysm needle is inserted between it and the artery, and a similar procedure is carried out until in this way the artery has been separated from its sheath round its whole circumference. Finally the needle is passed from the appropriate side between the artery and the sheath, the forceps steadying the corresponding edge in the incision in the sheath meanwhile.

Particular stress was laid by former writers upon the necessity for delicacy and care in performing this little operation. For instance, the operator was warned that on no account should he denude the artery of its sheath for more than a quarter of an inch, lest the nutrition of the vessel wall should be interfered with and secondary hæmorrhage should result. For a similar reason the vessel was not to be lifted out of its bed. We now know that neither of these points are of any practical importance, however much a rigorous observance of them may conduce to neatness in operating. In practice, therefore, the surgeon will clear the artery in such a manner as to enable him to pass the ligature between the vessel and its sheath with ease and without using any force. Any violence is almost certain to result in a contretemps of a serious nature, such as transfixion of the vessel wall or wound of some important neighbouring structure, such as the vein or the pleura. The surgeon should

have at hand aneurysm needles with various curves and bent at various angles. He may even have recourse to a probe, which can be bent to a suitable angle and upon which the ligature can be threaded.

The next important point is the question of *the material for ligature* and the method in which the ligature should be applied. Many different materials have been advocated from time to time, but the one that holds the field is silk; this can be rendered absolutely sterile by boiling, and therefore there need be no fear of its being the cause of sepsis or secondary hæmorrhage. The ordinary Chinese twist is generally used, and a moderate-sized thread will be required for ligature of most of the arteries. These are occluded by pulling the ligatures sufficiently tight to divide the inner and middle coats; this gives a characteristic sensation which cannot be mistaken. The first loop of the ligature is drawn tight in the ordinary way, and then the traction is kept up until the coats are felt to give way, when the second loop of the ligature is tightened. Care must of course be taken to tie a true reef-knot and not a 'granny'. Thus the traction required to divide the inner and middle coats necessitates the use of rather stouter silk than would be necessary were the vessel walls merely approximated.

Simple approximation of the vessel walls has been strongly advocated by Ballance and Edmunds (*Ligation in Continuity*, London, 1891) as a substitute for division of the inner and middle coats in all the larger arteries. Their experiments tend to show that, while simple approximation is sufficient to cause immediate and permanent occlusion of the vessel, it possesses the great advantage over division of the coats that there is no damage done to the arterial wall, which is as capable of withstanding the high arterial pressure as it was before ligature. As a matter of practice it is found immaterial whether or not the vessel walls are divided in the arteries below the common femoral, and, since it is easier to divide the coats than to approximate them carefully, this method of ligature is in general use for ligature of the superficial femoral and the third part of the axillary and all the branches below these vessels. Above these points, however, the pressure to which the damaged arterial wall will be exposed after division of its coats is so great that secondary hæmorrhage due to this mechanical cause is likely to occur even in an aseptic wound, and therefore simple approximation without division of the coats is distinctly preferable. For this purpose Ballance and Edmunds (*loc. cit.*) recommend the use of multiple ligatures of soft floss silk tied in what they term a 'stay-knot' (see Fig. 151). In this method at least two ligatures are employed; if more are used, as may be the case in large arteries such as the innominate, they should be arranged in pairs. The proximal of the two ligatures is first tied in a single loop,

and its ends are held on the stretch by an assistant just sufficiently tightly to bring the vessel walls together and check the pulsation on the distal side. This acts as a breakwater while the second ligature is made to approximate the vessel walls in a similar fashion; the two ligatures are applied closely side by side. The two ends of the primary loops of each ligature are then taken by the operator in each hand and are tied together to form the second loop of the knot (see Fig. 142). This makes a single flat knot which lies well upon the middle of the silk and does not press against the vessel wall as it pulsates. One reason for using double ligatures is that it ensures perfect stoppage of the

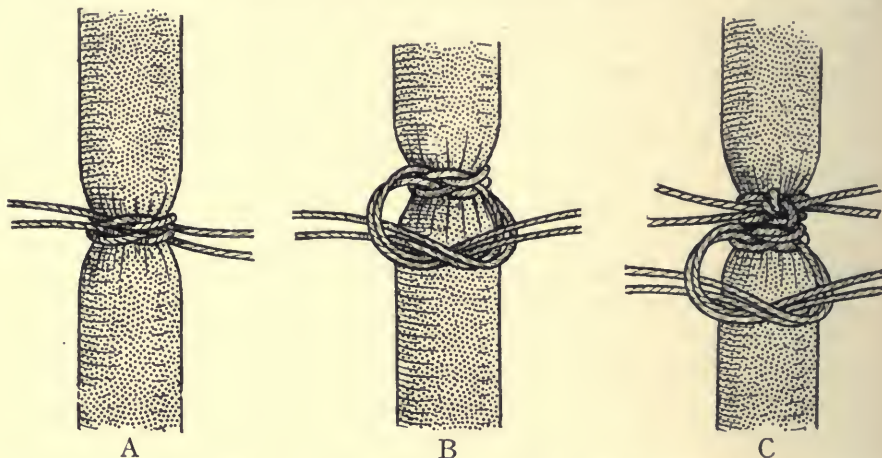


FIG. 151. THE 'STAY-KNOT' OF BALLANCE AND EDMUNDS. In A the first loops of the two ligatures have been tied. In B the two ends on each side are made to form the second loop of the knot, which is shown completed in C, in which a second pair of ligatures is being applied beyond it.

blood-stream. With a single ligature it is almost impossible to approximate the vessel walls accurately without dividing them, and, unless the approximation be perfect, the circulation will go on in spite of the ligature. By applying the ligatures in pairs the second can be tightened, whilst the first acts as a breakwater and takes the full force of the circulation, and therefore there is little chance of the second ligature stretching during the tying of the second knot. Another reason for the double ligature is that, owing to its breadth, it keeps the knot from being pressed upon by the expansile vessel wall; this Ballance and Edmunds found to be a fertile source of secondary hæmorrhage. For the large vessels it seems obviously a good plan to employ as wide a ligature as possible, and for this purpose two, three, or even more pairs of ligatures applied in this manner may be useful.

The aneurysm needle is always passed round the vessel unthreaded.

When a double ligature is to be applied this can be done by passing and withdrawing the needle once. When four or six are used it will probably be advisable to provide a needle with a particularly large eye into which all the ligatures can be threaded, as in vessels of the size of the innominate the frequent passage of an aneurysm needle around it is likely to be fraught with some danger. If no special needle of this kind be at hand the difficulty can be got over by passing a loop of silk round the vessel and threading through the loop the number of ligatures that are to surround the vessel. These are then pulled into place by withdrawing the loop.

Difficulties and dangers. There are of course many special difficulties and dangers connected with the ligature of individual arteries, which will be duly pointed out and the best means for avoiding them indicated in connexion with the particular operations in which they may arise. The only dangers common to all operations of this sort to which attention need be directed here are inclusion of other structures within the ligature, and wound of the companion vein. Of these dangers the first can obviously only be avoided by anatomical knowledge and careful operating. The surgeon should know what structures are to be avoided and where they are situated. A wound of the companion vein is an accident that is likely to occur in many situations. In some arteries, such as the popliteal and the lower part of the femoral, the vein is very closely adherent to the artery, and is easily pricked unless great care be taken. The best way of avoiding this accident is to always pass the needle from the vein, *i. e.* between the vein and the artery. This ensures the point of the needle being kept in strict contact with the wall of the artery for at least that portion of its course during which the vein is likely to be encountered. The time at which accidents usually occur is when the point of the needle is being made to emerge from the hole in the sheath after it has passed round the vessel. Should its point be allowed to get outside the sheath damage is sure to be done.

The treatment of this somewhat alarming accident is very simple. The needle should be withdrawn at once and no further attempt should be made to tie the artery in this situation. As a rule the hæmorrhage in the vein stops readily, particularly if the artery be ligatured at a fresh spot either above or below the point at which it was originally proposed to do this. Should the wound in the vein go on bleeding, either a lateral ligature may be put on or the wound may be sewn up with a fine continuous suture (see p. 263); this will probably stop the bleeding without interfering with the circulation through the vein.

After-treatment. Whenever the artery ligatured is an important one the most stringent precautions must be taken against gangrene.

The entire extremity should be thoroughly purified as if for operation, so that if gangrene occur sepsis shall not find entrance from outside. It is then enveloped in an aseptic dressing surrounded by a large mass of cotton wool several inches thick laid on quite evenly, and loosely bandaged on. The extremity is raised upon a suitable pillow or rest and is kept as warm as possible. It is a good plan to sling the limb and to alter the sling from day to day so as to prevent prolonged pressure upon any one point. The patient should not be allowed to move the limb for at least three weeks after the operation.

LIGATURE OF THE ARTERIES OF THE LOWER EXTREMITY

CHAPTER VI

LIGATURE OF THE ARTERIES OF THE FOOT AND LEG

LIGATURE OF THE DORSALIS PEDIS ARTERY

Indications. Very few; the operation is practically a dissecting-room exercise.

(i) It may be required for a *wound* of the vessel. Firm pressure should be applied over the line of the artery on the proximal side of the wound, which is then enlarged and the divided ends ligatured.

(ii) It has been resorted to in order to stop *secondary hæmorrhage* from a septic wound of the sole; in these cases the posterior tibial artery should be secured behind the inner ankle at the same time.

(iii) It has been done for *traumatic aneurysm* of the vessel. The best plan in these rare cases is to secure the vessel on either side of the aneurysm and then to excise the latter completely.

Surgical anatomy. The dorsalis pedis is the continuation of the anterior tibial artery, and extends from the mid-point between the two malleoli on the front of the ankle to the upper end of the first interosseous space, through which it passes into the sole between the two heads of the first dorsal interosseous muscle. In its course the artery lies successively upon the anterior ligament of the ankle-joint, the head of the astragalus (talus), the superior astragalo-scapoid (talo-navicular) ligament, the ligaments between the middle (second) and internal (first) cuneiforms, and part of the latter bone. It is covered by the skin and fascia, containing branches of the musculo-cutaneous (superficial peroneal) and anterior tibial (deep peroneal) nerves and the internal saphenous vein, and the upper part of it lies beneath the lower part of the anterior annular (crucial) ligament of the ankle, while below, near its termination, it is crossed obliquely by the innermost tendon of the extensor digitorum brevis. It lies between the tendon of the extensor hallucis longus internally and the innermost tendon of the extensor digitorum longus externally; between the latter structure and the artery is the anterior tibial (deep peroneal) nerve. The vessel is accompanied by *venæ comites*, one on either side (see Fig. 152).

The artery gives off its lateral tarsal branch just after it emerges from beneath the anterior annular (crucial) ligament, and its metatarsal (arcuate) branch just before it dips down into the first interosseous space. It may be tied anywhere between these two points; the ligature is usually applied at the point where the artery is crossed by the innermost tendon of the extensor brevis, viz. just before it passes into the first interosseous space.

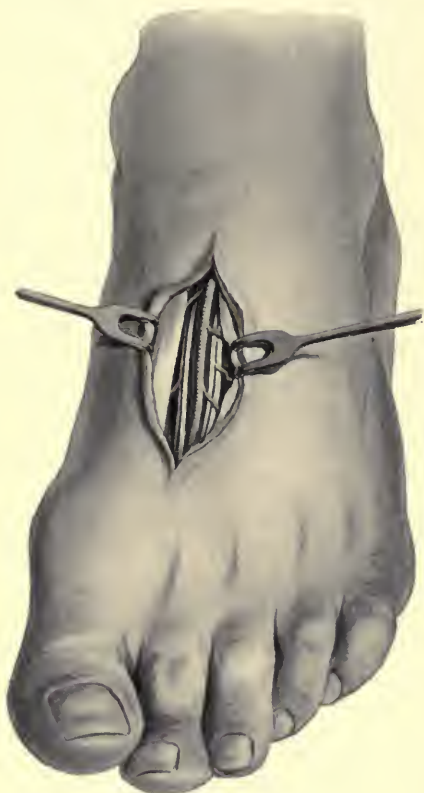

FIG. 152. THE DORSALIS PEDIS ARTERY. On the left-hand side is seen the tendon of the extensor hallucis longus. On the opposite side the innermost tendon of the extensor digitorum communis is pulled back by the retractor. The artery is seen with a vena comes on each side; external to the outer one lies the anterior tibial (deep peroneal) nerve.

then reveal the artery with its venæ comites, and the very narrow tendon of the extensor digitorum brevis crossing it (see Fig. 152). This tendon may be drawn either downwards or to the inner side, and the ligature is passed from the outer side. It is as well to include the venæ comites in the ligature, as they are often difficult to separate from

Operation. An assistant holds the foot resting firmly on the heel and somewhat plantar-flexed, so as to make the extensor tendons prominent. The surgeon stands to the outer side of the limb and makes an incision an inch long parallel with and just external to the tendon of the extensor hallucis longus when that can be identified; in cases of doubt the anatomical guide-line (see Fig. 153) given above should be followed. The incision is generally made over the lower end of the artery, terminating below over the upper end of the first interosseous space, but it may be anywhere along the line of the vessel.

This incision is deepened carefully in order to avoid wounding the tendon sheaths. The interval between the tendons of the first and second toes is identified and opened up by dividing the dorsal fascia of the foot, and a little dissection will

it. The anterior tibial (deep peroneal) nerve lies well to the outer side of the artery, almost under the innermost tendon of the extensor digitorum longus, and is often not seen.

It is better to seize the artery in two pairs of Spencer Wells's forceps, divide it between them, and then to tie each end separately, than to ligate the vessel in continuity.

Difficulties. The artery is very variable both in its size and its course. It may be wanting altogether; it not infrequently runs well to the outer side of its normal line, and between its points of origin and termination it may form a large loop with its convexity towards the outer border of the foot. A watch should be kept for the inner branch of the musculo-cutaneous (superficial peroneal) nerve, which should be avoided if possible. There is no difficulty in exposing the vessel in the living subject, as its pulsations are always to be felt plainly.

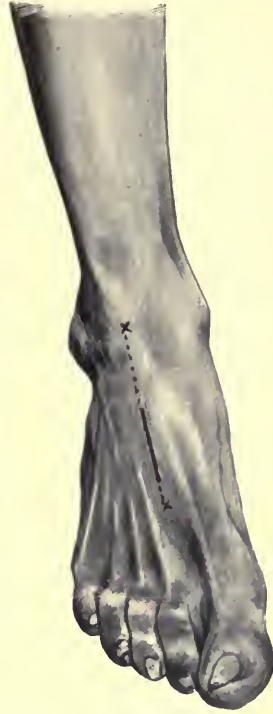

FIG. 153. THE INCISION FOR EXPOSURE OF THE DORSALIS PEDIS.

The upper \times is on the mid-point between the two malleoli, the lower on the upper end of the first interosseous space. The dotted line marks the anatomical line of the artery, the thick continuous one the incision for its exposure.

LIGATURE OF THE ANTERIOR TIBIAL ARTERY

Indications. This vessel is very rarely tied, and when ligature in continuity is practised, it will be for—

(i) *Aneurysm*, either spontaneous or traumatic; both affections are rare.

(ii) More frequently the vessel will require ligature for a punctured or a gunshot *wound* or a laceration resulting from a fracture of both bones of the leg. In these traumatic cases the best operation will not be ligature in continuity, but exposure and ligature of the divided ends. An elastic tourniquet round the thigh is of great service under these conditions in controlling the bleeding until the vessel has been exposed and secured.

Surgical anatomy. The vessel extends from the lower border

of the popliteus muscle to the centre of the front of the ankle, and its

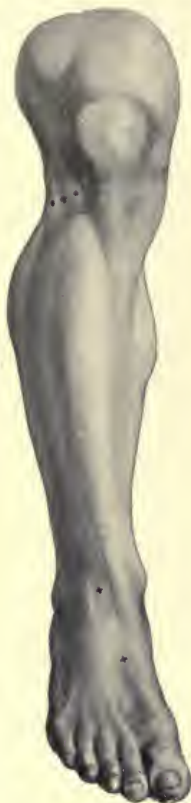

FIG. 154. LANDMARKS FOR THE ANTERIOR TIBIAL ARTERY. The two upper dots are placed upon the head of the fibula and the outer tuberosity of the tibia respectively. The + between them marks the upper end of the guide line to the anterior tibial, which runs down to the + on the centre of the ankle below. The lowest + is over the upper end of the first interosseous space.

course is denoted by a line drawn from the mid-point between the head of the fibula and the outer tuberosity of the tibia to the mid-point between the two malleoli on the front of the ankle (see Fig. 154). It is deeply placed in the upper two-thirds of its course, passing forwards from the calf over the upper edge of the interosseous membrane between the two heads of the tibialis posticus (posterior). It lies upon the anterior surface of the interosseous membrane, to which it is connected by delicate fibrous bands, as far down as the junction of the middle with the lower thirds of the leg, when it becomes more superficial and lies on the front of the tibia and the anterior ligament of the ankle-joint. In the upper third of the leg the vessel has the extensor digitorum longus on its outer and the tibialis anticus (anterior) on its inner side; in the middle third it lies between the extensor hallucis longus externally and the tibialis anticus (anterior) internally, while in the lower third the tendon of the extensor hallucis longus crosses it obliquely from without inwards, so that the termination of the vessel lies between that tendon internally and the innermost tendon of the extensor digitorum longus on the outer side. It is here covered by the anterior annular (crucial) ligament of the ankle-joint; in the upper two-thirds of its course it is overlapped by the muscles between which it lies.

The anterior tibial (deep peroneal) nerve lies at some little distance to the outer side of the artery in its upper fourth. It then approaches the vessel and lies over it, but rather to its outer side, throughout the middle two fourths, while in the lower part of its course it is on the outer side again, intervening between the vessel and the innermost tendon

of the extensor digitorum longus. Two venæ comites accompany the vessel, and anastomose freely across it at short intervals. The

musculo-cutaneous (superficial peroneal) nerve lies over the vessel superficial to the deep fascia.

The anterior tibial artery may be tied in the upper, middle, or lower thirds.

LIGATURE IN THE UPPER THIRD

The patient lies on his back with the knee flexed and the limb adducted and rotated inwards; the foot is plantar-flexed while the incision is being made, but dorsi-flexed afterwards. The surgeon stands on the outer side of the limb and makes his incision from above downwards on the right, and from below upwards on the left side. The line of the artery (*vide supra*) is carefully ascertained, and an incision four inches long is made over its upper third, its upper limit being an inch below the mid-point between the head of the fibula and the outer tuberosity of the tibia. This incision only goes down to the deep fascia in the first instance, and then, without displacing the soft parts at all, this structure is slit up throughout the length of the wound strictly in the same line as the skin incision. The next point is to identify the intermuscular septum between the tibialis anticus (anterior) and the extensor digitorum longus. There are two intermuscular septa on the front of the leg, the other being that between the extensor digitorum longus on the inner side and the peronei on the outer, and it is easy to mistake one for the other, as the extensor digitorum longus is very narrow just here. The most certain way to avoid error is to seize each edge of the incision in the deep fascia with forceps in turn, and to separate the subjacent muscle from it with the handle of the knife for an inch on each side; then the fascia is fully retracted and the proper septum can be identified. It is the first one met with external to the border of the tibia—which can always be felt—and it leads almost vertically down to the interosseous membrane and is further marked by numerous emergent muscular arteries, whereas the wrong septum leads downwards and outwards to the fibula and has no emergent vessels. The yellow or ‘white line’ so often mentioned in textbooks is generally wanting.

As soon as the septum has been identified, the foot is fully dorsi-flexed in order to relax the muscles as much as possible, and the handle of the knife is sunk into the septum, and the tibialis anticus (anterior) is separated from the extensor digitorum longus throughout the length of the wound. If the incision in the deep fascia does not coincide exactly with this septum in direction, it may be necessary to make a transverse incision in the fascia at one end of the wound, as the artery lies deep down on the interosseous membrane and as much room as possible is necessary. The muscles are kept out of the way with large flat retractors—ordinary

hook-retractors are useless—and the vessel, with its venæ comites, is seen lying on the membrane (see Fig. 155). The nerve lies well to the outer side and may not come into view. The best plan is to pass the needle round both artery and veins, as the latter anastomose so freely round the former that it is almost impossible to separate them, and a wound of

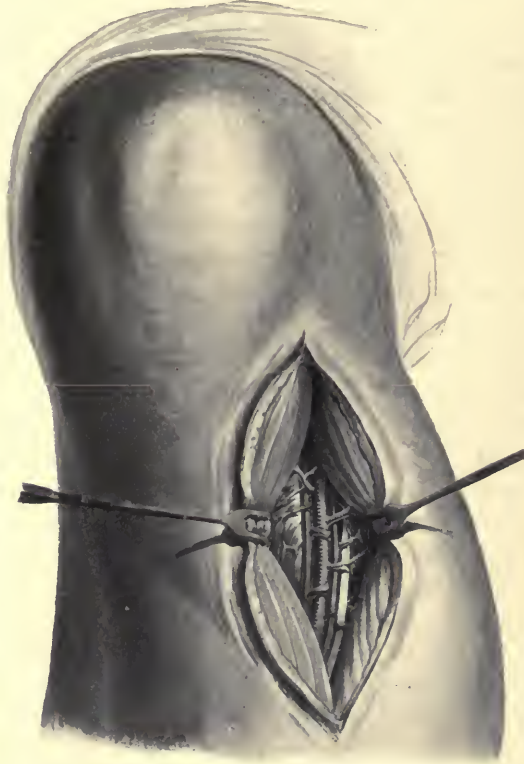


FIG. 155. THE ANTERIOR TIBIAL ARTERY IN THE UPPER THIRD. The tibialis anticus (anterior) is beneath the retractor on the left hand, the extensor digitorum longus beneath that on the right-hand side. The artery, with its venæ comites anastomosing across it, is seen on the interosseous membrane. The anterior tibial (deep peroneal) nerve is seen approaching it obliquely from the outer side.

the veins gives rise to most vexatious oozing. A needle with a very small curve is required; it is best to pass it from the outer side.

Difficulties. The chief difficulty is the identification of the proper septum. If the rules given above be followed exactly, there should be no serious difficulty in finding the vessel. The use of a blunt dissector is to be deprecated, and in no case should the muscular fibres be torn, as that is the surest way of losing all guides to the vessel. Another

difficulty is in getting a ligature round the vessel. In actual practice this will hardly ever be necessary, as the operation will be done for a wound, when it is only necessary to tie or twist the divided ends; in these cases a tourniquet should be applied to the thigh before the incision is made. A needle with a curve which is a segment of a very small circle will get over the difficulty best.

LIGATURE IN THE MIDDLE THIRD

Here the vessel lies between the tibialis anticus (anterior) on the inner and the extensor hallucis longus on the outer side. The

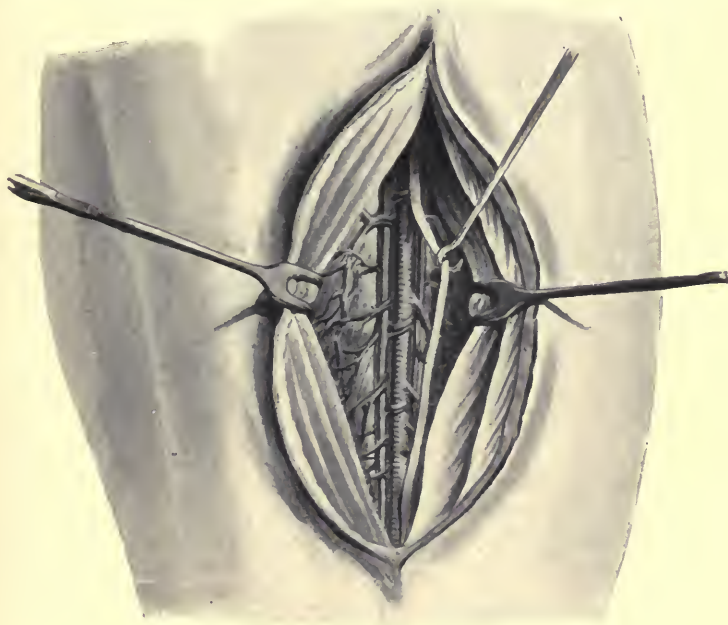


FIG. 156. THE ANTERIOR TIBIAL ARTERY IN THE MIDDLE OF THE LEG. The tibialis anticus (anterior) is retracted on the left-hand side. Beneath the hook of the retractor on the right-hand side is the extensor hallucis longus, while just above it lies the extensor digitorum longus. The artery and its anastomosing venæ comites are seen lying below the anterior tibial (deep peroneal) nerve, which is hooked up from its surface.

anterior tibial (deep peroneal) nerve usually lies over the front of the artery a little to its outer side and is closely adherent to it (see Fig. 156). The extensor digitorum longus muscle, when well developed, overlaps the extensor hallucis longus, so that the latter is not properly seen until the tibialis anticus (anterior) and the extensor digitorum longus have been separated from one another (see Fig. 157).

Operation. The positions of the limb and the surgeon are the same as in the preceding operation. The incision should be three inches long, over the line of the artery, and with its centre opposite the centre of the limb. The skin and deep fascia are incised along the line of the artery throughout the length of the wound. There is nearly always a well-marked intermuscular septum at this level, indicated by a fatty interspace containing emergent vessels. This space is opened up with

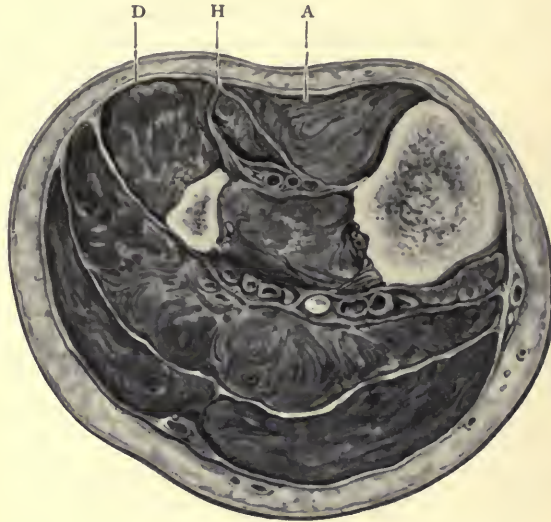


FIG. 157. TRANSVERSE SECTION THROUGH THE MIDDLE OF THE LEG TO SHOW THE RELATIONS OF THE ANTERIOR MUSCLES. The anterior tibial vessels are seen lying upon the front of the interosseous membrane. The section shows the arrangement of the three muscles in front of the tibia and fibula. The large tibialis anticus, A, and the equally large extensor digitorum longus, D, practically meet so as to conceal the extensor hallucis longus, H, which lies in the triangular interval between them. It will be seen that in this case there is only one septum on the front of the limb, but that it soon bifurcates into two, one lying between the tibialis anticus and the extensor hallucis longus, and the other between the latter muscles and the extensor digitorum longus.

the handle of the knife, and, as the separation proceeds, great care must be taken to keep close to the outer edge of the tibialis anticus (anterior) muscle. When the interosseous membrane is reached, the first structure seen is the anterior tibial (deep peroneal) nerve, which must be carefully separated from the artery. The needle is passed from the nerve, *i. e.* from the inner side.

Difficulties. The chief source of error is missing the septum between the tibialis anticus (anterior) and the extensor hallucis longus,

and getting into that between the latter muscle and the extensor digitorum longus. This mistake is avoided by identifying the tibialis anticus (anterior), which is the first muscle external to the tibia, and then keeping close round its outer margin when opening up the intermuscular septum (see Fig. 157).

An aneurysm needle with a small curve is required to pass the ligature

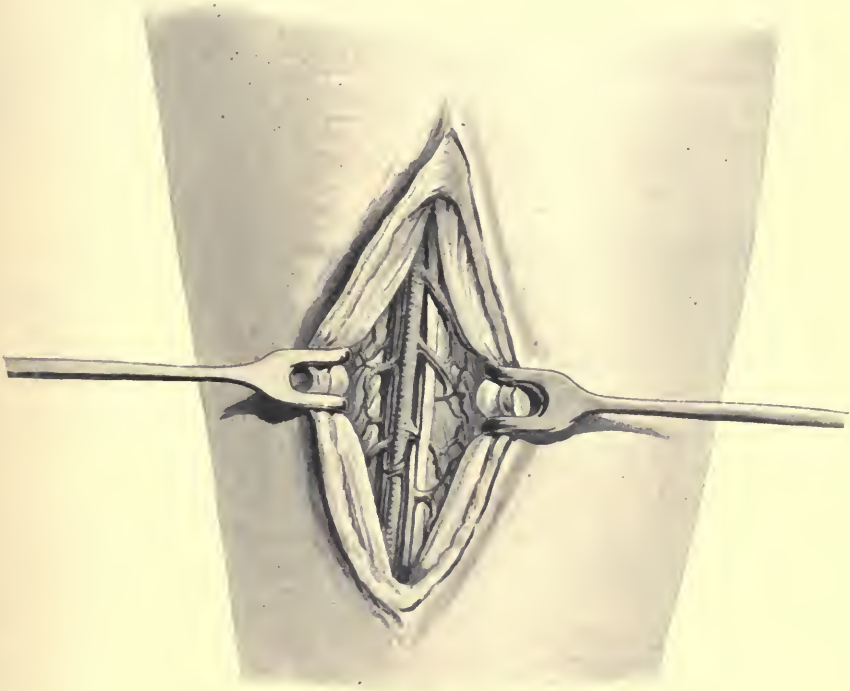


FIG. 158. THE ANTERIOR TIBIAL ARTERY IN THE LOWER THIRD OF THE LEG. The tibialis anticus (anterior) is hooked to the left-hand side, the semitendinosus extensor hallucis to the right-hand side. The vessel and its venæ comites are seen with the anterior tibial (deep peroneal) nerve on the outer side.

satisfactorily. The vessel is situated so deeply that passing the ligature is a very difficult matter.

LIGATURE IN THE LOWER THIRD

The tendon of the extensor hallucis longus crosses this part of the vessel and lies to its inner side at its termination, but the artery is generally tied just before the tendon crosses it. The anterior tibial (deep peroneal) nerve and the innermost tendon of the extensor digitorum longus lie to the outer side.

Operation. The position of the operator is as before (see p. 297), but the limb now lies extended, with the toes pointing upwards. An incision an inch and a half long is made over the line of the artery, extending down to just above the line of the ankle-joint. As the incision is deepened, the upper part of the anterior annular (crucial) ligament is divided, and the interval between the tendons of the tibialis anticus (anterior) and extensor hallucis longus is opened up; care must be taken not to open the synovial sheaths of these tendons. The artery is superficial and easy to find (see Fig. 158); if there be any difficulty, it should be looked for beneath the tendon of the extensor hallucis longus. The needle is passed from the outer side, and the divided portion of the annular (crucial) ligament is sutured with fine catgut before closing the wound.

LIGATURE OF THE POSTERIOR TIBIAL ARTERY

Indications. This artery very rarely requires ligature. The indications for it are :—

(i) Gunshot, punctured, or incised *wounds*. These will call for immediate ligature of the divided ends of the vessel in any part of its course. Laceration of the vessel may also occur as a complication of fracture of bones of the leg.

(ii) Traumatic *aneurysm* of the posterior tibial artery has been met with, but is very rare. It may be treated by ligature in continuity, but it would be better to apply Esmarch's bandage to the thigh, expose the aneurysm, secure the vessel on each side of it, and dissect out the sac entire.

Surgical anatomy. This large vessel extends from the lower border of the popliteus muscle to the mid-point between the tip of the internal malleolus and the most prominent part of the os calcis beneath the origin of the abductor hallucis from the internal annular (laciniate) ligament. The vessel lies in the interval between the superficial and deep calf muscles, to the latter of which it is bound down by a special fascia. It lies at first upon the tibialis posticus (posterior), then upon the flexor digitorum longus, and finally upon the posterior surface of the tibia and the posterior ligament of the ankle-joint.

The upper half of the artery is covered by the gastrocnemius and soleus, with the plantaris between them. The lower half is superficial and is covered only by the skin and deep fascia, except at its termination, where it is covered by the internal annular (laciniate) ligament and the origin of the abductor hallucis. The posterior tibial nerve is on its inner side in the upper third, then it crosses obliquely behind the artery,

and finally lies on its outer side. Two venæ comites accompany the vessel throughout its course and, like those of the anterior tibial, anastomose freely around the artery.

Ligature of the posterior tibial is chiefly a dissecting-room operation, and is done in three situations: (i) In the middle of the calf, (ii) in the lower third of the leg, and (iii) behind the inner ankle.

LIGATURE IN THE MIDDLE OF THE LEG

The limb is abducted and rotated outwards, the knee and hip are flexed, and the heel is made to rest on the instep of the opposite foot. The surgeon stands facing the inner aspect of the limb and makes an in-

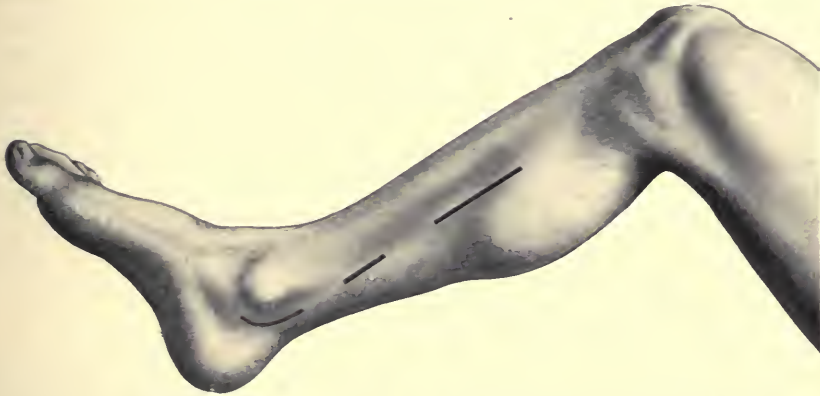

FIG. 159. INCISIONS FOR EXPOSURE OF THE POSTERIOR TIBIAL ARTERY. The incisions are for exposure of the vessel in the middle and lower thirds of the leg and behind the inner ankle, in order from right to left.

cision four inches long parallel to and a finger's breadth behind the inner border of the tibia, the centre of the incision corresponding to the mid-point of the leg (see Fig. 159). The incision is deepened carefully in order to avoid the internal (great) saphenous vein and nerve which lie parallel to and often immediately under it. If seen, the vein must be drawn aside; if it cross the incision too obliquely it must be divided. The deep fascia is next opened up to the full extent of the wound, the inner border of the gastrocnemius is drawn downwards, and the characteristic fibrous aponeurosis of the soleus is exposed. The portion of this muscle arising from the tibia must now be divided throughout its whole thickness before the deep calf muscles can be exposed. The incision in the muscle is made about three-quarters of an inch from the inner border of the tibia, with the blade of the knife held horizontal and cutting directly towards the posterior surface of that bone. As the muscle is cut through, its fibres are pushed aside, and the white, glistening intermuscular

aponeurosis comes into view. This is slit up for the whole length of the wound, and, after dividing a few more muscular fibres, the space between the superficial and deep muscles is opened up and the flexor digitorum longus is seen. The foot is now fully plantar-flexed and the knee a little more flexed in order to relax the calf muscles as much as possible, when the vessels will come into view lying upon the deep muscles and bound down by a special fascia which must be divided before they can be reached. The nerve lies to the outer side of the artery and is often not seen. The venæ comites had better be taken up with the artery. The needle is passed from the outer side.

Difficulties. There are several, unless the operation be done with great care. The first trouble may arise from a large gastrocnemius, especially if the calf muscles are not allowed to hang free, as, for instance, when the operation is attempted with the limb lying flat on the table, or with an assistant supporting the calf. The posterior surface of the gastrocnemius may then be exposed and mistaken for the soleus. The latter muscle can be recognized by the characteristic arrangement of the fibres of its posterior aponeurosis, which are arranged very obliquely to the long axis of the limb, while those of the gastrocnemius are parallel to it. Sometimes the gastrocnemius is cut through in mistake for the soleus. In this case the plantaris will be met with between the two muscles and will put the operator on the right track.

Another difficulty will be met with if the section of the muscular belly of the soleus be practised wrongly. If the knife be held with its blade nearly vertical instead of horizontal as it should be, the incision will travel downwards between the two aponeuroses of the soleus instead of across that muscle, and the deep muscles will not be reached.

Then again, the interval between the superficial and deep calf muscles may not be recognized, and the deep muscles may be detached from the tibia and retracted, and the vessels with them, until finally the operator arrives at the interosseous membrane. This mistake is easily obviated by taking care to recognize the intermuscular aponeurosis of the soleus when it is reached. The cellular interval in the calf is reached almost immediately after this has been divided. The artery is to be looked for lying behind the posterior surface of the tibia on the flexor digitorum longus, and not in the middle of the wound, where one is tempted to look for it.

LIGATURE IN THE LOWER THIRD OF THE LEG

The positions of the limb and of the surgeon are the same as in the preceding operation. An incision two inches long is made parallel to and midway between the adjacent margins of the tibia and the tendo

Achillis (see Fig. 159) ; if the latter cannot be felt the incision should be half an inch behind the inner border of the tibia. The internal (great) saphenous vein must be avoided as before, and the deep fascia opened up throughout the whole length of the wound ; the upper edge of the internal annular (laciniate) ligament may have to be divided below. This will expose the fascia binding down the deep flexor tendons, which must be divided and the tendons identified. The nearest to the edge of the tibia is the tibialis posticus (posterior), outside which comes the flexor digitorum longus. The cellular interval external to this tendon and between it and the flexor hallucis longus is now exposed without opening the tendon sheaths, and the artery is seen with its *venæ comites* and the large posterior tibial nerve lying external to it. The needle is passed from the outer side.

Difficulties. The only difficulty likely to arise is from the operator forgetting that the vessel lies on the deep muscles on the posterior surface of the tibia and bound down to them by a special fascia. It should, therefore, be looked for upon the anterior aspect of the wound, and not at the bottom of it, otherwise there is a risk of losing one's way in the fat in front of the tendo Achillis.

LIGATURE BEHIND THE INNER ANKLE

The knee is flexed and the limb laid on its outer side. The surgeon stands on the opposite side of the table, facing the inner aspect of the limb, and makes a crescentic incision with its concavity forwards a good finger's breadth behind the inner malleolus, nearly two inches in length, the greater part of the incision being parallel to its posterior border (see Fig. 159), as the artery should be secured above the point of the malleolus, where it is comparatively superficial. The incision must be deepened to the internal annular (laciniate) ligament, which is defined and incised carefully along the line of the original incision. This should lie almost over the vessels, which are situated in a definite cellular interval that can be felt just external or posterior to the tendon of the flexor digitorum longus and between it and that of the flexor hallucis longus. The first tendon felt beneath the malleolus is that of the tibialis posticus (posterior), next to that comes the flexor digitorum longus, then the interval for the vessels and nerve, and finally the tendon of the flexor hallucis longus ; the tendon sheaths should not be opened. The nerve lies on the outer or fibular aspect of the vessels, and is of large size ; the *venæ comites* may have to be taken up with the artery. The knife should be directed towards the malleolus as the incision is deepened, or else a deep dissection may be made backwards towards the heel.

CHAPTER VII

LIGATURE OF THE ARTERIES OF THE KNEE AND THIGH

LIGATURE OF THE POPLITEAL ARTERY

Indications. (i) *Punctured or gunshot wounds* involving the popliteal artery. These will require enlargement of the wound in the line of the artery, after a tourniquet has been applied round the thigh; when the bleeding point is found, the vessel must be secured between two ligatures. It will rarely be possible to suture the artery, even though there be only a small aperture in its walls owing to the deep situation of the vessel and the importance of the surrounding structures.

(ii) *Injury to the popliteal artery from dislocation, fracture of the femur, or direct crush.* In these cases the artery should be exposed near its origin by a median vertical incision over the upper part of the popliteal space, and traced down to the seat of injury, where a double ligature should be applied. A tourniquet will be required here also.

(iii) *Injury to the popliteal artery during osteotomy.* In these rare cases the artery should be exposed—after applying a tourniquet to the thigh—from the inner aspect of the thigh by the incision given below (see p. 307).

(iv) *Aneurysm.* Ligature of the popliteal artery for aneurysm may be practised for three different conditions:

(a) When the aneurysm springs from the lower part of the popliteal artery.

(b) When pulsation has recurred after ligature of the femoral in Hunter's canal for a popliteal aneurysm.

(c) When the surgeon desires to do the 'old' operation, as in cases of traumatic, ruptured, or inflamed aneurysm. It is, however, possible that further experience of Matas's operation for aneurysm may lead to a modification of the present treatment of this affection (see p. 266).

(v) *Wounds of the leg* in which it is uncertain whether the bleeding comes from the anterior or posterior tibial. In these cases the popliteal should be exposed at its termination and traced down until the source of bleeding has been identified and the bleeding ends secured.

Surgical anatomy. The popliteal artery extends from the lower border of the opening in the adductor magnus to the lower border

of the popliteus muscle, where it divides into the two tibials. This point on the back of the limb corresponds to the lower part of the tubercle of the tibia in front. At first the artery runs somewhat outwards until it reaches the interval between the two condyles, when it descends vertically in the middle of the popliteal space.

The vessel is very deeply placed, being in contact *anteriorly* with the triangular surface of the femur, the posterior ligament of the knee-joint, and the fascia covering the popliteus muscle. *Posteriorly*, it is overlapped above by the semimembranosus, while below it is beneath the adjacent borders of the two heads of the gastrocnemius, especially the inner one. The popliteal vein and the internal popliteal (tibial) nerve both lie behind the artery about its middle, the vein being closely applied to the back of the vessel and separating it from the nerve, which crosses the artery obliquely from without inwards and from above downwards. Below, the vessel is crossed by the nerve to the popliteus, and also by the plantaris muscle when it exists. On its *outer side* lie the popliteal vein and the internal popliteal (tibial) nerve above, the outer condyle of the femur about its middle, and the outer head of the gastrocnemius and the plantaris below. On the *inner side* are the semimembranosus above, the inner condyle about the middle, and the nerve to the popliteus, the internal popliteal (tibial) nerve and the inner head of the gastrocnemius below.

The artery may be tied at its commencement or at its termination. It is hardly ever tied in the middle of its course, although this might have to be done in cases of rupture; the vessel here is very deep and intimately connected with the vein, so that the difficulty of isolating and tying it is great.

The vessel may be ligatured (*a*) from the inner aspect of the thigh, (*b*) in the upper part of the popliteal space from behind, (*c*) in the lower part of the popliteal space from behind.

LIGATURE FROM THE INNER ASPECT OF THE THIGH

The knee is flexed nearly to a right angle, and the limb is abducted and rotated outwards, being supported on the heel. No pillow or support should be placed beneath the knee, otherwise the hamstrings will be displaced. The surgeon stands facing the inner aspect of the limb; if he stands on the outer side of the limb it is impossible to get a good view. The adductor magnus tendon is first identified by abducting the limb forcibly, and the adductor tubercle into which it is inserted is also made out. An incision four inches long and parallel to, but a little below, the adductor tendon is then made from the junction of the lower with the

middle third of the thigh downwards to just below the adductor tubercle (see Fig. 160). The internal (great) saphenous vein, which lies almost in the line of the incision, must be avoided. After division of the deep fascia the sartorius is seen, its anterior border is defined, and the muscle drawn downwards. The operator then feels for the adductor magnus tendon and cuts down on it. The free edge of this structure stands out as a rounded white cord, along the lower edge of which the knife is passed

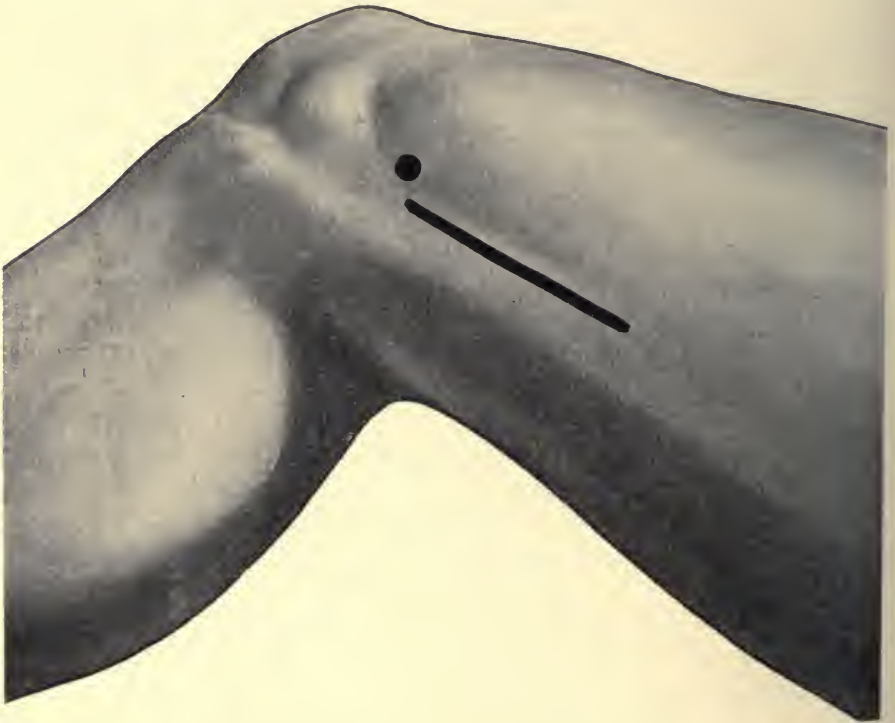


FIG. 160. INCISION FOR LIGATURE OF THE POPLITEAL ARTERY FROM THE INNER SIDE OF THE THIGH. The dot is placed upon the adductor tubercle.

so as to divide the fascia and allow the semimembranosus to be pulled downwards and the upper part of the popliteal space to be opened up. When this has been done, the finger, with the pulp directed upwards towards the triangular posterior surface of the femur, is passed into the areolar tissue of the popliteal space and the artery is felt beating between the bone and the finger. The knee is now flexed still more fully, so as to relax the parts as much as possible, and the surgeon opens the sheath of the artery from the inner side, clears the vessel and passes the

aneurysm needle from the upper and outer aspect of the artery (see Fig. 161). The vein and nerve lie to the outer side of the vessel and are not seen.

Difficulties and dangers. In the living subject the only difficulty met with is in opening the sheath and cleaning the artery in fat subjects. The artery lies very deep and can only be seen with difficulty. Good flexion of the knee, a forehead-light, a free incision and

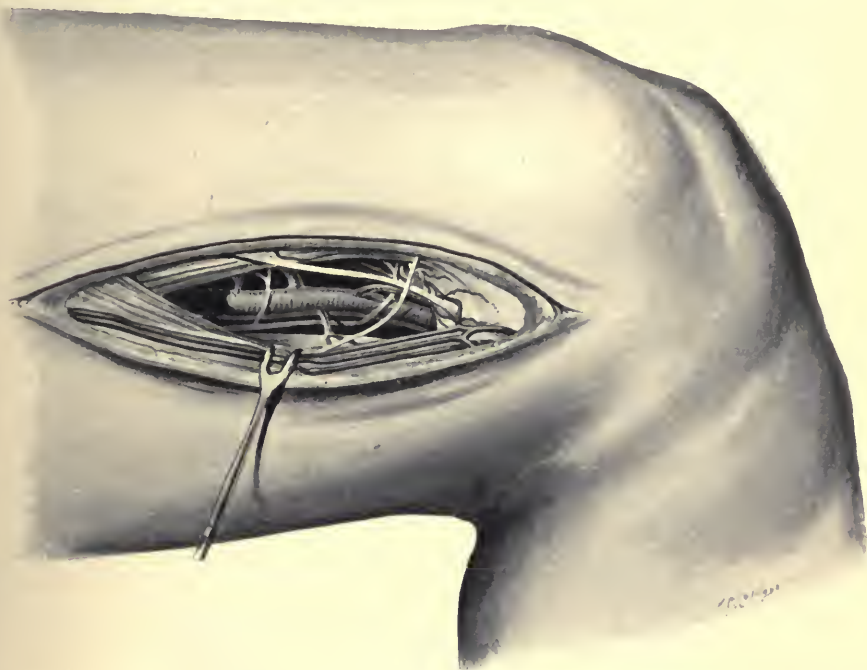


FIG. 161. THE POPLITEAL ARTERY FROM THE INNER SIDE OF THE THIGH. The hook is pulling down the sartorius and the internal (great) saphenous nerve is seen above. The lower border of the adductor tendon is visible above the artery.

long-handled instruments, including aneurysm needles of various curves, will overcome this difficulty. It is also essential that the surgeon should face his work; if he stands on the outer side of the limb, as is often recommended, his difficulties are greatly increased.

In the dead subject an additional difficulty may arise from inability to define the adductor tendon. A very common mistake, after the popliteal space has been opened, is to thrust the finger between the artery and the femur and push the former backwards into the popliteal space, where there may be great difficulty in identifying it. It should always

be possible to feel the artery easily against the femur in the dead subject, as it is a large and usually a rigid one. It should be cleared carefully without dragging it from its bed, and great caution is necessary in passing the aneurysm needle for fear of puncturing the vein. Fig. 162 shows the intimate connexion between the two structures in this situation.

LIGATURE FROM THE BACK OF THE LEG

In the upper part of the popliteal space. As it is inconvenient to the anæsthetist to roll the patient fully over on to his face, it will be

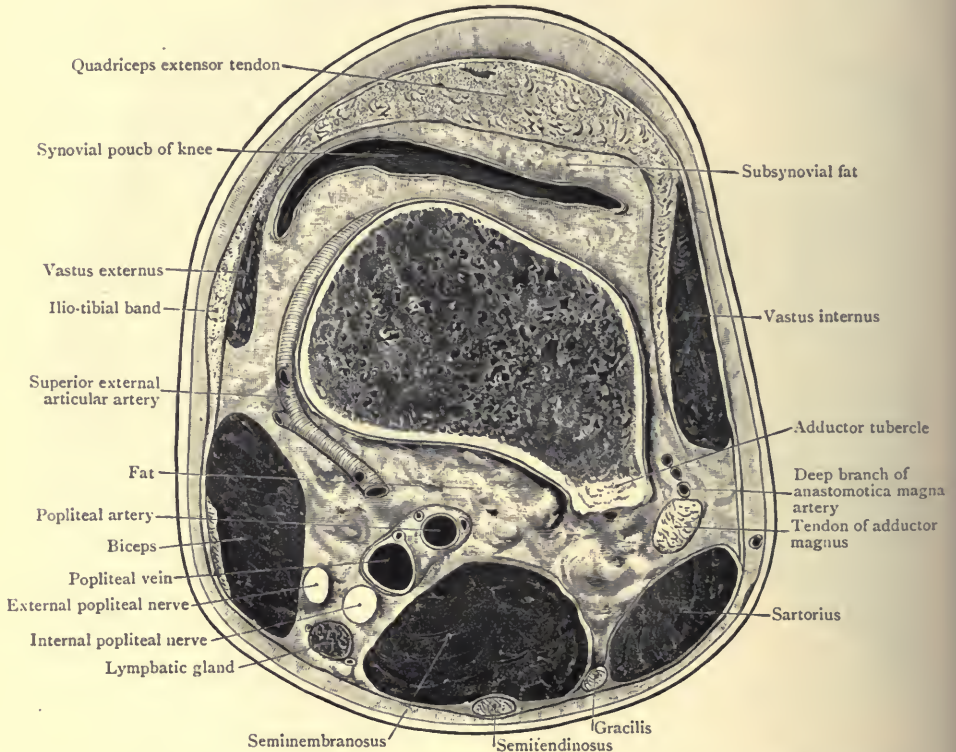


FIG. 162. SECTION THROUGH THE THIGH IMMEDIATELY ABOVE THE PATELLA (Cunningham's *Anatomy*).

sufficient to turn him well over on to the affected side, flexing the sound leg upon the trunk so as to prevent him from assuming the completely prone position.

The surgeon stands on the outer side of the limb and feels for the outer border of the semimembranosus. An incision four inches long is made along this structure down to the transverse popliteal crease seen

on the skin at the back of the knee. When the superficial structures have been divided, the outer edge of the semimembranosus comes into view and is cleared and pulled inwards, when the pulsations of the artery can be felt in the upper part of the popliteal space. In doing this the lesser sciatic (posterior femoral cutaneous) nerve will probably be seen and should be avoided. Large retractors are inserted into the wound, and the internal popliteal (tibial) nerve at once comes into view, hiding the artery, which lies to its inner side and on a deeper plane, with the vein interposed between it and the nerve; the latter structure should be drawn to the outer side with a retractor, the vein with it. The sheath of the artery is then opened from its inner side, and the vessel cleared. The needle should be passed between the vein and the artery, namely, from the outer side first. It is fairly easy to get at the artery in this position, certainly easier than in the preceding operation, but great care should be taken to avoid damaging the vein, which almost entirely conceals the artery and is closely connected with it. There is also occasionally troublesome bleeding from the small articular vessels in this situation.

In the lower part of the popliteal space.

The limb is in the same position as before, and the surgeon stands on the outer side. A vertical incision about three inches and a half long is made in the middle line of the popliteal space commencing about the level of the knee-joint, viz. one inch below the transverse crease usually seen at the back of the limb (see Fig. 163). If there be any difficulty in identifying this crease, the level of the knee-joint may be made out by inserting a finger deeply into the popliteal space and then flexing and extending the knee.

As the incision is deepened, the external saphenous (sural) nerve or the tibial communicating (medial sural cutaneous) nerve will be met with and must be avoided. The deep fascia is then opened up throughout the whole of the wound, and the heads of the gastrocnemius muscle are identified, and their line of union made out by the direction of the muscular fibres. The two heads of the muscle are then separated widely and the division between them is prolonged downwards, if necessary, through the muscular fibres for about an inch and a half to two inches. In doing this the operator will probably come across the sural vessels and

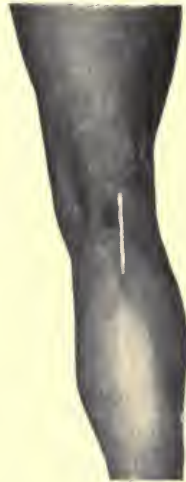

FIG. 163. INCISION FOR EXPOSURE OF THE POPLITEAL ARTERY IN THE LOWER PART OF THE POPLITEAL SPACE. The white line indicates the incision.

the plantaris muscle, which should be drawn aside. The next structure that comes into view is the internal popliteal (tibial) nerve which lies here on the inner side of the vein, and superficial to it. These structures are pulled over to the inner side with a blunt hook, without attempting to separate them (see Fig. 164). The artery can then be felt pulsating beneath them, and its sheath is opened well to the outer side, the vessel cleared, and the needle passed from the outer side, that is to say, between the vein and the artery.

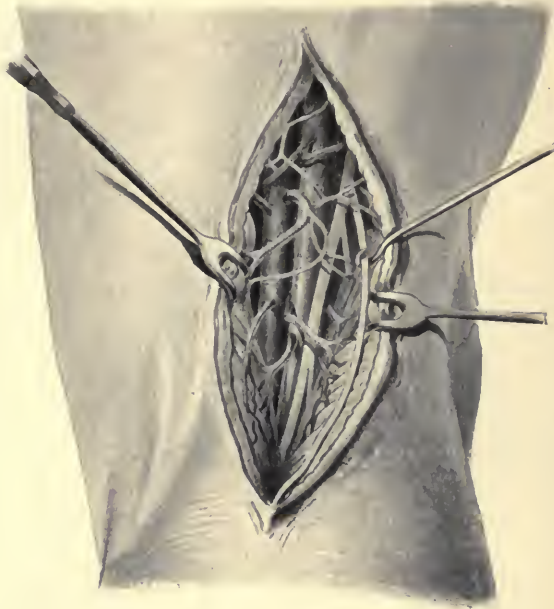


FIG. 164. THE POPLITEAL ARTERY IN THE LOWER PART OF THE LEFT POPLITEAL SPACE. The heads of the gastrocnemius have been separated for some distance and hooked aside. The relations of the nerve, vein, and artery are well seen. The nerve under the small hook is the tibial communicating (medial sural cutaneous).

Difficulties and dangers. The chief risk of the operation is the liability to wound the vein, which is best avoided by retracting it together with the internal popliteal (tibial) nerve to the inner side as directed above. The vessel should be secured well below the level of the junction of the two heads of the gastrocnemius muscle, and the depth at which the vessel lies may cause some difficulty in passing the needle; should this be the case, the knee must be fully flexed to relax the muscles.

The wound is sutured without a drainage tube, and the limb is put up on a straight back-splint with a small pad between it and the popliteal space. This will obliterate the cavity in the popliteal space sufficiently.

LIGATURE OF THE FEMORAL ARTERY

Indications. (i) *Wounds of the femoral artery.* In these cases the vessel must be exposed at the seat of injury and appropriate treatment employed, after the circulation has been commanded above the wound, either by a tourniquet or by digital pressure. Since arteriorrhaphy has come within the sphere of practical surgery there is little doubt that some of these cases will fall within its scope, especially when the wound is

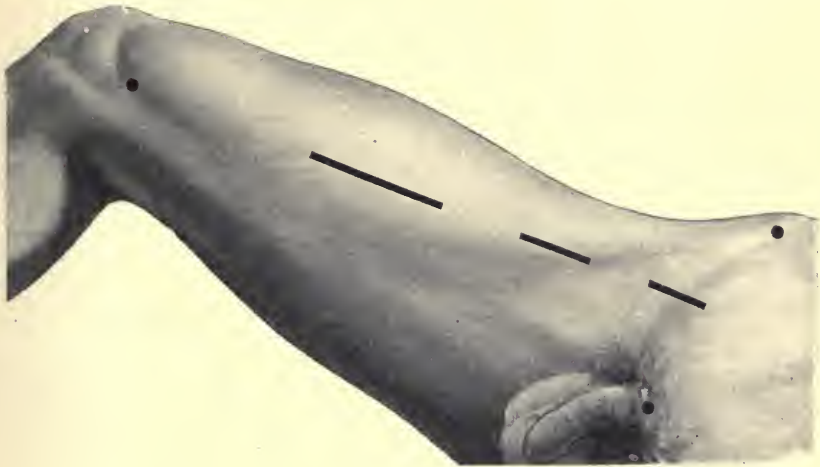

FIG. 165. INCISIONS FOR LIGATURE OF THE FEMORAL ARTERY. The two dots on the right-hand side are upon the anterior superior iliac spine and the symphysis pubis respectively ; that on the left is over the adductor tubercle. The incisions are, from left to right, for ligation of the vessel in Hunter's canal, at the apex of Scarpa's triangle, and below Poupart's ligament (common femoral).

small and situated where the vessel is large ; this is referred to again in connexion with ligation of the common femoral (see p. 320).

When no attempt to suture the wound in the vessel wall is deemed feasible or advisable, the vessel should be secured by ligation above and below the wound in its wall, and it will be a good plan to divide the vessel completely between the ligatures, as this allows retraction of the ends and complete protection against secondary hæmorrhage.

(ii) *Aneurysm.* The spot at which the vessel should be secured will vary according to the situation of the aneurysm ; thus, for an aneurysm in the popliteal space the artery may be tied either in Hunter's (the adductor) canal, or at the apex of Scarpa's triangle (the femoral trigone) ;

for an aneurysm of the superficial femoral the artery might be tied at the apex of Scarpa's triangle (the femoral trigone); more probably, however, the common femoral artery would have to be tied.

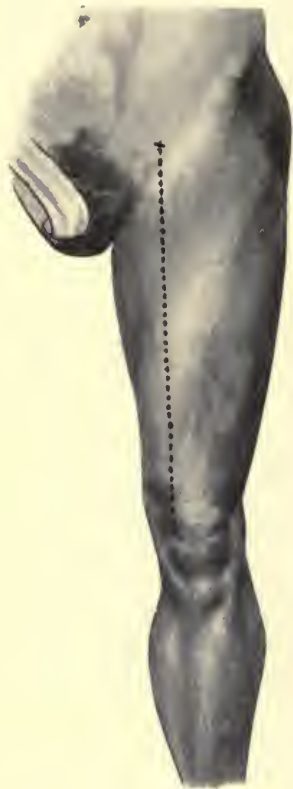

FIG. 166. LINE OF THE FEMORAL ARTERY WHEN THE LOWER EXTREMITY IS FULLY EXTENDED. The upper X is on the mid-point between the anterior superior iliac spine and the symphysis pubis, the lower on the inner border of the patella.

(iii) In *aneurysmal varix* at the groin the common or the superficial femoral artery may require ligature. In such a case as this, however, the best operation would be to secure the femoral between double ligatures on each side of the communication, and then to divide the vessel between the double ligatures, thus leaving the circulation through the vein unimpaired; or it might be possible to expose the connexion between the two vessels and suture each orifice separately (see p. 278).

(iv) Ligature of the femoral may be necessary in *the removal of large growths* from Scarpa's triangle. As a rule, however, it will be sufficient to expose the common femoral trunk and apply a temporary ligature or a Crile's clamp (see Fig. 140) to it. This matter is more fully referred to in connexion with ligature of the common femoral artery (see p. 320).

Surgical anatomy. The femoral artery is the direct continuation of the external iliac; it extends from the lower border of Poupart's ligament to the tendinous opening in the adductor magnus. Its course is indicated by a line drawn from the mid-point between the anterior superior spine of the ilium and the symphysis pubis to the adductor tubercle when the knee is slightly flexed and the thigh rotated outwards (see Fig. 165). When the limb lies flat on the table, and is parallel to its fellow, however, the line of the artery is materially altered—

a point of great importance when tying the vessel in the rigid dissecting-room subjects prepared by the formalin method. In this case the line should be taken to the inner border of the patella instead of to the adductor tubercle (see Fig. 166). In the upper half of its course the artery lies in Scarpa's triangle (the femoral trigone), and is superficial. In the

lower half, however, it is more deeply placed and lies in Hunter's (the adductor) canal. At its commencement the artery lies in a funnel-shaped process of the fascia called the femoral sheath, which is divided by septa into three compartments, the outer one containing the artery and the crural (lumbo-inguinal) branch of the genito-crural (genito-femoral) nerve, the middle one the femoral vein, and the most internal, called the crural canal, containing lymphatics and lymphatic glands. The first inch and

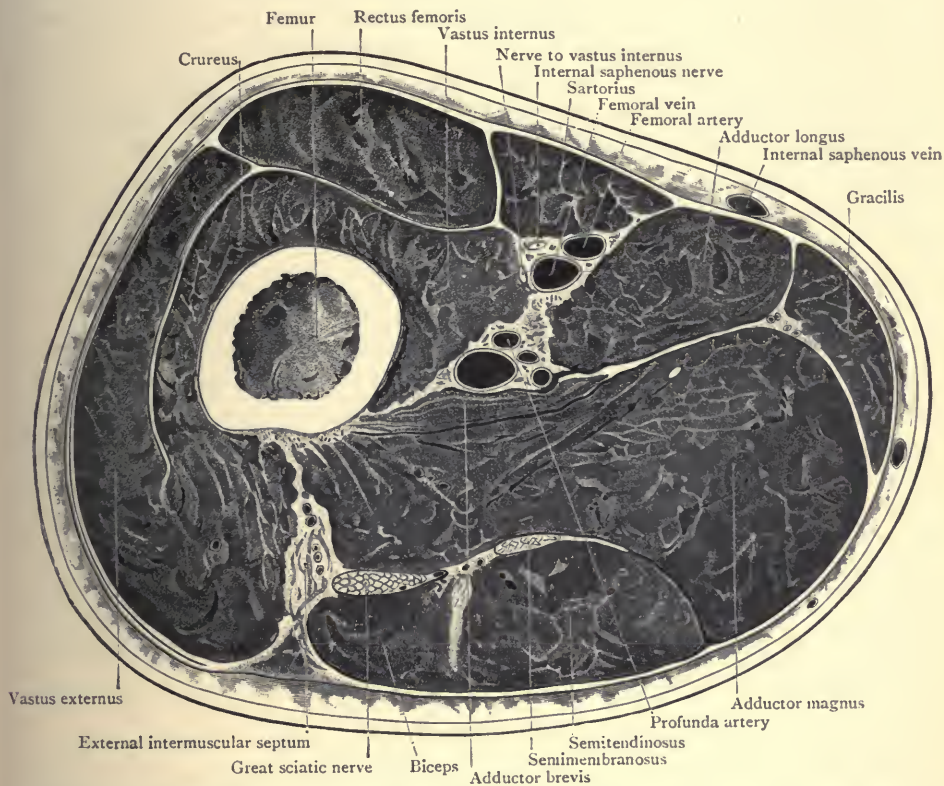


FIG. 167. SECTION THROUGH THE THIGH AT THE LEVEL OF THE UPPER PART OF HUNTER'S CANAL (Cunningham's *Anatomy*).

a half to two inches of the vessel is known as the common femoral, the rest being termed the superficial femoral.

In front the artery is covered by the skin and superficial fascia, in which are the superficial inguinal glands, and the superficial circumflex iliac vein crosses it. It is also covered by the anterior part of the femoral sheath, the iliac portion of the fascia lata, the cribriform fascia, and, below this, by the deep fascia of the thigh. Near the apex of Scarpa's triangle

(the femoral trigone) it is crossed by a cutaneous branch of the anterior crural (femoral) nerve and a branch of the internal (great) saphenous vein. The crural (lumbo-inguinal) branch of the genito-crural (genito-femoral) nerve is in front and to the outer side of the artery above, and runs for some distance within the femoral sheath.

In Hunter's (the adductor) canal (see Fig. 167) the vessel is covered by a special fascia forming the roof of the canal; superficial to this is the sartorius muscle with the skin, superficial and deep fasciæ. The internal or long saphenous nerve lies at first to the outer side of the artery in the canal, then it crosses in front of it, and finally descends upon its inner side.

Behind, the artery is in relation from above downwards with the posterior part of the femoral sheath, the pubic portion of the fascia lata, the psoas, pectineus, and the upper part of the adductor longus muscle; while in Hunter's (the adductor) canal it lies in the angle between the vastus internus (medialis) and the adductors. The nerve to the pectineus passes between the artery and the psoas muscle, while the femoral vein and the profunda artery and vein intervene between it and the pectineus. The femoral vein also separates it from the adductor longus.

Laterally, the femoral vein lies to the inner side of the artery above, at the apex of Scarpa's triangle (the femoral trigone) it passes behind it, and in Hunter's (the adductor) canal it is posterior and to some extent external to it. On the outer side of the artery above is the anterior crural (femoral) nerve, but this structure is separated from it by nearly half an inch. Lower down, the saphenous nerve crosses the artery obliquely in Hunter's (the adductor) canal from the outer to the inner side, and the nerve to the vastus internus (medialis) is on its outer side.

The artery may be tied in three situations: (i) in Hunter's (the adductor) canal, (ii) at the apex of Scarpa's triangle (the femoral trigone), (iii) above the origin of the superficial femoral.

LIGATURE IN HUNTER'S CANAL

The surgeon stands on the outer side and has the knee flexed and the thigh somewhat abducted and rotated outwards. An easy way to maintain this position is to place the foot of the affected side upon the opposite instep and to support the knee on a suitable sand-bag. The line of the artery (*vide supra*) is marked out, and the surgeon makes an incision about three inches long in the line of the vessel, with its centre opposite the middle of the thigh (see Fig. 165). As the wound is deepened the internal (great) saphenous vein will probably be encountered and should be drawn aside, or divided between ligatures if this be impossible. The deep fascia is then incised throughout the length of the wound, and the sartorius comes into view. This muscle is identified by the direction of its fibres,

which run vertically downwards. The outer border of the muscle is defined and drawn inwards or downwards with a retractor. This exposes the roof of Hunter's (the adductor) canal, which can nearly always be distinguished by the transverse direction of its fibres, and through which the pulsations of the artery can be felt in the living subject (see Fig. 168). The roof of the canal is now opened throughout the length of the wound, and the artery comes into view with the saphenous nerve crossing it from without inwards. The nerve to the vastus internus (medialis) lies some distance to the outer side of the vessel and is not seen if the incision has

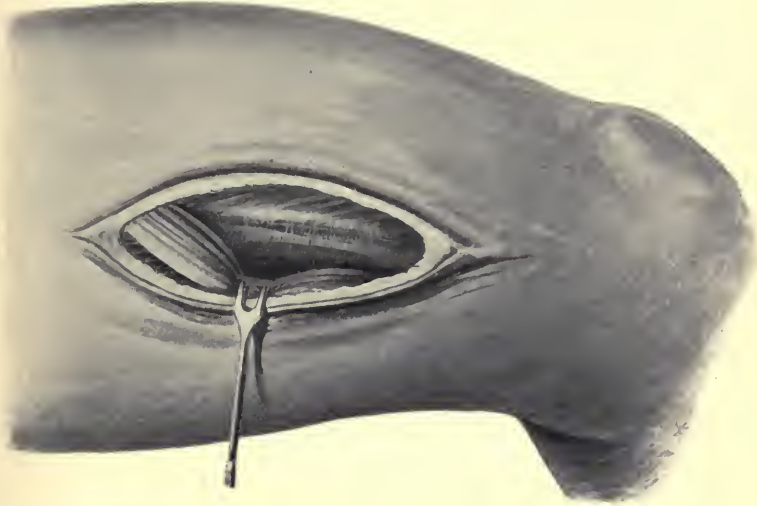

FIG. 168. LIGATURE OF THE FEMORAL ARTERY IN HUNTER'S CANAL. The sartorius is pulled down by the retractor, exposing the vastus internus (medialis) fibres and the aponeurotic roof of Hunter's canal, through which can be seen the artery with the long saphenous nerve crossing it obliquely from without inwards.

been accurately made. The sheath is opened, the vessel cleared, and the aneurysm needle passed in the usual way, and in whatever direction is easiest, care being taken to keep it closely in contact with the posterior aspect of the artery, as the vein lies behind.

Difficulties and dangers. The chief difficulty in the operation comes from taking an incorrect line for the artery, so that the incision is made too far internally, and the surgeon looks for the vessels on the muscles on the inner side of the thigh. If this be done a deep dissection may be made without any chance of finding the vessel. It is very important to remember that the limb should be rotated outwards and moderately abducted before the incision is made; if this cannot be done owing to rigidity of the limb, the alternative line given above (see p. 314) should

be used and will help to avoid confusion. The vein lies behind the artery and is not seen, but it may be wounded by the aneurysm needle unless care be taken to keep the point of the latter in close contact with the vessel wall as it is passed around its posterior aspect. Fig. 169 gives a clear view of the relations of the structures in this region.

LIGATURE AT THE APEX OF SCARPA'S TRIANGLE

The limb should be in the same position as for the preceding operation (*vide supra*), and the surgeon, standing on the outer side of the limb,

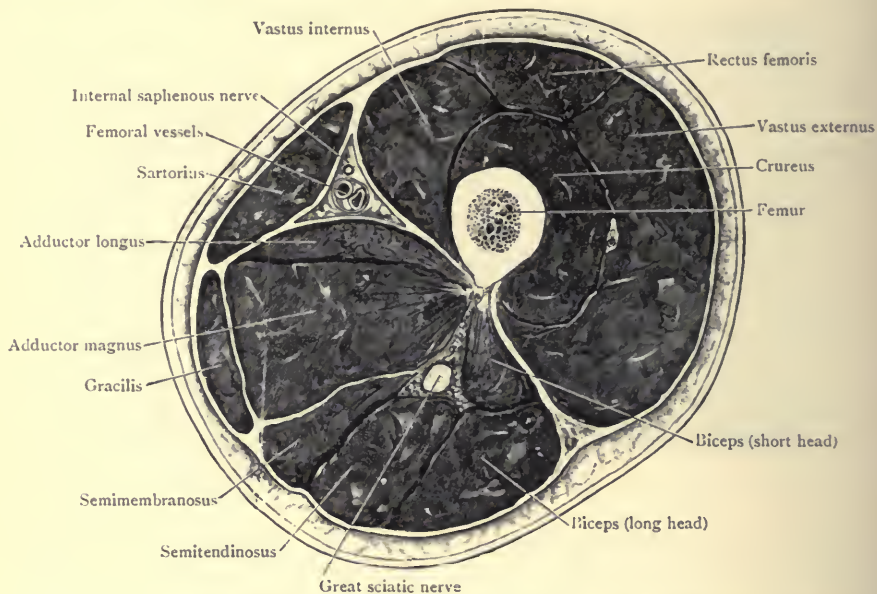


FIG. 169. TRANSVERSE SECTION THROUGH THE THIGH (HUNTER'S CANAL)
(Cunningham's *Anatomy*.)

makes an incision about two inches long in the line of the artery (see p. 314), commencing about four inches below Poupart's ligament. The skin and fascia are divided throughout the whole length of the wound—dividing the veins going to join the saphenous—when the sartorius comes into view, and is identified by the direction of its fibres, which run obliquely downwards and inwards. The inner border of this muscle is defined and drawn outwards with a retractor, and the artery will then be felt pulsating immediately beneath the muscle at the lower end of the wound. The femoral sheath is opened well to the outer side, taking care in doing so to avoid damage to the crural (lumbo-inguinal) branch of the genito-crural (genito-femoral) nerve. The artery is carefully cleared, and the

needle is passed from within outwards ; it must be kept very close to the artery in the first part of its course, so as to avoid the vein which lies to the inner side, and somewhat behind the artery. When the ligature is tightened, the middle and internal coats of the vessel should be divided.

Difficulties and dangers. Wound of the femoral vein is not a very uncommon accident and generally results from clumsy attempts to clear the artery. Unless the sheath be adequately opened before the



FIG. 170. LIGATURE OF THE SUPERFICIAL FEMORAL AT THE APEX OF SCARPA'S TRIANGLE. The sartorius is pulled outwards by the retractor. The small nerves in the hook are cutaneous branches from the anterior crural.

needle is insinuated round the vessel, its point is apt to be forced through the wall of the vein. Should such an accident occur, pressure should be applied to the vein on both sides of the injured spot and a lateral ligature applied. The artery should then be cleared at a fresh spot lower down and tied.

The internal (great) saphenous vein may be exposed and wounded ; if so, it should be tied. This accident is not of the least consequence in an aseptic wound and does not give rise to œdema unless sepsis occurs.

No other accidents are likely to occur, as the artery is superficial and

easily found, and the various nerves in the vicinity are some little distance from the vessel.

Before the operation, the whole lower extremity should be scrupulously purified and wrapped up in sterilized cotton wool. After the operation, the limb should be elevated in bed on a firm pillow with a stout ring pad beneath the heel and a cradle over the limb, so as to minimize the risk of gangrene. In all cases of ligature of the femoral artery the patient must be kept in bed for at least three weeks after the operation. When this has been done for aneurysm another three or four weeks must be allowed for proper consolidation to occur in the sac.

LIGATURE BELOW POUPART'S LIGAMENT (THE COMMON FEMORAL)

This operation is comparatively often done and may be required :

Indications. (i) For a *wound of the artery* or for one of the sequelæ of a wound, such as a *traumatic aneurysm* or an *aneurysmal varix*. The wounds of this vessel that the surgeon is likely to be called upon to treat are either punctured wounds of the groin, where the damage to the artery is small enough to allow of its being stopped by pressure before the hæmorrhage is fatal, or, more commonly, an injury to the vessel occurring during an operation such as removal of large tumours from the groin.

Ligature of the artery need not necessarily be performed for simple wounds that do not involve loss of a portion of the vessel wall, as it is here that arteriorrhaphy should find one of its most useful applications, since it is easy to control the circulation above and below the wound, and the size of the artery allows of easy manipulation and suture of the vessel wall without materially interfering with its lumen. Even complete division of the vessel may be treated by end-to-end suture provided that no portion of the artery be actually removed ; the loss of a portion would probably prevent end-to-end union owing to the difficulty of getting the divided ends into apposition. When, however, large growths or malignant glands are being removed from the groin, portions of the artery and the vein may be removed with them either accidentally or designedly. The vein more often requires removal than the artery, as its sheath is in close proximity to the glands and soon becomes infiltrated, in which case it is much sounder surgery to remove the glands with the requisite portion of the vein than to dissect the glands off the wall of the vein, a procedure which is very liable to end in recurrence. Removal of a portion of the common femoral vein presents no risks provided that the wound be aseptic, nor need the surgeon hesitate to

remove a portion of the common femoral artery also should occasion demand it.

That complete removal of the main artery and vein of the limb from the external iliac to the profunda does not necessarily cause gangrene was proved by the case shown by Mr. C. H. Fagge at the Royal Society of Medicine, May 8, 1908, in which the right external iliac artery was exposed and trebly ligatured with catgut, the lowest ligature being an inch and a half above Poupart's ligament. The deep epigastric was tied, the incision prolonged downwards, and the superficial femoral ligatured, as was also the deep femoral branch. The circumflex iliac vessels were similarly treated, and the corresponding veins were tied so that the whole mass could be removed. The thigh and leg presented a mottled appearance for forty-eight hours, after which pulsation returned, but the pulse in the operation area could not be felt for a month afterwards. Superficial gangrene appeared in the region of the wound, and a small blister formed on the heel.

In cases of *aneurysmal varix* it will hardly ever be necessary to tie the common femoral, since the circulation can be controlled effectually on both sides of the communication by a temporary ligature, after which an attempt may be made to separate the union between the vein and the artery and to repair the opening in each of these structures by appropriate plastic methods (see p. 278). Failing this, the best plan will be to secure the artery on either side of the anastomosis, and then to suture the opening in the vein so as not to impair the circulation through it.

(ii) Ligature of the common femoral has been only rarely performed for the cure of an *aneurysm of the superficial femoral*, as in the past the majority of surgeons were in favour of applying a ligature to the external iliac instead. The reasons given for this were that the collateral circulation in the neighbourhood of the ligature on the common femoral is so free that proper consolidation is not likely to occur in the aneurysm, and that the length of the common femoral is so variable that it is easy to tie the superficial branch in mistake for the common trunk. An argument that formerly weighed considerably against the operation was the risk of gangrene, which appears to have been much greater when the common femoral was tied than when the ligature was put on the external iliac.

This, however, was associated with sepsis and is not now to be feared. The arguments adduced above do not appear to rest upon any sound basis, and excellent results have been obtained by the ligature of the common femoral. I should not hesitate to make use of it for aneurysm high up on the superficial femoral in a suitable case, although it is probable that Matas's operation will largely take its place in the future.

Operation. The groin is shaved, the limb is put into a position similar to that for the preceding operation (see p. 316), and the line of the artery (see p. 314) marked out as before. It is important to identify Poupart's ligament accurately, which is often difficult in the dead body but easy in the living subject. An incision two inches long is made in the line of the artery with its centre over Poupart's ligament, and the superficial structures are divided until that structure is reached. Several glands and small vessels are met with and must be dealt with as may be

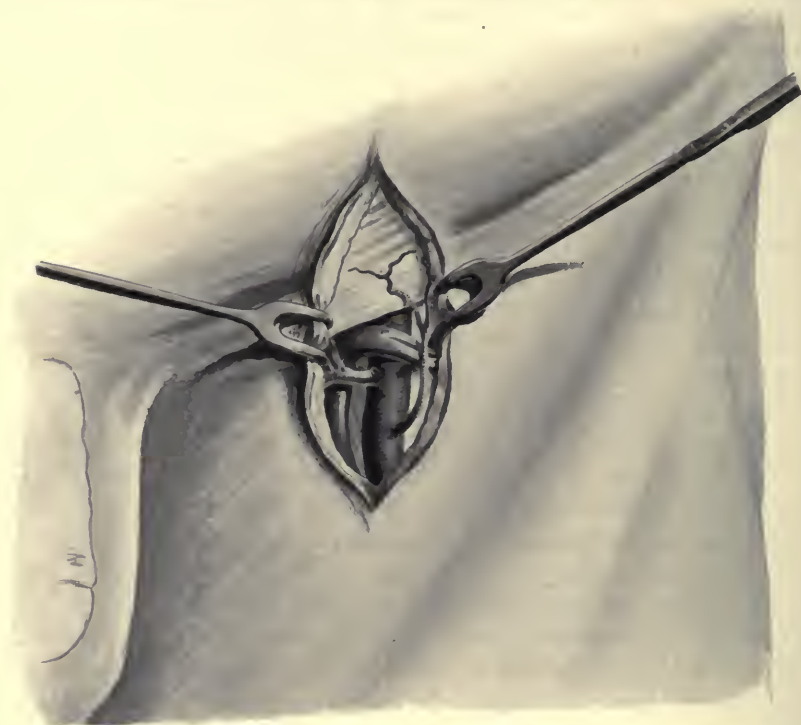


FIG. 171. LIGATURE OF THE COMMON FEMORAL BENEATH POUPART'S
LIGAMENT.

necessary. The deep fascia of the thigh is opened immediately below Poupart's ligament by a vertical incision, when the artery can be felt at once. The femoral sheath is opened well to its outer side and the artery is cleared (see Fig. 171). The needle is passed from within outwards, and care must be taken to keep it in close contact with the vessel so as to avoid taking in the crural (lumbo-inguinal) branch of the genito-crural (genito-femoral) nerve which lies upon the front of its sheath. In tying the ligature it will be well to make use of the stay-knot (see p. 290), and not to divide the inner and middle coats of the vessel. The wound is

closed without a drainage tube : the treatment of the limb is the same as in the preceding operation (see p. 320).

The *after-treatment* is the same as for the previous case.

Difficulties and dangers. The chief difficulty is the uncertainty as to whether the common trunk or the superficial branch has been secured. It is not uncommon to find the common femoral exceedingly short ; it is rarely more than one and a half inches long, and on occasions it may be almost absent. Under these circumstances the surgeon mistakes the superficial femoral for the common trunk. This mistake is very common in operations upon the dead subject, and is best avoided by making sure that the point at which the artery is tied is immediately under Poupart's ligament ; the further away from it the ligature is placed, the greater is the likelihood of mistake.

CHAPTER VIII

LIGATURE OF THE ARTERIES OF THE PELVIS

LIGATURE OF THE EXTERNAL ILIAC ARTERY

Indications. (i) This artery is rarely tied ; almost the only condition that calls for ligature of it is a *femoral aneurysm* high enough up to preclude ligature of either the superficial or the common femoral trunk.

(ii) For *wounds of the external iliac* it is not likely to be practised frequently. Wounds of that vessel are rare, and the few cases that survive the injury long enough to come under the hands of the surgeon will be more appropriately treated by some form of arteriorrhaphy (see p. 261). The external iliac artery is so large that suture of a wound in its walls should be a matter of comparative simplicity. It can be exposed by either of the methods given below, the circulation temporarily arrested by clamps or temporary ligatures applied on both sides of the wound, and the latter sutured. Even complete division of the artery—which as a non-fatal event would only be likely to occur during the course of a surgical operation—would be better treated by an end-to-end circular arteriorrhaphy (see p. 265) than by ligature.

(iii) Ligature of the external iliac artery was formerly a recognized method of treatment for *elephantiasis*, but this has been given up ; it is useless and not devoid of risk.

Surgical anatomy. This artery is the larger of the two terminal divisions of the common iliac trunk, and extends from the side of the lumbo-sacral articulation to Poupart's ligament. The anatomical line of the artery is from a point three-quarters of an inch below and a little to the left of the umbilicus, to another point midway between the anterior superior spine of the ilium and the symphysis pubis ; the former point lies on the level of a line joining the highest parts of the crests of the ilia. The lower two-thirds of this line denote the external iliac vessel. The artery varies in length, but usually is about three and a half inches long.

In front of the artery are the peritoneum, and on the right side the terminal portion of the ileum and occasionally the appendix, while on the left side are the sigmoid flexure and some coils of small intestine. The ureter may cross the artery near its origin ; the ovarian vessels also cross it in the female, and the spermatic in the male, the former near its

origin, the latter near its termination. Near its termination also, the genital (external spermatic) branch of the genito-crural (genito-femoral) nerve and the deep circumflex iliac vein are in front of the vessel, while the vas deferens in the male and the round ligament in the female curve over it to enter the pelvis; numerous lymphatic vessels lie in front of the vessel throughout its whole length.

Behind, the artery lies upon the iliac fascia, from which it is separated by the external iliac vein above, and the psoas muscle and its tendon lower down; near its commencement the obturator nerve lies behind the artery.

Laterally, the genito-crural (genito-femoral) nerve lies to its outer side, while internally and somewhat more deeply placed is the external iliac vein. This aspect of the vessel is covered by peritoneum and is crossed by the vas deferens in the male and the ovarian vessels in the female.

Operation. The vessel may be reached by two routes, namely the *extra-peritoneal* or the *trans-peritoneal*. Of these the former is better suited for those cases in which the ligature has to be applied to the lower end of the artery, whilst the trans-peritoneal method is generally reserved for those in which the ligature must be applied high up, or may even have to be put round the common iliac trunk. Trans-peritoneal exposure of the artery, as will be seen from a perusal of the steps of the operation, is a very simple method, and it affords ample access to the great vessels, from the bifurcation of the aorta downwards, in a way that none of the other operations do. Now that trans-peritoneal operations have been robbed of their risk of sepsis, and especially since the introduction of the Trendelenburg position, the abdomen should be opened in all cases except those in which it is certain that the surgeon will have to deal with the extreme lower end of the vessel only. For these, Sir Astley Cooper's extra-peritoneal method is all that is required. It allows easier access to the vessel than does the trans-peritoneal method, in which the deep epigastric artery gets seriously in the way when the lower end of the vessel has to be exposed; at the same time there is no weakness left in the abdominal wall after it.

THE EXTRA-PERITONEAL OPERATION

Two operations are usually given in books for extra-peritoneal exposure of this vessel, called respectively by the names of Sir Astley Cooper and John Abernethy. Of these Sir A. Cooper's operation is probably the only one that would be done at the present day, and is well suited for reaching the artery at the lower end of its course with the least displacement of parts or liability to subsequent weakening of the abdominal wall. Abernethy's operation, on the contrary, does more damage to the abdominal

wall, and is apt to leave it permanently weakened ; it is more adapted for the application of a ligature high up on the external iliac artery, or on the common trunk, and, as this object is better attained by the trans-peritoneal method, Abernethy's operation will not be described here.

Sir Astley Cooper's operation. The bowels should be well cleared out before operation, and the pubic region shaved. An incision from three and a half to five inches long, according to the thickness

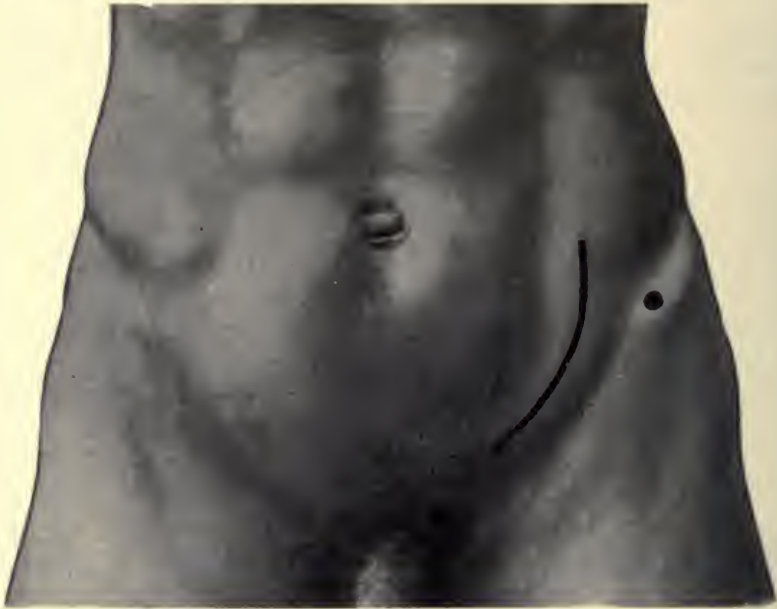

FIG. 172. SIR ASTLEY COOPER'S INCISION FOR EXTRA-PERITONEAL LIGATURE OF THE EXTERNAL ILIAC ARTERY. The right-hand dot is over the anterior superior iliac spine, the left-hand one over the spine of the pubes.

of the subcutaneous fat, is commenced at a point an inch and a quarter outside the pubic spine, and three-eighths of an inch above Poupart's ligament. The first two-thirds of this incision run parallel to Poupart's ligament, and then the incision curves upwards and inwards until it terminates an inch above and internal to the anterior superior spine of the ilium (see Fig. 172). In this incision numerous superficial vessels (*e.g.* superficial epigastric and circumflex iliac) are divided and will require ligature. When the incision has been deepened down to the external oblique aponeurosis, that structure is carefully slit up in the direction of its fibres throughout the whole length of the incision, and the fleshy fibres of the internal oblique muscle are identified below it. These in turn are

divided to a similar extent and carefully differentiated from the arched fibres of the transversalis muscle a little deeper ; at this stage the upper end of the internal abdominal ring will come into view. The fibres of the transversalis muscle are next cut through in the line of the wound, exposing the transversalis fascia ; in the living subject there is usually a definite layer of cellular tissue between these two structures. The transversalis fascia is similarly divided throughout the extent of the wound and the extra-peritoneal fat and cellular tissue exposed. This stage of the operation requires to be done with great care, as the peritoneum may be mistaken for the transversalis fascia and opened by mistake.

When the transversalis fascia has been divided, the fingers are inserted into the wound, and the peritoneum is gently stripped upwards and inwards from the iliac fossa towards the umbilicus, carrying with it the intestines contained inside it. This is done with the fingers, as there is then less risk of damaging the membrane, and it must be effected with gentleness ; if force be employed, the iliac fascia may be separated from the psoas muscle, and the vessels stripped up and carried with it. When the peritoneum has been separated sufficiently widely, a large retractor is inserted so as to pull it and the intestines up towards the umbilicus, and a good view can be then obtained, especially if a forehead-lamp be used. The external iliac artery will be felt running along the brim of the pelvis near the inner end of the wound, and its sheath should be opened well on the outer side, so as to avoid the vein which lies to its inner side. The genito-crural (genito-femoral) nerve must also be avoided both in clearing the sheath and in passing the ligature, which should be done from the inner side ; the simplest plan is to hold the nerve aside with a small hook.

It is usual to tie the artery about an inch and a half above Poupart's ligament, so as to be above the origin of the deep epigastric branch which comes off the parent trunk quite close to the ligament. The ligature should only be tied tight enough to approximate the coats of the vessel and not to divide them ; for this purpose the ' stay-knot ' (see p. 290) is excellent.

After the bleeding has been arrested, the cut edges of each individual muscle are approximated by sutures of moderately stout catgut, and the wound is closed without a drainage tube. It is important, both for the proper approximation of the parts and the relief of tension on the divided abdominal muscles, that the patient should be propped up after the operation, and a large pillow placed under the knees so as to relax the abdominal wall as fully as possible. The precautions already indicated (see p. 320) are taken to avoid the occurrence of gangrene.

Difficulties and dangers. The difficulties of this operation are greater in the dead subject than in the living, in whom the differentiation between the various muscular planes of the abdominal wall is quite well marked. In the dead subject, especially in old and emaciated persons, it is easy to mistake the peritoneum for the transversalis fascia and to open the former by mistake. In the living subject, however, this mistake is not likely to occur unless the incision be begun too high above Poupart's ligament, in which case the well-marked cellular interval, which is always present between the fascia transversalis and the point at which the peritoneum becomes reflected from the abdominal wall on to the iliac fossa, is missed. Should such an accident happen, however, it would have but slight importance at the present day, since the operation could be completed quite satisfactorily either after sewing up the rent in the peritoneum or by enlarging the incision in it and completing the operation through the peritoneum.

The chief difficulty both in the living and the dead subject will be found in too short an incision. It is of great importance to calculate the length of the incision carefully, and to make all the incisions in the deeper parts the same length as that in the skin. The danger of detaching the artery from the psoas muscle has already been referred to; this accident, however, can hardly happen except as the result of using considerable force. Injury to the vein or to the genito-crural nerve may occur, but is easily avoided by care in clearing the vessel. The operator is usually warned not to open the internal ring, but this is a matter of very little importance, as it is easily sewn up subsequently. A more important thing is damage to the cord, which may occur if the incision be placed too low.

Jacobson and Rowlands (*The Operations of Surgery*, Fifth Edition, vol. ii, p. 7) mention a method of performing this operation by splitting the fibres of the abdominal muscles in the same manner as is done in the appendix operation. They claim for it that 'the risk of ventral hernia is greatly diminished, and the difficulties of the operation are not materially increased, if good retractors be used'. It is difficult to see why the ordinary operation should be accompanied by any risk of ventral hernia if the wound be kept clean and no drainage tube be used. Indeed, as far as the muscular incisions are concerned they correspond fairly closely to certain forms of operation for the radical cure of hernia. Any one who has tried the two methods will agree, I think, that it impedes the operator to split the muscles, and that in a fat subject it would be almost impossible to expose the artery thus if an aneurysm were present. Moreover, there is likely to be troublesome bleeding from large branches of the deep epigastric.

THE TRANS-PERITONEAL OPERATION

For reasons already mentioned (see p. 325) this method offers decided advantages over the preceding one, as it enables the surgeon to apply the ligature to any part of the vessel that may seem desirable; or he can, if he thinks fit, secure the common iliac trunk or the internal iliac branch through the same incision. The risks attaching to this operation have been very largely diminished at the present day, owing to the adoption of the Trendelenburg position; thanks to it, the field of operation is never obscured and the operation is greatly simplified.

A very useful incision is one about an inch to the mesial side of the *linea semilunaris*, from about half an inch above Poupart's ligament to the level of, or well above, the umbilicus, according to the fatness of the patient. The anterior layer of the sheath of the rectus is first divided, and then the outer edge of the rectus is defined and the muscle pulled inwards towards the middle line. The deep epigastric vessels must not be wounded in doing this, as very troublesome bleeding may occur if they are. The posterior layer of the sheath and the peritoneum are then opened in the line of the original skin incision, the patient is put in the Trendelenburg position, and the intestines are packed well out of the way in the upper half of the abdomen by means of a large abdominal cloth. The edges of the wound are held wide apart with broad flat retractors, and, if necessary, a forehead lamp is used to illuminate the field of operation.

The next steps of the operation vary somewhat according to whether the artery to be tied is on the left or the right side. On the left side the artery is covered by the meso-rectum, which has to be divided before the vessel can be reached. The common iliac and the upper part of the external trunk are covered by the inferior mesenteric vessels as they pass down in the meso-sigmoid to reach the meso-rectum. In order to reach the artery in this situation, therefore, it will be necessary to make a vertical slit in the peritoneum just to the left of the middle line, and then to peel this structure outwards until the vessel is exposed. In doing this the large common and external iliac veins are also exposed. The ureter must be looked for and carefully avoided, as it would be disastrous to include it in the ligature, which should be passed from the vein, *i.e.* the inner, side.

On the right side, the operation is much easier, the artery being crossed by the termination of the ileum, which only requires to be pulled up, and the peritoneum can then be divided directly over the vessel. The operation is therefore much easier on the right side than on the left.

The coats of the vessel are approximated by a 'stay-knot' (see

p. 290), and when that has been tied and the ends cut short the incision in the peritoneum is closed by a fine catgut suture. The abdominal wall is closed in the usual way, as after laparotomy.

Difficulties and dangers. There are a few difficulties attending this form of the operation. The chief one is the difficulty in getting a good view of the artery; this is only of real importance in very fat subjects. When there is an immense amount of fat in the abdominal wall, the omentum, and the mesentery, &c., it becomes very difficult to get a clear field for operation. The difficulty is best obviated by the use of the Trendelenburg position; a clear view of the field of operation can be obtained after packing the intestines out of the way, and it should then be impossible to overlook the presence of the ureter and include it in the ligature.

On the right side it is a little difficult to clear the vessel so as to avoid the vein, but only patience is required.

LIGATURE OF THE INTERNAL ILIAC (HYPOGASTRIC) ARTERY

Indications. These will be very few. Almost the only condition for which the artery is likely to require ligature is an aneurysm in the gluteal region. The vessel may sometimes be tied as a preliminary to excision of the rectum by the abdomino-perineal method; it may be tied also as a preliminary to complete extirpation of the uterus.

If a gluteal aneurysm be present it is most difficult to ligature the superior gluteal artery, and the old operation of laying open the sac, turning out the clot, and securing the open mouth of the vessel is a very hazardous one.¹ Ligature of the internal iliac (hypogastric) artery, of which the superior gluteal is the terminal branch, is therefore a much simpler method. Similarly, when a gluteal abscess opens into the artery and forms a diffuse aneurysm in the buttock, it may be necessary to tie the internal iliac (hypogastric) trunk.

Ligature of the internal iliac (hypogastric) artery forms a recognized preliminary measure in the abdomino-perineal resection of the rectum recommended by Hartmann and Quénu, and I have performed it with ease and rapidity in two such cases. In panhysterectomy, on the other hand, it is not so generally necessary, as the uterine and vaginal vessels can be secured *seriatim* with comparative ease.

In certain cases of wounds of the buttock such as stabs or bayonet wounds, or injuries to the pelvis by means of firearms, there may be severe bleeding from a wound in the neighbourhood of the great sacro-

¹ See, however, the case reported by Abbé (see p. 269).

sciatic foramen, apparently from the gluteal artery. If slight enlargement of the wound does not allow the surgeon to secure the bleeding vessel, and if the loss of blood be severe, it will be wise to plug the wound firmly with gauze and adrenalin, and to open the abdomen with the view of securing the internal iliac (hypogastric) artery.

Anatomy. The artery is about one and a quarter inches long and extends from one side of the lumbo-sacral articulation to the upper margin of the great sacro-sciatic foramen, where it divides into its two terminal branches.

It is covered *in front* by the peritoneum and is crossed by the ureter. On the left side it is crossed by the rectum, which eventually lies on its inner side, and on the right side the coils of small intestine do the same. Both the external iliac (just before it becomes the common iliac) and the internal iliac (hypogastric) veins lie *behind* it, as do also the lumbo-sacral cord and the sacrum. It is separated from the inner edge of the psoas by the external iliac vein above. The obturator nerve also lies between it and the wall of the pelvis rather posterior to the vessel.

The operation is done by the trans-peritoneal method, in a manner similar to that described for the external iliac trunk. The extra-peritoneal route is so unnecessarily difficult and hazardous that it is not likely to be used and therefore will not be described.

After the abdomen has been opened and the intestines have been packed out of the way, the bifurcation of the common iliac is felt for and the internal iliac (hypogastric) artery is traced down into the pelvis. The peritoneum is incised over the artery, and the vessel cleared, and a ligature passed from whichever side may be most easy.

LIGATURE OF THE COMMON ILIAC ARTERY

Indications. (i) The chief affection for which ligature of the common iliac trunk will be required is an *aneurysm of the external iliac artery*. Owing however to the great risk of gangrene following ligature (*vide infra*) an attempt to preserve the circulation in the vessel by means of Matas's operation (see p. 266) will be probably preferred.

(ii) The vessel has been tied on several occasions for *wounds*—usually in association with gunshot injuries. These cases must obviously always be rare, as the condition is a very fatal one. Here again ligature will probably be abandoned in future in favour of arteriorrhaphy (see p. 263).

(iii) It has also been tied for *secondary hæmorrhage*, but this will hardly be necessary at the present time when secondary hæmorrhage has practically disappeared from surgery.

(iv) Either the common or the external trunk will be ligatured and divided in *removal of one half of the pelvis*.

Anatomy. The artery extends from the bifurcation of the aorta (three-quarters of an inch below and a little to the left of the umbilicus, opposite the middle of the fourth lumbar vertebra) to one side of the lumbo-sacral articulation, where it divides into its external iliac and internal iliac (hypogastric) branches.

The *right common iliac artery* is longer than the left and has behind it the commencement of the vena cava, both the common iliac veins, the psoas muscle, the lumbo-sacral cord, the obturator nerve, and the ilio-lumbar artery. *In front* it is covered by the peritoneum, the termination of the ileum, and sometimes by the head of the cæcum and the appendix. The ureter crosses it near its bifurcation, as do also the ovarian vessels in the female. To its *outer side* lie the vena cava, the upper end of the right common iliac vein, and the psoas. To its *inner side* is the right common iliac vein below and the left common iliac vein above.

The *left common iliac artery* is one and three-quarter inches long and has the same relations *in front* as the right, except that it is crossed by the sigmoid flexure and its meso-sigmoid, containing the superior hæmorrhoidal vessels, instead of the end of the ileum. *Behind*, it lies upon the fourth and fifth lumbar vertebræ, the obturator nerve, the ilio-lumbar artery, and the lumbo-sacral cord. To its *outer side* is the psoas; to its *inner side* are the left common iliac vein and the middle sacral artery.

Operation. The operation is done in all respects in the same manner as that for the trans-peritoneal ligature of the external iliac, except that in this instance it will be better to make the abdominal incision nearer to the middle line; it should therefore extend from an inch and a half above Poupart's ligament to just above the level of the umbilicus, and should be about an inch to its own side of the middle line. The anterior layer of the sheath of the rectus is opened, the inner margin of that muscle is defined and pulled outwards, and the posterior layer of the sheath and the peritoneum are divided in the usual manner. The Trendelenburg position is then adopted, and the intestines packed up out of the way.

The peritoneum is incised directly over the artery, and the ligature is passed as in the case of the external iliac. The *after-treatment* is also similar.

There is more than one method of applying a ligature to this vessel by the extra-peritoneal route which has been in vogue in the past, but which will be entirely abandoned in future in favour of the safer, more certain, and more rapid trans-peritoneal operation. The latter is so obviously superior, that the extra-peritoneal operation will not be described.

The ligature should be tied only tightly enough to approximate the coats of the vessel without dividing them, and it is well to use the 'stay-knot' with a double floss silk ligature as recommended by Ballance and Edmunds (see p. 290).

Results. Gillette (*Annals of Surgery*, vol. *xlvi*, 1908, p. 22) reports

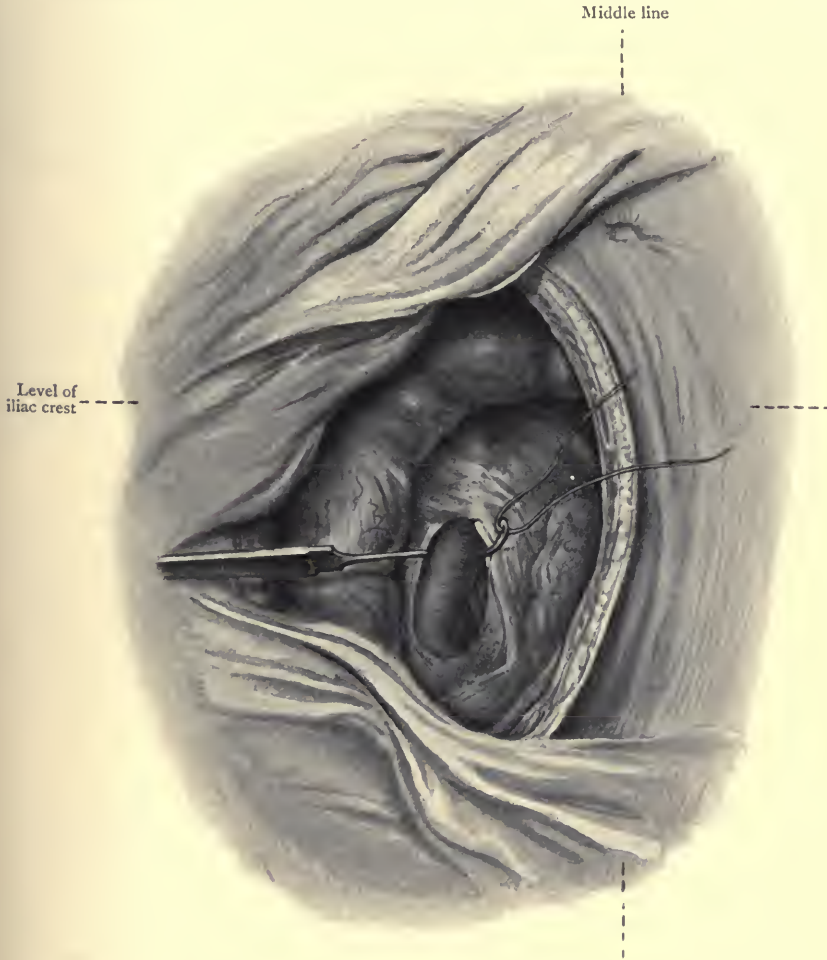


FIG. 173. LIGATURE OF THE RIGHT COMMON ILIAC ARTERY. The needle is passed around the vessel just above its bifurcation. The ureter is seen pulled towards the middle line and just denuded of its peritoneal covering in the upper part of the incision in the peritoneum.

a case of ligature of the common iliac for aneurysm of the sciatic artery. The ligature was practised through the peritoneum and tied close to the bifurcation of the aorta. Gangrene of the leg followed and amputa-

tion was done at the junction of the upper and middle thirds, but the flaps sloughed and finally a cure resulted after amputation six inches above the knee. He gives a summary of the cases reported, and mentions eighty cases with fifty-six deaths, or a death-rate of 70 per cent.; fifty-nine of these he classes as prior to the antiseptic era in 1880, and of these forty-six died, a death-rate of 77.97 per cent. Since 1880 twenty-one cases have been reported, presumably with proper antiseptic precautions, with a mortality of ten cases or 47.64 per cent. Gangrene of the leg has occurred in the last twenty-one cases seven times, *i.e.* 33 $\frac{1}{3}$ per cent. Although the death-rate has been lowered by more improved methods the operation no doubt is still dangerous, chiefly owing to the risk of gangrene, and should be only employed in cases of absolute necessity.

LIGATURE OF THE SUPERIOR GLUTEAL ARTERY

Indications. This is practically only a dissecting-room operation; even then, however, it is scarcely a fair test of surgical ability, as the position in which the body lies causes the veins to become intensely congested and the soft parts to become water-logged, so that a clear view of the vessel is impossible.

At one time ligature of the vessel was done in the living subject for the cure of gluteal aneurysm, and for some cases in which the artery had ulcerated or ruptured into a gluteal abscess. Either of these conditions, however, should be treated by ligature of the internal iliac (hypogastric) artery by the trans-peritoneal method (see p. 330). No surgeon conversant with the difficulties in securing the vessel outside the pelvis would willingly face the extra-pelvic operation if he could do the comparatively easy trans-peritoneal ligature of the internal iliac (hypogastric) artery.

Anatomy. This vessel is the largest branch of the internal iliac (hypogastric) artery, and passes backwards out of the pelvis through the great sacro-sciatic foramen immediately above the pyriformis muscle, between it and the gluteus medius; the superior gluteal vein is superficial to it. The superior gluteal nerve emerges from the foramen below the artery. The artery divides into superficial and deep branches; the point of division is variable and sometimes is well inside the pelvis. The superficial branch passes directly upwards or backwards to supply the under-surface of the gluteus maximus, whilst the deeper branch accompanies the superior gluteal nerve between the gluteus medius and minimus.

The point of exit of the artery from the pelvis corresponds to the junction of the inner with the middle third of a line drawn from the

posterior superior spine of the ilium to the top of the great trochanter, when the thigh is flexed and rotated slightly inwards. Another landmark is the junction of the posterior with the middle third of a line drawn from the anterior superior to the posterior superior spine of the ilium (Morris).

Operation. The patient lies as nearly in the prone position as the exigencies of the anæsthetic allow, and is drawn to the end of the

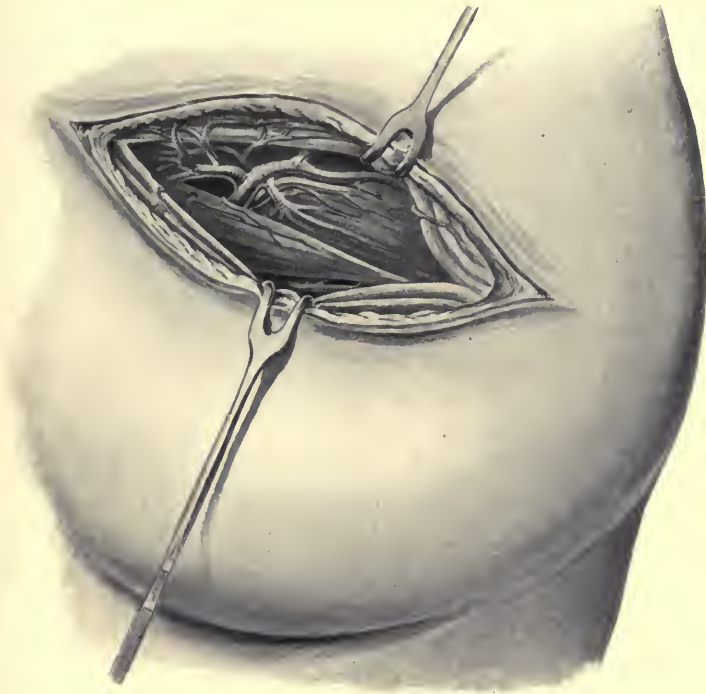


FIG. 174. THE SUPERIOR GLUTEAL ARTERY. The trunk of the vessel is seen emerging above the pyriformis and dividing into its terminal branches.

table so that the affected limb hangs over its end ; the thigh is rotated inwards. The surgeon stands on the affected side and makes an incision five inches long in the line from the posterior superior iliac spine to the great trochanter, the centre of the incision corresponding to the point of emergence of the vessel from the pelvis (*vide supra*). After the coarse skin and subcutaneous fat of the buttock have been incised, the fibres of the gluteus maximus are seen arranged in large bundles running practically in the line of the wound, and are pulled aside with broad retractors until the cellular interval between the under-surface of the

gluteus maximus and the pyriformis and gluteus medius is reached. The surgeon must be careful to ascertain when he has reached this interval, as the appearances are rather deceptive, the gluteus maximus being intersected here and there with tracts of fatty cellular tissue which may lead to the erroneous conclusion that this interval has been reached some time before the thick muscle has been traversed entirely.

After the gluteus maximus has been divided completely, the leg is placed in the horizontal position so as to relax the muscles to the utmost, and the pyriformis and gluteus medius are identified; the interval between these two muscles is opened up, the upper margin of the pyriformis and the lower border of the great sacro-sciatic notch being carefully defined. Emerging from above the upper border of the pyriformis will be seen the superficial division of the artery, together with the superior gluteal nerve, and this should be traced downwards and inwards until the trunk of the vessel is reached (see Fig. 174). This is more difficult than the description would indicate, owing to the presence of numerous veins, and the fact that the branches of the gluteal often come off on a plane almost at right angles to that of the main trunk, so that there may be most embarrassing bleeding from a wound of these branches before the main trunk is reached. The ligature should be passed as far inside the pelvis as possible, always at least under cover of the edge of the great sacro-sciatic foramen. Aneurysm needles with various curves will probably be required, and a good artificial light will be necessary, especially in fat subjects.

LIGATURE OF THE SCIATIC (INFERIOR GLUTEAL) ARTERY

Ligature of this vessel also is a mere dissecting-room exercise. In the living subject it could only be required for some perforating wound, in which case obviously the wound would be enlarged and the bleeding spot identified and secured.

Anatomy. The artery, together with the internal pudic, escapes from the pelvis through the great sacro-sciatic foramen below the pyriformis muscle, between it and the gemelli. It rests upon the obturator internus and passes behind the internal pudic artery so as to reach its outer side, and is superficial or posterior both to the great and small sciatic nerves. Its point of exit from the pelvis corresponds to the junction of the lower with the middle third of a line drawn from the posterior superior iliac spine to the outer part of the tuber ischii. The artery not infrequently comes off from the anterior division of the internal iliac (hypogastric) artery in common with the internal pudic.

Operation. The positions of the patient and the surgeon are the same as in the preceding operation. An incision four inches long is made in the direction of the fibres of the gluteus maximus, and is so placed that its centre corresponds to the point of emergence of the vessel from the pelvis (*vide supra*). The steps of the operation are very similar to those of the previous one, the fibres of the gluteus maximus being separated as before, and the lower border of the pyriformis being identified after the whole thickness of the former muscle has been traversed. The

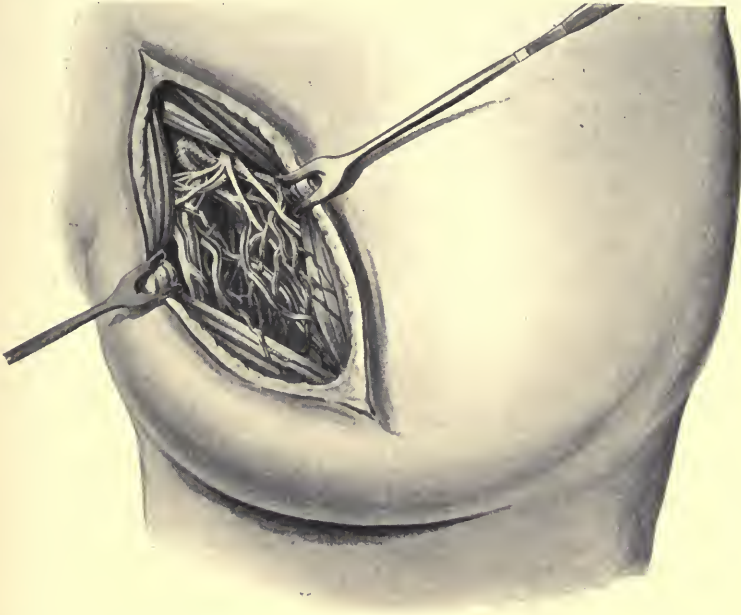


FIG. 175. THE SCIATIC AND INTERNAL PUDIC ARTERIES. Both vessels emerge beneath the lower border of the pyriformis as a single trunk. The internal pudic nerve is seen close to the left-hand retractor, which is pulling back the fibres of the gluteus maximus. The sciatic nerve breaking up into a number of branches is close to the retractor on the right-hand side.

artery is found and secured between the lower border of the pyriformis and the gemelli (see Fig. 175).

LIGATURE OF THE INTERNAL PUDIC ARTERY

Anatomy. This artery leaves the pelvis between the pyriformis and the coccygeus muscles along with the sciatic nerve. After leaving the pelvis the artery runs downwards, internal to the sciatic, over the spine of the ischium, and re-enters the pelvis through the small sacro-sciatic foramen.

The point at which this artery crosses the ischial spine corresponds to the junction of the inner with the middle third of a line drawn from the base of the coccyx to the top of the great trochanter when the femur is rotated inwards. This may help to locate the artery in cases of difficulty.

Operation. The positions of the patient and the surgeon and the incision are the same as in the preceding operation. After the lower border of the pyriformis has been defined, the ischial spine is identified and the artery is secured as it passes over it well internal to the position of the sciatic. The pudic nerve lies internal to the artery and should not be included in the ligature (see Fig. 175); the nerve to the obturator internus lies to its outer side.

The principal difficulty in the dead subject is to distinguish the artery from the sciatic, especially when the two arise from a common trunk.

CHAPTER IX

LIGATURE OF THE ABDOMINAL AORTA

ALTHOUGH no case of permanent ligature of the abdominal aorta has hitherto been successful, it cannot be said with justice that the operation is therefore removed from the sphere of practical surgery. The field for the operation must always remain very limited, and the number of those who will have the courage to apply a ligature in such an important and dangerous region will be probably even more limited still. It is possible, too, that the operation itself may undergo profound modification, and that ligature of the abdominal aorta in the true sense of the term may disappear from operative surgery within a short time, its place being taken either by the application of some form of temporary compression or by Matas's operation, a full account of which is given on p. 268.

Indications. There is practically only one indication for this formidable operation, namely, *aneurysm of the common iliac or of the aorta itself*. In *iliac aneurysm* ligature of the abdominal aorta will only be done when the aneurysm extends up along the artery as far as the bifurcation of the aorta, and Matas's operation is impracticable. With more modern methods and improved aseptic technique, aneurysm of the common iliac trunk should be amenable to less heroic measures than ligature of the aorta, as, owing to the size of the parts and their comparative accessibility in the Trendelenburg position after an abdominal section, it seems reasonable to suppose that Matas's operation should be of great value here. The large size of the vessel will render possible the 'reconstructive' suture in fusiform aneurysms that cannot be dealt with by the 'restorative' suture. Hence the great risk of ligation, viz. gangrene, may possibly be minimized.

In *aortic aneurysm* the operation must obviously take the form of proximal ligature, and therefore the point at which the ligature can be applied is determined by anatomical considerations. It will be impossible to tie the artery higher up than the root of the mesentery, which corresponds roughly to the origin of the inferior mesenteric branch. Above this the mesentery, the third portion of the duodenum, and the renal vessels effectually preclude any possibility of the application of a ligature. It is, therefore, only an aneurysm between the origin of the inferior

mesenteric artery and the bifurcation of the aorta that could be successfully treated by proximal ligation, as in this region the vessel is comparatively accessible. It would seem, however, to one who has never had the opportunity of dealing with the condition, that it should be less dangerous as well as less difficult to control the circulation on each side of the aneurysm and then to incise the sac and treat it according to the plan suggested by Matas, making a special effort to preserve the circulation at the end of the operation by the use of the 'reconstructive' suture.¹

The real difficulty, however, is not to decide which is the best method of treatment, for that will depend largely upon the conditions met with in any individual case and will probably be plainly apparent to the surgeon who has to deal with such a case; it is to say whether and when operative measures are called for in the treatment of abdominal aneurysm. Unfortunately no one possesses experience of a sufficiently large number of cases to entitle him to be dogmatic upon such an important subject. Aneurysm of the abdominal aorta between the origin of the inferior mesenteric and the bifurcation of the aorta is not of frequent occurrence. The majority of abdominal aneurysms occur at or above the origin of the cœliac axis (see Bryant, *Clinical Journal*, 1903). The prognosis is gloomy in the extreme; few patients live more than eighteen months after development of the aneurysm, and not many pass the first year. The disease is often marked by great pain, and the enforced rest practically disables the patient entirely. Surgical measures undoubtedly often prove directly fatal, and it can only very rarely be said that they are productive of any benefit at all.

The consideration of published cases leads to the conclusion that direct operative interference with the main artery, such as by ligation of the aorta or Matas's operation, will be called for in the rare cases in which

¹ Abbé (*Annals of Surgery*, 1908, vol. xlviii, p. 10) mentions his method of treatment of abdominal aneurysm published by him in the *New York Medical Journal*, 1894. This consists in clamping the aorta above and below, excising the affected area, and tying into the gap a glass tube of sufficient calibre. This was done in a cat, and four months afterwards the animal was shown with the tube healed firmly in her aorta. The blood flowed through it for days until the tube excited endarteritis. He makes a valuable suggestion that in cases of aneurysm of the aorta it may be possible to open the abdomen, clamp the aorta above and below, incise the sac, fasten in a glass tube through the aneurysmal cavity, and then to bring the aneurysmal wall together by Matas's method over the tube. It is undoubtedly a suggestion worth considering, the object being to secure gradual obliteration of the aorta and thus to give time for the collateral circulation to become established. It is, however, probable that Matas's 'reconstructive' suture (see p. 274) would serve the same purpose without the necessity of having to sew into the aorta a foreign body that was to remain *in situ* indefinitely.

the disease is diagnosed early and the tumour is small and circumscribed. Early resort to exploratory laparotomy for an obscure tumour of the abdomen may lead to this happy result, and under these circumstances better results may be hoped for from direct surgical interference in the future than has been the case in the past. On the other hand, the less directly operative procedures, such as Macewen's acupuncture treatment, or the introduction of wire into the sac, should be reserved for the cases in which the aneurysm has reached such a size that its boundaries are no longer clear and it has become so matted to surrounding parts that direct interference with the main artery would be difficult and even hazardous. If either of the methods referred to be employed, they should be practised after a laparotomy has been done to expose the wall of the sac so that the needles or the trocar and canula can be thrust through some safe spot where it is certain they will not transfix the intestinal wall or any important blood-vessel. Both Macewen's acupuncture and the method of introducing wire into the sac are dealt with in connexion with aortic aneurysm, for which they are more frequently used.

The other surgical affection that usually demands ligature of a vessel, namely *hæmorrhage*, does not call for the application of a ligature in the case of the aorta. Wounds of the aorta must necessarily be rare, and the vast majority from their very nature must prove fatal before any surgical measures can become available. There are, however, a few cases which may be satisfactorily treated. These will be small wounds and will chiefly occur in the course of operations; for example, the renal artery may be torn from the aorta at its origin. Should such a case occur, it could be dealt with satisfactorily by arteriorrhaphy. The circulation through the aorta is commanded on either side of the wound, which is then sutured in the appropriate manner (see p. 263). This treatment has the advantage that it is not only simpler but it preserves the lumen of the artery intact, and should therefore not be accompanied by any grave danger to life.

Operation. Two methods are always described, namely, the extra-peritoneal and the trans-peritoneal methods. In the present state of operative surgery it would seem to be a mere waste of time to describe the extra-peritoneal method, which, however excellent a purpose it may have served in the past, is barbarous and unscientific when compared with the trans-peritoneal operation.

The patient should undergo a preliminary treatment for a week or more destined to evacuate the bowels thoroughly and to keep them empty, as distended intestines are a most fruitful source of inconvenience during the operation; the rest of the preparation is the same

as for an ordinary laparotomy. The incision is made one inch to the left of the middle line downwards for nearly five or six inches from a point three inches above the umbilicus. The anterior sheath of the rectus is divided in the line of the incision and the inner border of that muscle is defined and pulled outwards and then the posterior sheath of the rectus and the peritoneum are opened. The patient is now put in the Trendelenburg position and the intestines are packed up out of

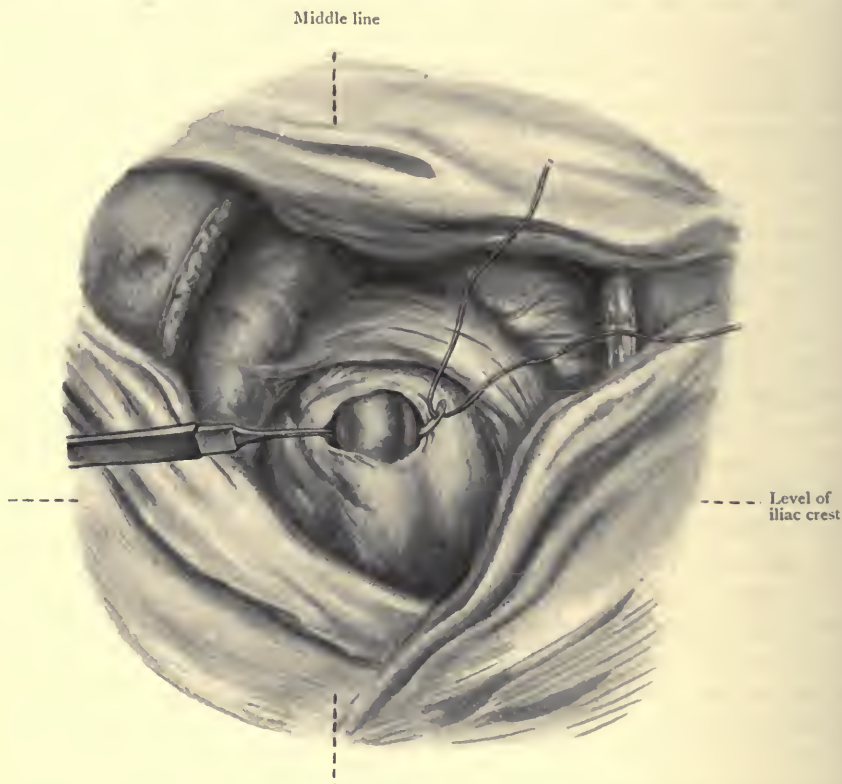


FIG. 176. LIGATURE OF THE ABDOMINAL AORTA. The vessel is secured just above its bifurcation and below the origin of the inferior mesenteric artery.

the way with suitable sterilized cloths. Particular care must be taken to see that the small intestine is thrown well up into the upper part of the abdomen; the sigmoid flexure can be allowed to fall into the pelvis out of the way, if necessary. The artery and the aneurysm will be thus rendered visible. The operator defines the vessel above the sac, and, whatever he intends to do subsequently, proceeds to clear the vessel for the application of a ligature. The peritoneum and the sheath of the vessel should be opened separately with great care

as far over to the left side as possible, and the most difficult step of the operation, namely the clearing of the artery, is then undertaken. It is most important to avoid including the aortic plexus of the sympathetic in the ligature. The clearing of the vessel must be done with the greatest care and several directors or aneurysm needles with suitable curves must be at hand.

When the vessel has been cleared satisfactorily the surgeon applies either a permanent or a temporary ligature (see Fig. 176) according as he is going to make use of ligation in continuity or Matas's operation. In the former case the ligature should certainly consist of two, or preferably of four, strands of soft material, such as floss silk or even kangaroo tendon, each ligature being drawn tight in regular order so that the first will break the force of the circulation and allow the second and subsequent ones, which are applied on the distal side of the first, to approximate the wall of the vessel sufficiently to control the circulation through it. On no account should sufficient force be exerted to rupture the inner coats, and it will be well to make use of the 'stay-knot' advocated by Ballance and Edmunds (see p. 289). If four ligatures are used it is a good plan to group the ligatures into two sets, tying the second loop of each knot with two ligatures on either side (see Fig. 151). The incision into the peritoneum is sutured, the abdominal cavity is closed in the usual way, and the patient kept in the Trendelenburg position until he is put back in bed. Every precaution must be taken against shock before, during, and after the operation. After the operation the extremities must be wrapped up in cotton wool and kept elevated on pillows and by raising the foot of the bed on blocks.

LIGATURE OF THE ARTERIES OF THE UPPER EXTREMITY

CHAPTER X

LIGATURE OF THE ARTERIES OF THE HAND AND FOREARM

LIGATURE OF THE RADIAL ARTERY

Indications. (i) *Wounds.* These are frequently met with in any part of the vessel. The best plan is to cut down directly upon the bleeding spot in the line of the vessel, making use of the original wound, and to secure the cut ends with ligatures.

(ii) *Aneurysms.* These may be either of the traumatic—chiefly met with about the wrist—or the arterio-venous variety; the latter used to be frequently met with about the bend of the elbow in the days when venesection was in vogue, and generally affected the brachial trunk. Aneurysms of the radial artery are not likely to be too large to prevent them from being excised completely after the circulation in the limb has been commanded by an Esmarch bandage.

(iii) *Wounds of the palmar arch.* In order to check bleeding from this cause, the radial and the ulnar arteries have been ligatured simultaneously just above the wrist when the wounded vessel could not be found after enlarging the incision in the palm. It is hardly likely that this treatment would be followed at the present day however. The circulation in the limb should be controlled, the wound enlarged, and the bleeding points secured. In neglected septic cases, however, the artery may have to be tied if secondary hæmorrhage sets in. Most surgeons, however, prefer to tie the brachial artery at the bend of the elbow if they cannot secure the bleeding points.

Surgical anatomy. The radial artery is the smaller of the two terminal divisions of the brachial, and is a direct continuation of it. It extends from the middle of the front of the elbow to the back of the first interosseous space, where it dips down to join the deep branch of the ulnar artery. Its anatomical line is drawn from the centre of the front of the bend of the elbow to the line of the pulse, namely, just external to the tendon of the flexor carpi radialis (see Fig. 177).

In the forearm the artery lies in succession upon the tendon of the biceps, the supinator (brevis), the pronator teres, the radial portion of the flexor digitorum sublimis, the flexor pollicis longus, the pronator quadratus, and the anterior ligament of the wrist-joint. It is overlapped in the upper part of its course by the anterior margin of the supinator longus (brachio-radialis), but lower down it becomes subcutaneous. On its outer side is the supinator longus (brachio-radialis) or its tendon throughout, and the radial nerve in the middle third; elsewhere in its course the nerve is not in relation with the artery. On



FIG. 177. INCISIONS FOR THE RADIAL AND ULNAR ARTERIES ON THE FRONT OF THE FOREARM. The three upper incisions are those for the radial artery, and the upper pair of dots are placed respectively on the centre of the ante-cubital fossa and the pulse at the wrist. The lower two incisions are for ligature of the ulnar artery, the lower pair of dots being placed, one upon the tip of the internal condyle and the other upon the pisiform bone. The + is at the junction of the upper with the middle third of this line and corresponds to the point at which the ulnar artery joins it. The upper third of the ulnar artery is denoted by a line between the upper right-hand dot and the + with a slight convexity towards the inner side of the forearm.

the inner side lies the pronator teres, with the flexor carpi radialis below. There are two venæ comites, one on each side of the artery.

In its course from the front of the forearm to the back of the wrist, the radial artery lies upon the external lateral (radial) ligament of the wrist-joint, the scaphoid (navicular), the trapezium (great multangular), and the base of the first metacarpal. Superficial to it are the tendons of the extensor ossis metacarpi pollicis (abductor pollicis longus), the extensor pollicis brevis, and the extensor pollicis longus. Above this is the fascia, in which are branches of the radial nerve and the commencement of the radial vein. The line of this part of the vessel is from the tip of the styloid process to the upper end of the first metacarpal space (see Fig. 181).

The artery may be tied in its upper, middle, or lower thirds. It is

also sometimes tied at the back of the wrist in what is known as the 'anatomical snuff-box'; this, however, is only a dissecting-room exercise.

LIGATURE IN THE UPPER THIRD OF THE FOREARM

The arm is fully supinated and supported at right angles to the trunk upon a suitable table or rest ; the surgeon stands on the outer side of

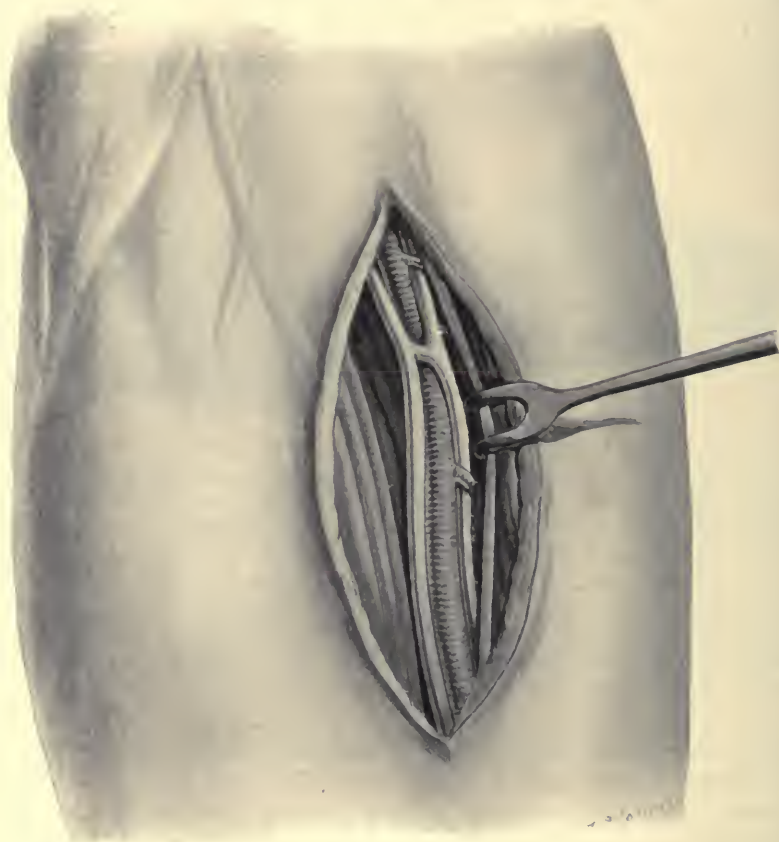

FIG. 178. THE RADIAL ARTERY IN THE UPPER THIRD OF THE FOREARM. The hook pulls back the supinator longus (brachio-radialis) and the superficial radial vein. The muscle on the inner side of the artery is the pronator (radii) teres. The radial nerve is not seen.

the limb. An incision two and a half inches long is made along the line of the artery (*vide supra*) in the upper third of the forearm. A few branches of the radial vein are divided, and the deep fascia is opened up throughout the length of the wound. The interval between the supinator longus (brachio-radialis) externally and the pronator teres internally is

then sought for. The situation of this interval is very variable, and depends upon the muscular development of the limb; it is best found by noting the direction of the muscular fibres, those from the supinator longus (brachio-radialis) passing directly down the forearm, whilst those of the pronator pass from the internal condyle obliquely downwards and outwards to the radial side. When the interval has been found, the inner margin of the supinator longus (brachio-radialis) is defined,

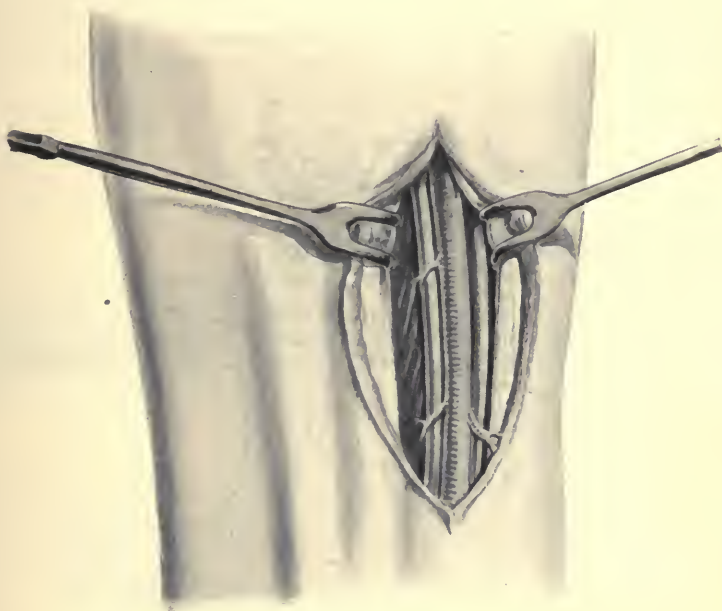

FIG. 179. THE RADIAL ARTERY IN THE MIDDLE THIRD OF THE FOREARM. The right-hand retractor is pulling back the supinator longus (brachio-radialis), immediately internal to which is seen the radial nerve on the outer side of the artery, approaching it somewhat obliquely from above. The artery is seen with its venæ comites on its inner side lying upon the insertion of the pronator (radii) teres.

first by a few touches of the point of the knife and then by its handle, and the muscle is pulled outwards with a retractor and the artery is seen lying beneath it (Fig. 178). In a muscular limb the wrist and elbow joints will need to be flexed in order to facilitate retraction of the muscle and access to the artery. The venæ comites are separated from the artery if possible, but, if necessary, may be taken up in the ligature; the latter is usually passed from without inwards.

LIGATURE IN THE MIDDLE THIRD OF THE FOREARM

The positions of the limb and the operator are the same as before. The incision should be two inches long, in the line of the artery (see p. 344), and its centre should correspond to the middle of the forearm. After the deep fascia has been opened up, the inner margin of the supinator longus (brachio-radialis) is defined as before, and drawn well outwards with a retractor. The artery lies upon the insertion of the pronator teres, and is bound down to it by a special fascia. The

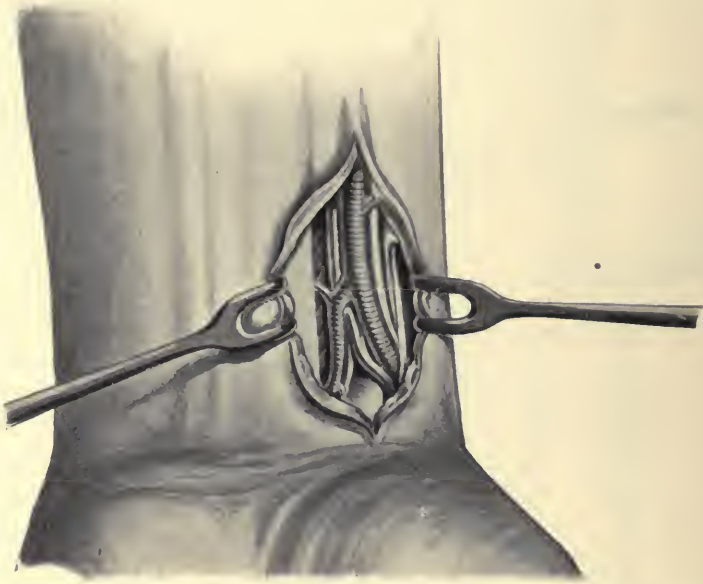


FIG. 180. THE RADIAL ARTERY AT THE WRIST. The artery, with the superficialis volæ arising from it, is seen between its venæ comites.

(superficial) radial nerve lies close to its outer side (see Fig. 179), and the needle should therefore be passed from the outer side.

LIGATURE IN THE LOWER THIRD OF THE FOREARM

Here the vessel is only covered by the skin and superficial fascia, while some of the branches of the superficial radial vein and a few cutaneous nerves lie over it.

The position of the limb is the same as before (see p. 346), and the surgeon makes an incision half an inch long in the line of the artery (see p. 344), just external to the tendon of the flexor carpi radialis. Care must be taken in making this incision to go very lightly through the skin, as the fascia is thin, and the radial artery may be wounded at the

first cut if too much force be used. When the deep fascia is reached it is incised, and the artery at once comes into view with its venæ comites (see Fig. 180); these are separated and the vessel is secured. The (superficial) radial nerve does not come into relation with the artery, having turned beneath the supinator longus (brachio-radialis) to the back of the wrist.

LIGATURE IN THE 'ANATOMICAL SNUFF-BOX'

This is a dissecting-room operation. The hand rests upon its ulnar border, and the thumb is held by an assistant in a position of full abduc-

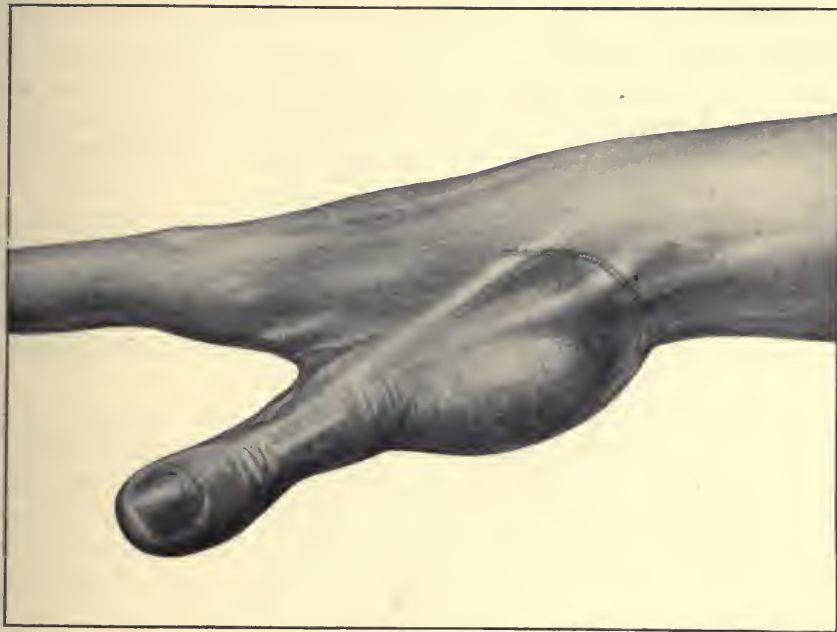

FIG. 181. THE LINE OF THE RADIAL ARTERY IN THE 'ANATOMICAL SNUFF-BOX'. The tendons of the extensors of the wrist are well shown. A dot is placed upon the styloid process of the radius.

tion. If the outline of the tendons can be made out, an incision three-quarters of an inch in length is made parallel to and to the radial side of the extensor secundi internodii pollicis (extensor pollicis brevis) tendon, avoiding, if possible, the large branch of the superficial radial vein which crosses the snuff-box somewhat obliquely. The incision is deepened until the deep fascia is reached, and this is divided throughout the full length of the wound without opening the tendon sheaths; they should be pulled apart with blunt hooks while the vessel is sought for. The artery lies in some fatty tissue close upon the wrist-joint and

surrounded by its venæ comites ; it should be secured just before it reaches the upper end of the first metacarpal space.

If the outlines of the tendons cannot be made out, as may be the case in the dead subject, a simple plan is to make an incision along the line of the artery from the styloid process of the radius to the upper end of the first metacarpal space (see Fig. 181). This incision is parallel to the vessel throughout, whereas the previous incision crosses it at an angle. The steps of the operation are the same as above.

LIGATURE OF THE ULNAR ARTERY

Indications. Similar to those for the radial artery (see p. 344).

Surgical Anatomy. The ulnar artery is the larger of the two branches into which the brachial divides, and it extends from the mid-point of the ante-cubital fossa on the front of the elbow, opposite the neck of the radius, to the palm of the hand, where it forms the superficial palmar arch.

The course of the lower two-thirds of the artery is indicated by a line drawn from the back of the internal condyle of the humerus to the radial side of the pisiform bone. The upper third of the vessel is indicated by a curved line with its convexity to the inner or ulnar side, extending from the mid-point of the ante-cubital fossa to the junction of the middle with the upper third of the first line (see Fig. 177).

Posteriorly the artery rests from above downwards upon the lower part of the brachialis (anticus), the flexor digitorum profundus, and the deep part of the anterior annular (transverse carpal) ligament. *Anteriorly* it is crossed by the pronator teres, the median nerve—which is separated from the artery by the deep head of the pronator—the flexor digitorum sublimis, the flexor carpi radialis, and the palmaris longus. In the middle third of the forearm it is overlapped by the anterior border of the flexor carpi ulnaris, and lower down still it becomes subcutaneous. *Laterally* it is accompanied by venæ comites ; and on the ulnar or inner side lie the ulnar nerve and the flexor carpi ulnaris in the lower two-thirds. On the radial side the flexor digitorum sublimis is found in its lower two-thirds.

The artery is usually tied either just above the wrist or in the middle of the forearm. It can be reached in its upper third, but here it is very deeply placed, and it would only be exposed for a wound of the vessel, in which case the existing wound would be enlarged.

LIGATURE IN THE LOWER THIRD OF THE FOREARM

The limb is fully supinated and rests on a suitable support. An incision half an inch long is made along the line of the artery (*vide supra*)

through the skin and deep fascia ; this should extend down to within a quarter of an inch of the pisiform bone, and should lie just to the radial border of the flexor carpi ulnaris tendon. When the deep fascia has been opened, the artery comes into view, with the nerve on its inner or ulnar side (see Fig. 182). The needle should be passed from the nerve, viz. from the inner side.

LIGATURE IN THE MIDDLE OF THE FOREARM

The position of the limb is the same as before, and an incision is made three to four inches in length with its centre opposite the middle of the forearm along the line of the artery (see p. 350). The deep fascia

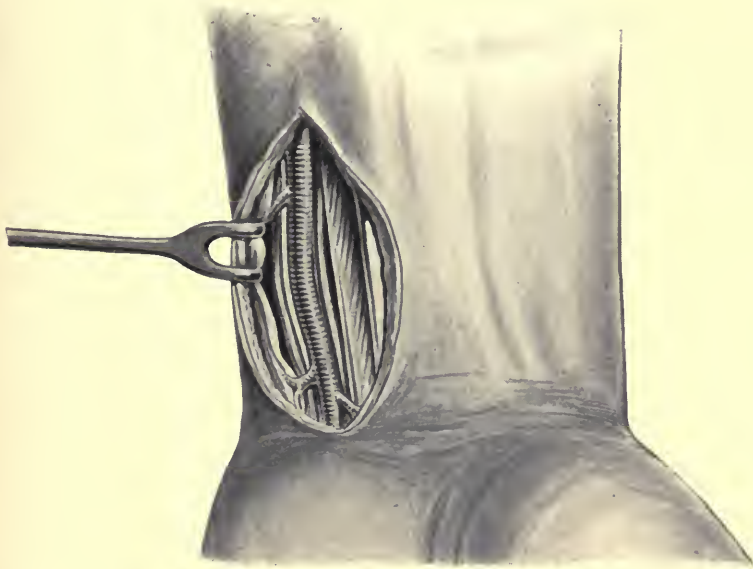


FIG. 182. THE ULNAR ARTERY AT THE WRIST. The tendon of the flexor carpi ulnaris is hooked back, and the artery is seen lying on the flexor sublimis. The nerve is to its inner side over the internal vena comes.

is opened throughout the whole length of the wound, and the radial border of the flexor carpi ulnaris is sought for. There is often a well-marked intermuscular septum between this muscle and the flexor digitorum sublimis which may contain a considerable quantity of fat. Into this septum the handle of the knife is sunk, and the flexor carpi ulnaris is pulled gently to the inner side. As this is done, the elbow and the wrist should be flexed in order to enable the muscle to be drawn well back with retractors. The artery, with the nerve on its inner side, is then disclosed lying beneath the flexor carpi ulnaris (see Fig. 183). It

is cleared, and the needle is passed from the inner side. The nerve is generally seen first and forms the guide to the artery.

Difficulties and dangers. This operation is often difficult, especially in the dead subject, where the pulsation of the artery cannot be felt. The chief difficulty lies in identifying the outer border of the flexor carpi ulnaris, and the intermuscular septum between it and the flexor digitorum sublimis. In a well-developed muscular subject this septum may be some distance outside the line of the artery, and this

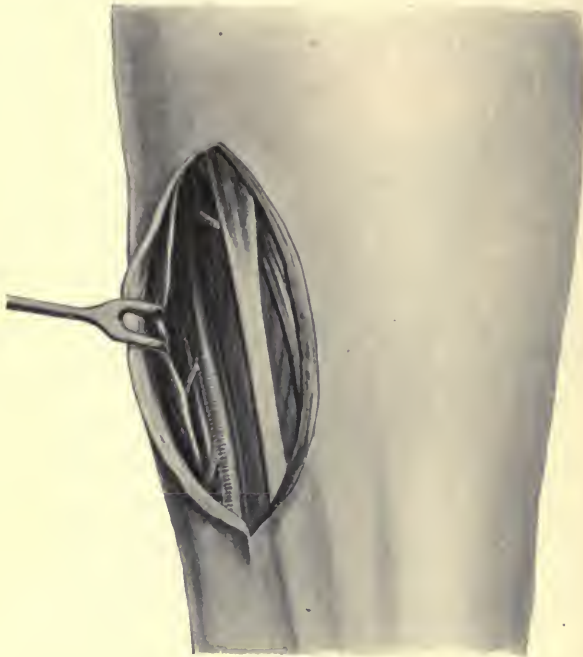


FIG. 183. THE ULNAR ARTERY IN THE MIDDLE OF THE FOREARM. The artery lies deeply under the flexor carpi ulnaris with the nerve to its inner side.

fact must be remembered. The most useful guide to the position of the septum will be found in the presence of small intermuscular vessels which are always found in it, and which, when followed up, will lead to its identification and to the artery. The septum usually mistaken for the one in question is that between the flexor carpi ulnaris and the extensor muscles. This mistake is only likely to happen when the line of the artery has been taken incorrectly, and the incision made too far to the ulnar side of the forearm. If, on the other hand, the incision be made too far to the radial side of the artery, the septum between the palmaris longus and the flexor sublimis may be mistaken for the one in question.

LIGATURE IN THE UPPER THIRD

This, as already said, is not a recognized operation, as the first part of the artery is too deeply placed to be easily accessible ; as a rule it is only undertaken for a wound of the vessel, when it suffices to enlarge the wound and to find the seat of the injury. The operation is, however, sometimes set at examinations, and it will then be found easy to secure the vessel through a vertical incision about three inches long, slightly to the ulnar side of the middle line, and having its centre just above the upper or outer border of the pronator teres, which may be indicated roughly by a line drawn from the internal condyle to the middle of the radius. When the deep fascia has been divided, the upper border of the pronator is defined and pulled downwards with a retractor ; it is easy to identify this muscle from the direction of its fibres, which run downwards and to the radial side. By a little dissection, the bifurcation of the brachial artery is exposed, and the ulnar artery is then traced downwards to the point at which it is desired to apply the ligature. If there be any doubt, the median nerve, which crosses the ulnar artery, will form a useful guide.

CHAPTER XI

LIGATURE OF THE ARTERIES OF THE UPPER ARM AND AXILLA

LIGATURE OF THE BRACHIAL ARTERY

Indications. (i) *Wounds of the artery.* In these cases the wound will be enlarged and the divided ends secured by ligature.

(ii) *Wounds of the palmar arch.* If the bleeding be persistent and cannot be stopped by the application of firm pressure, ligature of the brachial artery may be necessary. This operation is more satisfactory than ligature of the radial and ulnar arteries separately, owing to the free anastomosis about the wrist ; the artery should be tied at the bend of the elbow. It will probably only be in cases of secondary hæmorrhage from a septic wound that this will be required. In a recent wound the parts would be made aseptic, the circulation controlled by an Esmarch bandage, the wound enlarged and the bleeding points identified and secured.

(iii) *Aneurysm* either traumatic or spontaneous will call for ligature of the vessel, but this affection is not common nowadays. Formerly an arterio-venous aneurysm at the bend of the elbow was a common sequela of venesection.

Surgical anatomy. The brachial is the direct continuation of the axillary artery, and extends from the lower border of the teres major to the middle of the ante-cubital fossa.

Anteriorly it is overlapped by the inner margin of the biceps, and is crossed about its centre by the median nerve, which passes from its outer to its inner side. The median (basilic) vein lies immediately over the artery at the bend of the elbow, being separated from it only by the deep fascia and the bicipital fascia (lacertus fibrosus of the biceps).

Posteriorly it lies upon the front of the long head of the triceps, upon the internal head of the same muscle, and, lower down, upon the insertion of the coraco-brachialis and the origin of the brachialis (anticus) muscles.

The musculo-spiral (radial) nerve and the (superior) profunda artery separate it above from the outer head of the triceps. *To its outer side* lie the coraco-brachialis and the median nerve above and the triceps below ; *to its inner side* lie the median nerve below, and the basilic vein,

the internal (medial antebrachial) cutaneous, the lesser internal (medial brachial) cutaneous, and the ulnar nerves above. It has two venæ comites.

The course of the artery is denoted by a line drawn from the junction of the upper with the middle third of a perpendicular let fall from the anterior to the posterior fold of the axilla, down to the centre of the ante-cubital fossa. In practice the line made use of is that corresponding



FIG. 184. INCISION FOR LIGATURE OF THE BRACHIAL ARTERY IN THE MIDDLE OF THE ARM. The elbow is supported by an assistant, so that the triceps shall hang free.

to the inner edge of the biceps muscle, which can always be seen even in fat subjects.

The artery is tied either in the centre of the arm or in front of the bend of the elbow.

LIGATURE IN THE MIDDLE OF THE ARM

An assistant holds the arm horizontal and at right angles to the trunk (see Fig. 184). The limb may be supported in that position by resting the

tip of the olecranon on a sand-bag, but under no circumstances should the arm rest with the triceps flat upon a board or upon the table. The surgeon, who will find it most convenient to sit upon a stool between the trunk and the limb, makes an incision two and a half inches long in the line of the artery and over the inner border of the biceps muscle; the basilic vein must be avoided should it lie beneath the incision. The deep fascia is incised throughout the length of the wound and the

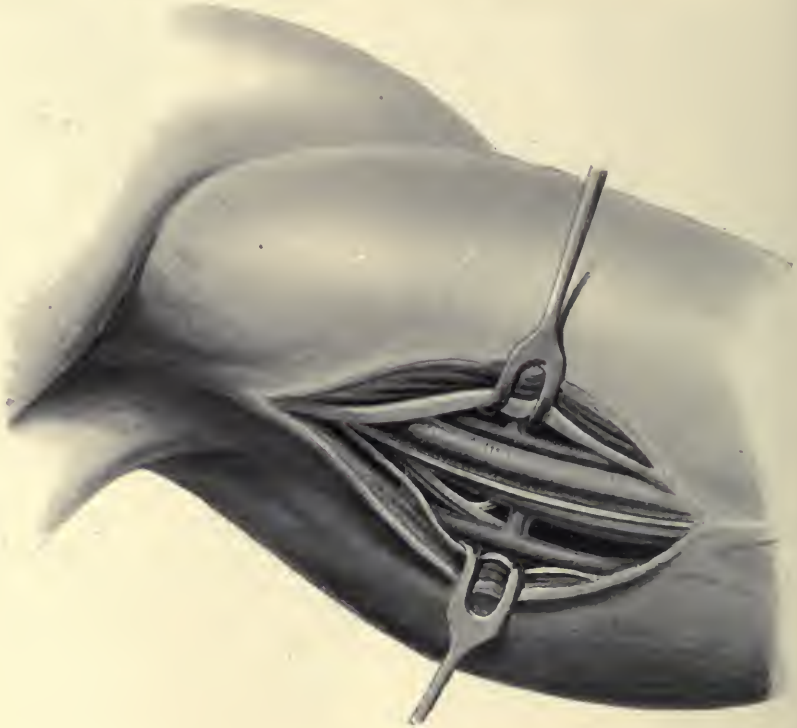


FIG. 185. THE BRACHIAL ARTERY IN THE MIDDLE OF THE ARM. The median nerve is hooked up, and the triceps, with the lesser internal (medial brachial) cutaneous nerve, is hooked downwards. Just below the artery is the internal (medial antebrachial) cutaneous nerve.

inner border of the biceps is defined and drawn outwards and upwards. The finger inserted into the wound will feel the pulsation of the artery in the living subject, or the hard rounded cord formed by the median nerve in the cadaver. The latter structure is defined by a few touches of the knife and raised in a hook. If the artery be exposed exactly at the centre of the limb, the median nerve will be crossing in front of it, while above this it will be to its outer and below it to its inner side.

As long as the incision is not below the centre of the limb, it is best to draw the median nerve outwards or upwards in a retractor ; if the artery has been exposed below the centre of the arm the nerve should be pulled inwards. The artery is thereby exposed with its venæ comites, of which the lower or inner one is generally larger than its fellow (see Fig. 185). The artery is separated from the veins, its sheath is opened and the needle is passed from without inwards.

Difficulties and dangers. Although this artery can generally

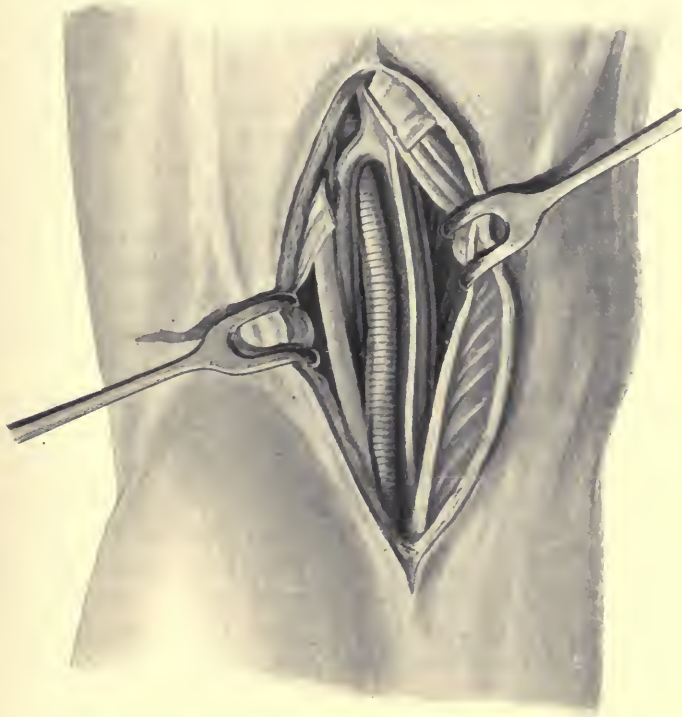


FIG. 186. THE BRACHIAL ARTERY AT THE BEND OF THE ELBOW. The bicipital fascia has been divided above, exposing the artery and its venæ comites. On its inner (left-hand) side is the large median nerve.

be felt through the skin before the operation, even in the dead subject, it is remarkable how many mistakes are made when it is cut down upon, especially in the dead subject. Even in the living subject the operation may be difficult owing to feeble pulsation of the vessel. The most important point in operating is to keep to the proper line of the vessel, namely, the inner border of the biceps muscle. For this reason it is most important that the triceps should hang free ; if it be displaced

upwards, the incision will be too far downwards or inwards, and the basilic vein will probably be wounded and the ulnar nerve exposed and mistaken for the median. The chief aid to successful operation is finding the median nerve; when this has been done, the brachial artery can be identified and tied without disturbing the surrounding structures, but if these latter be dissected out separately the operator soon becomes confused and fails to identify them. Another source of confusion is that the brachial artery is frequently abnormal in its distribution.

LIGATURE AT THE BEND OF THE ELBOW

The limb is abducted and the forearm is supinated and steadied upon a suitable sand-bag or rest. The elbow should not be too fully extended; if it is, the artery may be wounded in making the skin incision, as it lies close to the surface and becomes unduly prominent when the elbow is over-extended. The surgeon stands on the outer side of the limb, and feels for the inner border of the biceps tendon. He also should render the median basilic vein prominent by compressing it above, so that it may not be cut in making the skin incision, which should be about one and a half inches long and parallel to and over the inner border of the biceps tendon; its upper extremity should be on the level of the tip of the internal condyle. When properly planned this incision will be parallel to the median basilic vein and to its outer side. The thin fascia in the front of the elbow is divided throughout the length of the wound, and then the bicipital fascia (lacertus fibrosus of the biceps), which may be recognized by its curved fibres running downwards and inwards, is divided fully. This exposes the brachial artery and its venæ comites (see Fig. 186); as a rule no other structure comes into view. The median nerve lies nearly half an inch to its inner side, and is not actually in relation with the vessel. The artery should be separated from its venæ comites and the needle passed from the inner side.

LIGATURE OF THE AXILLARY ARTERY

Indications. (i) *Wounds of the artery.* These are not uncommon; punctured wounds are often met with both in civil and military practice.

(ii) *Brachial aneurysm* situated too near to the commencement of the brachial artery to allow that vessel to be tied.

(iii) *Subclavian aneurysm.* Ligature of the axillary is occasionally done as the distal operation for an aneurysm of the subclavian artery in which it is impossible to apply a ligature on the proximal side.

(iv) Occasionally the axillary artery has to be ligatured *during removal of malignant glands* from the axilla, either because the vessel is accidentally wounded or because the sheath of the artery is invaded by the growth.

(v) Very rarely ligature may be required for *rupture of the axillary artery* following attempts to reduce a long-standing dislocation of the shoulder.

(vi) Ligature of the axillary forms part of *the old operation for axillary aneurysm*, by incision and evacuation of the contents of the sac.

Surgical anatomy. The axillary artery extends from the lower border of the first rib to the lower border of the teres major. It is usually divided into three parts; as a rule a ligature is only applied to the first and third parts.

The line of the artery is from the middle of the clavicle to the junction of the upper with the middle third of a perpendicular let fall from the anterior to the posterior fold of the axilla when the arm is abducted to a right angle with the trunk. It should be remembered that the line of the vessel varies with the position of the arm and, in particular, the relation of the vein to the artery is modified thereby. Thus, when the arm is drawn down to the side, the vein lies to the inner side of and somewhat below the artery, but when the arm is at right angles to the trunk or when it is raised above the head, the artery is completely hidden by the vein, which then lies in front of it. The vein varies greatly in size with respiration.

It is worth noting that the upper border of the pectoralis minor is on a level with the outer border of the first rib and that therefore, strictly speaking, no part of the artery is above this muscle. The distinction, however, is convenient as indicating that the artery is accessible both above and below this structure.

Relations of the first part of the artery. *Behind*, the vessel lies upon the first digitation of the serratus magnus (anterior) muscle, the first intercostal space with its contents, and the posterior or long thoracic nerve.

In the front are the costo-coracoid membrane (coraco-clavicular fascia), which separates the artery from the cephalic vein, and the external anterior thoracic nerve and the acromio-thoracic (thoraco-acromial) vessels. Superficial to these are the clavicular fibres of the pectoralis major, the deep fascia, platysma, and the descending clavicular branches of the cervical plexus.

Above, and to the outer side, are the cords of the brachial plexus.

Below, and to the inner side, are the axillary vein and the internal anterior thoracic nerve.

Relations of the third part of the artery. *Behind*, the vessel lies upon the lower border of the subscapularis, the latissimus dorsi and the teres major muscles. The circumflex (axillary) and the musculo-spiral (radial) nerves pass behind this part of the vessel.

In front, the artery is crossed by the inner head of the median nerve,

and above it is covered by the pectoralis major muscle, the lower portion being covered only by the skin and fascia of the axilla.

To the outer side are the median and the musculo-cutaneous nerves, and the coraco-brachialis muscle.

To the inner side lies the axillary vein, but between this structure and the artery there intervene the ulnar nerve in the angle behind, and the internal cutaneous (medial antebrachial) nerve in the angle in front. The lesser internal (brachial) cutaneous nerve lies internal to the vein. The brachial venæ comites unite to form the axillary vein at the lower border of the subscapularis muscle.

LIGATURE OF THE FIRST PART

This operation is of the greatest rarity in the living subject, and the depth at which the artery is situated and the proximity of a number of important branches render it very difficult and dangerous. The surgeon would therefore always ligature the third part of the subclavian in preference to the first part of the axillary if he has the choice. It is, however, a favourite examination operation upon the dead subject.

The operation may be done in three ways: (i) Through a curved incision below the clavicle. (ii) Through one directly over the line of the artery. (iii) Through the interval between the deltoid and the clavicular fibres of the pectoralis major. Of these methods the first is probably the best, as it gives ample room and only involves division of some of the fibres of the pectoralis major. Operations upon the breast amply demonstrate that so small a damage as this to the pectoralis major is of no material consequence. This method is the only one that will be described; the others are distinctly inferior to it, inasmuch as they do not furnish such easy access to the vessel.

Operation. The thorax is slightly raised on a pillow and the arm is abducted almost to a right angle with the trunk in order to put the fibres of the pectoralis major on the stretch. The surgeon stands between the body and the limb, and makes an incision extending from the junction of the middle with the inner third of the clavicle to a point just outside the coracoid process. This incision should have a gentle convexity downwards. It is usually recommended that the incision should extend from the sterno-clavicular articulation, but this is unnecessary except in very fat people or cases in which there is much œdema, as most of the operation is performed at the outer end of the wound, and such a long incision is unnecessary. The skin, superficial fascia and platysma, with the supra-clavicular branches of the cervical plexus, are divided. The next step is to cut through the clavicular fibres of the pectoralis major exposed in the wound a finger's breadth below the

clavicle ; this will leave enough muscular fibre to allow of the cut surfaces being brought together at the end of the operation. Damage to the cephalic vein at the outer end of the wound must be avoided, and the acromio-thoracic vessels, which serve as useful guides to the artery, should not be injured ; the wound is deepened at the outer end of the incision with great care, until the situation of these structures is evident.

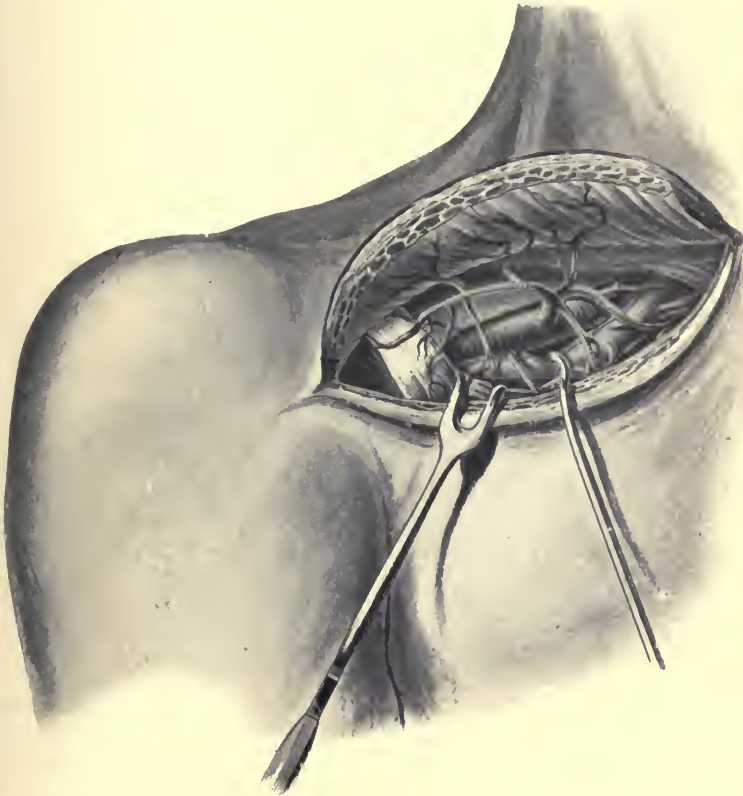


FIG. 187. THE FIRST PART OF THE AXILLARY ARTERY. The vessel has been exposed by the incision described in the text. The retractor pulls down the pectoralis minor and the blunt hook depresses the vein and exposes the artery.

When all hæmorrhage has been stopped, the loose cellular tissue beneath the pectoralis major is opened up, and the upper or inner border of the pectoralis minor is defined and pulled downwards with a broad retractor. This exposes the costo-coracoid membrane (coraco-clavicular fascia), which should be divided by a horizontal incision near the coracoid process ; the axillary vein which bulges up into the wound with the

movements of respiration must be carefully avoided in doing this. At this stage of the operation it will be well to bring the arm to the side and pull down the shoulder firmly; this draws the vein away from the front of the artery and improves the view.

The operator is now working near the base of the coracoid process, and will find it advisable to use an electric forehead-lamp or a suitable head-mirror. Large reflecting retractors should be inserted into the wound, which requires frequent sponging, as there is often trouble-

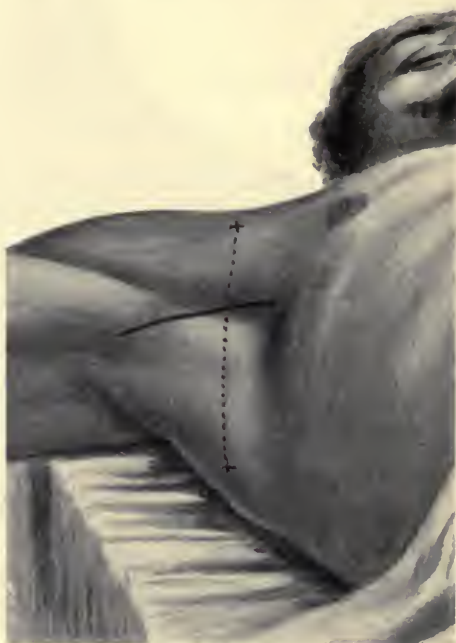

FIG. 188. INCISION FOR LIGATURE OF THE THIRD PART OF THE AXILLARY ARTERY. The upper + is on the margin of the anterior fold of the axilla, the lower one on the posterior fold.

some oozing from numerous small vessels; adrenalin solution (1 in 1,000) dropped into the wound will be helpful in checking this. The finger introduced into the wound feels the artery pulsating, and the vein can be seen expanding and contracting with respiration and hiding the artery. Above, and to the outer side of the artery, and somewhat superficial to it, lie the thick cords of the brachial plexus, which can hardly be mistaken even in the dead subject (see Fig. 187). The vein and the plexus are both more superficial than the artery, and together hide it completely. The vein is therefore pushed gently downwards with a blunt spatula, whilst the brachial plexus is pulled

upwards with a blunt hook. The sheath of the artery is then opened, and the needle insinuated round the vessel. This is often very difficult, as the artery is deep down at the bottom of the wound; aneurysm needles with varying curves should be at hand, and it is very useful to have a flexible one which can be bent to any desired curve. The needle is best passed from below upwards, *i. e.* between the artery and



FIG. 189. THE THIRD PART OF THE AXILLARY ARTERY. The median nerve and its two heads are seen, also the internal (medial antebrachial) cutaneous nerve between the artery and vein. The ulnar nerve is not seen.

the vein, as the latter structure is difficult to keep out of the way otherwise, whilst the brachial plexus can be protected from injury by the tip of the finger or a fine spatula. The acromio-thoracic (thoraco-acromial) artery must be preserved from injury throughout the operation.

LIGATURE OF THE THIRD PART

This operation is similar to ligature of the brachial artery; indeed, at examinations the ligature is often applied to the upper part of the brachial in mistake for the third part of the axillary. The positions of the limb and of the surgeon are the same as for ligature of the brachial

(see p. 355). A horizontal incision about three inches long is made along the line of the artery at the junction of the upper with the middle third of the perpendicular let fall from the anterior to the posterior fold of the axilla ; this corresponds to the inner border of the coraco-brachialis muscle (see Fig. 188). After the deep fascia has been divided, the inner edge of the coraco-brachialis muscle is identified and drawn upwards along with the musculo-cutaneous nerve. The artery should now be felt at once with the median nerve on its outer side ; the latter structure should be drawn upwards with a blunt hook. The vein is seen in front of and below the artery, and is gently drawn down with another hook, when the ulnar nerve will be seen between the two (see Fig. 189). The needle is then passed round the artery generally from below upwards.

CHAPTER XII

LIGATURE OF THE ARTERIES OF THE NECK

LIGATURE OF THE INNOMINATE ARTERY

THIS operation is fraught with considerable danger, although hitherto the results have been more satisfactory than those of ligature of the first part of the subclavian. The chief danger in each case is death from secondary hæmorrhage, due to the proximity of the ligature to the heart. Moreover, this particular operation is beset with grave anatomical obstacles; the deep situation of the vessel and the number and importance of the structures in its immediate vicinity are calculated to tax to the utmost the skill and resource of even the boldest operator. When the patient is spare, and there is only slight venous engorgement, the operation, if performed carefully and methodically, does not present any insuperable difficulty; on the other hand, should the opposite conditions exist, the greatest care and skill may be unavailing, and the patient may either die of hæmorrhage on the table, or the surgeon may be forced to abandon the operation.

Indications. The operation will only be required for an *aneurysm* involving either the first part of the common carotid trunk, or the first or second part of the right subclavian. A wound of such an important vessel as the innominate could hardly fail to prove fatal before assistance could be obtained. For an aortic aneurysm distal ligature of the carotid and subclavian would be done, as the affection would be almost certain to involve the root of the innominate.

Surgical anatomy. The artery extends from the arch of the aorta to the upper limit of the right sterno-clavicular articulation, and is nearly two inches long. It runs upwards, forwards, and outwards in the superior mediastinum. *Behind*, it lies upon the trachea below and the right pleura above. *In front*, the left innominate vein crosses the artery near its origin, and higher up it is separated by the sterno-thyreoid muscle from the sterno-hyoid and the right sterno-clavicular joint. The artery is overlapped by the right pleura, in front of which are the remains of the thymus and the manubrium sterni. It is also crossed obliquely by the inferior thyreoid veins. *On the right* of the artery are the upper part of the superior vena cava and the right innominate

vein, the right vagus and the pleura. *On the left side* are the first part of the left common carotid and some of the inferior thyroid veins below, and the trachea higher up.

Operation. (a) *Through a Δ -shaped incision.* The position of the patient is the same as for ligature of the subclavian (see p. 373). The surgeon stands on the right side facing the head and makes an angular incision, one limb of which follows the inner margin of the sterno-mastoid, and the other runs horizontally along the clavicle on the right side; each limb of this incision is about three inches long. The skin and fascia forming this triangular flap are dissected up, and the origin of the sterno-mastoid is exposed and divided throughout its whole length about an inch above the clavicle, so as to enable the divided ends to be sutured together at the end of the operation. The anterior jugular vein, which opens into the external jugular just before the junction of the latter with the subclavian, will probably require ligature and division. Beneath the sterno-mastoid are the sterno-hyoid and sterno-thyreoid muscles. The sterno-hyoid and, if necessary, the sterno-thyreoid are drawn aside or divided, and the bifurcation of the innominate is thereby exposed.

Up to this point the operation is fairly easy, but in proceeding with its further steps the most serious difficulties may be encountered. Should the patient be thin and the innominate of full length, it may be fairly easy to place a ligature upon its trunk, owing to the comparatively high level of the bifurcation in the neck. Should the innominate be short, however, the bifurcation may be well down behind the sterno-clavicular articulation, and it will be impossible to pass the needle below it without obtaining more room. A similar difficulty may arise if the patient be very fat or the neck short and thick. In these very embarrassing cases it is now the rule to remove the upper portion of the sternum and the adjacent sterno-clavicular articulation. This is an excellent plan which only prolongs the operation by a few minutes, whilst no important structures are endangered, and the after-results are good. In order to carry it out, the soft parts should be carefully peeled off the back of the manubrium sterni with a periosteum detacher, and then the operator removes a rectangular portion of bone from the centre of the sternal notch to about the centre of the sterno-clavicular articulation with a suitable chisel, saw, or cutting-pliers. There is no objection to removing the articular end of the clavicle at the same time if more room is desirable (see Fig. 190). This procedure exposes the innominate trunk and renders it accessible to ligature, and is an improvement strongly to be recommended whenever the surgeon has the least difficulty in effecting his purpose by the ordinary method. It has been

recommended, as a means of bringing the innominate into reach, to pass a temporary ligature round the lower end of the common carotid, and to pull the innominate more up into the neck by traction upon this; this is a dangerous method, however, and is not so efficacious as removal of the bone.

When the artery has been exposed, the left innominate vein must be

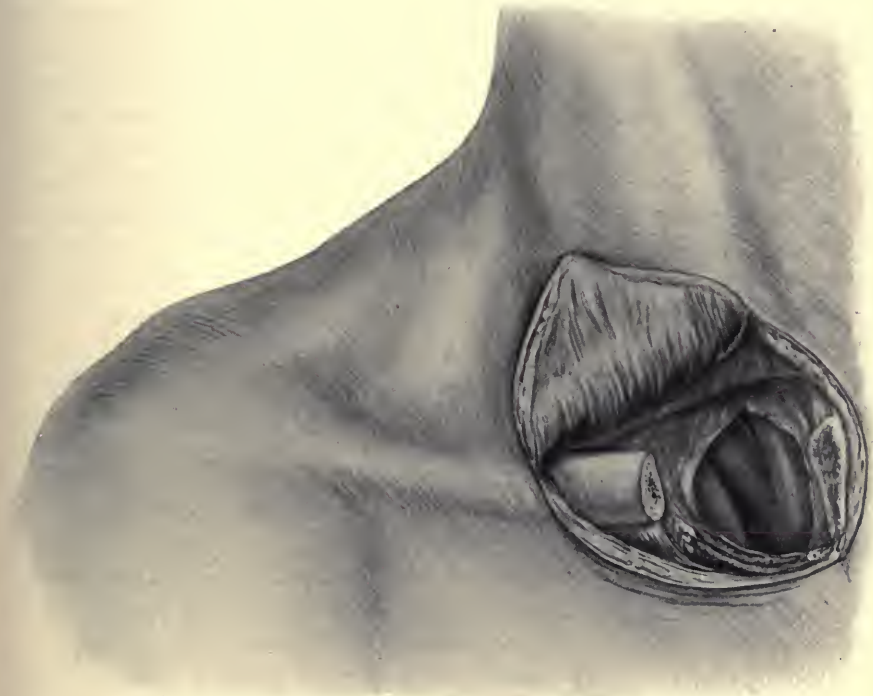


FIG. 190. LIGATURE OF THE INNOMINATE ARTERY. Parts of the sternum and the clavicle have been removed. The cut muscles are seen, also the innominate vein to the left and in front of the bifurcation of the artery.

pushed down out of the way with a fine flat, broad spatula, so that the sheath of the artery can be opened and the vessel cleared. It is always difficult to pass the needle round the artery, and the surgeon should be furnished with a series of needles with different curves and at different angles. The needle should be passed from the outer (or right-hand) side, and the ligature should be a double one of floss silk tied in a 'stay-knot' (see p. 290), and only drawn tight enough to cause apposition of the arterial walls without dividing them.

The divided muscles are sutured, and the skin is united by a continuous suture; it is well, however, to insert a small drainage tube for forty-eight hours in order to drain the large cavity left after the operation.

(b) *Through a median vertical incision.* Mr. Walter Spencer has suggested the employment of a median vertical incision for ligature of this vessel, on the ground that, as no muscles are divided, the parts will fall together sufficiently well after the operation to obviate the necessity for a drainage tube, a point of some importance considering the extreme danger of sepsis as a cause of secondary hæmorrhage. There is no doubt that the parts do come together better with this incision, and therefore the need for drainage is not so great, but it is more difficult to get at the innominate through this incision, and it may be necessary to remove bone in order to do so (*vide supra*). On the whole, the old angular incision probably gives more satisfactory access than the median one. At the present time, moreover, the risk of sepsis is so slight that it can no longer be an important factor in determining which method should be employed.

LIGATURE OF THE SUBCLAVIAN ARTERY

Indications. (i) For certain cases of *axillary aneurysm*. The operation will take the form of proximal ligature.

(ii) For some cases of *innominate or aortic aneurysm*. Here the operation will take the form of distal ligature.

(iii) For a few cases of *aneurysm of the first part of the axillary artery* not encroaching upon the third part of the subclavian. The operation is only possible when the aneurysm is small.

(iv) For *wounds of the subclavian*, generally stabs. Operation here is rarely of avail, as the patient usually dies before assistance can be obtained.

(v) *As a preliminary to removal of the entire upper extremity* (see p. 151).

(vi) *To secure hæmostasis* in amputations of the upper limb or in removal of large growths about the axilla or scapula. In these cases a temporary ligature only will be used.

Surgical anatomy. On the right side the artery commences at the bifurcation of the innominate artery behind the right sterno-clavicular articulation. On the left side it arises from the aorta behind the lower part of the manubrium sterni. The left subclavian is, therefore, longer than the right, measuring nearly four inches as against three, and lies both at the base of the posterior triangle and in the upper part of the

superior mediastinum. The relations of the second and third parts are similar on the two sides ; those of the first parts differ widely.

Relations of the first part of the right subclavian. *Behind* the artery are the recurrent laryngeal and the sympathetic nerves and the dome of the pleura. Deeper still are the transverse processes of the last cervical and first dorsal vertebræ, and the longus colli muscle.

In front of it are the right vagus, the phrenic, and branches of the sympathetic, the internal jugular and the vertebral veins, whilst still more superficially are the sterno-hyoid and sterno-thyreoid muscles, the anterior jugular vein, the sternal end of the clavicle and its ligaments, and the sterno-mastoid muscles.

Below, the recurrent laryngeal nerve passes between the artery and the top of the pleura. The subclavian vein is below and superficial or anterior to the artery.

Relations of the first part of the left subclavian. This portion is almost vertical. *Behind* it are the left margin of the œsophagus, the thoracic duct, the inferior cervical ganglion, and the longus colli muscle.

In front, and to the right of the artery, lie the left vagus and its inferior cardiac branch, the superior cardiac branch of the sympathetic, the phrenic, and the left common carotid artery. The left innominate vein crosses it obliquely below, as do also the internal jugular, vertebral, and subclavian veins above. The left vagus runs down the inner side of the artery but crosses its anterior surface below. Its left side is overlapped to some extent by the left lung and pleura, the sterno-hyoid, sterno-thyreoid, and sterno-mastoid muscles. *Internal* to it are the thoracic duct, the œsophagus, the left recurrent laryngeal nerve, and the trachea. *External* to it is the left pleura.

Relations of the second and third parts of the artery. These portions of the artery lie at the root of the neck, reaching outwards over the top of the lung, and passing behind the scalenus anticus (anterior) muscle. The second part of the artery lies entirely behind the scalenus, whilst the third part extends from the outer border of that muscle to the outer border of the first rib.

Behind and below, the second part of the artery is in close apposition to the pleura, while the third part of the artery rests upon the upper surface of the first rib. *In front*, the second part is covered by the scalenus anticus (anterior) and the sterno-mastoid muscles, the former of which separates it from the subclavian vein (which lies on a slightly lower level), from the transverse cervical and suprascapular (transverse scapular) arteries, from the anterior jugular vein, and, on the right side, from the phrenic nerve. *In front* of the third part and on a slightly lower level lies the subclavian vein, to join which the external jugular crosses the artery

towards its inner end and there receives the transverse cervical and suprascapular (transverse scapular) veins, which are, therefore, superficial to the artery. The nerve to the subclavius muscle crosses the artery, and, with the clavicle, is also an anterior relation of the vessel; the artery is also covered by the deep cervical fascia, the clavicular branches of the descending cervical nerves, the platysma and the skin. *Above*, and to the other side of the artery, lies the lowest cord of the brachial plexus.

The first part of the artery is but rarely tied, the operation having proved almost uniformly fatal. It would appear that the fatality of the operation is not likely to be greatly diminished in the immediate future, as death usually takes place from secondary hæmorrhage due to giving way of the coats of the vessel even in an aseptic wound. The operation will, however, be described, as it is not infrequently set for examination purposes.

The operation for ligature of the third part of the subclavian is the one usually performed. The second part of the artery is practically never tied, except in some few cases where after exposure the third portion has been found involved in the aneurysm, so that the vessel has to be traced further up, and the ligature applied to the second part.

LIGATURE OF THE FIRST PART OF THE RIGHT SUBCLAVIAN

This operation is not only difficult to perform, but it has hitherto been followed with indifferent success. It is difficult to say how much better results may be looked for in the future, owing to the improvements in wound-treatment and the use of non-irritating ligatures, but it seems certain that there must always be a serious risk of secondary hæmorrhage, owing to the proximity of the seat of ligature to the heart, and the great force which the walls of the vessel have to withstand, and which they are so often unable to bear when damaged by the ligature. The operation is never attempted upon the left side, except as a dissecting-room exercise, but it is feasible upon the right side, and in that situation must be looked upon as a recognized operation notwithstanding the condemnation passed upon it by writers reviewing results due, to a large extent, to faulty technique.

Blake (*Annals of Surgery*, 1906, vol. xliii, p. 919) gives the notes of a very interesting case of an aneurysm of the second and third parts of the right subclavian successfully treated by combined ligature of the first part of the subclavian artery and the first part of the axillary. The first part of the subclavian was exposed by the method detailed below (see p. 371), and a ligature was successfully applied to it. The

wound healed perfectly, but the pulsation never completely ceased in the aneurysm and began to get worse, so that a month later the first part of the axillary was exposed by an incision between the deltoid and pectoralis fibres, and a ligature applied to it as near the subclavian as possible; this resulted in complete cure of the aneurysm. When the number and size of the branches given off by the first and second portions of the artery are considered, and the freedom with which they anastomose, this would appear to be the only rational method from which to expect a permanent cure of an aneurysm in this situation. The risk to the circulation in the upper extremity is very slight indeed, and if the treatment be undertaken in two stages, as in this case, no harm is likely to happen; indeed it is questionable if gangrene would ever be likely to occur provided that the wound were kept aseptic.

Pack (*ibid.*, p. 930) recorded a similar operation for the cure of traumatic aneurysm of the thyroid axis. This also was successful, and only differed from the preceding case in that the second ligature, instead of being placed at the junction of the axillary with the subclavian, was placed on the latter vessel just external to the scalenus anticus.

The mortality of this operation is said by Lillienthal (*Annals of Surgery*, 1906, vol. xliii, p. 921) to have fallen since 1890 from 75% to 16%. No doubt some part of this diminution is due to improved aseptic methods, but there is little doubt in the minds of most observers that it is also partly due to the absence of secondary hæmorrhage from direct irritation of the ligature as a result of the use of approximation ligatures; the adoption of the 'stay-knot' of Ballance and Edmunds (see p. 289) has to some extent contributed to this result.

Indications. These will be practically identical with those for ligature of the third part.

Operation. The positions of the patient and the surgeon are the same as for ligature of the innominate. The surgeon has the choice of two incisions for exposure of the vessel:—

(a) *An oblique incision* about four inches long parallel to and about half an inch external to the anterior margin of the sterno-mastoid, and extending well down on to the clavicle. As this incision is deepened, the interval between the two heads of the sterno-mastoid is reached, and this is enlarged upwards by splitting the fibres of the muscle so as to enable the two heads of the muscle to be sufficiently retracted to opposite sides to give proper access to the vessel. The remaining steps of the operation are the same as in the Δ -shaped incision (*vide infra*).

This oblique incision possesses the *advantage* that the parts fall together well after the operation, and leave no large cavity requiring drainage—an important consideration in these cases. It has the *disadvantage*,

however, that it hardly gives enough room, except in thin subjects in whom the sterno-mastoid is comparatively small ; it should therefore be reserved for them.

(b) An Δ -shaped incision is the more usual one ; one limb lies over the anterior margin of the sterno-mastoid, and the other horizontally along the clavicle. The triangular flap thus formed is dissected up, and the sterno-mastoid is divided horizontally about half an inch above its origin so as to leave enough of the latter for the fibres to be reunited at the end of the operation. In doing this the anterior jugular vein will probably be divided. The sterno-thyreoid muscle covers the artery and must either be pulled aside or divided, and, if necessary, a portion of the outer edge of the sterno-hyoid must be similarly treated. This brings the great vessels of the neck into view, and the bifurcation of the innominate can be detected by the finger.

The chief sources of difficulty met with at this stage are the large venous trunks in front of the artery, which vary in size with respiration, and seriously impede the operation. They should be cautiously peeled down and pushed out of the way, a few light touches with the point of a sharp knife being required to loosen the delicate cellular tissue which connects them to the arteries. They are then held down out of the way by a fine thin narrow spatula, and the sheath of the innominate artery is opened quite close to its bifurcation. The subclavian is then traced from this point outwards beyond the bifurcation, and the needle is insinuated round it from below upwards, as in that way the vein and the pleura are best avoided. During this procedure the termination of the internal jugular vein will have to be pulled to the outer side with the finger or a small spatula ; with it should go the vagus.

It is usually recommended that the vertebral should be tied (see p. 388) simultaneously with the first part of the subclavian. At this stage of the operation it is somewhat less difficult than under ordinary circumstances, owing to the free exposure of the parts, but it would be impossible if the operation were being done for aneurysm of the second part of the subclavian. A point that must not be forgotten is that the subclavian comes off at a very acute angle, and not almost horizontally as one would suppose. It ascends almost vertically from behind the carotid, and the angle between these two arteries is quite small.

Perusal of the cases quoted by Blake and Pack (*loc. cit.*) makes one consider seriously the question of applying a ligature simultaneously to the third part of the subclavian, or the first part of the axillary in cases of aneurysm of the second or third part of the artery.

LIGATURE OF THE THIRD PART

Operation. A pillow is placed beneath the shoulder on the affected side, the head is turned to the opposite side, the neck moderately extended, and the arm drawn firmly downwards so as to depress the clavicle and thus open up the posterior triangle as much as possible. The surgeon stands on the affected side facing the patient, and, drawing down the skin over the clavicle with his left hand as far as it will come, makes

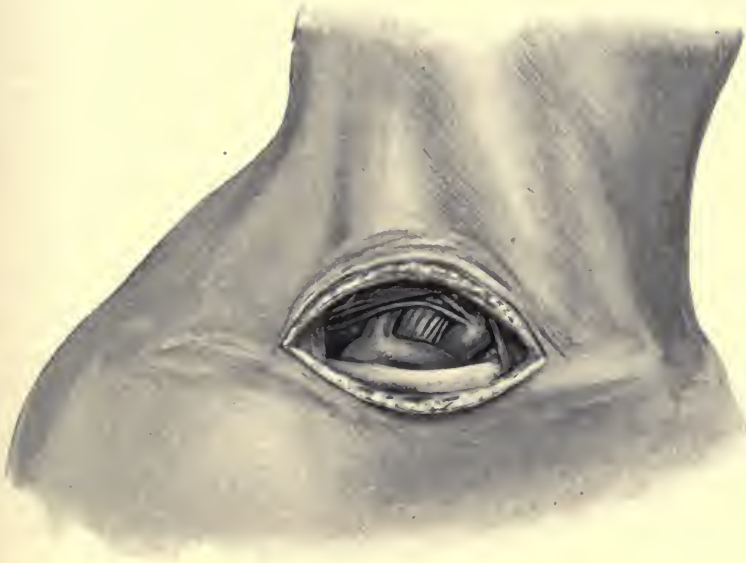

FIG. 191. LIGATURE OF THE THIRD PART OF THE SUBCLAVIAN. The artery and its branches, which in this case arise from the beginning of the third part instead of the second, as is usually the case, are seen below the last cord of the plexus. The subclavian vein is receiving the external jugular; both were unduly large in the subject from which the drawing was made.

an incision three inches in length down to that bone between the adjacent margins of the sterno-mastoid and the trapezius muscles. The skin is pulled down in order to avoid injury to the external jugular vein, which pierces the deep fascia immediately above the clavicle; as this spot is fixed, it is impossible to draw it down with the skin, and therefore the vein cannot be injured in the first incision. After the skin has been allowed to retract, the incision crosses the root of the posterior triangle transversely a little more than an inch above the clavicle.

The position of the external jugular vein is now defined, the deep

fascia is opened up throughout the length of the incision, and a little dissection reveals the posterior belly of the omo-hyoid muscle, the lower margin of which is defined and drawn up with a retractor. The base of the posterior triangle is thus displayed, and the finger introduced into it will at once feel the cords of the brachial plexus, which run from above obliquely downwards and outwards; they are the best guide to the artery. The outer border of the anterior scalene and the scalene tubercle, which are mentioned by most writers as the best guides to the artery, are often wholly unreliable. In the dead subject, at any rate, it may be difficult to identify the outer border of the scalene muscle, and equally difficult to identify the tubercle, while the cords of the plexus can never be mistaken, at any rate when the posterior triangle has been well opened up. There is often considerable oozing from the numerous veins in the posterior triangle; these should be tied as they are injured, but it is important to avoid injuring the corresponding arteries; the latter run nearly parallel with the main vessel, and so it is easy to avoid injuring them.

When the lowest cord of the plexus has been identified by clearing it with a few light touches of the knife, it is hooked up out of the way. The artery lies parallel with it, below it and on a slightly deeper plane. As a rule the vein does not come into view unless respiration be obstructed, as it lies below the artery and is separated from it by the scalenus anticus (anterior) muscle. When the artery has been identified, its sheath is opened and the vessel cleared, particular care being taken to avoid puncturing the pleura, which lies below the artery. It will be found safest to pass the needle from below upwards, so as to avoid damage to the pleura and the vein; it is easy to avoid including the lowest cord of the plexus in the ligature by pressing it back out of the way with the finger, or with a dissector. The ligature should be made to approximate the coats of the artery and not to divide them. The wound is sutured without a drainage tube, and the arm is fastened to the side for a week or ten days.

Difficulties and dangers. These should be few if the above recommendations be followed. The principal difficulty will occur from the matting together of the tissues in the posterior triangle when the sac of the aneurysm encroaches upon it. This is likely to cause troublesome oozing, which is best dealt with by tying each bleeding point as it is met with, and by not using blunt dissectors or any tearing instruments, as they only cause infiltration of the areolar tissue with blood, and obscure the view. The artery is easy to find if the brachial plexus be taken as a guide. This prominent structure can be actually felt through the skin in a thin subject, and can hardly be mistaken when the posterior triangle has been opened up. The chief difficulty in the operation lies

in clearing the artery and in passing the needle without damaging the pleura. This can only be avoided by care and gentleness, pulling down the shoulder as far as it will go, and using needles of different curves.

LIGATURE OF THE COMMON CAROTID ARTERY

Indications. (i) For *wounds of the vessel itself*. These will be chiefly stabs or gunshot wounds. When the artery is damaged in cut-throat, death usually occurs before assistance can be obtained.

(ii) For *aneurysm of the carotid trunk or its main branches*. This affection is more frequent in the common trunk than in either of its terminal branches. The ligature will be applied on the proximal side of the aneurysm, and if it be applied for aneurysm of the common trunk the external carotid may be ligatured simultaneously (see p. 383) in order to prevent recurrence of the pulsation through this freely anastomosing vessel.

(iii) For *aneurysm of the innominate or the aorta*. Here the distal operation is performed, and, as a rule, the subclavian artery will be tied simultaneously.

(iv) For *aneurysm of the orbit*. The operation has been performed several times for this condition, and has succeeded in some instances; it is by no means invariably successful, however.

(v) A *temporary ligature* is not infrequently passed around the common carotid trunk to control the bleeding during removal of large tumours from the side of the head or face, or during removal of very vascular tumours of the jaws. A better plan is to apply the compression to the external carotid only. Instead of a ligature, Crile's artery compressors may be used (see p. 263).

(vi) The common carotid has also been tied for the *control of hæmorrhage* due to various conditions, such as cancer of the tongue or face, profuse bleeding after removal of the tonsil or the opening of a tonsillar abscess; but a better plan is to tie the external carotid trunk either on one or both sides, as the cerebral symptoms due to the scanty blood-supply via the internal carotid are not then met with. The same remark applies to ligature of the common carotid when performed for the cure of aneurysm by anastomosis.

Surgical anatomy. The right common carotid artery extends from the right sterno-clavicular articulation to the level of the upper border of the thyroid cartilage, where it divides into its external and internal branches. The left trunk arises from the arch of the aorta, but terminates at a similar point and is therefore longer than its fellow. The relations of the two in the neck are similar; the left common carotid has intra-thoracic relations in addition.

Relations of the left common carotid in the thorax. The intra-thoracic

part of this artery measures from one to one and a half inches in length, and passes upwards and slightly outwards through the superior mediastinum on a plane posterior to the innominate trunk; it is therefore more overlapped by the pleura.

Posteriorly, the vessel lies upon the trachea, the left recurrent laryngeal nerve, the œsophagus and the thoracic duct.

In front, the left innominate vein crosses the artery obliquely, while the cardiac branches of the left vagus and sympathetic cross it vertically. Superficial to these are the remains of the thymus and the anterior margins of the left lung and pleura, in front of which again lies the manubrium sterni with the origin of the sterno-hyoid and sterno-thyreoid muscles.

On the right side are the innominate artery below, and the trachea and the inferior thyreoid veins higher up.

On the left side, the left pleura is in close contact with the artery. Somewhat posteriorly are the left phrenic and vagus nerves and the left subclavian artery.

Relations of the common carotid in the neck. This portion of the vessel is about three and a half inches long and runs upwards, outwards, and backwards in the anterior triangle of the neck. It diverges somewhat from its fellow on the opposite side, being separated from it below by the trachea and œsophagus and above by the much wider pharynx. The artery is enclosed in a special sheath of deep cervical fascia called the carotid sheath, together with the internal jugular vein and the vagus nerve.

Behind, the vessel lies from above downwards upon the rectus capitis anticus major (longus capitis), the longus colli, and the scalenus anterior, upon which are the prevertebral fascia and the cords of the cervical sympathetic nerve. Just below the level of the cricoid cartilage the inferior thyreoid artery passes behind the vessel, whilst lower down the vessel lies over the vertebral artery and the thoracic duct; the vagus lies behind and to its outer side.

In front, the descendens hypoglossi nerve lies on the sheath of the artery, but is sometimes enclosed within it. The artery is crossed by the omo-hyoid muscle and the sterno-mastoid branch of the superior thyreoid artery, and by the superior and middle thyreoid and generally also by the lingual veins. Above the omo-hyoid the vessel is overlapped by the anterior margin of the sterno-mastoid, whilst below that muscle it is also covered by the sterno-thyreoid and sterno-hyoid muscles, and frequently also by the lateral lobe of the thyreoid body. The communicating vein between the facial and anterior jugular lies along the anterior margin of the sterno-mastoid, and hence crosses the line of the artery obliquely. The anterior jugular vein is also in front of the artery just

above the sternum, but the sterno-hyoid and the sterno-mastoid muscles intervene between these two structures.

On the inner side below lie the trachea and the œsophagus with the recurrent laryngeal in the angle between them, also the lateral lobe of the thyroid body and the inferior thyroid vessels, whilst above are the larynx and the pharynx.

On the outer side lie the internal jugular vein, which overlaps the lower end of the artery in front, especially on the left side, and the vagus nerve.

Line of the artery. From the sterno-clavicular articulation to the mid-point between the angle of the jaw and the mastoid process. The bifurcation of the carotid corresponds to a point along this line opposite the upper border of the thyroid cartilage. The line of the artery corresponds fairly closely with the anterior margin of the sterno-mastoid when the head is turned slightly to the opposite side.

The carotid is tied either above or below the omo-hyoid according to the position of the ligature relative to this structure. The former operation is easier and is therefore more frequently done, the operation being known as ligature of the common carotid at 'the seat of election'. The artery is much more deeply placed below the omo-hyoid, and the operation for its ligature is proportionately more difficult.

LIGATURE ABOVE THE OMO-HYOID

Operation. The parts are shaved, a small pillow is placed beneath the shoulder on the affected side, the neck is slightly extended, and the chin is turned to the opposite side. The surgeon stands on the affected side and makes an incision (see Fig. 192) three inches long in the line of the artery (*vide supra*), with its centre opposite the cricoid cartilage. This incision divides the platysma and the superficial fascia and will probably also divide the communicating vein between the facial and the anterior jugular, and will expose the inner margin of the sterno-mastoid enclosed in its sheath of deep cervical fascia. The deep cervical fascia is next incised throughout the length of the incision just anterior to the margin of the muscle, which is drawn back in its sheath with suitable retractors. This opens up the anterior triangle of the neck and exposes the omo-hyoid muscle crossing the artery obliquely from below upwards and inwards; its upper border is defined by a few touches of the knife and the muscle is pulled downwards. In doing this it will probably be necessary to tie the middle thyroid vein as it crosses the field of operation; the sterno-mastoid artery may also be divided. The lateral lobe of the thyroid does not usually give trouble; should it be enlarged, it must be pulled to the inner side. In the dead subject it may cause

confusion, and may be mistaken for the omo-hyoid or some of the laryngeal muscles. The absence of definite fibres will demonstrate the mistake.

The internal jugular vein will now be seen, and, in the living subject, the artery will be felt pulsating just internal to it. In the dead subject the vein offers no hindrance to the operator; in the living, however,

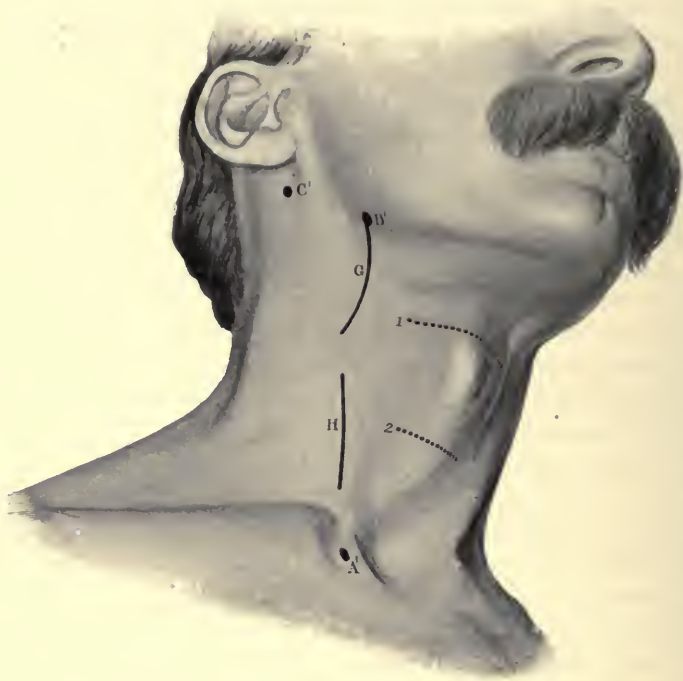

FIG. 192. INCISIONS FOR LIGATURE OF THE COMMON AND EXTERNAL CAROTID ARTERIES. A¹ is on the sterno-clavicular articulation, C¹ on the tip of the mastoid process, and B¹ on the angle of the jaw. The dotted line 1 is the level of the upper border of the thyroid cartilage, 2 that of the cricoid. H is the incision for ligature of the common carotid above the omo-hyoid, G that for ligature of the external carotid.

it is often in the way, owing to its variation in size during respiration, and special care has to be taken to avoid damaging it when opening the sheath of the artery. The sheath, along which will be seen the descendens hypoglossi nerve (see Fig. 193), is opened to the inner side, and in clearing the vessel care must be taken to keep the point of the needle closely in contact with the vessel wall behind so as to avoid including the vagus in the ligature. The methods of clearing the artery and passing the needle have already been described (see p. 288), and the

details there given apply to this vessel, and should be followed scrupulously. If the sterno-mastoid be unduly large, or the neck be fat and thick, the head should be bent forwards by an assistant so as to relax the muscles while the artery is being cleared and the ligature passed; the latter should be tied so as to divide the inner and middle coats.

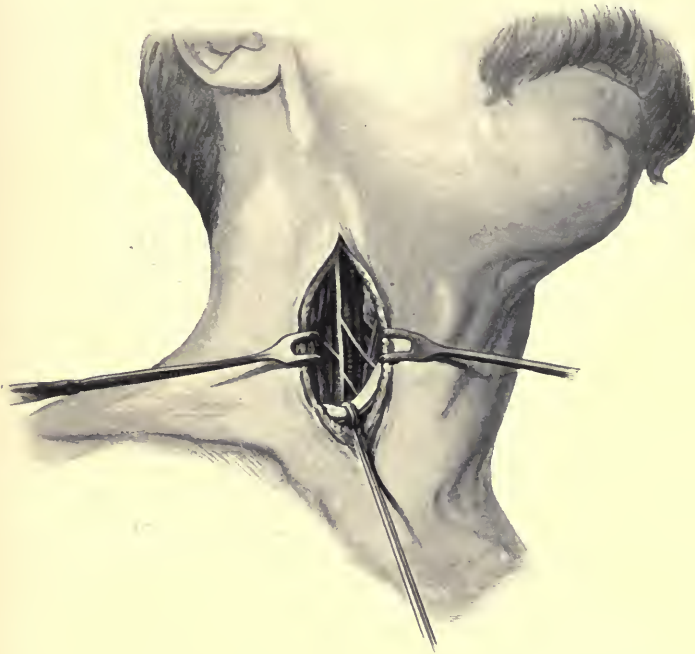


FIG. 193. LIGATURE OF THE COMMON CAROTID ABOVE THE OMO-HYOID. The omohyoid is hooked downwards and the artery is seen with the vein external to it and the descendens hypoglossi nerve on its sheath.

LIGATURE BELOW THE OMO-HYOID

Operation. The positions of patient and operator are the same as before. The incision (see Fig. 194), which should be about three and a half inches long, reaches from the cricoid cartilage to the sterno-clavicular joint, following the line of the artery given above (see p. 377). The inner margin of the sterno-mastoid is exposed, and the deep cervical fascia in front of it is incised so as to allow the muscle to be pulled back in its sheath. This may be very difficult in stout subjects with well-developed muscles, and it may therefore be necessary to detach the sterno-mastoid partially from the clavicle. This will expose the sterno-thyreoid and possibly the sterno-hyoid muscles, which

should be pulled inwards, whilst the omo-hyoid, which lies more externally, should have its lower border defined and hooked upwards and outwards (see Fig. 195). At this stage there may be severe oozing from the anterior jugular and the inferior thyreoid veins, which may all require ligature and division. When the muscles have been

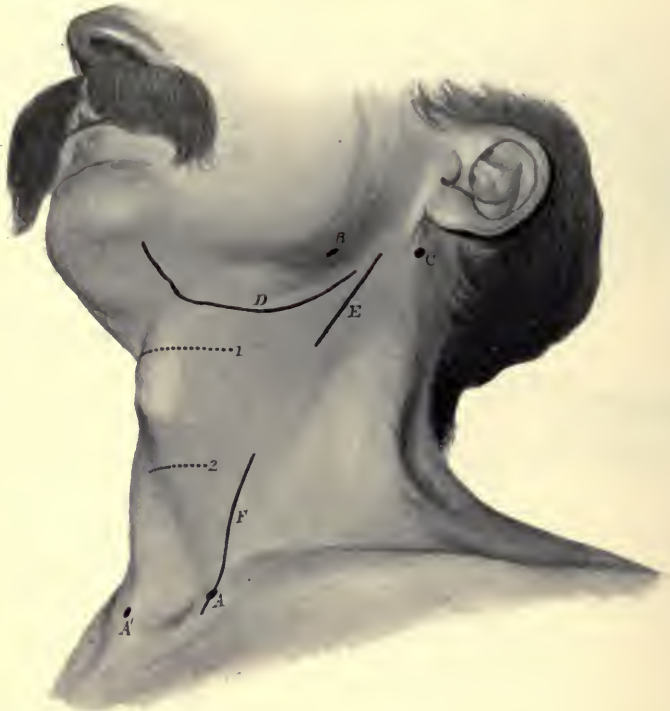

FIG. 194. INCISIONS FOR LIGATURE OF THE COMMON AND INTERNAL CAROTID AND THE LINGUAL ARTERIES. A is on the sterno-clavicular joint, B on the angle of the jaw, and C on the tip of the mastoid process. The dotted line 1 denotes the level of the upper border of the thyroid cartilage, 2 that of the cricoid. F is the incision for ligature of the common carotid below the omo-hyoid, E that for the internal carotid, while D is the incision for ligature of the lingual.

retracted, the artery can be felt pulsating at the bottom of the wound. It is here that the chief difficulty will be met with, as the distended internal jugular vein gets in the way and greatly interferes with the process of opening the sheath and clearing the artery. This is especially the case on the left side, where the distended vein may actually lie in front of the artery during expiration. On the right side there is generally an interval between the two, and the vein only comes into close relation

with the artery when it is distended to the utmost. The vein will probably have to be held back by a narrow flat spatula or by the surgeon's fingers, as its walls are delicate and are easily punctured by the aneurysm needle. A wound of the vein in this situation is a very dangerous matter (*vide infra*).

Difficulties and dangers. These are very few, especially when the artery is being tied above the omo-hyoid. If the chin be turned

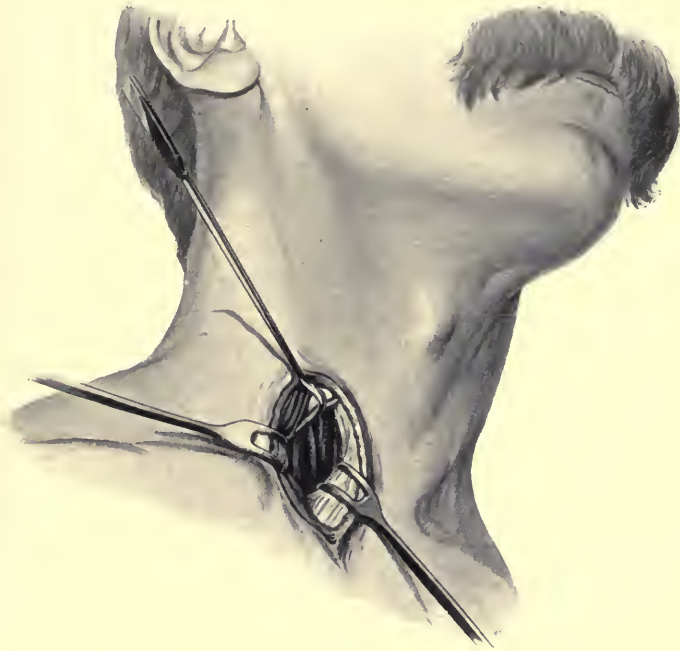


FIG. 195. LIGATURE OF THE COMMON CAROTID BELOW THE OMO-HYOID. The omo-hyoid is hooked up, showing the artery and the very large internal jugular vein.

too far to the opposite side, the incision may be made over the sternomastoid muscle, instead of along its anterior margin, and the operator may therefore be delayed by having to search for this landmark. Moreover, such an incision renders the proper retraction of the parts more difficult. Serious oozing from the thyreoid veins or an enlarged lateral lobe of the thyreoid will not be met with if care be taken to incise cleanly, and to pick up and tie bleeding points as they are met with. Troubles of this description are only likely to be met with when the parts are ruthlessly torn with blunt dissectors. The chief difficulty

in tying the vessel in the dead subject comes from a misconception as to the depth at which the vessel lies. When the neck is rigid, as it generally is, and the head cannot be turned over to the opposite side, the artery lies much deeper than it does in the ordinary position.

Injury to the structures in the immediate vicinity of the artery is the chief risk in the operation of ligature below the omo-hyoid. Injury to the internal jugular vein may easily occur owing to the constant variation in size caused by respiration. The surest way to avoid injuring the vein is to press it well to the outer side with the finger, or else to define its inner edge by a few touches with the point of a sharp knife, and then pull the vein away from the artery and hold it out of danger with a blunt hook. The vein is not likely to be damaged during the passage of the needle round the artery, unless the sheath be insufficiently opened and undue force be employed. Should the vein be punctured, the hæmorrhage is profuse, and if the wound in it be large, and especially if it be seated below the omo-hyoid, air may be sucked into the vein. Immediately such an accident is recognized, pressure should be applied to the wound in the vein to occlude it and prevent further entry of air. The wound should then be flooded with sterilized salt solution, pressure applied on either side of the opening in the vein, and the rent in it seized with forceps and a lateral ligature applied. The artery should be cleared afresh and ligatured either above or below the spot at which the wound in the vein has occurred.

Inclusion of the vagus or sympathetic nerves in the ligature is not likely to happen unless undue force be used to get the needle round the artery. If the sheath be properly opened, the needle finds its way readily between the artery and the sheath, and, as the vagus and sympathetic lie outside and behind this structure, their inclusion in the ligature should be out of the question. In the dead subject there is considerably more difficulty in passing the needle owing to the rigidity and retraction of the parts.

The chief danger after ligature of the common carotid is the occurrence of cerebral complications due to defective blood-supply, which leads to a temporary abeyance of function, and may end in cerebral softening, coma, and death. In the minor cases the patient gets symptoms of cerebral anæmia, such as twitchings, giddiness, and temporary paralysis; whilst in the graver cases, gradually increasing coma ensues, followed by convulsions and death. It is owing to this serious complication that the mortality of the operation is still so comparatively high. The surgeon, therefore, should always tie the external carotid in preference to the common trunk when he has the choice.

LIGATURE OF THE EXTERNAL CAROTID ARTERY

Indications. (i) For *wounds*. These will be chiefly stabs in the parotid region. The artery is occasionally damaged in attempted cut-throat; here the lesion is generally immediately fatal.

(ii) For *persistent hæmorrhage from the tonsil*. For these cases ligature of the external carotid is distinctly preferable to ligature of the common trunk, as it is equally effective in arresting the bleeding, and there is no risk of cerebral complications.

(iii) For *aneurysm of the external carotid*: a very rare condition.

(iv) *Temporary ligature* of the external carotid may be very useful when removing growths in the parotid region or on the side of the face. Some surgeons tie the artery permanently under these circumstances, but it is quite sufficient to exercise a temporary compression of it so that the circulation can be controlled throughout the operation; when the tumour has been removed, the temporary compression is relaxed and the bleeding vessels are secured. This method of employing temporary compression is most valuable when the wound communicates with the mouth or pharynx, as secondary hæmorrhage is a frequent complication of permanent ligature of the external carotid under these circumstances; when only temporary compression of the vessel is employed during the operation and the terminal branches are secured at the end of it, this serious complication is not so likely to occur. Crile's compression clamp (see p. 263) may be used in place of a temporary ligature.

(v) The vessel is sometimes tied in order to *starve large malignant growths* involving the mouth, side of the face, parotid or jaw, which there is no possibility of removing successfully. The operation is done with the same object as ligature of the lingual for inoperable cancer of the tongue. It is not very likely, however, to be followed with much success, as the anastomosis with the opposite side is very free. If done at all, the artery on the opposite side should be ligatured simultaneously.

(vi) For *persistent middle meningeal hæmorrhage*. As a rule even the worst bleeding from the middle meningeal may be arrested by plugging the foramen spinosum with Horsley's wax or some other suitable material after enlarging the wound in the skull sufficiently downwards. Occasionally, however, it may be necessary to tie the carotid.

(vii) For *aneurysm by anastomosis*. When the aneurysm is situated on the face and side of the head, the control of the blood-supply through the external carotid will greatly facilitate the other measures suitable for the treatment of this condition. If the aneurysm can be excised, it will suffice to exercise temporary compression of the carotid during

the excision. The bleeding points can then be secured and the compression relaxed.

Surgical anatomy. *Behind*, the artery lies close to the internal carotid, which is superficial and posterior to it at the bifurcation. The two vessels are separated by the stylo-glossus and stylo-pharyngeus muscles, which pass behind the external trunk, as do also the glosso-pharyngeal nerve, the pharyngeal branch of the vagus, and the stylo-hyoid ligament. Higher up in the neck it is in relation with the parotid gland and the cartilaginous portion of the external auditory meatus.

In front, it is crossed by the various veins joining the internal jugular, namely, the lingual, common facial, and superior thyreoid. The hypoglossal nerve crosses the artery and turns inwards immediately below the origin of the occipital branch. The posterior belly of the digastric and the stylo-hyoid muscles also cross the artery, whilst more superficially it is overlapped by the anterior border of the sterno-mastoid below and the parotid gland above. In the latter structure the temporo-maxillary (common facial) vein descends on the outer side of the artery, and the facial nerve crosses it.

On its *inner side* it is in relation with the inferior constrictor near its commencement, but it is separated above from the pharynx by the stylo-pharyngeus and the stylo-glossus muscles, the glosso-pharyngeal nerve, and the pharyngeal branch of the vagus. The laryngeal branches of the superior laryngeal nerve also lie on its inner side.

The artery may be tied either above or below the posterior belly of the digastric, but it should always be exposed in the latter situation, if possible, on account of the danger of dividing the facial nerve in the incision for exposing the vessel above the digastric. If it be desired to apply the ligature above that muscle, therefore, the vessel should be exposed below it and traced upwards after the digastric has been displaced. The ligature is usually applied between the superior thyreoid and the lingual arteries—which vessels should also be tied simultaneously—and the seat of ligature is generally opposite the great cornu of the hyoid bone, which can be easily felt by the finger in the wound.

Operation. The positions of the patient and the surgeon are the same as in the preceding operation (see p. 377). An incision (see Fig. 192) two and a half inches long is made in the line of the artery from the angle of the jaw to the bifurcation of the common carotid (see p. 377). After the deep fascia has been divided, and the anterior triangle has been opened up, the sterno-mastoid is drawn well back, and the lower border of the posterior belly of the digastric is defined and pulled upwards. The vessel will then be exposed, as it passes beneath this muscle opposite the great cornu of the hyoid bone, which can be felt in the wound ;

if a further guide be necessary, identification of the hypoglossal nerve winding round the occipital artery will satisfy the surgeon that he is dealing with the external carotid. A little dissection is required to identify the vessels between which the ligature is to be placed. Of these the most constant in its direction is the superior thyreoid, which has a characteristic curve, at first upwards and then downwards and inwards (see Fig. 196). This vessel should be secured, and the carotid

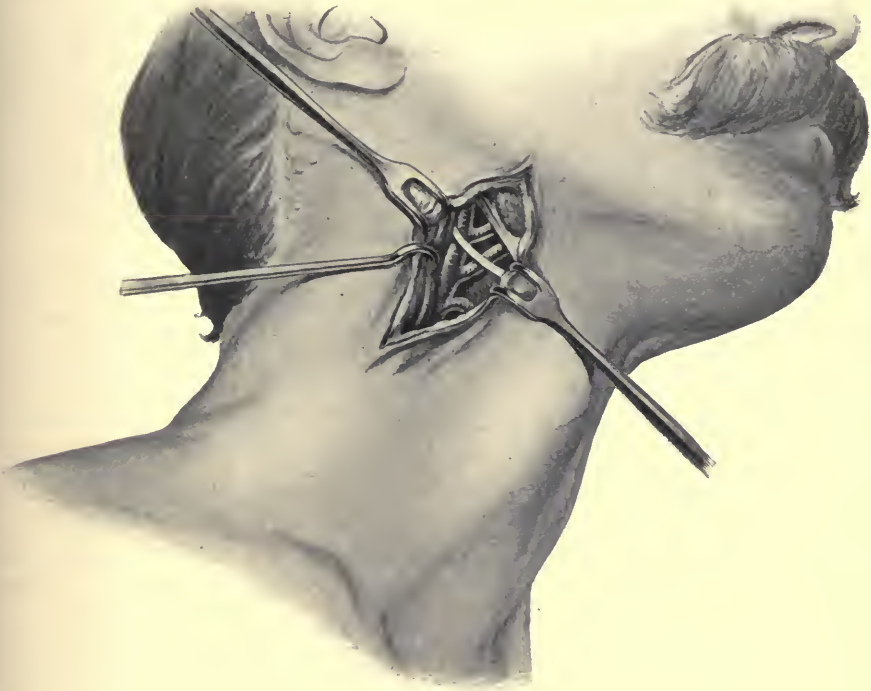


FIG. 196. LIGATURE OF THE EXTERNAL CAROTID ARTERY. The artery and its branches are seen, as is also the hypoglossal nerve and the posterior belly of the digastric.

is then cleared upwards to the next branch, namely, the lingual, which is secured in a similar manner. Finally the needle is passed round the external carotid trunk from without inwards; the facial and the ascending pharyngeal branches may with advantage be ligatured at the same time.

If it be desired to put a temporary ligature round the vessel, its branches are not secured. A ligature of silk, tape, or kangaroo tendon is passed round the vessel, its ends are knotted together to form a loop,

by means of which traction is made so as to kink the artery acutely and obstruct the circulation through it. Crile's clamp (see p. 263) may be used instead of a ligature.

LIGATURE OF THE INTERNAL CAROTID ARTERY

Indications. This operation is very rarely done. It may be called for—

(i) For *wounds of the vessel*, which, however, are usually fatal before help can be obtained.

(ii) For *aneurysm of the internal carotid*. There will rarely be room, however, to apply a ligature to the internal carotid below an aneurysm of that vessel. In very small aneurysms, however, it is possible that advantage might be taken of the fact that the internal carotid gives off no branches in the neck to expose and tie the vessel above and below the aneurysm, and either incise the aneurysm and turn out the clot, or excise the sac completely.

(iii) For *orbital aneurysm*. Since this condition is supposed to be due to a communication between the internal carotid and the cavernous sinus, ligature of the internal carotid would be a better method of treatment than ligature of the common trunk. I have treated two such cases successfully (one after previous unsuccessful ligation of the common carotid) by combined ligature of the internal carotid and the angular vein (see *Ophthal. Soc. Trans.*, 1907).

Surgical anatomy. The line of the artery is a continuation upwards of that of the common carotid trunk (see p. 377). The vessel extends from the upper border of the thyreoid cartilage to the anterior clinoid process of the sphenoid, traversing the carotid canal in the temporal bone. In the neck it lies at first behind and to the outer side of the external branch, but it gets to its inner side as it passes beneath the posterior belly of the digastric; it then ascends under cover of the parotid gland to the carotid canal.

Relations. *Behind*, it lies upon the rectus capitis anticus major (longus capitis), with the prevertebral fascia, the superior cervical ganglion, and the cords of the sympathetic and the vagus nerve. Just as it is about to enter the skull through the carotid canal, the hypoglossal, the vagus, the glosso-pharyngeal, and the spinal accessory nerves pass behind it and separate it from the internal jugular vein.

In front are the sterno-mastoid, with the platysma and the deep cervical fascia, and the posterior belly of the digastric and the stylohyoid, and the deep surface of the parotid gland higher up. The hypoglossal nerve, the occipital artery, and the posterior auricular artery

also cross it beneath the sterno-mastoid. Passing obliquely across its anterior and outer surface and separating it from the external carotid are the stylo-pharyngeus, the tip of the styloid process, the stylo-glossus muscle, the glosso-pharyngeal nerve, and the pharyngeal branch of the vagus.

Internal to it is the external carotid below, and above that are the wall of the pharynx, the ascending pharyngeal artery, the pharyngeal plexus of veins, and the external and internal laryngeal nerves; near

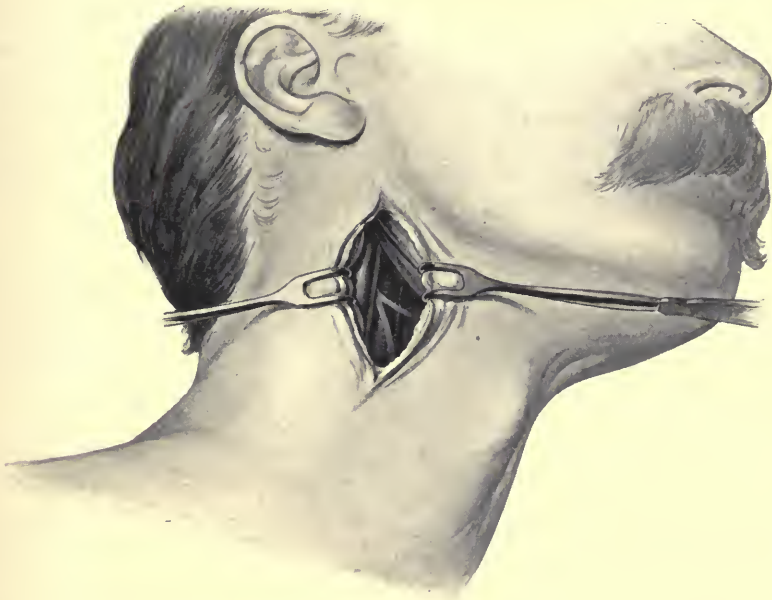


FIG. 197. LIGATURE OF THE INTERNAL CAROTID ARTERY. The internal jugular vein is seen behind the artery, while crossing it is the hypoglossal nerve, giving off its descending branch.

the entry of the vessel into the carotid canal are the levator palati muscle and the Eustachian tube. Somewhat to its *outer side*, and rather posterior, are the internal jugular vein and the vagus nerve.

Operation. The positions of the patient and the surgeon are the same as in the last operation. An incision about three inches long is made along the line of the artery (see p. 377), corresponding closely to the anterior border of the sterno-mastoid and commencing just below the upper border of the thyreoid cartilage (see Fig. 194). The anterior margin of the sterno-mastoid is pulled well back, and the bifurcation of the common carotid is exposed. It should be remembered that the internal carotid is superficial and posterior to the external at this point.

Another means of identification is the absence of branches from the internal trunk, and the presence of the internal jugular vein on its outer side (see Fig. 197). The needle is passed from without inwards.

LIGATURE OF THE VERTEBRAL ARTERY

Indications. These must always be extremely rare; indeed, the operation is practically a mere dissecting-room exercise. In the living subject it might be required for stabs or traumatic aneurysm of the vertebral. Some years ago it was much advocated for the cure of epilepsy, but time has shown that it does not exert any real restraining influence on the disease. Owing to the depth at which the artery is situated, and the importance of the structures by which it is surrounded, the operation must always be one of great difficulty. Should it be necessary to expose the vessel for injury or traumatic aneurysm, this difficulty will be increased enormously.

Surgical anatomy. The vertebral artery is the first branch of the subclavian, and springs from its upper and back part just opposite the septum between the scalenus anticus (anterior) and the longus colli muscles. It runs up in the interval between these two muscles and ends at the lower border of the pons, where it unites with its fellow on the opposite side to form the basilar artery.

Relations in the neck. The artery lies in the interval between the inner border of the scalenus anticus (anterior) and the outer border of the longus colli. It is crossed by the internal jugular and the vertebral veins, by the inferior thyreoid artery, and, on the left side, by the terminal portion of the thoracic duct. It is surrounded by a plexus of sympathetic nerve fibres, and enters the foramen in the transverse process of the sixth cervical vertebra.

Operation. The positions of the patient and the operator are the same as for ligature of the common carotid (see p. 377), except that the head is turned rather more forcibly to the opposite side. An incision three and a half inches long is made along the posterior border of the sterno-mastoid, extending downwards as far as the clavicle. Before the deep fascia is reached, the external jugular vein should be identified, as it runs almost parallel with the margin of the muscle, and must be avoided if possible; if not, it must be divided between two ligatures before it pierces the deep fascia. The deep fascia has now to be divided along the posterior edge of the sterno-mastoid, and that muscle and the jugular vein are drawn inwards, the head being bent to allow this to be done; should the patient be stout, or the muscle unduly large, it may be partially divided from the clavicle, if necessary. The artery

lies very deep, and the best guide to it is the outer edge of the scalenus anticus (anterior), which lies parallel to and deeper than the outer border of the sterno-mastoid. When this muscle has been identified, the interval between it and the longus colli is looked for. Help may be obtained by feeling the transverse process of the sixth cervical vertebra

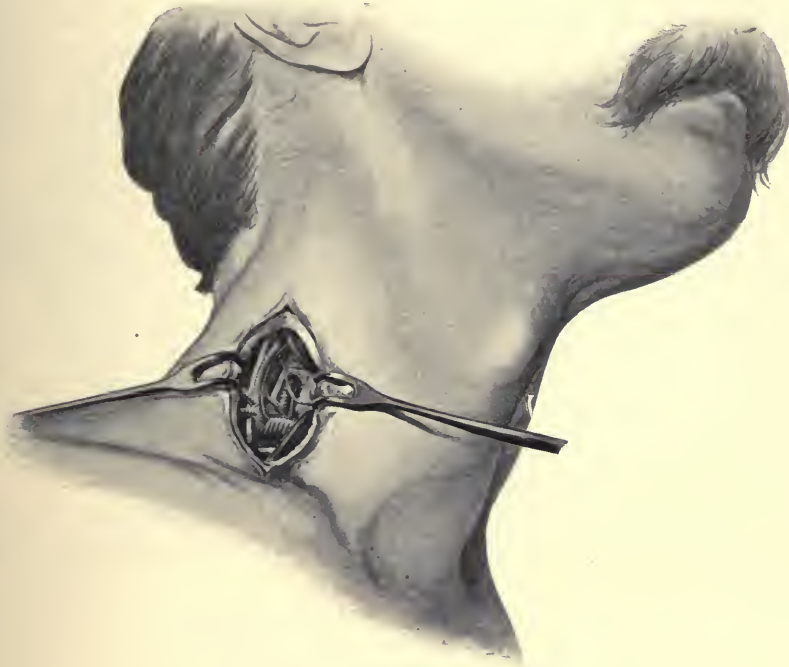


FIG. 198. LIGATURE OF THE VERTEBRAL ARTERY. The sterno-mastoid is pulled forwards and the artery is seen entering the foramen in the transverse process of the sixth cervical vertebra. It is difficult to convey an idea of the great depth at which the vessel lies.

in the wound; the artery can generally be felt deep down beneath it (see Fig. 198).

The operation is exceedingly difficult owing to the depth at which the artery is placed and to the free venous oozing. The vertebral and internal jugular veins lying directly over the artery are a great source of hindrance to the operator, and it is easy to wound the former, which, however, may be tied without hesitation. The muscles of the neck must be relaxed as far as possible, the wound widely retracted, and a powerful illumination secured. The needle should be passed from without inwards. It is said that the fibres of the sympathetic

are always interfered with in ligature of this vessel, and contraction of the corresponding pupil is usually met with when the ligature has been applied successfully.

LIGATURE OF THE LINGUAL ARTERY

Indications. (i) The artery is usually tied either *in the course of, or as a preliminary to, excision of the tongue*. In the former case the artery will be secured at or near its origin from the external carotid, and that operation will not be described here as it merely entails exposure of the artery in the wound made for the removal of the submaxillary lymphatic glands, which is a part of the operation for removal of the tongue. When the vessel is found, it is traced back to its origin and a ligature is applied to it. When, however, ligature is performed as a preliminary to removal of the tongue, the vessel is usually tied in what is called its second part, viz. the portion lying beneath the hyoglossus muscle.

(ii) Both lingual arteries are not infrequently tied in order *to restrain hæmorrhage* from a cancerous growth of the tongue, or to starve the growth by cutting off its blood-supply. In this case it is well to tie the artery in its first part, namely, near its origin from the external carotid, as thereby all its branches are cut off.

(iii) Ligature may be required for *a wound of the vessel*, such as a stab. In this case the wound should be enlarged and the bleeding points sought for and tied.

Ligature of the artery may be practised in two situations, viz. near its origin from the carotid—the so-called ‘first part’—or as it lies beneath the fibres of the hyoglossus, in the so-called ‘second part’.

LIGATURE AT ITS ORIGIN

Ligature of the vessel in its first part is practically identical with ligature of the external carotid (see p. 384), save that the ligature is applied to the lingual branch instead of to the external carotid trunk; it need not be described here.

LIGATURE BENEATH THE HYOGLOSSUS MUSCLE

Surgical anatomy. The second part of the lingual artery passes beneath the hyoglossus muscle, which separates it from the hypoglossal nerve, the lingual vein, and a portion of the submaxillary gland. It lies upon the middle constrictor of the pharynx, and its course beneath the hyoglossus is usually indicated by the hypoglossal nerve, which lies superficial to that muscle. From this part of the artery the dorsalis linguæ branch arises and supplies the back part of the tongue. In

order to make sure that this branch is controlled, therefore, the ligature must be applied quite far back, practically at the junction of the first with the second part.

Operation. The head and shoulders are somewhat raised, and the chin is turned well to the opposite side, drawn upwards, and steadied by an assistant. The surgeon stands upon the same side and makes an incision through the skin and deep fascia, commencing just below

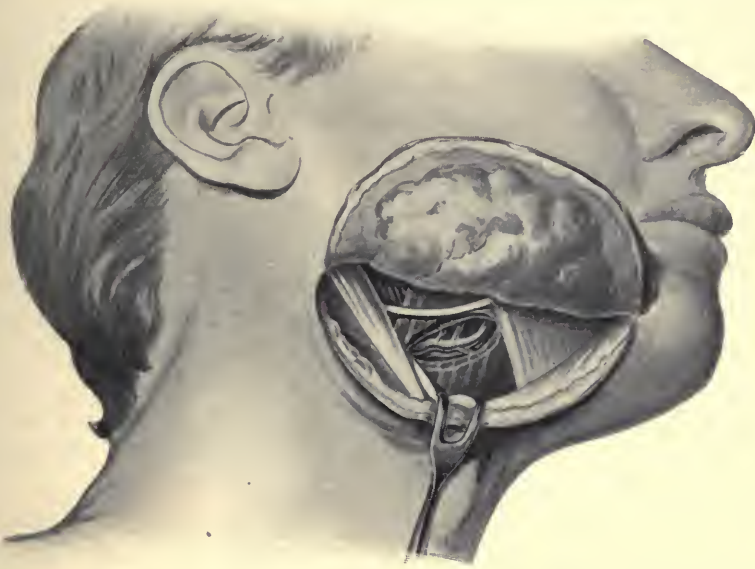

FIG. 199. LIGATURE OF THE LINGUAL ARTERY. The artery is seen through the fibres of the hyo-glossus. The hypoglossal nerve has been displaced slightly upwards.

and outside the symphysis menti, and running downwards to the hyoid bone, whence it curves upwards and backwards nearly to the angle of the jaw (see Fig. 194): in doing this, free oozing may occur from branches of the facial and anterior jugular veins which will need to be controlled. The deep fascia is divided by a horizontal incision parallel to and almost over the hyoid bone, which exposes the submaxillary salivary gland; this reaches almost down to the hyoid in the living subject, and completely so in the dead. The gland is now raised from its bed partly with the handle of the knife, and partly by a few touches of its point; the gland structure itself must not be damaged, and the skin and gland should be raised together and fastened to the cheek with a fine suture so as to avoid having to retract it forcibly in the later stages of the operation.

The digastric tendon, with the two bellies of the muscle, and the mylo-hyoid will now be seen in the front part of the wound. The fascia is cleaned from the posterior margin of the mylo-hyoid, and the digastric tendon is defined and pulled firmly downwards and backwards with a blunt hook, so as to bring into view the fibres of the hyo-glossus muscle, which run almost vertically. The hyo-glossus is crossed horizontally by the prominent hypoglossal nerve, which runs parallel to and almost over the artery, the hyo-glossus fibres, however, being interposed between the two. Below the nerve, and also superficial to the hyo-glossus, lies the lingual vein. These two structures are gently displaced upwards with a blunt hook, and the fibres of the hyo-glossus are cut through with the point of the knife immediately above and parallel to the margin of the hyoid bone. This incision is made with great care, and to a slight extent only at each stroke of the knife. The cut muscular fibres retract immediately, so that the artery is soon seen protruding through the cut (see Fig. 199); it is usually somewhat tortuous, which renders it more prominent when exposed. The needle is passed round it in whichever way seems easiest. The submaxillary gland and the skin flap are then laid down in place and sutured. If all bleeding points be secured by ligature there is no need to employ a drainage tube.

Difficulties and dangers. This operation is by no means as easy as a perusal of its steps might lead one to suppose. Amongst the chief difficulties may be enumerated:—

(i) *Too short an incision.* This is only likely to occur when the operation is not part of a complete removal of the tongue and the submaxillary lymphatic glands. The surgeon, in order to minimize the scar made by the operation, is tempted to shorten his incision by curving it upwards from the hyoid bone to the point at which the facial artery crosses the ramus of the lower jaw. It is quite possible to secure the vessel through this incision, and the short incision is often used, but it limits the access to the vessel, and good retraction and much accuracy of operating is required to enable the operator to secure the vessel satisfactorily.

(ii) *Difficulty with the submaxillary gland.* This structure extends lower down than might be thought, and, in raising it, the tendency is to cut through the gland instead of getting properly below it and lifting it out of its bed undamaged. Unless due care be exercised, not only may serious damage be done to the gland itself, but the surgeon will be much hampered in defining the structures met with, and there will be troublesome oozing which it is difficult to stop.

(iii) *Difficulty in finding the artery after incising the hyo-glossus.* The chief danger here is that the cavity of the pharynx, from which the

artery is only separated by the middle constrictor and the mucous membrane, may be opened at the first cut of the knife. There should be little difficulty in finding the artery if the fibres of the hyo-glossus be cut through little by little and separated as they are cut, and if the incision be made strictly parallel to and less than a quarter of an inch above the body of the hyoid bone.

(iv) *Wound of the pharynx in passing the needle.* This is a serious matter owing to the risk of secondary hæmorrhage from sepsis. It is, however, easily avoided. When found, as described above, the artery should be seized in forceps, when it can be stripped off the middle constrictor and traced back to the edge of the hyo-glossus, or at any rate

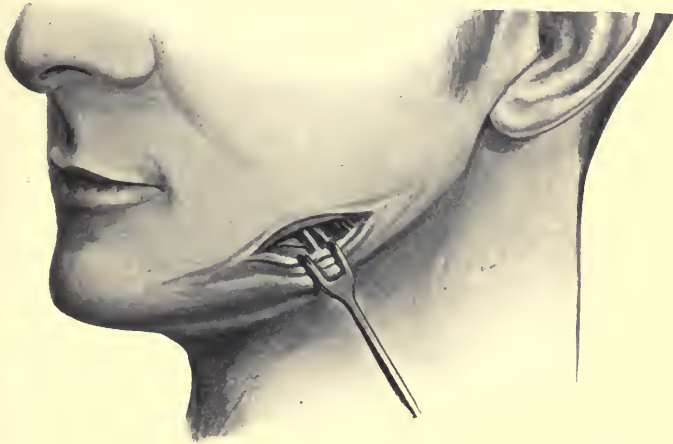


FIG. 200. LIGATURE OF THE FACIAL ARTERY. The vein is behind the artery.

to the proximal side of the origin of the dorsalis linguæ branch, where the ligature should be applied.

LIGATURE OF THE FACIAL ARTERY

This operation and the three following ones are mere dissecting-room operations and do not require extended notice.

Ligature of the facial artery is hardly ever done as a formal operation. When the artery is tied it is usually in the course of some other procedure, such as excision of the lower jaw.

It may be secured at its commencement, as already described under ligature of the external carotid artery (see p. 384), or at the point where it crosses the lower jaw—as for a wound of the face. This point corresponds to the anterior margin of the masseter, and the only thing worthy of note is that the incision should be parallel with the lower border of

the jaw, so as to avoid damage to the facial nerve. The facial artery is easily recognized by its pulsation as the wound is deepened. The facial vein lies behind the artery (see Fig. 200), and the needle should therefore be passed from behind forwards.

LIGATURE OF THE TEMPORAL ARTERY

This may be required for a wound of the scalp, the bleeding from which cannot be controlled otherwise.

The vessel is secured through a vertical incision about half an inch

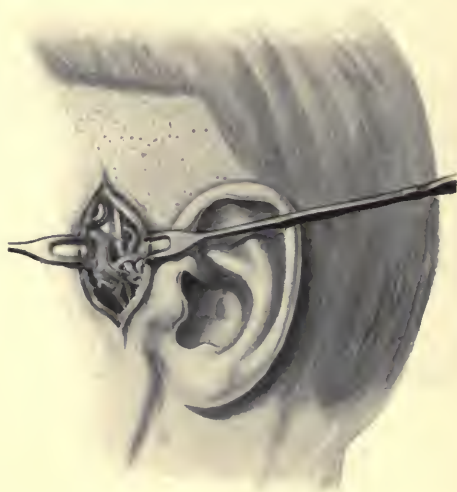

FIG. 201. LIGATURE OF THE TEMPORAL ARTERY. The auriculo-temporal nerve lies behind the artery.

in length midway between the tragus and the condyle of the jaw. There is no difficulty in the living subject, as this is one of the situations in which the pulse is usually felt. The artery is tied as it crosses the root of the zygoma, and here it is only covered by skin and fascia. The vein lies behind the artery, which is crossed by branches of the temporo-facial vein and the facial nerve (see Fig. 201). The needle should be passed from behind forwards.

LIGATURE OF THE OCCIPITAL ARTERY

This may be required for conditions similar to those requiring ligature of the temporal artery; it has been done for an occipital aneurysm. The vessel may also be tied to complete the operation for ligature of the external carotid (see p. 384). In this case the operation is similar to that for ligature of that vessel and needs no description here.

Ligature of the terminal portion of the artery. This is done through an incision about two and a half inches long, extending from the tip of the mastoid process in the direction of the external occipital protuberance. The artery, lying in the occipital groove, emerges from beneath the posterior belly of the digastric, having on its inner side the rectus capitis lateralis, which separates it from the vertebral artery. It is here under cover of the sterno-mastoid, the splenius capitis, and the trachelo-mastoid (longissimus capitis) muscles. At its termination the great occipital nerve crosses it, and the vessel either pierces the aponeurosis

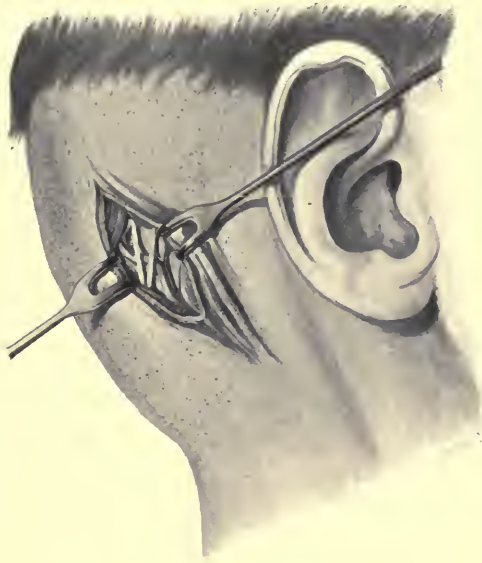


FIG. 202. LIGATURE OF THE OCCIPITAL ARTERY. The great occipital nerve crosses the vessel. The ligature is applied at the extreme lower end of the wound, where the vessel emerges from beneath the mastoid process.

uniting the sterno-mastoid and the trapezius to pass through the deep fascia, or it perforates the posterior part of the occipito-frontalis (epicranium) muscle.

The incision is deepened until the sterno-mastoid is exposed, and the fibres of this muscle are divided throughout the length of the incision, and those of the splenius identified. These are cut in their turn, with as much of the trachelo-mastoid (longissimus capitis) as comes into the wound. After the cut muscles have been retracted, the posterior belly of the digastric muscle comes into view, and the occipital artery will be seen emerging (see Fig. 202). In this situation the vessel lies upon the superior oblique and the complexus, and is about midway between

the transverse process of the atlas and the mastoid process. The needle may be passed in whichever direction seems easiest.

This operation is often somewhat difficult owing to the abnormalities in the distribution of the artery. It is common to find a considerable part of the vessel superficial to the trapezius, and it is apt to be wounded in deepening the skin incision. The wound in which the vessel is usually secured is somewhat deep, and good light and careful sponging are essential; the application of adrenalin is useful in ensuring a good view.

CHAPTER XIII

OPERATIONS UPON VEINS

PLASTIC OPERATIONS

OPERATIONS for the repair of wounds in veins are rarely required. It is seldom worth while to go to the trouble of repairing a wounded vein so as to preserve the circulation through it ; in an aseptic wound the obliteration of all but the largest veins, such as the axillary or the common femoral, is not likely of itself to give rise to more than temporary inconvenience and transient œdema ; even in these the effects of ligature are not grave. In the majority of cases of wounds of veins, therefore, there is no objection to adopting the simpler and more rapid method of ligature of the vein above and below the wound.

Indications. There are certain cases, however, in which it is certainly advisable to close a wound in a vein without arresting the circulation through it permanently. A not infrequent accident in the course of operations upon the cervical glands is an injury to the internal jugular vein, and, although it is not a serious matter to apply a ligature above and below the wound in the vein and so occlude the vessel entirely, yet it is preferable to stop the bleeding by some means that will at the same time preserve the circulation through the vein, if this can be done without undue prolongation of the operation.

There are other cases again in which the repair of a wounded vein is most important. It happens occasionally that the renal vein is torn away from the vena cava during nephrectomy. This results in furious hæmorrhage which it is difficult to stop and which it is out of the question to arrest by applying a ligature to the vena cava above and below the entrance of the renal vein. Occasionally also in pelvic operations one of the iliac veins has been wounded, and in this situation also an operation that will close the wound, and at the same time allow the circulation through the vein to remain unimpaired, is of great value.

Operation. (i) For small wounds, such as *punctures*, or for *avulsion of a tributary* close to the main trunk, it is sufficient to pick up the bleeding point in the wall of the vein and surround the opening in it with a lateral ligature. The low blood-pressure in the vein is not likely to cause dislodgement of the ligature, provided that this be tied

very tight. It not infrequently happens that, during operations upon glands in the neck, when a lateral ligature of this kind has been placed upon the internal jugular there is a recurrence of hæmorrhage ; this is generally due to an insufficiently firm ligature.

(ii) When there is a *longitudinal or transverse slit of any considerable extent*, and more particularly when a portion is sliced out of the vein, this method will not do, and the wound in the vein must be sutured. As a matter of practice it is found that almost any method of suture will do, and the one commonly employed has been a continuous running suture taking up all the coats of the vessel. The circulation is arrested on each side of the wound by digital or instrumental pressure, and the edges of the incision in the vein being held together with very fine toothed forceps, they are sewn up by the finest spring-eyed, fully curved, round intestinal needle carrying the finest obtainable catgut. The suture should begin about one-eighth of an inch beyond one end of the wound and should extend for about the same distance on the far side ; a single row of sutures is sufficient. A suture identical with Dorrance's for arteriorrhaphy (see p. 263) may be used, and is perhaps less likely to be followed by thrombosis, as the suture does not then project into the blood-stream.

ARTERIO-VEINOUS ANASTOMOSIS

This has already been described fully in connexion with the operations for reversal of the circulation of a limb (see p. 280). It has also been suggested—although, as far as I am aware, not carried out in practice—that the cure of a fusiform aneurysm might be effected by dividing the parent vessel above and below the sac and performing an end-to-end anastomosis, using as an intermediary in the gap caused by the removal of the aneurysmal sac a suitable portion of the companion vein. That this is ever likely to become a recognized operation is very doubtful, and that it is preferable to simple ligature of the artery above and below the sac is open to question. To employ the main vein for the purpose of anastomosis is very likely to result in gangrene, owing to simultaneous blocking of the artery and the vein, whereas the older operation would obliterate the artery alone, leaving the circulation in the vein unimpaired. It has yet to be shown moreover that an anastomosis of this kind, where the rough cut ends of the artery, as well as the sutures, are exposed in the blood-stream, can successfully resist the tendency to thrombosis which is well known to exist under these circumstances.

OPERATIONS UPON VARICOSE VEINS

In this connexion the operations upon varicose veins of the extremities alone will be considered. Those upon the veins of the pampiniform plexus will be considered in the section devoted to operations for the cure of varicocele; while those upon the veins of the hæmorrhoidal plexus are the operations for piles and are dealt with among operations upon the rectum.

Methods. Properly speaking there is only one operative treatment for the cure of varicose veins, namely, excision between ligatures, but the two methods by which this is done differ both in technique and in results; they are :—

(a) *Trendelenburg's operation*, or division of the internal (great) saphenous vein between ligatures applied a little below the saphenous opening,

(b) *Excision of the varices* wholly or in part, with or without removal of the internal (great) saphenous trunk.

Indications. The following facts bearing upon the operative treatment of varicose veins are gradually becoming recognized :—

(a) That excision of varices is not a radical cure of the affection; the benefit is only temporary, other veins enlarging in due course.

(b) That pronounced varices on the inner side of the leg and knee are most prone to complications, such as thrombosis, &c., presumably from their position, which exposes them to injury or irritation.

(c) That the most important factor bearing on the well-being of the subjects of extensive varicose veins is the competency or otherwise of the valves in the saphenous vein. As long as these are doing their work efficiently there is only slight discomfort and possibly the risk of traumatic complications, but when they cease to act satisfactorily, sensory and circulatory troubles are prone to set in.

A consideration of the above facts leads to the conclusion that the following groups of cases are most suitable for operation :—

(i) Those in which there is insufficiency of the valves, as shown by the test introduced by Trendelenburg. To do this, the limb is emptied of blood by elevation, and pressure is made upon the saphenous opening until the patient resumes the upright position. If then the vein fills rapidly immediately the pressure on the saphenous vein is removed, it may be taken for granted that the valves are insufficient to hold up the column of blood in the vein.

(ii) Chronic ulcers of the leg in subjects of varicose veins. Here the operation is done with the object of removing the constant congestion and thereby facilitating rapid healing.

(iii) Serious hæmorrhage either from a vein that has burst or from one in the wall of a chronic ulcer that has ulcerated through.

(iv) Localized varices limited to one area of the limb but unaccompanied by swelling of the foot or marked pain. Here the operation is generally done to enable the patient to enter one of the public services.

(v) Prominent varices in a region, such as the inner side of the knee, preventing the patient from following some particular calling or exercise, such as riding, &c., in which the varices would be exposed to injurious pressure.

In all but the two last groups of cases, which however are large, the operation of choice will be that known as Trendelenburg's, or division of the internal (great) saphenous vein below the saphenous opening, whilst in the two last groups the chief object of the operation will be to remove the actual varices, and this may or may not be combined with Trendelenburg's operation. Personally, I always do Trendelenburg's operation at the same time as I remove those varices which are exposed to pressure or injury about the inner side of the knee and upper part of the leg.

Operations. Trendelenburg's operation is extremely simple and only occupies a short time, whereas the operation for the removal of the individual varices is often extremely difficult and tedious, not infrequently lasting two hours or more. In cases such as these it is well to remember that the operation can be done satisfactorily under the infiltration method of local analgesia (see p. 36).

Preliminary purification. In all these cases there are two points of great importance to be remembered. The first is that the most scrupulous care must be bestowed upon the aseptic precautions, as suppuration in the neighbourhood of these large veins would be a disaster of the first magnitude, and it is very easy to go wrong in this matter owing to the length of time consumed in the operation, and the various manipulations of the limb that are often required to get at the field of operation properly. The entire limb should always be shaved from the groin to the foot and thoroughly purified back and front. The foot should be wrapped up in a sterilized towel and by it all the movements of the limb should be made. The surgeon should confine himself as much as possible to the use of scalpel and forceps, and should handle the wounds as little as possible.

Mode of identifying the veins. The second point is to remember that it may be most difficult to identify the affected veins on the operating table, especially when excising local varices, unless some special means have been taken to facilitate this. There are several ways of doing this. The patient is made to stand up after the limb has been

purified and before the overnight compress is put on, and, as soon as the veins have become fully prominent, they are marked out either with an aniline pencil dipped in a sterile solution, or by a solution of nitrate of silver (60 gr. to the oz.) painted on with a fine camel's-hair brush and allowed to dry; in the course of twelve hours this causes an indelible brown stain upon the skin. If the stain has not appeared at the time of the operation next morning it may be developed by brushing over the surface with a solution of pyrogallic acid. This nitrate of silver method is an excellent one, and leaves a stain that no purification on the operating table will eradicate. The aniline pencil-mark, on the other hand, although it is indelible as far as the overnight compress is concerned, gets washed out during the process of purification on the operating table, and in order to avoid this when aniline markings have been used I always mark in the proposed incisions lightly with a touch of the knife before the final purification is begun; the bleeding scratches thus made cannot be overlooked when the purification has been completed.

Trendelenburg's operation. An incision about three inches long is made over the line of the internal (great) saphenous vein, which can always be felt or seen before the operation sufficiently well for it to be marked out. The vein is exposed and dissected free from nerve filaments and surrounding fat, and a ligature is applied to it about two inches below the saphenous opening. A second ligature is applied two or three inches lower down and the intervening portion of the vein is removed; the wound is sewn up without a drainage tube. Fine chromicized catgut is the best material for ligature.

Excision of varices. As far as possible the incisions should be planned to take in venous junctions so that each incision may remove portions of more than one vein. There is no necessity to make long incisions except when it is desired to reach several junctions from one incision or when only a single group of veins, such as the internal (great) saphenous and its tributaries, is affected, in which case a long incision will block the venous return from a large area. Even here, however, incisions about two inches long are sufficient, and with them there is less danger of damaging the sensory nerve-supply; as a rule they should be made directly over the vein that is to be removed. Occasionally, however, it will be better to turn back a flap and remove a mass of veins from beneath it; this is advisable in the case of varices and their tributaries which are collected into large whorls or bundles. This method, however, is not advisable if it can be avoided, as the varices frequently thin the skin over them so much that the nutrition of the flap may be interfered with in raising it.

The skin incision should be deepened with care, as it is important to avoid wounding the veins if the surgeon wishes to do the operation as expeditiously as possible. In order to render the field of operation bloodless he may, if he chooses, use an Esmarch tourniquet, but this should be avoided, except when it is absolutely necessary, on account of the oozing that follows its removal and the possibility of thrombosis of the veins at its point of application. Blood collecting in these wounds is likely to give trouble subsequently, and therefore the use of the tourniquet should be restricted to the rarer cases in which it is essential to raise a flap and remove a mass of tortuous veins occupying a large area, and from which the bleeding would otherwise be very profuse before the main branches could be secured.

The enlarged veins are connected to the skin by a series of fine fibrous bands, which require division with the point of a very sharp knife. The least possible handling of the skin should be practised; very fine toothed forceps are best for this purpose. As soon as the skin has been separated from the vein, the remainder of the operation is easy, a few strokes with a blunt dissector or the point of the knife sufficing to isolate the vein and its tributaries from the surrounding fat. No attempt, however, should be made to effect this separation with any blunt instrument until the skin and its fibrous processes have been properly dissected off the vessel. The upper end of the main vein should be isolated first, picked up and clamped close up to the upper end of the skin incision in two pairs of forceps and divided between them. The portion of vein to be removed is then raised by taking hold of the lower pair of forceps and putting the vein on the stretch; this renders all its tributaries apparent, and enables them to be dissected cleanly from the surrounding structures and clamped and divided in turn so that the whole portion of the vein is dissected downwards and removed; it is important to effect the separation of the veins from the surrounding structures cleanly, as otherwise cutaneous nerves may be tied in with the vein and the patient may suffer considerably.

When all the branches have been clamped and divided, the lower end is clamped and the entire mass is removed. Fine chromicized catgut ligatures are now applied to the clamped ends, and it is a point of some practical importance to see that the knot of the ligature is turned towards the deep surface of the wound, so that there is no risk of the cut ends of the ligature projecting from the skin wound when the latter is sewn up. Owing to the thinness of the skin and the proximity of the veins to it, this troublesome little accident is very likely to occur unless special pains be taken to avoid it. Another small point of practical importance is to dissect the skin up for a short distance

above and below the ligatured ends of the veins, so that the catgut lies well hidden beneath the skin. If the ligature projects from the wound it always comes away later on and will thus prolong convalescence. If the steps described above are carefully followed, the operation can be done almost bloodlessly.

It is well not to sew up the wound at the time it is made, but to cover it with a piece of sterilized gauze and to proceed to remove all the rest of the veins that it is desired to excise before sewing up any of the wounds. This enables one to see whether there are any other bleeding points that require ligature, and ensures a perfectly dry wound at the end of the operation, when all the incisions are sewn up *seriatim* in the order in which they are made. No drainage tube is required, but it is most essential to see that the wound is dry before it is sutured. It is well to use fine silkworm-gut, horsehair, or Michel's sutures, as they are all non-absorbent, and even slight staphylococcic infection from the skin may lead to serious consequences.

Occasionally it may be necessary to excise a large mass of veins that have so thinned the skin over it as to endanger its vitality when raised as a flap, and in these cases it may be necessary to plan the skin incision so that a certain portion of the skin may be excised and the wound brought together afterwards. Under such circumstances it is well to employ a tourniquet, as the veins are certain to be wounded during the operation, and otherwise there will be so much oozing, that it will be very difficult to see the condition of the parts, and a good deal of unnecessary damage may be caused. After the dressings have been applied, the knee should be kept steady between sand-bags and more or less fixed; it is not necessary to employ a splint unless the patient is restless.

After-treatment. The stitches should be removed about the eighth day and a collodion dressing applied. The patient should be kept in bed for a fortnight and should spend the following week on a couch; at the end of that time he may walk about.

VENESECTON

Indications. For any condition accompanied by engorgement of the right side of the heart. The operation is rarely practised at the present day, but it has a definite sphere of usefulness, and in many cases is of the highest value. In diseases like chronic bronchitis accompanied by over-distension of the right side of the heart and intense engorgement of the systemic venous system, venesection may act like a charm by mechanically removing this undue pressure, and may thus enable the patient to tide over the critical stage of his illness.

Operation. Slight as it is, this operation must be done skilfully in order to ensure a satisfactory result. As a rule no general anæsthetic is permissible, and it is not even necessary to use any local analgesia (see p. 36); but there is no objection to the use of local infiltration should the surgeon desire it, although it must be remembered that the proper performance of the operation depends very largely upon the accurate definition of the vein, and that any subcutaneous œdema will obscure the parts. The patient should be in the semi-recumbent position so that he may be readily laid flat should he be faint. In no case should venesection be performed with the patient in the upright position.

In order to render the veins prominent a single loop of bandage or broad tape is fastened moderately tightly around the middle of the upper arm in order to compress and distend the cutaneous veins. In order to effect this object still better the patient is made to clench his hand firmly or to grasp some moderate-sized object firmly in it. This renders prominent all veins in the forearm. The vein selected is usually the median basilic, because of its large size and superficial position. Venesection is hardly ever done in any other situation except at the bend of the elbow; in former days it was frequently practised at the ankle and on the temporal and external jugular veins.

The region of the median basilic is thoroughly purified in the ordinary manner, and the surgeon places his left thumb immediately below the spot at which he is going to incise the vein. This is done with two objects, viz. to steady the vein during the incision, and to enable the thumb to be slipped over the incision immediately it is made, and thus to check the outflow of blood until the lancet is put down and the bleeding-bowl is in position. The incision is made with a fine double-edged lancet, grasped between the thumb and forefinger close to its point and steadied by resting the right hand upon the left thumb. This is a necessary precaution, as the incision into the vein must be judged to a nicety, otherwise it is quite easy to make the incision either too superficial, in which case the vein is not opened, or too deep, in which case both walls of the vein may be transfixed, the bicipital fascia beneath divided, and the brachial artery itself wounded; this was a common accident in former days and was the cause of the arterio-venous aneurysms that were so frequently met with in this region.

The incision should open the vein at the first attempt and should divide its anterior wall parallel with its long axis and in the middle of its anterior aspect. The left thumb is at once placed over the opening, the lancet is put down, and the vessel into which the blood is to be received placed beneath the limb; the limb is then turned over so that the opening in the vein is downwards and the thumb is taken off the incision. After

the requisite amount of blood, which varies from six to twelve ounces or more, has been removed, a small gauze pad is fastened firmly over the opening in the vein, the bandage round the arm is removed, and the patient should carry his arm in a sling for a few days until the wound has healed. The bandage round the arm should be fastened by a slip-knot so that it can be easily pulled off with one hand, and the gauze pad over the incision may be fastened in position by a piece of broad tape passing around the elbow-joint in a figure-of-eight.

INTRA-VEINOUS INFUSION

At the present time it is the custom to inject sterilized normal saline solution into the veins for certain conditions. Formerly blood, either in its ordinary state or defibrinated, was used for this purpose. This method fell largely into disuse, but the plan of injecting defibrinated blood and even human serum intra-venously is now looked upon with favour in certain quarters. This is, however, not the place in which to discuss the merits of the various fluids used for intra-venous injections.

Indications. (i) *Hæmorrhage.* The condition which, above all others, is suited for intra-venous injection is severe hæmorrhage. It would appear that when a certain proportion of the blood in the body has been lost, the heart's action fails mainly for want of fluid upon which to contract, and that if the fluid be supplied, whatever be its nature, the heart's action will be maintained. It is common knowledge with every surgeon of experience that many lives have been saved by the judicious use of intra-venous injection for severe hæmorrhage.

A caution may, however, be given in this connexion, namely, that intra-venous infusion should never be used for the relief of severe hæmorrhage unless the source of bleeding that has called for the remedy has been secured. In severe hæmorrhage the blood pressure falls so low that at last spontaneous arrest of the bleeding occurs, and to raise the blood pressure without securing the bleeding point merely serves to cause the bleeding to commence afresh, and so to lose more of the already insufficient amount of blood that the patient possesses. I have lost patients solely from this cause, and if it be impossible to secure the bleeding points I should prefer to trust to the chance of thrombosis by natural processes rather than run the risk of raising the blood pressure by infusion and causing the hæmorrhage to recur.

(ii) *Shock.* Intra-venous infusion has been largely used in shock and is much recommended by some. Its action, however, is uncertain, and it is doubtful whether it is really good for uncomplicated cases of shock. In any case it seems to offer no advantages over the method of infusion by subcutaneous or rectal injection. It is certainly more rapid in its

action, but the patient will rarely be allowed to fall into such a profound state of shock as to necessitate recourse to this operation without subcutaneous infusion having been previously tried. The more gradual absorption of the fluid from the subcutaneous tissues seems to minimize shock better than the injection of large quantities into the systemic circulation; such a procedure must dilute the blood largely and render its oxygenation deficient.

Operation. The vein usually chosen is the median basilic. It is exposed by a cut directly over it, and is rapidly separated from the surrounding tissues with a blunt dissector for a distance of three-quarters of an inch or more. The patient will generally be under an anæsthetic when this is done, but if not, an anæsthetic will hardly be necessary,

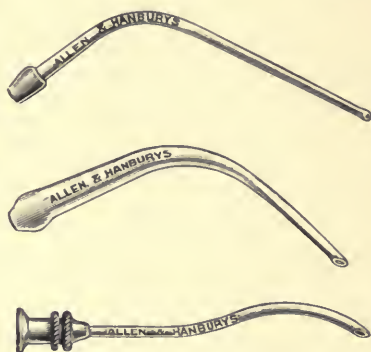


FIG. 203. CANULÆ FOR INTRA-VEINUS INFUSION. These are blunt-pointed and may be made of glass, silver, or steel.

as the condition will be so grave that sensation is largely abolished. An aneurysm needle carrying a double ligature of catgut is passed beneath the vein, and the two ligatures are separated, one being drawn to the lower end of the vein, the other to the upper. An incision is made in the anterior wall of the vein large enough to admit the nozzle of the fine canula which is sold for the purpose (see Fig. 203). This is introduced with its nozzle pointing towards the heart, that the stream of fluid from it shall be in the same direction as the venous flow. The upper ligature is tied around the point of the canula, and the lower one is tied around the vein below the incision and its ends cut short. The sterilized normal saline solution at the body temperature, which may contain about a drachm of adrenalin chloride (1 in 1,000), is now run into the vein, taking great care to see that there are no air-bubbles in the apparatus. The infusion should be made quite slowly, the receptacle being raised only slightly above the level of the heart. The amount introduced is

regulated by the effect of the infusion upon the pulse. As a rule at least two pints may be injected before any marked alteration can be detected, but after this amount has been introduced the pulse becomes slower and improves in volume. As a rule about three pints are usually sufficient for cases of bad hæmorrhage or severe shock. When the infusion is being practised for the relief of shock, it is a good plan to leave the canula and apparatus in position, as it may become necessary to repeat the injections fairly frequently, it may be every two hours, since the effect of the infusion may pass off rapidly and the symptoms recur. In cases of hæmorrhage, however, it is not as a rule necessary to repeat the infusion, and the canula may be withdrawn and the upper end of the vein permanently ligatured.

Difficulties. The chief difficulty in the operation is to identify the vein in the collapsed condition in which it always is in cases either of severe hæmorrhage or bad shock. It is often impossible to distend the veins sufficiently to identify them, and perhaps the best plan is to cut transversely across the direction of the median basilic and thus divide the vein completely. The two open ends can then be seen in the wound, the lower one tied, and the point of the canula introduced into the upper one and secured there.

CHAPTER XIV
OPERATIONS UPON THE LYMPHATICS
SUTURE OF THE THORACIC DUCT

ON several occasions the thoracic duct has been wounded in operations for the removal of tuberculous or malignant glands at the root of the neck on the left side. The accident can be recognized at once by the steady oozing of milky chyle into the wound. A similar accident may happen to the lymphatic duct on the right side.

Operation. Attempts have been made to close the wound with a fine catgut suture, and this of course is quite the ideal operation; it is similar in all respects to suture of a vein (see p. 398). On the two occasions upon which I have wounded the duct I have found that a perfectly satisfactory result has followed simple closure of the wound in the soft parts without attempting to suture the wound in the vessel. It was so difficult to make out structures when chyle was welling up into the wound, that I found it impossible to suture. It is a good plan to put in one or two deeply buried catgut sutures so as to obliterate any space in which chyle might accumulate. In some of the earlier cases it was found that simple closure of the wound was followed by a soft fluctuating swelling which persisted for some little time but which eventually disappeared. This did not occur in either of the cases in which I brought the deep tissues of the wound together with buried sutures. It is unnecessary to remark that the greatest care must be taken in securing asepsis in wounds of this sort, but if that be granted there is no difficulty at all.

LYMPHANGIOPLASTY

This term is applied to a method of artificial drainage for cases in which the lymphatic system of a limb has become blocked, introduced by Mr. Sampson Handley (see *Lancet*, 1908, vol. i, p. 783). It consists in making artificial capillary drains by means of long strands of sterilized silk threaded through the subcutaneous tissues by means of a long-eyed probe.

Indications. The cases for which this operation was introduced were those of brawny arm following recurrent cancer of the breast,

but it would seem that, if the operation stands the test of time, it has a wider field of usefulness. Thus it would appear worth trying in cases of white leg, and also in the œdema following typhoid fever, and possibly in cases associated with elephantiasis. It is also possible that it might be used with success as a means of draining the peritoneal cavity into the subcutaneous tissues of the abdomen or chest in cases of ascites, although, as far as I am aware, this has not yet been put into practice. I have tried silk on several occasions as a drain between the lateral ventricles and the sub-dural space in cases of hydrocephalus, but hitherto without success. The brain substance appears to choke the silk and destroy its capillary action after a short time. It will be interesting to see how long silk will retain this function in the subcutaneous tissues.

Operation. A small incision is made through the skin near the extremity of the limb, and from this a long probe is thrust through the subcutaneous tissues as far up the limb as it will go; its point is then cut down upon and made to emerge through this second opening in the skin. One or more pieces of silk, each as long as the entire limb, are then threaded into the eye of the probe, which is pulled out through the second opening, thus drawing the silk through the subcutaneous fat from the first to the second opening. The end of the silk emerges from the first opening and is temporarily fixed there in forceps to prevent it being pulled up into the subcutaneous tissues. The probe is then introduced through the second opening, thrust up the limb as before as far upwards as it will go, and a third incision is made upon its point. Through this incision the probe is drawn out, still carrying the silk, and this process is repeated until finally the end of the probe emerges at the upper extremity of the limb, over the pectoral region in the case of the upper arm, or the abdominal wall in the lower limb. This leaves the silk thread in the subcutaneous tissues with its ends emerging from the first and last apertures in the skin respectively. The ends of the silk are then pushed down in the wounds, and all the small incisions are closed by suture, the silk remaining permanently embedded. A number of these threads may be introduced around the circumference of the limb by making fresh incisions in a similar manner.

These operations have been very successful in some cases, the permanent œdema disappearing rapidly, and a useless limb becoming useful once more. It is interesting to note that, in one case reported by Mr. Handley, paralysis, which had been present before the operation, passed off after the œdema had diminished considerably. The agonizing pain so often complained of in these cases is relieved in a very short time.

SECTION V
OPERATIONS UPON NERVES

BY

FRED^c. F. BURGHARD, M.S. (Lond.), F.R.C.S. (Eng.)

Teacher of Operative Surgery in King's College, London; Surgeon to King's
College Hospital; and Senior Surgeon to the Children's Hospital,
Paddington Green

CHAPTER I

NERVE SUTURE : PLASTIC OPERATIONS UPON NERVES

NERVE SUTURE

NERVE suture is required for a number of conditions, and the operations for its performance are usually divided into (i) those in which a nerve is sutured immediately after it has been divided, when the operation is called *primary nerve suture*, and (ii) those undertaken some time after the division of the nerve, when the operation is called *secondary nerve suture*. These two operations will be described separately. In connexion with either of these operations nerve-grafting may be performed; for the sake of clearness, however, it will be better to describe this separately.

PRIMARY NERVE SUTURE

Indications. Nerve suture may be required :

- (i) For the repair of wounds of nerves, either incised or due to gunshot or similar injuries.
- (ii) For the repair of a nerve from which a portion has been excised, *e.g.* in the removal of a tumour. This may call for nerve-grafting.
- (iii) For the repair of a nerve accidentally severed during an operation, *e.g.* the spinal accessory in removal of tuberculous cervical glands.
- (iv) For the repair of a subcutaneous laceration of a nerve, *e.g.* in cases of fracture.
- (v) In the operation of nerve-grafting or nerve-implantation.

Operation. With the exception of the last two conditions enumerated above, the latter of which is dealt with separately (see p. 425), the operation is concerned solely with the steps necessary for the suture of the divided ends, as these will be already exposed in the wound, except possibly when a nerve has been severed by a stab or a bullet wound, in which case the wound must be opened up and the divided ends of the nerves exposed.

The greatest care must be taken to ensure asepsis throughout, as septic infection is fatal to a successful result and is probably largely responsible for the ill success that attended these operations in former days.

The method of suturing nerves. In connexion with primary nerve suture it will suffice to describe only those cases in which the divided

ends can be brought together without undue tension, reserving for consideration under the heading of plastic operations upon nerves or nerve-bridging (see p. 418) those cases in which a gap remains that must be bridged artificially. The most common lesion met with in practice is simple transverse division of the nerve demanding an end-to-end union; much more rarely the nerve is divided obliquely and the union will be by lateral suture.

For a successful *end-to-end suture* there are three chief requisites. The first is that there shall be no tension upon the line of union; the second, that there shall be no risk of lateral displacement; and the third,

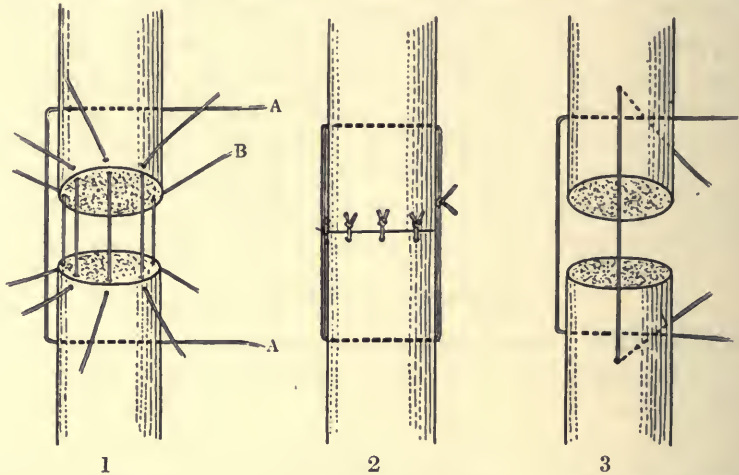


FIG. 204. SIMPLE END-TO-END SUTURE OF A NERVE. The cut ends are brought together by the tension sutures, A, and more accurately adjusted by the coaptation sutures, B, which only penetrate the sheath of the nerve. In 1 and 2 only a single tension suture is employed. In 3 there are two which are introduced at right angles to each other.

that the limb shall be fixed after the operation so that there is no risk of the sutures being torn out of the nerve by any violent muscular action. The method illustrated in Fig. 204 is the best with which I am acquainted. Two types of suture are used, one the tension suture, A, which transfixes the whole thickness of the nerve well above and below the line of suture and serves to take off all tension from the second type of suture, B, the coaptation suture.

The tension sutures should be of moderately fine catgut (No. 000), and should be as few as possible in number consistent with safety. For small nerves, such as the spinal accessory, none are needed unless the nerve has been dissected out in the anterior triangle and isolated, when a single very fine one will suffice. For the ulnar a single one is sufficient, while for the median or musculo-spiral two may be required, and for

the sciatic three. They should be introduced not less than half an inch away from the cut end, and are mounted on round intestinal needles, straight or curved according to the exigencies of the case. If a single suture be used it may traverse the nerve antero-posteriorly or laterally at the option of the operator; if two be employed it is a good plan to pass one in each direction, as this steadies the ends excellently (see Fig. 204). During the introduction of these sutures the manipulation of the nerves should be of the most gentle description; very fine toothed forceps should catch hold of the nerve sheath only. While the sutures are being tightened the limb should be put in the position in which it will be fixed at the end of the operation, viz. the one that will ensure the most relaxation of the sutured nerve, and it must be kept in that position

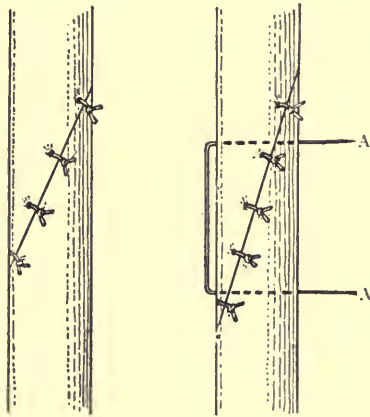


FIG. 205. LATERAL SUTURE OF A NERVE. As a rule the simple coaptation sutures shown in the left-hand figure suffice. If a tension suture be inserted it will be passed as shown in A in the right-hand figure.

until it has been so fixed. The suture is tightened so as to approximate the divided ends without the least tension.

When these sutures have been fastened the coaptation sutures, B, are inserted. These are of the finest obtainable catgut inserted with fine spring-eyed fully-curved round intestinal needles. They go through the nerve sheath only and are inserted about an eighth of an inch from the line of union. As their function is merely to prevent lateral displacement a few will suffice, which need only go about two-thirds round the circumference of the nerve; none need be inserted on the posterior aspect.

It now only remains to close the wound and fix the limb. Great care must be taken to tie all bleeding points, as a dry wound is essential to success. A few fine buried catgut sutures should approximate the adjacent soft parts around the line of junction. This keeps the nerve in its

natural channel and prevents the accumulation of blood around the seat of anastomosis. No drainage tube should be used.

The limb may be put up in the desired position in plaster of Paris, but a better plan is to mould a malleable iron bar to the limb and fasten it on with plaster bandages. This allows the after-treatment to be carried out without disturbance of the limb.

When a *lateral suture* is to be made, it will rarely be necessary to use any tension sutures; at the most only one will be required, and this should be introduced as shown in Fig. 205.

After-treatment. The dressings may be left undisturbed and the position of the limb unchanged for from ten to fourteen days. From that time onwards the position of the limb is gradually altered by slightly increasing the angle at which it is put up, until in about twelve days its normal position has been reached. From this time onwards nothing more is essential, as the functions of the nerve should return gradually. Matters may be hastened a little perhaps by daily massage to the muscles, if any, supplied by the nerve, and the application of the galvanic current over its course.

Results. The results of primary nerve suture depend so much upon the skill and accuracy with which the operation is performed that it is difficult to do more than summarize one's own experience, since there are many fallacies in the statistics of recorded cases. Unfortunately one's experience of these cases is limited, as most cases of primary nerve suture are done for cut wrist and similar injuries, which are usually sutured directly by the medical man who first sees them. Judging, however, from my own experience, it would seem that the results should be uniformly good so long as the accident is recognized and properly repaired at the time. The time taken for the recovery of function varies a good deal. Patients frequently state that they begin to have restoration of sensation immediately after the operation, but this is to be explained on other grounds. Recovery seems to set in from about six to eight weeks after suture and is complete in from three to four months after such an injury as division of the nerves at the wrist.

SECONDARY NERVE SUTURE

Indications. (i) For the repair of a divided nerve which has been allowed to go unsutured for some time.

(ii) For the repair of a nerve in which primary nerve suture has been done unsuccessfully.

This operation differs from primary nerve suture in several points. After a short time changes take place in the divided ends of the nerves which necessitate their being resected before they can be sutured, and,

moreover, a certain amount of retraction and displacement of the divided ends nearly always occurs. As a result of these two factors it will be difficult to place the freshened ends in apposition without undue tension, and therefore special means will have to be adopted to secure this end. Some method of plastic operation will often be necessary.

Operation. As some time will have elapsed since the receipt of the injury, it will be necessary to cut down and expose the nerve. If possible this should always be done above the seat of injury, as then the nerve will be exposed where it is normal and can be traced down to the point at which it has been divided. It is bad practice to try and dissect down through any cicatrix that may be present, as this is sure to lead to confusion and may end in serious damage. In the succeeding chapters will be found directions for exposure of all the chief nerve trunks. The operation must be done with scrupulous regard for asepsis, as suppuration is fatal to success.

Identification of the ends. After the nerve has been exposed above the seat of division it must be traced down to the seat of injury. This may be very difficult when there is much cicatricial tissue, and, under these circumstances, an Esmarch bandage is most useful. This should not be used, however, unless it is actually necessary, and in any case it should be removed as soon as the ends of the nerve have been identified, so as to minimize the oozing that always follows its use.

The upper or central end will be found first. It is always somewhat bulbous and should be dissected out clear of the scar tissue until its bulbous end is quite free. Then the distal or peripheral end must be found, and this is often a harder matter still, as it is thinned and pointed and much scar tissue may have to be dissected away before it is reached. Its end is freed from the surrounding tissues.

Preparing the ends. Since the plastic operations upon nerves are described separately (see p. 418) we shall assume in this case that the ends of the nerve, when freed from the surrounding tissues, will come together satisfactorily without the need of anything further than the assumption of a suitable position of the limb. The next point is to prepare the ends for suture. Both will need to be refreshed, but, whereas the lower one only will require a mere slice to be removed from the cicatricial tissue on its surface, the upper end must have its bulbous extremity pared away before it can be sutured successfully. The section should be made with a very sharp knife and bruising of the nerve structures must be avoided.

Suture of the ends. The ends are now brought into apposition and secured by suture. The steps of this part of the operation and the *after-treatment* are identical with those of primary nerve suture (see p. 413).

PLASTIC OPERATIONS UPON NERVES

In this category are included two different classes of operation, which, however, resemble each other closely in some of their steps and also occasionally in their aims. The first group are the true *neuroplastic* operations designed to fill in a gap between the divided ends of a nerve that is too wide to be obliterated by simple approximation of the ends. These will be termed 'nerve-bridging' operations. The other includes the true grafting methods by which one nerve which is paralysed from injury or disease is implanted or grafted into another which is physiologically sound, with the object of making this nerve perform the functions of the paralysed one, either in addition to or instead of its own. These latter operations have been steadily assuming increased importance of late years for the cure of various paralyses of long standing, and may justly be called 'nerve-grafting' operations.

NERVE-BRIDGING

Indications. The operation is called for when, in the course of an operation for primary or secondary nerve suture, there is a gap between the divided ends that cannot be obliterated by direct approximation of the distal and proximal segments.

Although the experiments of Münzer and Fischer (*Neurolog. Centralbl.*, March 16, 1906), and Kilvington (*Brit. Med. Journ.*, June 13, 1908), show that spontaneous regeneration can occur across a gap without any artificial aid provided that the distance between the divided ends does not exceed three-fourths of an inch, yet it is not wise to trust to spontaneous bridging in any case where there is a gap, however narrow. Means should always be taken to connect them artificially, as restoration of function is more rapid and complete under these circumstances.

There are a great number of methods in vogue for nerve-bridging, and it is difficult to classify them with clearness and accuracy. Two large groups may be distinguished:—

(1) Those in which the gap is small enough to be closed by slips derived from the nerves concerned or by strands of catgut. For the sake of clearness these may be termed **Plastic methods**, and may be further subdivided into (a) the *autoplasmic methods*, in which slips from the nerves themselves are used, and (b) the *heteroplasmic methods*, in which catgut or some similar foreign material is used to close the gap.

(2) The second large group contains those cases in which the gap is so wide as to need a suitable length of nerve or other living tissue to be grafted into it to form the bridge. As these grafts cannot be derived from the damaged nerves themselves they must be transplanted into

the gap from elsewhere. They may therefore be termed the **Transplantation methods**. Kilvington (*loc. cit.*) quotes Merzbacher (*Neurolog. Centralbl.*, Bd. xxiv, 1905) as subdividing this group into three:—

1. *Auto-transplantation operations*, where the nerve thus transplanted is obtained from the subject of the lesion.
2. *Homo-transplantation operations*, in which the nerve is obtained from an animal of the same species.
3. *Hetero-transplantation operations*, where the nerve is obtained from an animal of a different species.

As Kilvington rightly points out, this classification should be extended still further by splitting each of the three subdivisions mentioned above into two smaller groups, the first containing those in which the bridging is done with nervous tissue, the second in which it is done with non-nervous tissue, such as fascia, muscle, &c. Bridging with foreign materials such as catgut is included under the plastic methods. Although this classification is academically correct, it is never likely that nerve-bridging with any form of living tissue derived from another animal will be put into practice. The non-nervous form of bridging would only be done in man; if no nerve from another animal were available it might be necessary to use the patient's own non-nervous tissues, but non-nervous tissue would never be taken for this purpose from another human being or from one of the lower animals.

The following table represents the various ways in which nerve-bridging can be carried out:—

1. Plastic methods	{	Autoplastic—	with nerve.
		Heteroplastic—	with foreign material.
2. Transplantation methods	{	Autoplastic	{
			with nerve from patient.
			with fascia, fat, muscle, &c., from patient.
		Homoplastic	{
			with nerve from animal of same species.
			with fascia, &c., ditto (rare).
		Heteroplastic	{
			with nerve from animal of different species.
			with fascia, &c., ditto (rare).

As a rule the choice will be made between the heteroplastic form of the plastic methods or one of the transplantation methods, either catgut or a nerve from one of the lower animals being made use of. The bone has been resected in order to approximate the divided edges of a nerve, but this is hardly likely to be done at the present day.

The following operative procedures will be described: (i) autoplastic

nerve-bridging, (ii) heteroplastic bridging with foreign (non-living) material, and (iii) bridging with nerve tissue.

Autoplastic nerve-bridging. In this method the divided nerve ends are approximated by cutting slips from one end or both and reflecting them into the gap, where they are sutured. One end of the slip is made to retain its connexion with the end of the nerve from which it is derived.

Indications. Speaking generally, it may be said that this auto-

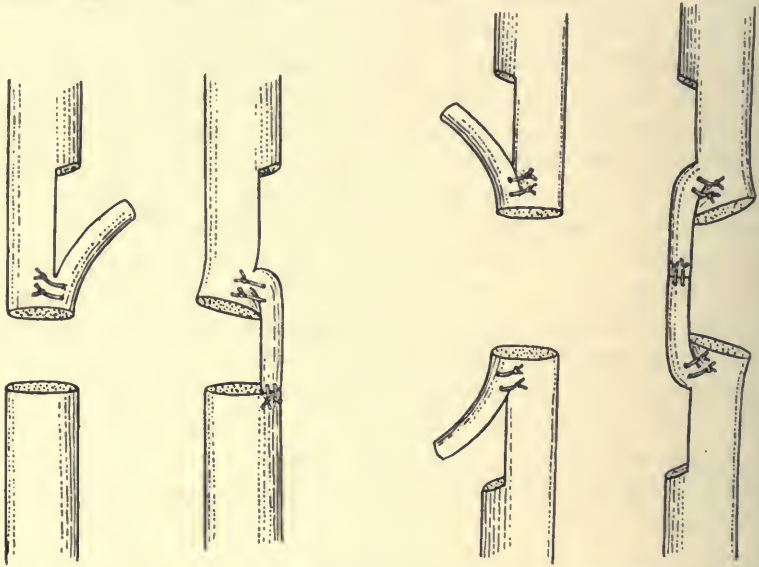


FIG. 206. NERVE-BRIDGING BY REFLECTED SLIPS. The diagrams explain the methods. The sutures at the angle of reflection are to prevent the slip being torn away from the parent trunk. The right-hand figures show the method by double reflected slips.

plastic method is most suitable for large nerves in which the gap does not exceed three-quarters of an inch. In small nerves with wide gaps the slips become mere wisps of tissue and functionally are little better than catgut.

Operation. Fig. 206 shows how this detachment of slips can be effected. The method is very similar to that for the union of tendons. The section of the nerve should be made with a very sharp knife, and the slip will generally be detached from the upper or central end of the nerve, which will be larger and in better functional condition than the lower. Sutures must be inserted at the angle of reflection of the slips to prevent the latter being torn away from the parent nerve.

Heteroplastic nerve-bridging. In these operations the gap is

bridged by strands of catgut either alone or in combination with reflected slips or a protective tube.

Indications. This type of operation is best suited for cases in which the gap is moderate—say not more than two inches—and no nerve from elsewhere, either in the patient himself or from one of the lower animals, is available. It should give place to the method of bridging with living tissues when the gap is wider than this.

Operation. The nerve ends, which must be properly freshened if



FIG. 207. NERVE-BRIDGING BY STRANDS OF CATGUT. Very fine catgut only should be used, as the nerve fibrils must be damaged by the passage of the needle.

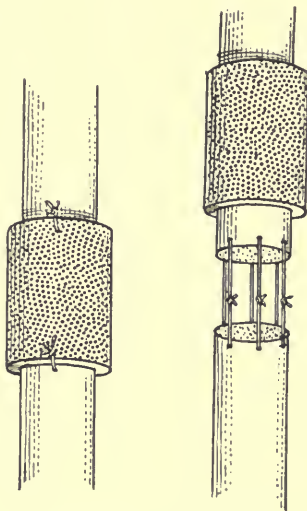


FIG. 208. NERVE-BRIDGING BY PROTECTIVE TUBES. The tube is drawn back over one end until the sutures are in place, as in the last figure, and then the tube is slipped down over the junction and fastened in place by a suture or two.

the operation is done in a case of long standing, are connected by a number of catgut sutures each of which transfixes the nerve from side to side, as shown in Fig. 207. The sutures should be of chromicized catgut threaded in a fine round intestinal needle, so as to avoid unnecessary damage to the nerve fibrils. Enough sutures should be introduced to form a fairly complete circle round the nerve; about six in the case of the median, eight or more in the sciatic. These sutures form an investment and support to the material effused between the divided ends and serve to define a path along which the nerve fibrils may grow. It is well to arrange matters so that the bridged

portions lie in a definite smooth track in the wound, such as an intermuscular septum, and are provided with a fascial envelope which is sutured over them before the wound is closed. Here, as in all these cases, a dry wound is essential.

Fig. 208 shows an elaboration of this method with the idea of forming a protecting tunnel down which the nerve fibrils may grow unhampered by the surrounding tissues. The ends are dissected up for a short distance, the proximal one for twice the distance of the other. Over this end

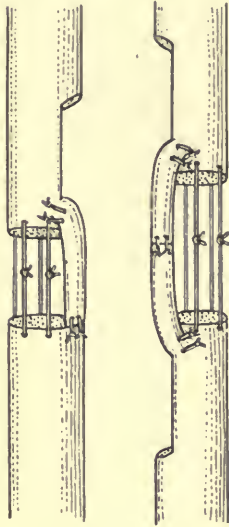


FIG. 209. NERVE-BRIDGING BY THE COMBINED METHOD. The catgut strands are made to reinforce the reflected nerve slip.

is passed a decalcified bone tube just large enough to slip easily over the nerve. This is pushed along the nerve until the divided end of the latter projects beyond its mouth. The two ends of the nerve are then sutured by long strands of catgut as in Fig. 207, and when the union is complete the tube is slipped down so as to cover it (see Fig. 208). The tube should be long enough to cover the gap and a quarter of an inch of nerve on either side. It may be prevented from slipping out of position by passing a suture through it and fastening this to the nerve itself, or any fixed fascial structure in the immediate neighbourhood. The wound is then closed in the usual way. Foramitti (*Contributo alla Chirurgia Nervosa*, 1908, p. 11) has suggested the use of dogs' arteries hardened in formalin in place of the somewhat clumsy bone tube. The hardened arteries, of suitable size, are cut into lengths, slit longitudinally, and then applied around the seat of union of the nerve much as a cigarette-paper is applied to the tobacco, being fastened by sutures so as to protect the anastomosis entirely. The thinness and resilience of the elastic tubes thus produced are much in their favour.

Bridging by catgut may be very useful in reinforcing union by reflected slips of nerve (see Fig. 209).

Results. There is no doubt that this method gives quite remarkably good results in suitable cases. No one surgeon's experience is large enough to enable helpful figures to be given, but numbers of successful cases have been done both in man and animals. Kilvington (*loc. cit.*) quotes four experiments in which portions of nerve varying from three-quarters to an inch and a half of nerve were excised and the gap bridged in this manner. One result was perfect, two fairly good, and the remaining one poor.

Nerve-transplantation methods. A classification of these is given on p. 419. A few words may be devoted to each.

Autoplastic transplantation with nerve. Obviously it can be only very rarely that this method will be used in the living subject, since it involves bridging the gap with a portion of nerve derived from some other nerve in the patient's body. There are, however, conditions under which it becomes very useful when it is impossible to obtain a fresh nerve

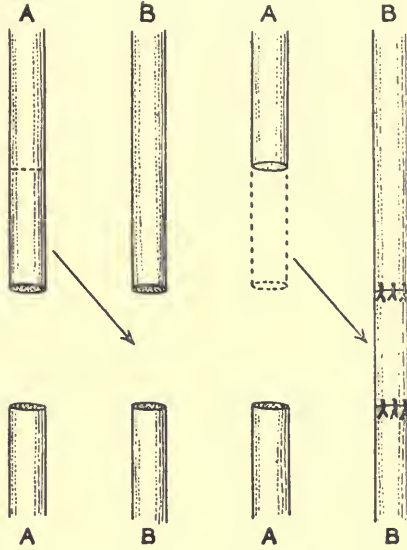


FIG. 210. DIAGRAM ILLUSTRATING THE REPAIR OF ONE NERVE WITH A PORTION OF ANOTHER. A and B are two neighbouring nerves in which there is a gap that cannot be bridged with any prospect of success by anything but a nerve-graft. If a nerve from a lower animal be not available, a portion is excised from the less important nerve of the two, A, and sutured into the gap in B. Thus the functions of B may be preserved instead of paralysis of both A and B following. The gap in A may be bridged with catgut or non-nervous tissue from the immediate neighbourhood in the hope that restoration of function may occur; if not, a portion of nerve from one of the lower animals may be grafted in at a subsequent date.

from one of the lower animals. Injuries are met with, particularly in the front of the forearm, in which a large part of more than one nerve is lost. This will leave a gap that it may be impossible to bridge by any of the foregoing methods, and a nerve from any other source may be unavailable. Sooner than condemn a patient to lose the functions of both nerves, it will be better to restore the functions of one by grafting into its gap a portion derived from one end of the other (see Fig. 210). This only increases the already unbridgeable gap in the other, which may possibly be closed by hetero-transplantation on some more auspicious

occasion. Another condition is when there is an unbridgeable gap in a main trunk like the musculo-spiral, which has large and important branches. Here, since failure to close the gap means permanent loss of function of all the branches, it will be justifiable to excise a portion of one of the branches and graft it into the gap in the main trunk, thus restoring the functions of all parts of the nerve save the branch divided for the graft. When an autoplasmic operation is very necessary, it may be justifiable to excise the internal saphenous nerve and graft that (*vide infra*) into the gap in a more important nerve in the same patient. The functions of the internal saphenous nerve are purely sensory and not important.

Autoplasmic transplantation with non-nervous tissues. Occasionally a surgeon may prefer to close a gap that he cannot bridge by the slip method by grafting into it muscle, fascia, or fat from the immediate neighbourhood, when he cannot get nervous tissue and distrusts his catgut. Success has attended this method, but the catgut strands seem preferable.

Homo-transplantation with nerve. This is a good method, but the difficulty is to find suitable human nerves for the purpose, as they must be derived from amputated limbs, which are seldom furnished by healthy subjects. The results should be as good as those following autoplasmic nerve transplantation, which are excellent, but the operation must always remain rare because of the infrequency of an amputation in a healthy subject coinciding with a case of nerve-bridging.

Homo-transplantation with non-nervous tissue. This would obviously never be done in practice. If non-nervous tissue were to be grafted at all it would be derived from the patient himself.

Hetero-transplantation with nerve. This is the common method for bridging large gaps in the human subject, and many successes have been reported. By means of it ample material can be obtained for the bridge without any tension or fear of subsequent breakdown. It is, however, not so likely to be successful as is auto-transplantation.

The nerve will probably be derived from a dog, the sciatic for choice. It may be necessary to lay two or three lengths of the nerve side by side in the gap, according to the width of the nerve that has to be bridged. Thus the sciatic would probably want three or four parallel lengths, the median two or three, and the radial or ulnar only one. The width of the bridge should equal the width of the nerve. It should be cut fully half an inch longer than is actually necessary, in order to obviate tension, and it is a matter of the greatest importance to lay the bridge in a situation, such as an intermuscular space, in which there is little or no scar tissue. As Kilvington (*loc. cit.*) remarks, 'to insert a nerve-

graft in the relentless grip of scar tissue is to court failure.' His recommendation to open up a fresh intermuscular space and place in it the nerve and its graft when the seat of the lesion is full of dense cicatricial material is an excellent one.

The chief difficulty in the operation is the avoidance of sepsis, the slightest degrees of which are fatal to success. The infection generally occurs in obtaining and transporting the nerve-graft from the animal to the patient. The safest plan is to have the graft prepared by special assistants who do not take part in the operation, and who will expose and remove the desired amount of nerve with the fullest aseptic precautions. The principal difficulty in this is to avoid infection from the animal's hair. The limb should therefore be shaved and purified as thoroughly as possible, and when the animal is killed the part is rapidly skinned and its surface again purified before proceeding to the actual exposure of the nerve, which should be done with a fresh set of sterilized instruments, and after isolating the limb operated upon with fresh sterilized towels. The preparation of the graft should take place in the near vicinity of the operation and as much of the nerve as possible should be removed; it can be cut to the required length when it is laid in the gap. It is transported in hot wet sterilized gauze or in a bowl of normal saline solution at the body temperature.

The method of suturing the graft is the same as in primary nerve suture (see p. 413). In these cases the graft can be cut long enough to avoid the necessity of flexing any of the joints to relieve tension. The recovery of function may be hastened by the use of massage to the muscles supplied by the nerve and possibly by the application of the galvanic current along the course of the nerve itself.

Results. There are not enough published cases to render any generalization reliable. The same remark applies to experiments on animals in whom the results have varied widely. All that can be said of the method at the present time is that, while it is not to be expected that it will be as successful as the autoplasmic methods, yet it has succeeded in several cases and should always be tried when the gap is so wide that no other method is available.

NERVE-GRAFTING (IMPLANTATION)

By this term is understood the operation of implanting one nerve trunk into another in order to restore the functions of one nerve without interfering with those of the other. Strictly speaking, these operations are the true nerve-grafting operations, for by their means one nerve has the functions of another grafted upon it in addition to discharging its own.

Indications. (i) At the present time the operation is chiefly done for the purpose of restoring the functions of a paralysed facial nerve. A permanent facial paralysis, either from middle-ear disease or of the idiopathic type, is amenable to treatment by means of an anastomosis between the extra-cranial portion of the facial and either the spinal accessory or the hypoglossal nerve. A similar operation is applicable to many cases of paralysis not dependent upon section of the nerve, and therefore not remediable by nerve suture or nerve-bridging, such as spastic paralysis, &c.

(ii) In cases of infantile paralysis the main nerve supplying the

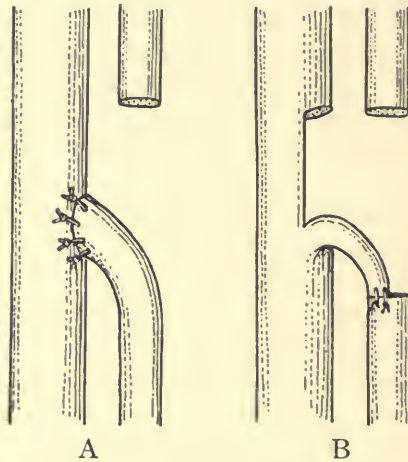


FIG. 211. NERVE-GRAFTING BY LATERAL IMPLANTATION. The usual method is seen in A. A longitudinal slit is made in the sheath of the host, and the end of the graft is inserted in this, only the adjacent edges of the sheath being taken up in the sutures. B shows a method that may be used when it is difficult to approximate the cut end of the graft to its host.

paralysed group of muscles may be grafted into that supplying an unaffected group with some prospect of improvement, provided that the operation be done early.

(iii) This method may also be adopted when long portions of a nerve are lost as the result of either accident or operations.

Operation. The chief steps of the operation are to isolate the paralysed nerve until a sufficient amount is obtained to enable it to be brought across to the nerve with which it is to be anastomosed, and then to divide it at the most suitable spot and graft the distal end into the sound nerve selected after making a vertical incision in the sheath of the latter for its reception (see Fig. 211). This incision should only go through the sheath of the nerve, and the two nerves are fastened

together with fine sutures of catgut, taking up only the nerve sheath, except when there is some tension, when tension sutures (see Fig. 204) must be inserted. They should never be used, however, unless it is absolutely necessary, as it is most important to do as little injury to the nerve fibrils as possible.

This method is the most appropriate one either for anastomosis of the facial or for altering the nerve-supply of a muscle or set of muscles. It is not necessary to divide the sound nerve; it may possibly be necessary to reflect a slip from it to join to the paralysed one when there is much difficulty in making this approach the sound trunk (see Fig. 211, B), but this can be only rarely necessary.

When a long portion of a nerve has been lost and the gap either cannot be or has been unsuccessfully grafted, an anastomosis may be made of the nature shown in Fig. 212. Here the sound nerve has both ends of the damaged one grafted into it, with a considerable interval between them. It may be perhaps a useful precaution to do the anastomosis in this way, although it is hardly possible that fibres could grow from the central end down along the sheath of the sound nerve until they come to the distal end of their own nerve, when they would leave their temporary abode and follow the right path. Fig. 213 shows another useful method of nerve-grafting when portions of two parallel nerves have been lost and nerve-bridging is impossible.

The steps of the operation for facio-hypoglossal and facio-accessory anastomosis are described in connexion with exposure of the facial and spinal accessory nerves respectively (see pp. 453-5). In the case of alteration of the nerve-supply of a muscle or set of muscles, no definite steps can be laid down, as the operations will vary widely. The most important one will be the isolation and division of one popliteal nerve and its lateral implantation into the other.

Results. The operation has not been established in popular favour long enough to allow of any reliable figures being given, since the results must obviously depend upon such widely different conditions as the proper selection of cases, the operative capabilities of the surgeon, and his power to command asepsis.

There is, however, an increasingly large number of recorded cases,

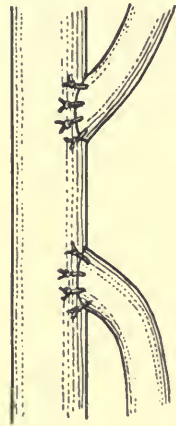


FIG. 212. NERVE-GRAFTING BY DOUBLE LATERAL IMPLANTATION. Both ends of the paralysed nerve are grafted into the host in the manner described in the text.

chiefly of anastomosis of the facial with the spinal accessory or the hypoglossal nerves, to prove that this method is of the highest value. As the technique and the selection of cases improve the results are likely to be better in the immediate future. Experience teaches that in cases of nerve suture the manipulative power of the surgeon counts for much.

In connexion with the transference of muscular nerve-supply, Tubby (*Clin. Soc. Trans.*, vol. xl, p. 267) reports two cases of complete paralysis

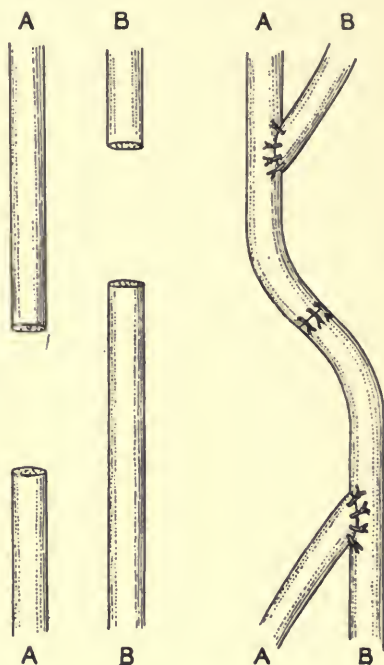


FIG. 213. METHOD OF GRAFTING WHEN TWO PARALLEL NERVES ARE DIVIDED. There is a loss of substance in the two adjacent nerves A and B at different levels. A and B are grafted direct by end-to-end suture, while the proximal end of B and the distal end of A are grafted into the newly constituted nerve by lateral implantation.

of the soleus and gastrocnemius accompanied by marked talipes calcaneus in which he identified by electric stimulation the branches from the internal popliteal nerve which supplies the gastrocnemius and soleus, traced them a long way up in the internal popliteal trunk, and then divided them, grafting their distal ends into the external popliteal by lateral implantation.

In one case there was very slight recovery, the boy being able to raise his heel in walking and plantar-flex the foot.

In the other case the range of movement became normal, and there

was a gratifying increase in power, which commenced to return within nine weeks from the operation, whereas it took four and a half months in the previous case. There was visible tightening of the tendo Achillis in both cases when an attempt was made to raise the heel.

Good results have followed within a few weeks after nerve-grafting of this kind performed for paralysis of many years' standing, with ultimate perfect recovery of function, but it is very necessary to select cases with care and to plan the operation carefully. Thus the nerve that is to take on the functions of the paralysed one must be at least equal to the latter in size and functional importance. It is apparently possible to make the same nerve work muscles whose actions are directly antagonistic, *e.g.* flexors and extensors, or pronators and supinators.

CHAPTER II

OPERATIONS UPON THE CRANIAL NERVES AND THE GASSERIAN GANGLION

EXPOSURE OF THE SUPRA-ORBITAL NERVE

Indications. This nerve, which is the largest of the terminal branches of the ophthalmic division of the fifth nerve, is exposed either for the purpose of stretching it, or, preferably, of resecting a portion in those cases of trigeminal neuralgia in which the pain is limited to the first division.

Surgical Anatomy. The nerve leaves the orbit through the supra-orbital notch, and ascends vertically over the frontal bone to supply the adjacent portion of the scalp. The supra-orbital notch is situated at the junction of the middle with the inner third of the upper margin of the orbit, and in this situation the nerve lies beneath the fibres of the orbicularis palpebrarum (oculi) muscle, and divides into two or more branches almost immediately after it has emerged from the notch. The supra-orbital vessels are on its outer side and not so deeply situated.

Operation. The eyebrow need not be shaved; it suffices to purify it thoroughly. Irregular growth of the eyebrow may follow shaving, which experience has proved to be unnecessary. The surgeon defines the supra-orbital notch and makes a curved incision about half an inch long, following the upper margin of the orbit with its centre opposite the notch. The fibres of the orbicularis palpebrarum (oculi) are separated with the handle of the knife until the periosteum is reached, when the notch can be felt and the nerve seen emerging from it close down on the periosteum. In order to stretch the nerve a hook is passed beneath it; should it be desirable to remove a portion, the nerve is pulled up with a hook, divided some little distance up on the scalp, and then as much of the nerve as possible is pulled out by grasping the proximal cut end in Spencer Wells's forceps and winding the nerve around the blades so as to tear away as much as will come. The incision above recommended leaves very little scar, as it is made through the eyebrow; as it is parallel to the fibres of the orbicularis these do not gape when the wound is closed.

RESECTION OF THE SUPERIOR MAXILLARY NERVE

Indications. This nerve is frequently resected for obstinate trigeminal neuralgia affecting chiefly the second division. It is never exposed merely for the purpose of being stretched. The operation usually gives relief for a period varying from a few weeks to two years or longer, but rarely succeeds in effecting a permanent cure.

Surgical anatomy. This nerve, the second division of the fifth, is about two inches in length, and extends from the foramen rotundum to the infra-orbital foramen on the front of the superior maxilla, where it breaks up into its terminal branches.

The infra-orbital foramen is localized by drawing a line from the supra-orbital notch to the interval between the two lower bicuspid teeth. Along this line lies the infra-orbital foramen about half an inch below the lower margin of the orbit. In the speno-maxillary (pterygo-palatine) fossa between the foramen rotundum and the back of the upper jaw lies Meckel's (spheno-palatine) ganglion, which should be removed with the nerve; in order to get beyond all the branches of this division the nerve should be divided on the proximal side of the ganglion. In its course through the upper jaw the nerve lies partly in the infra-orbital canal.

Operation. The nerve may be resected:

- (i) At the infra-orbital foramen.
- (ii) Behind Meckel's (spheno-palatine) ganglion at the foramen rotundum. This operation is much more satisfactory in its results than the former, although it is far more difficult to perform.

At the infra-orbital foramen. The head is turned slightly towards the affected side and is raised upon a pillow, the position of the infra-orbital foramen is determined (*vide supra*), and a slightly curved incision about half an inch in length with its concavity upwards is made so that its centre crosses the foramen. This incision exposes the fibres of the orbicularis palpebrarum (oculi), which are separated in the line of the incision, and those of the levator labii superioris (caput infra-orbitale) are then exposed and split in the direction of their fibres. This exposes the trunk of the nerve, which divides into a number of branches as it emerges from the foramen. There is often troublesome bleeding due to damage to the infra-orbital artery or vein, and it may be necessary to employ adrenalin in order to stop this. The nerve is picked up with a blunt hook as it emerges from the foramen, divided with scissors about half an inch from it, and the proximal end is seized in Spencer Wells's forceps and twisted around the blades so as to drag as much of it out of the foramen as possible.

This operation is not followed by much success and is therefore rarely performed.

At the foramen rotundum. In order to remove the nerve as far back as the foramen rotundum it must be followed up through the upper jaw. The incision most frequently advised is a V-shaped one, the apex of the V being downwards and its centre just below the infra-orbital foramen. A less noticeable cicatrix may be obtained by planning the incision so that it lies in one of the natural folds of the face. I have found the one recommended by Kocher to be the easiest to work through and the best as far as the æsthetic result is concerned. It commences just below the inner end of the infra-orbital margin, and runs obliquely downwards and outwards to the lower angle of the malar bone. It should be sufficiently long to give good exposure of the anterior surface of the superior maxilla from the canine fossa to the lower margin of the orbit.

After having made the skin incision, the surgeon separates the fibres of the levator labii superioris (caput infra-orbitale) and finds the infra-orbital nerve as it comes out of the foramen (*vide supra*), and fastens a ligature to it in order to identify it during the rest of the operation. The nerve is then cut through on the distal side of the ligature.

The front of the jaw is cleared of muscles and periosteum and is cut away with a chisel so as to leave a square hole, the sides of which are an inch long. This should be so planned that the infra-orbital foramen is slightly below the centre of the square, the upper edge of which will be just below the margin of the orbit. In doing this care must be taken not to tear the nerve, which is left hanging out through the opening. As the antrum is opened up there is usually free oozing, which may be stopped by packing the wound with small pledgets of wool dipped in adrenalin chloride (1 in 1,000); adrenalin is most useful in this operation, and it is almost impossible to get a clear view without it. When the bleeding has ceased, the surgeon, with the aid of a forehead-light, identifies the nerve hanging from its bony canal in the roof of the antrum, and clips away the lower wall of this canal with scissors or a very fine chisel. The nerve must not be damaged in doing this or else the guide to the subsequent steps of the operation will be lost.

When the whole of the bony floor of the canal in which the nerve lies has been cut away right to the back of the posterior wall of the antrum, an aperture, similar to but slightly smaller in size than that already made on the anterior wall, is cut out of the posterior wall in a similar manner. This leaves the nerve protruding through the cavity, and, after stopping the bleeding and pulling it taut, it can be traced up to the foramen rotundum and Meckel's (spheno-palatine) ganglion identified. While

traction is kept up on the ligature attached to the nerve, a pair of Spencer Wells's forceps is slipped up around the trunk nearly to the foramen rotundum and the nerve is either pulled out forcibly from, or cut off flush with the foramen with a pair of curved scissors; in either case the ganglion will come away with the trunk. The nerve should always be pulled as far out of the foramen as possible, so that it may retract inside it after it has been divided.

RESECTION OF THE INFERIOR MAXILLARY NERVE

Anatomy. The third or inferior maxillary (mandibular) division of the fifth nerve leaves the skull by the foramen ovale, and divides almost immediately into two main branches, the anterior being the smaller and giving off the temporal, masseteric, buccal, and the external pterygoid branches. From the posterior or larger division arise the auriculo-temporal, lingual, and inferior dental (alveolar) branches.

In trigeminal neuralgia the pain may be most marked in, or entirely confined to, this division of the fifth nerve, and under these circumstances it is usual to try the effect of division of its terminal branches in the first instance. Should this fail, it has been recommended to divide the main trunk at its exit from the foramen ovale, but, having regard to the want of success of the operation as regards recurrence of pain, and looking also at the severity of the operative procedure and the disfigurement it entails, it would seem better to expose and remove the Gasserian ganglion in all cases of neuralgia of the third division in which neurectomy of the inferior dental (alveolar) or lingual branches has proved ineffectual.

Resection of the inferior dental nerve. Indications.

(i) Persistent neuralgia. This operation will be practised when the neuralgia is comparatively recent and is limited to the distribution of the inferior dental nerve, or to it and the lingual branch, in which case the latter nerve will be divided at the same time (see p. 434).

(ii) Certain cases of inoperable cancer of the tongue or jaw in which the pain is excessive and cannot be subdued by narcotics. Simultaneous resection of the lingual nerve (see p. 434) will be probably required here also.

Operation. The patient's head is well propped up and the mouth is opened widely with a gag; the table must be so arranged that a good natural or reflected light is directed upon the affected side. The surgeon stands on the opposite side, and the tongue is pulled to that side and kept out of the way by a suitable broad tongue depressor. As it is essential that the tongue should not slip and obscure the view, a stout

silk ligature passed well through its centre may be used as a retractor, or sharp-pointed single tenaculum forceps may be used.

An incision about one inch long is made parallel with, and just internal or posterior to, the anterior border of the ascending ramus of the jaw, and the muco-periosteum is separated from the bone until the inferior dental (mandibular) spine is felt above the commencement of the inferior dental (mandibular) canal. The long internal lateral (spheno-mandibular) ligament of the jaw, which is attached to the spine, is carefully divided with fine blunt-pointed scissors, and then the inferior dental (alveolar) nerve is identified just behind this and hooked up into the wound. There is free oozing during this stage of the operation, and it may be advisable to have recourse to temporary plugging with adrenalin chloride (1 in 1,000). The nerve lies in front of the inferior dental (alveolar) vessels, but it is close to them as it enters the canal, and they may be easily wounded by careless manipulation. Half an inch or more of the nerve is removed with scissors, and the wound is left to heal by granulation.

The mouth is washed out frequently with a mouth-wash containing one drachm of sanitas to the pint. The patient is generally well in a week; there is stiffness and pain in the jaw for the first few days only.

This operation is much to be preferred to the method of reaching the nerve through the outside of the cheek by exposing and deepening the sigmoid (mandibular) notch of the lower jaw. The latter method is easy, but it leaves an unsightly scar and therefore will not be described; the intra-buccal method described above, although rather difficult owing to the free venous oozing, is nevertheless to be preferred.

Resection of the lingual nerve. *Indications.* As for the preceding operation (see p. 433).

Operation. The patient is propped well up, the head is turned to the opposite side, and the mouth is opened widely, while the tip of the tongue is grasped in forceps and pulled firmly to the opposite side. The nerve at once stands out in relief beneath the mucous membrane of the tongue behind the last lower molar tooth. An incision about half an inch long is made parallel to and just over the nerve, which is caught up with a blunt hook and the desired portion excised. No sutures are needed to close the wound in the mucous membrane.

Resection of the auriculo-temporal nerve. *Indications.* This operation is hardly likely to be called for in the living subject. Pain in the auriculo-temporal nerve in cases of trigeminal neuralgia will usually call for more radical measures, such as removal of the Gasserian ganglion. When pain in this nerve occurs in connexion with cancer of the tongue or jaw the pain is reflex, and may be stopped

by division of the lingual or inferior dental (mandibular) nerves or both.

Operation. The nerve can be exposed by a vertical incision over the posterior root of the zygoma midway between the tragus and the condyle of the jaw. The incision need only be half an inch in length, and the nerve will be found posterior to and parallel with the superficial temporal artery (see Fig. 201).

REMOVAL OF THE GASSERIAN GANGLION

Indications. Removal of the Gasserian (semilunar) ganglion is the only reliable cure for inveterate trigeminal neuralgia that has resisted prolonged medical treatment and has recurred after any of the preceding operations upon the branches of the fifth nerve have failed to give permanent relief. The operation is one of considerable severity, and the mortality directly traceable to it is still comparatively high; therefore it should not be resorted to until it is clear that other methods have proved ineffectual. At the present time most surgeons perform resection of some of the terminal branches of the fifth, such as the infra-orbital, lingual, or inferior dental (alveolar) nerves, before proceeding to remove the ganglion, because the period of freedom from pain following these milder operations is often considerable. On the other hand it is important that the operation should not be delayed until the patient is broken down in health by the excessive pain, want of sleep, and, possibly, abuse of morphine.

Surgical anatomy. The Gasserian (semilunar) ganglion is reniform in shape with its convexity directed forwards and outwards. It rests in a special depression upon the upper surface of the petrous portion of the temporal bone and the cartilage filling up the foramen lacerum medium. It is of a reddish grey colour and lies in a cleft in the dura mater (Meckel's cave). From its anterior border are given off three main divisions, the first or ophthalmic being long and slender and running horizontally forwards, whilst the third or mandibular division is short and stout and passes almost vertically down from the ganglion to the foramen ovale so that very little of it is seen in the field of operation. The middle or (superior) maxillary division is longer and is intermediate in size between the other two; it passes forwards and a little downwards to the foramen rotundum. Both the ophthalmic and the (superior) maxillary divisions lie in close relation to the outer wall of the cavernous sinus, particularly the former, which lies a little below and parallel to the fourth nerve until the latter's disappearance into the orbit through the sphenoidal (superior orbital) fissure. The inferior

maxillary (mandibular) branch receives the small motor root of the trigeminal nerve, which passes forward beneath the ganglion; beyond the foramen ovale they join together to form the inferior maxillary (mandibular) branch. The point at which the trigeminal nerve expands into the ganglion is within the dura mater, which here forms a sheath of investment around it. The ganglion itself, or at any rate the greater portion of it, and its main divisions lie outside the dura mater.

Operation. A number of methods have been employed for the exposure and removal of this structure. The one first described was by an extra-dural route through the foramen ovale, and was introduced by Professor Rose, who was the first surgeon to remove the ganglion (*Lancet*, November 1, 1890). This method, however, has fallen entirely into disuse owing to the difficulty, danger, and uncertainty attending it. It is certain that in very few cases was the ganglion reached and entirely removed by this method.

The next operation in chronological order is that of Sir Victor Horsley, who opened the skull from the temporal region, divided the dura mater, lifted up the temporo-sphenoidal lobe, and removed the ganglion from within the dura mater. The patient died of shock, and the operation did not become popular. Its place was soon taken by the method now known as the Hartley-Krause method, which was described independently by Dr. Hartley (*New York Medical Journal*, vol. lv, 1892) and Professor Krause (*Deutsche Med. Wochenschrift*, 1893, No. 15), the details of which are given on p. 447. It will be seen that this method consists essentially in making a large opening in the temporal region, either with or without an osteoplastic flap, and then raising the dura mater from the floor of the middle fossa of the base of the skull until the ganglion is reached and can be removed.

This method held the field for a considerable time to the exclusion of all others, and is even now the operation most generally practised. While it may well be granted that this method is a great improvement upon its predecessors, it will probably have occurred to most of those who have performed it that the opening in the skull is placed too high up, and that the difficulties of the operation are greatly increased by having to raise the brain inside the dura mater for a considerable distance out of the floor of the middle fossa before the ganglion can be reached. Examination of the skull will show that if the opening be made lower down, the operation can be done with much less interference to these important structures, and in my last four cases I have abandoned the Hartley-Krause method in favour of a modification of the method introduced by Cushing and described by Kocher (*Operative Surgery*, translated by H. J. Stiles, 2nd ed., 1903).

The modified Cushing method. The operation that I use is a compromise between that of Cushing, who peels down the temporal muscle, and therefore restricts the field of operation, and that of Doyen, who, after sawing through the zygoma as Cushing does, divides the attachment of the temporal muscle to the coronoid process and turns it and its tendon upwards, thus giving a clear space above the pterygoid ridge where space is of most value. In Doyen's operation a trephine opening is made immediately above the pterygoid ridge and, after the inferior maxillary (mandibular) nerve has been identified as it leaves the foramen ovale, the base of the skull is chiselled away between the trephine opening and the outer margin of the foramen ovale. In this way it is possible to get at and remove the ganglion without disturbing the dura mater, and therefore without exerting injurious pressure upon the brain above.

I am inclined to think that the methods of both Doyen and Cushing are superior to the Hartley-Krause; of the two I prefer that of Cushing modified in the manner to be described immediately, as the removal of the thick base of the skull in Doyen's method gives rise to bleeding, which is not only exceedingly troublesome, but may be actually dangerous.

The modified Cushing method will be described first in full; subsequently the chief steps of the other operations will be indicated briefly.

Operation. Shock must be guarded against most carefully, as the operation is sure to be prolonged under the most favourable circumstances; if the operator be inexperienced it is no uncommon thing for it to last more than two hours. Moreover, the patient is generally elderly and broken down in health, and the bleeding is always free. The operating room should be at a temperature of at least 70° F., the patient should be warmly wrapped up upon a hot-water table, and should have a nutrient enema containing 1 oz. of brandy before operation. The apparatus for saline intra-venous infusion should be at hand (see p. 406). The surgeon must be provided with a powerful electric forehead-lamp, without which it is impossible to get a good view of the depths of the wound; the lamp, properly focused, should be fitted on before the operation is begun, so that an assistant can switch on the light during the operation and the surgeon need not touch the lamp himself. Horsley's aseptic wax¹ and adrenalin chloride should be at hand.

The patient should be propped up as much as the anæsthetist will allow, in order to minimize the venous oozing which is invariably a serious hindrance during the operation, and the head should be thrown somewhat

¹ Beeswax 7 parts, almond oil 1 part, and salicylic acid 1 part. This is mixed and sterilized by immersion in boiling water, and is kept under 1 in 20 carbolic solution. It is a hardish wax that must be softened by working it up in the fingers.

back and turned slightly to the opposite side; a special head-rest attached to the table very greatly facilitates matters. A most important point is to see that the anæsthetist and his apparatus do not trespass upon the field of operation. The operation is a long one, and there must always be a risk of septic infection owing to the proximity of the wound to various sources of contamination.

After numerous trials I have found that the best way of securing this object is to fasten one edge of a sterilized towel to the skin all around the proposed area of operation by means either of sutures or special forceps, which clip the skin to the towel. The other edge of the towel is then hung over a suitable rest, so that it serves as a curtain which cuts the anæsthetist off from the field of operation. This plan is much more satisfactory than the method of laying cloths around the operation area and encircling the head with them. It is impossible to prevent the towels from becoming displaced unless they are actually fastened to the skin, and in this particular operation even a slight displacement may open the door to septic contamination, which has had such serious results in the past. Another not inconsiderable advantage of securing the cloths to the skin in this manner is that a much smaller area of the scalp need be shaved and purified. It used to be the custom to shave at least half of the scalp, and in many cases the whole of the hair-bearing area was shaved and purified. This is a very serious drawback, especially in women, and experience shows that it is not necessary. If the sterilized cloths be secured around the operation area in the manner recommended, it is sufficient to shave the hair for the space of a clear inch and a half around the incision in all directions, and if the cloths be fastened to the edge of this space it is impossible for contamination from the hair to occur, while the plan has the great advantage that after recovery the area of operation is comparatively easily hidden by dressing the hair over it. I have adopted this plan in these cases for the last two years, and have also employed it in operations upon the mastoid antrum, in which preservation of as much of the hair as possible is a point that appeals very strongly to the patient. I have found that the incision can be carried into close proximity with the hairy scalp without any risk of infection.

The temporal region is purified by means of the usual compress applied overnight, and by thorough purification immediately before the operation. It is important to protect the conjunctiva on the affected side, and this is best done by suturing the eyelids together. The conjunctiva and the conjunctival sac are first washed out with warm boric lotion (gr. v ad ʒi), and the lids are then stitched together by pinching up a fold of each and fastening them with a running stitch of fine

silkworm-gut. This suture is left in place for a few days after the operation (see p. 446).

The incision generally used is omega-shaped (see Fig. 223); this gives a good exposure if it be carried down to the level of the zygoma. This, however, entails division of the nerve-supply to the orbicularis, and therefore for the last two years I have substituted the sickle-shaped incision (Fig. 214), which avoids the branches of the facial nerve. This

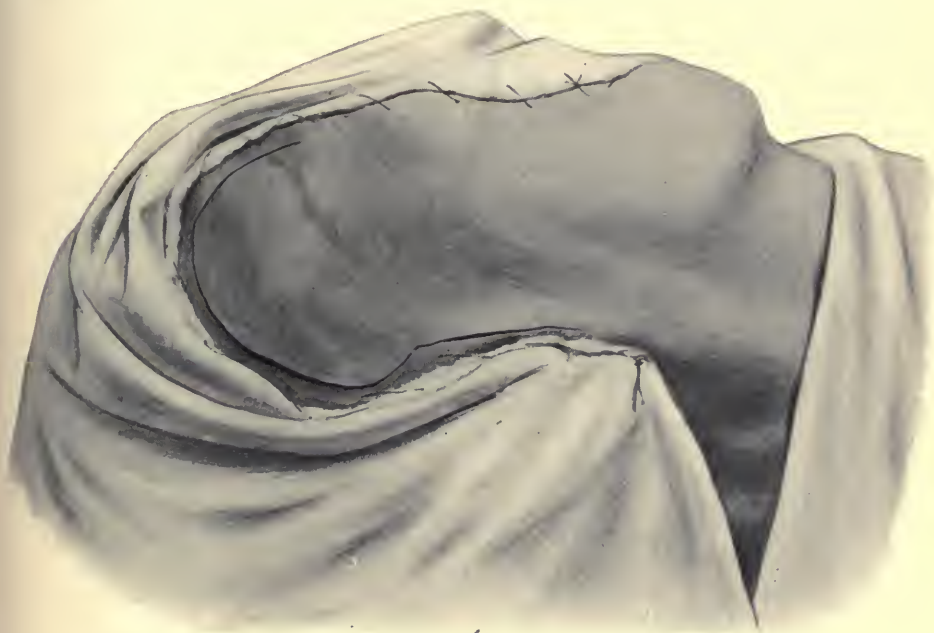


FIG. 214. INCISION FOR REMOVAL OF THE GASSERIAN GANGLION. The drawing shows the sterilized cloth sewn to the skin. In the actual operation the free edge of this is hung over a special screen.

incision commences well below the zygoma just in front of the superficial temporal artery, and runs vertically up for about an inch and a half; it then takes a bold curve with its concavity forwards, extending up as far as the outer angle of the orbit. This is practically identical with the later incision recommended by Cushing (*Annals of Surgery*, 1906, vol. xliii, p. 1). Quite good exposure is got by dragging the skin flap downwards and forwards over the zygoma. Both these incisions only go down to the deep fascia.

The temporal fascia and the periosteum are divided over the posterior end of the zygoma, and that bone is sawn through or divided with cutting pliers. The temporal fascia is then divided along the upper

margin of the bone until its anterior end is exposed. This is divided in a similar manner, and the bone, together with the muscle and fascia attached to it, can then be drawn downwards by a retractor. This brings into view the coronoid process with the tendon of the temporal muscle inserted into it (see Fig. 215). The coronoid process is sawn through, or the temporal tendon is detached from it, whichever seems the more easy to the operator, and, when this has been done, the temporal muscle is turned up so as to expose the lateral surface of the skull just above

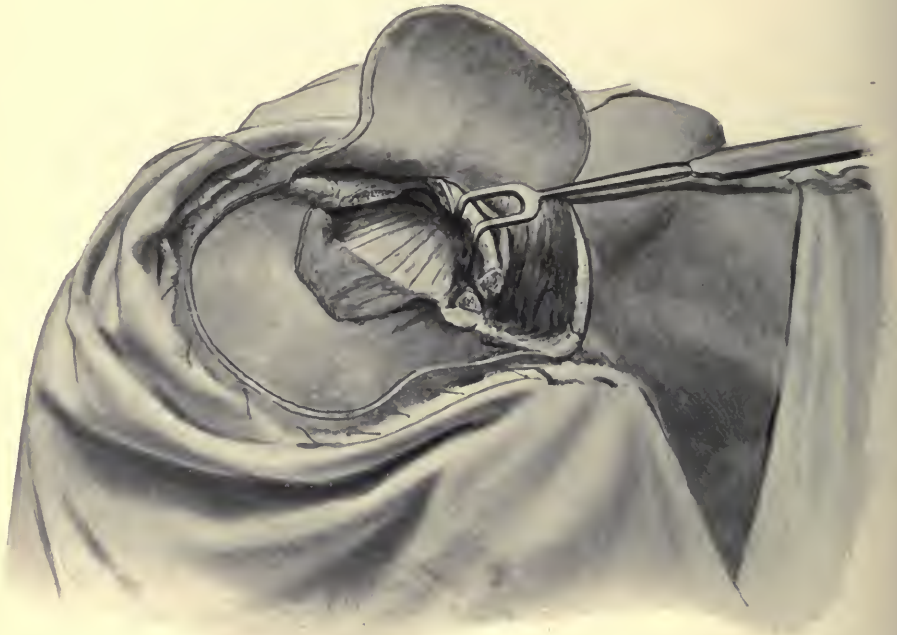

FIG. 215. SECTION OF THE ZYGOMA. The temporal muscle is exposed to view.

the pterygoid ridge. This is the region in which the skull is to be opened, and the opening may be made either with a one-inch trephine or with a gouge. The former method is the more rapid, the latter perhaps the safer, but in any case the bone must be cut through very cautiously owing to the varying thickness of the skull. Much inconvenience will be caused to the operator should the dura mater be inadvertently opened at this stage of the operation.

When the opening in the skull has been made it must be enlarged in all directions with suitable bone-cutting forceps (see Fig. 216), preferably as much downwards as possible, so as to make the opening in the bone nearly on a level with the floor of the middle fossa of the base of

the skull. An opening two and a half inches from front to back and two inches from above downwards ought to give enough room for the subsequent manipulations (see Fig. 217). During this stage of the operation, very troublesome bleeding from the bone and the pterygoid plexus is nearly always encountered. Bleeding from the bone can be stopped by pressing Horsley's wax firmly into the bleeding surface if necessary, whilst the venous oozing is best controlled by packing the wound firmly with gauze impregnated with adrenalin chloride (1 in 1,000).

The next step is to raise the dura mater from the base of the skull, and this should be done at first with a fine instrument like Horsley's

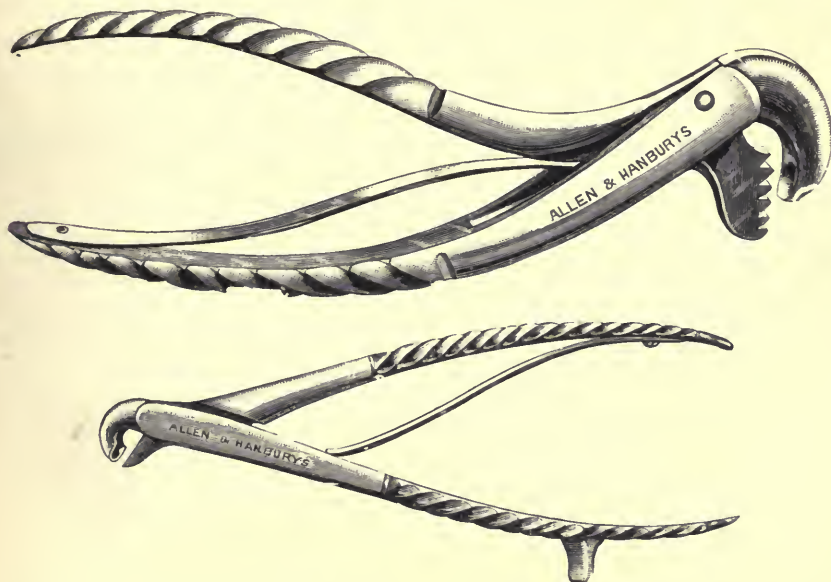


FIG. 216. FORCEPS FOR REMOVAL OF THE SKULL. The upper pair is a most powerful tool which acts by biting or breaking away large pieces of bone. The lower pair is finer and used to smooth off rough edges.

dura mater separator, but, as the operation proceeds, the finger should be substituted for it. The dura mater and the superjacent brain are raised gently and slowly so as to mould the brain gradually into its new position and to avoid bruising its under surface. Broad, thin, flexible spatulæ are most useful for holding up the brain, and a number of varying widths should be at hand.

The first structure met with on raising the dura from the floor of the middle fossa will probably be the middle meningeal artery. The vessel enters the skull through the foramen spinosum, which lies behind and to the outer side of the foramen ovale. As a rule, the artery need not be interfered with, but if it gets in the way it will be necessary to

secure it. The best way of doing this is to seize and divide it between two pairs of forceps some distance above the foramen; the proximal end is then twisted up several times and, if necessary, pushed down into the foramen with a stout probe. Another plan is to pass a ligature round it by means of an aneurysm needle with a very small curve, or special forceps (see Fig. 218), and tie it just above the foramen. If by mischance the artery should be torn across flush with the foramen,

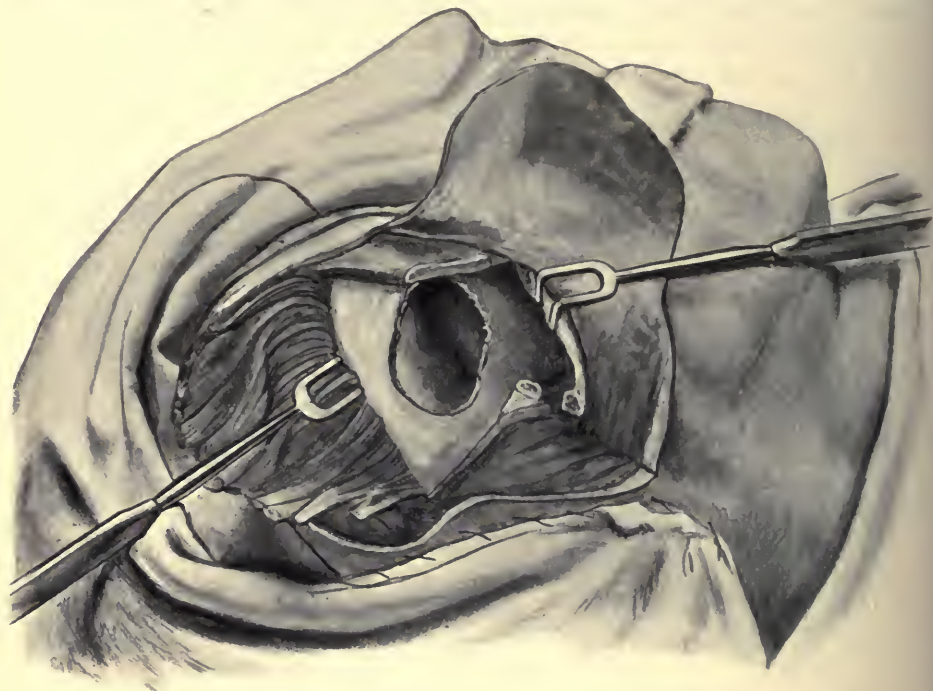


FIG. 217. EXPOSURE OF THE FLOOR OF THE MIDDLE FOSSA OF THE BASE OF THE SKULL. The dura mater is being lifted out of the base of the middle fossa. The temporal muscle has been turned up and the flap protected by gauze.

the bleeding from it may be stopped by pushing a probe well into the foramen, or, failing this, by plugging the latter with Horsley's wax.

As the separation of the dura mater proceeds, the three divisions of the nerve come into view; first the third, then the second, and finally the first division are seen (see Fig. 219). The second division is usually the most noticeable, as the third is quite short and may be difficult to identify at first. At this stage of the operation there is usually free oozing, which has to be met by continuous sponging and the use of adrenalin and firm temporary packing.

In order to diminish the risk of arterial bleeding still further, Crile

(*Annals of Surgery*, 1906, vol. xlv, p. 842) exposes the common carotid artery and clamps it temporarily by his temporary compressors (see Fig. 220). In spite of these precautions there will still be serious oozing from the veins and sinuses inside the skull, and to check this he keeps small rolls or pledgets of sterilized gauze pressed firmly round the operation area with special spatulæ, shaped like small tongue depressors (see Fig. 220). These compress the bleeding points and keep the operation area free of blood; they are shifted from place to place as the operation progresses.

Of the usefulness of this latter precaution I can speak from experience. With a proper supply of small pledgets and an assistant who understands where to pack them, the later stages of the operation, which are generally the most difficult, are greatly facilitated. I have never had recourse to temporary clamping of the carotid in this operation as the arterial bleeding is usually very slight if the superficial temporal be tied at an early stage and care be taken not to injure the middle meningeal when raising the dura mater. When, however, the orthodox Hartley-Krause method is adopted there is often very severe hæmorrhage in turning down the omega-shaped flap, and it is also easy to damage the middle meningeal artery and difficult to pick it up; under these circumstances temporary compression of the common carotid may be worth the extra time that it entails.

The dura mater is steadily raised from the upper surface of the nerves and the ganglion until they are thoroughly exposed; the dura mater may be punctured at this stage of the operation, in which case the cerebro-spinal fluid escapes and allows it to collapse somewhat. The third division is isolated by means of a fine dissector and is caught up on a fine blunt hook and divided with a blunt-pointed tenotome as close to the foramen ovale as possible. The motor root of the fifth lies behind the main trunk and should be left intact. The divided proximal end of the third division is now caught in strong long-handled catch forceps and lifted upwards and forwards so as to put the posterior and outer margins of

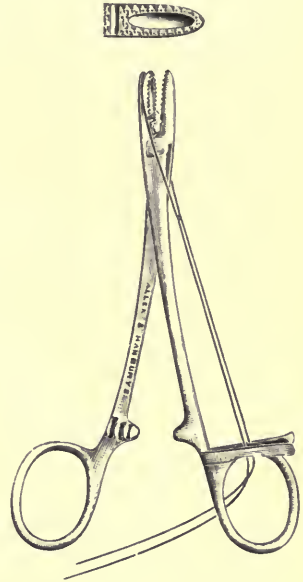


FIG. 218. SCHOEMAKER'S ARTERY FORCEPS. This is an ingenious device for tying deeply seated vessels. The suture is held taut by the clips on the handle, and the forceps are used to pick up the vessel, just as are Spencer Wells's. When the vessel has been seized, the ligature is loosened from the clips and tied.

the ganglion upon the stretch. This portion of the periphery of the ganglion is isolated with a fine dissector, and the main trunk of the fifth nerve is cut across well behind the ganglion, which is then pulled forward, separated from the bone beneath, and its first and second divisions gently raised from the wall of the cavernous sinus and divided as far forward as possible. If the motor root of the nerve can be identified when the ganglion is raised from its bed it should be left uninjured, but this is often impossible owing to free oozing from the small tributaries of the sinus.

Some authorities recommend that the ophthalmic division should

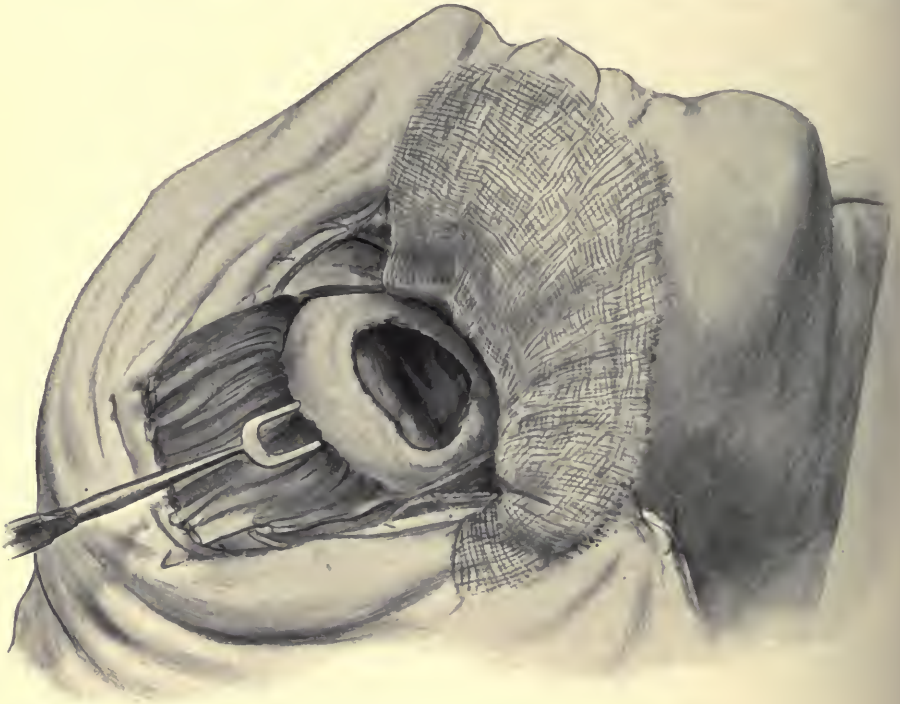


FIG. 219. EXPOSURE OF THE GASSERIAN GANGLION. The ganglion and its three branches are seen lying deep inside the skull.

be left intact whenever the pain in that branch is not pronounced; personally, I am in favour of removing all three branches with the ganglion for fear of recurrence. Should the surgeon decide, however, to leave the ophthalmic division intact, his best plan, after having divided and secured the third division, is to divide the second division at the foramen rotundum and seize it in forceps as he did the third division; in this way the ganglion can be lifted out of its bed and removed by a few snips of a pair of fine blunt-pointed scissors, while the first division is left intact.

The advantage of dividing the nerve behind the ganglion and turning the latter forwards with the second division attached to it is that there is less likely to be serious bleeding from the cavernous sinus, which is easily wounded when the second division is separated from it. Should this accident happen, the operation must be suspended for some minutes while the wound is packed firmly with pieces of sponge or gauze impregnated with adrenalin chloride (1 in 1,000) and the patient's head is raised. The bleeding is sometimes so profuse as to be positively terrifying; however, it invariably ceases in a short time.

When the ganglion has been removed, the dura mater is allowed to fall into place, when the bleeding will generally stop and the wound can

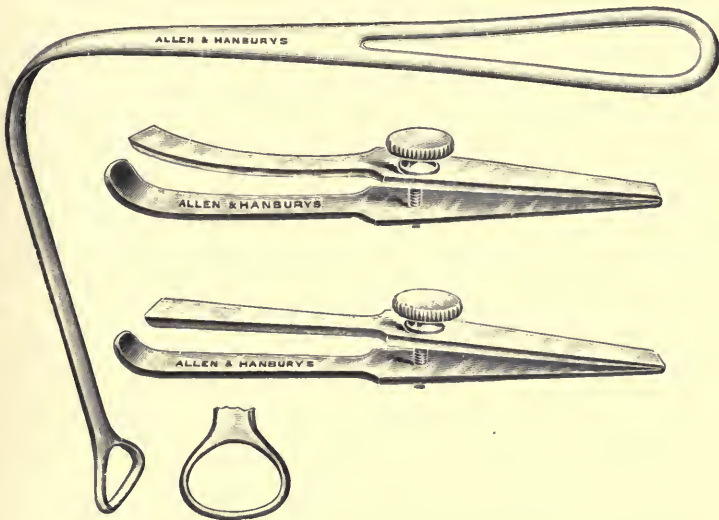


FIG. 220. CRILE'S ARTERY CLAMPS AND HÆMOSTATIC SPATULA.

be closed; as a rule no drainage tube is required, but if the bleeding persist in spite of elevation of the head, a small tube must be inserted just beneath the dura at the entrance to the skull; it may be removed in twenty-four hours. If the motor root of the nerve has been divided, it is unnecessary to suture the divided tendon of the temporal muscle, or to wire the zygoma in position, as both the temporal and the masseter muscles will be paralysed; the temporal tendon may be united with catgut sutures, however, should it be necessary, and the zygoma may be drilled and fastened with catgut. This will be done whenever it has been possible to save the motor root. If a drainage tube be inserted through the opening in the bone it should be brought out through one extremity of the incision. Large dressings are applied to the head, and a separate

pad is fastened over the eye. When put back in bed the patient should be propped up in the sitting position for the first twelve or twenty-four hours.

After-treatment. There is usually considerable shock which, however, rarely proves fatal. It varies with the amount of blood lost at the time of the operation, and, in bad cases, it will be necessary to have recourse to subcutaneous saline infusion. In any case the patient should have an enema immediately after the operation containing 1 oz. of brandy, 1 oz. of strong coffee, and 2 oz. of beef tea, to which 30 min. of laudanum may be added. A saline rectal injection (10 oz.) at the body temperature may be given two hours later and repeated in four hours if necessary. The shock is rarely bad enough to call for intravenous infusion.

If a drainage tube has been inserted, it should be removed at the end of forty-eight hours at the latest ; it is always best to dispense with one if possible, as cerebro-spinal fluid may continue to leak from the wound for some time if one be used. The dressing over the eye should be renewed, and the lids washed with boric lotion daily. The stitches may be taken out of the lids on the fourth or fifth day, but the eye should be kept protected by a dressing for at least three or four weeks after the operation. The stitches can be removed from the scalp wound about the ninth or tenth day, and the aperture in the skull needs no protection and soon becomes inconspicuous, being low down and well protected. If the motor root has been left undisturbed, the masseteric and the temporal muscles will not be paralysed ; if this be the case the surgeon will have reunited the temporal muscle to the coronoid process and have fastened the zygoma in position before closing the wound, and as a result the patient may get good movement of the jaw. In most cases, however, the motor root is divided when the ganglion is removed, and the movement of the jaw is permanently defective. Little complaint is made of this inconvenience, however, as the relief of pain following removal of the ganglion far outweighs it.

Difficulties and dangers. The chief difficulty in the operation is *hæmorrhage*. In the early stages of the operation this is comparatively unimportant if the steps detailed above be followed. In Cushing's original method, however, in which the temporal muscle is stripped off the bone, there may be considerable bleeding from the divided branches of the temporal vessels even at this stage. The serious hæmorrhage occurs during the separation of the dura mater in order to expose the ganglion, and may arise either from a wound of the middle meningeal artery or damage to the cavernous sinus. Bleeding may also occur from the small (accessory) meningeal, which passes through the foramen ovale, when the third division is cut. Both these vessels may be secured

either by ligature (see p. 442), or if that fail, by the application of Horsley's wax.

The most serious bleeding, however, is from the cavernous sinus, which is in close relation to the first and second divisions of the nerve; both branches run along its outer wall. In order to avoid injuring it the precautions given above should be strictly followed, and the most cautious manipulation, careful sponging, and perfect illumination must be secured if a clear view is to be obtained and injury to any structure save the ganglion itself is to be avoided. Wound of the cavernous sinus is followed not only by the most alarmingly profuse hæmorrhage at the time, but not infrequently by thrombosis of the sinus subsequently, a complication marked by proptosis, intense chemosis, retinal hæmorrhages, œdema over the mastoid region, and permanently impaired vision or temporary blindness; there is usually, also, temporary paralysis of all the ocular muscles. Should such an accident occur, the best plan is to plug the area from which the bleeding comes with a small piece of gauze and leave it in place for ten or fifteen minutes, after which the bleeding will generally cease spontaneously. It has happened, however, that the bleeding from this cause has been so free that the operation has had to be abandoned, and the wound packed with gauze which was removed at a subsequent dressing. It is, however, very unlikely that this procedure will be necessary, and it is generally possible to sew the wound up without a drainage tube, since the bleeding ceases when the dura mater is allowed to fall back into place.

Another complication is *shock*, which is generally associated with loss of blood. The precautions against this have already been given (see p. 437). It may be so severe as to prove fatal in old and broken-down subjects.

Sepsis has occurred in a fairly large proportion of cases and is generally attributed to the length of the operation, the proximity of the anæsthetic apparatus, the mouth, or the hairy scalp, &c. This is a complication that should not occur, and no surgeon should undertake the operation unless he is confident of his power to maintain rigid asepsis throughout.

The Hartley-Krause method. An omega-shaped incision is made with its base just above the level of the zygoma and extending between the external angular process in front and the tragus behind. The incision is carried down to the bone, the bleeding is arrested, and then the pericranium is retracted for about a quarter of an inch on either side of the incision throughout its whole extent. An osteoplastic flap is then raised in the following manner:—

A half-inch trephine hole is made at the two top corners of the proposed bone-flap, and these are connected by a horizontal incision made through

the skull either with forceps, such as those of De Vilbiss (see Fig. 221), or a guarded chisel (see Fig. 222); the former method is preferable, as being more rapid. Other methods of dividing the skull are by means of Gigli's wire saw (see Fig. 25), which must be protected from wounding the dura mater by passing a flexible metal guide between it and the bone (see Fig. 223), or by Hey's saw, which is, however, a very tedious method.

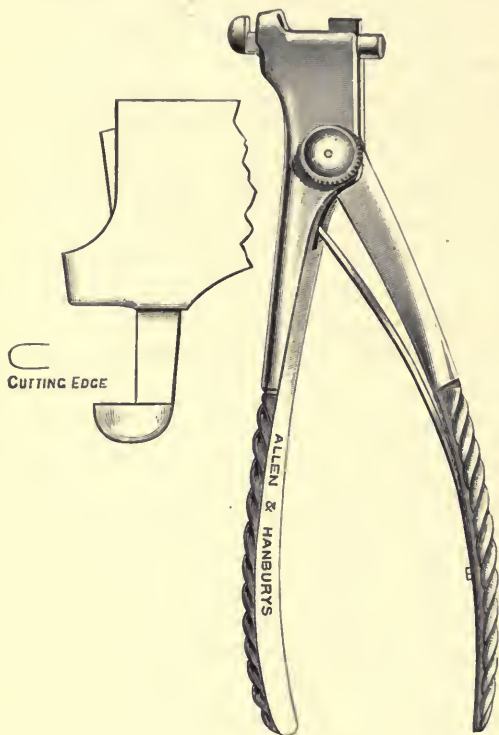


FIG. 221. DE VILBISS'S SKULL FORCEPS. These will cut a track through the skull the width of the cutting edge of the blade. They are very powerful and the work can be done rapidly.



FIG. 222. GUARDED CHISEL FOR SKULL OPERATIONS. The probe-like projection is inserted between the dura mater and the bone. The chisel can only be used from a large trephine hole.

From each trephine hole a vertical incision, made in the same way, is carried down to the base of the bone flap; some surgeons make a trephine hole at each inferior angle also, but this is unnecessary. A rectangular portion of bone is thus divided from the surrounding skull around three of its sides and only remains attached by its base; this, being thin, can be fractured by levering the bone flap outwards with a strong elevator introduced into the upper horizontal cut. In this way a flap is reflected

which consists of the scalp and the subjacent area of the skull, the latter still maintaining its vascular connexions with the soft parts (see Fig. 224). The reflected flap should be covered with a sterilized cloth during the operation, at the end of which it can be replaced accurately by merely turning it up into position; owing to the fact that the vascular connexion between the bone and the soft parts is unimpaired, the bone does not undergo necrosis unless the wound becomes septic. If the flap be cut in the manner above indicated the length of time taken by the

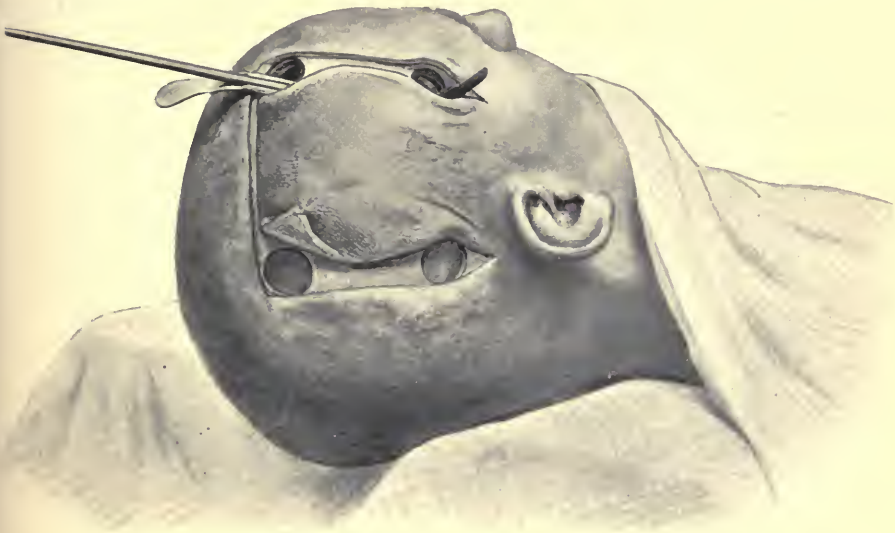


FIG. 223. GIGLI'S WIRE SAW INTRODUCER. The saw itself is seen in Fig. 25. This figure (for which I am indebted to Mr. Louis B. Rawling) shows the flexible whalebone introducer in place with the metal guard over it, preliminary to drawing the saw into place by means of the whalebone guide. It will be noticed that the operation here illustrated is not for removal of the Gasserian ganglion. It illustrates Mr. Rawling's description of the formation of osteoplastic flaps.

operation is only increased by about twenty to thirty minutes. The important practical point is to make the flap large enough in the first instance to enable the manipulations to be carried out successfully without any necessity for enlarging the opening in the bone subsequently. The reason why an osteoplastic flap is useful in this operation and not in the preceding one is that the opening is higher up on the side of the skull and therefore needs protection.

The reflection of the osteoplastic flap exposes the dura mater, which must be lifted out of the middle fossa of the base of the skull until the ganglion and its branches are exposed and can be treated in the manner

already described (see p. 441). The task of raising the dura from the bone is more tedious and difficult than in the method first described, owing to the fact that in the operation under consideration (Hartley-Krause) the skull is opened higher up and therefore considerable compression has to be applied to the superjacent brain, which has to be pressed out of the way in order to get proper access to the nerves and the ganglion.

Doyen's method. In this operation the sickle-shaped incision (Fig. 214) already described (see p. 439) is employed. After the skin flap

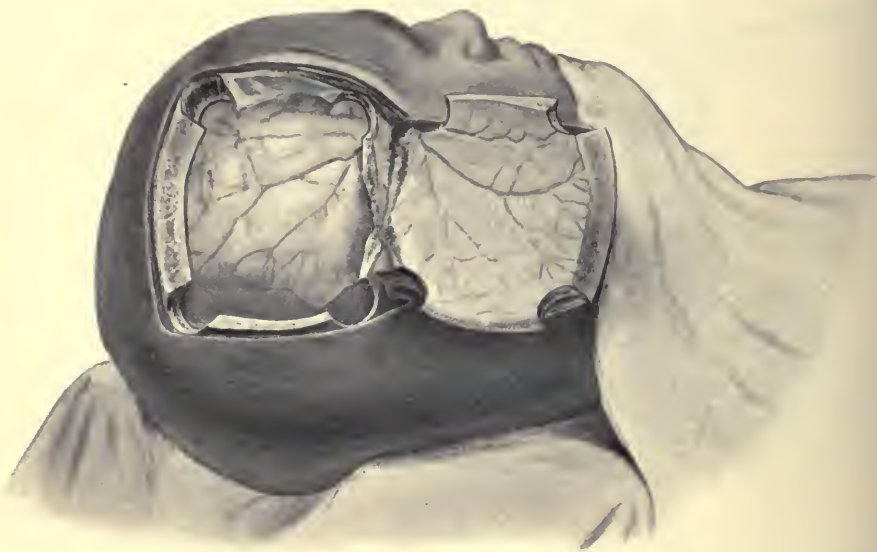


FIG. 224. OSTEOPLASTIC FLAP REFLECTED. The base has been broken through and the flap thrown down. This is another of Mr. Rawling's illustrations, and the method employed differs in slight particulars from that described in the text.

has been reflected, the zygoma and the coronoid process are divided, just as in Cushing's operation. The third division of the fifth is then identified at its exit from the skull and cut as long as possible, and a stout silk ligature fastened to its proximal end. The internal maxillary artery is tied close to its origin. The skull is opened on the level of the temporo-sphenoidal suture with a trephine, after which that portion of the greater wing of the sphenoid and the squamous portion of the temporal bone intervening between the opening in the skull and the foramen ovale (see Fig. 225) is cut away with powerful cutting-pliers or a chisel or gouge, the dura being raised and protected from injury by a fine spatula. When the outer

margin of the foramen ovale has been removed, traction upon the third division guides the surgeon to the ganglion, which is raised from its bed, divided at its junction with the trunk of the trigeminal, pulled forwards, and removed by cutting across its three branches on the distal side of the ganglion.

In this operation it is rather easier to avoid wounding the cavernous sinus, but the bleeding from the pterygoid plexus of veins is usually severe, and the field of operation is somewhat cramped and difficult to

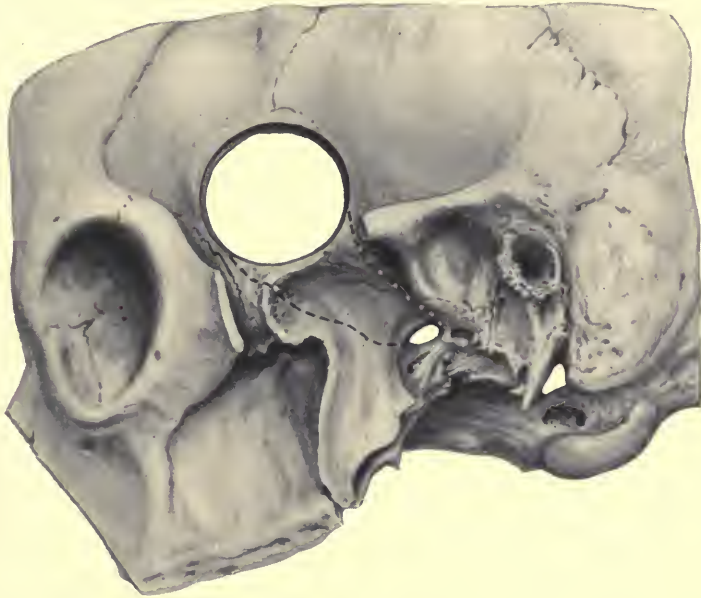

FIG. 225. DOYEN'S BONE SECTION FOR REMOVAL OF THE GASSERIAN GANGLION. The circular incision is the trephine opening.

keep bloodless. Firm packing and the free use of adrenalin will be necessary.

Results. On the whole the results of removal of the Gasserian ganglion are favourable, although the death-rate in the past has been considerable. This should improve in the future, as a number of the deaths appear to have been due entirely to sepsis. Abbé (*Annals of Surgery*, vol. xxxvii, 1903, p. 1), quoting from Léxer (*Archiv. f. klin. Chir.*, vol. lxxv, p. 1902), says that of 201 cases collected by Türk 85 per cent. survived the operation and 77.6 per cent. were permanently cured; 17 died on the table, 11 without regaining consciousness; 9 died of sepsis, 1 of hæmorrhage, 2 of brain tumour, 2 of post-operative pneumonia, 1 of heart failure, 1 of uræmia, and 1 of cerebral softening.

The immediate effect of the operation is loss of sensation over the affected side of the face, but this is considerably diminished in the course of a few weeks. The chief trouble is ulceration of the cornea on the affected side, which, however, is not a necessary accompaniment of the operation, and is best guarded against by keeping the eye well protected from the light and from all forms of irritation, however slight. At the operation, and for the first four or five days following it, the eye is protected by stitching the lids together (see p. 438). After the stitches have been removed, the conjunctiva is washed twice or three times a day with warm boric lotion, and the eye protected by a pad and bandage for three weeks or longer. The patient should wear protective glasses for the rest of his life, as the least irritation of the insensitive cornea may end in loss of the eye.

Recurrence of the pain rarely occurs when the ganglion has been completely removed. It may spread to the opposite side, and it has been known to spread to other nerves, but as a rule the arrest of the neuralgia in the affected region is permanent, provided always that the whole of the ganglion has been removed; there should be no great difficulty about making sure of complete removal if the steps enumerated above be carefully followed.

ANASTOMOSIS OF THE FACIAL NERVE

Indications. The distal portion of the facial nerve is frequently anastomosed with the hypoglossal or the spinal accessory nerves in cases of permanent facial paralysis, usually associated with middle-ear disease. The nerve is exposed and divided at its exit from the skull through the stylo-mastoid foramen, and the distal end is implanted into the hypoglossal or the spinal accessory nerve according to the wish of the operator. In the earlier cases the spinal accessory was chosen, but, owing to the greater difficulty of the operation and to the fact that associated movements of the shoulder followed restoration of function of the facial muscles and lasted for a long time, the hypoglossal is now generally preferred as the nerve for anastomosis.

This nerve has been stretched for the cure of facial tic, but as a rule the results are not permanent. The operation is usually followed by transient facial paralysis.

The facial nerve emerges from the stylo-mastoid foramen and passes forwards through the parotid gland, crossing the external carotid artery and the branches of the temporo-maxillary (posterior facial) vein in that structure. In the neck it gives off branches to the stylo-hyoid and the posterior belly of the digastric, as well as the posterior auricular

nerve which turns up along the anterior border of the mastoid process in close connexion with the posterior auricular artery. In the parotid gland it breaks up into its terminal branches, which are distributed to the face.

Operation. The parts are shaved, the head is turned to the opposite side, and the pinna is pulled forcibly forwards. When the nerve is only to be stretched, an incision is made along the anterior margin of the mastoid process from the level of the centre of the external auditory meatus to its tip, and is curved forwards from this point to the angle of the jaw, thus marking out a somewhat crescentic flap with its convexity backwards. In thin subjects this flap is sufficient, but in fat ones it is generally advisable to make a second small incision forwards about an inch long and nearly at right angles to the former, just below the lobule of the ear, so that two small flaps are formed and a little more room is gained. When, however the nerve is to be anastomosed either to the hypoglossal or to the spinal accessory nerve the incision should start on a level with the centre of the external auditory meatus, close along the anterior border of the mastoid, and follow down the anterior margin of the sterno-mastoid to the level of the hyoid bone; should it be found necessary, a second incision one inch long and at right angles to it should pass forwards from the centre of this to the angle of the jaw. The interval between the parotid gland and the anterior margin of the sterno-mastoid is defined, and the gland is pulled forwards whilst the muscle is drawn backwards. If the gland be displaced well forwards the posterior belly of the digastric will be seen crossing the wound, and its upper margin should be defined and the nerve sought for above it. This stage of the operation is often rendered difficult by free oozing from the posterior auricular vein and some of the venous branches in the parotid which will need ligature. When the upper border of the digastric has been identified, it is usually fairly easy to make out the nerve which crosses the wound obliquely from behind forwards. It is raised upon a small hook and stretched, or, if it is to be anastomosed, it is divided at its exit from the stylo-mastoid foramen by a blunt tenotome, and its distal end is brought down to the hypoglossal or the spinal accessory nerve and anastomosed to it (*vide infra*).

WITH THE HYPOGLOSSAL NERVE

The nerve should be exposed beneath the digastric and stylo-hyoid muscles, as it lies on the outer side of the internal carotid artery. This can be done by the same incision as for ligature of the lingual artery, but this only exposes its terminal portion, which is not used for the purpose of anastomosis. In order to expose it for anastomosis with the

facial, the incision should be identical with that given above for exposure of the facial and should reach down as far as the great cornu of the hyoid bone.

The first stage of the operation is the exposure, identification, and division of the facial nerve (*vide supra*). When the facial has been identified and divided, the hypoglossal is sought for as it emerges from beneath the digastric and stylo-hyoid muscles and passes forward to supply the muscles of the tongue, turning around the origin of the occipital artery from the external carotid; it is then traced upwards beneath the digastric from that point. Division of the digastric and stylo-hyoid facilitates the anastomosis greatly and seems to be harmless. When the nerve has been cleared, the divided distal end of the facial is brought into contact with it, a slit is made in its sheath, and the cut end of the facial is inserted into it and secured in the usual way (see p. 426). The greatest gentleness must be observed in the manipulations throughout.

WITH THE SPINAL ACCESSORY NERVE

The nerve leaves the cranial cavity through the jugular foramen in the same compartment of the dura mater as the pneumogastric, and runs down the neck between the internal carotid and the jugular vein. After a short distance it passes obliquely downwards and backwards across the vein beneath the posterior belly of the digastric to the sterno-mastoid, the deep surface of which it pierces to pass obliquely through the muscle and cross the posterior triangle to become distributed to the trapezius. Its course is represented roughly by a line drawn at right angles to, and bisecting another line joining the tip of the mastoid process to the angle of the jaw. The nerve pierces the deep surface of the sterno-mastoid about two inches below the tip of the mastoid. It is very important to know the course of this nerve, as it is invariably involved in enlargement of glands in the upper part of the posterior triangle, and division of the nerve on the proximal side of the sterno-mastoid is followed by paralysis of the trapezius as well as by paralysis of that muscle.

A stout sandbag is placed beneath the shoulders, the head is thrown a little back, and the chin is turned to the opposite side. The incision commences at the tip of the mastoid process, and is similar in all respects to that for exposure of the hypoglossal nerve (*vide supra*). The anterior border of this muscle having been defined, the deep cervical fascia is opened just in front of it throughout the whole length of the incision, and the muscle is drawn firmly back, the neck being slightly flexed to facilitate this. The posterior belly of the digastric is next identified as it crosses the wound, running obliquely downwards and forwards, and its

lower margin is defined, when the nerve should be seen emerging from beneath it. Another useful landmark is the transverse process of the atlas, which can be felt easily with the finger and over which the nerve passes. Should the surgeon desire to anastomose the nerve to the facial, the spinal accessory is traced back as far as possible, the digastric and stylo-hyoid muscles being divided if necessary. The facial is then laid in apposition with the spinal accessory and grafted into it through a slit in its sheath (see p. 426).

This nerve is also occasionally divided and, still more rarely, stretched for the relief of spasmodic wryneck. Stretching and simple division of the nerve are of little use, but resection of a portion has been followed by better results.

RESECTION OF THE POSTERIOR PRIMARY DIVISIONS OF THE FIRST THREE CERVICAL NERVES

Indications. This operation is sometimes an extension of the operation for resection of the spinal accessory for severe spasmodic tic; the steps of the operation by which these nerves are exposed and resected are well described by Professor Keen (*Annals of Surgery*, 1891).

Surgical Anatomy. The posterior primary division of the first cervical nerve passes backwards between the occipital bone and the posterior arch of the atlas, and lies in the sub-occipital triangle below and behind the vertebral artery, under cover of the complexus (*semispinalis capitis*) muscle (see Fig. 226).

The posterior primary division of the second cervical nerve is the largest of all and passes backwards between the atlas and the axis below the obliquus inferior muscle. The complexus (*semispinalis capitis*) covers it and the *semispinalis colli* is to its inner side. The main trunk then pierces the complexus and the trapezius and becomes, as the greater occipital, the chief cutaneous nerve of the back of the scalp. It pierces the superficial fascia on the level of the superior curved line about an inch from the external occipital protuberance. It usually accompanies the occipital artery.

The posterior primary division of the third cervical nerve is much smaller than the second, with which it communicates by a loop.

Operation. Professor Keen recommends a transverse incision half an inch below the level of the lobule of the ear, commencing at the middle line of the neck behind, and running outwards for about two and a half to three inches. This, however, does not always give sufficient room to get a clear view of the structures, especially in a thick-necked subject, and a better plan is to raise a flap outwards from the middle line, which

will expose the whole area concerned fully. An incision is made in the middle line of the neck behind, beginning about half an inch below the external occipital protuberance, and running vertically down for nearly three inches; from each end of this an incision about an inch and a half long is carried transversely outwards on to the neck. The flap thus marked out is dissected up.

The first nerve to be identified is the greater occipital, and this is found by dividing the trapezius horizontally near the upper limit of

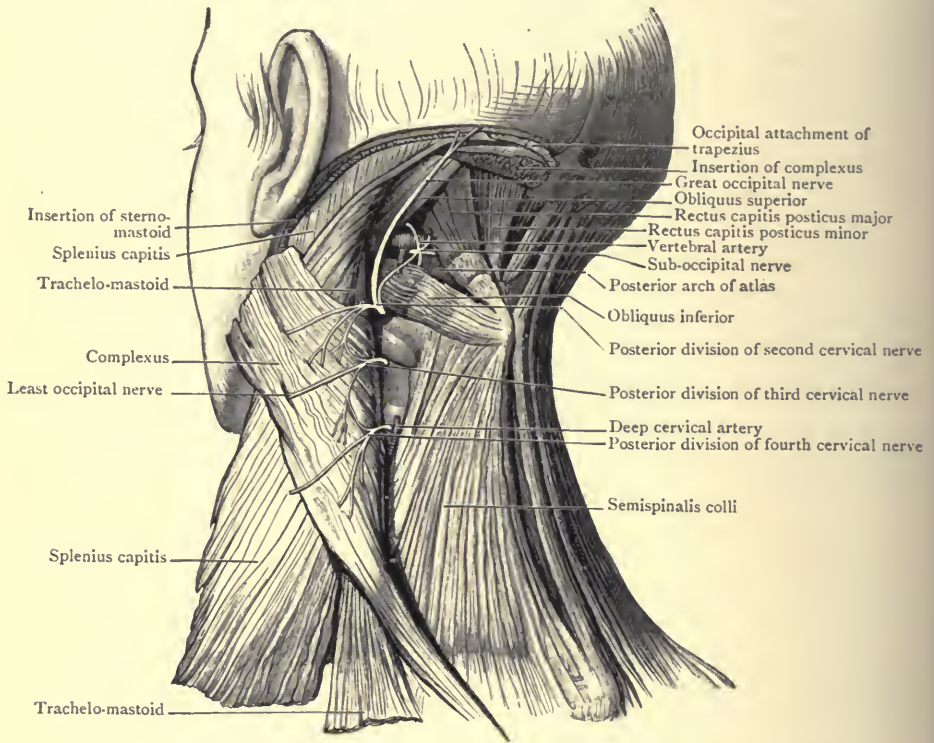


FIG. 226. POSTERIOR CERVICAL PLEXUS (Cunningham's *Anatomy*).

the incision, and finding the nerve as it emerges from the complexus (semispinalis capitis) about midway between the aponeurosis and the middle line. The complexus is divided transversely at the point at which the nerve emerges from it, and the latter is traced backwards until the posterior primary division of the second cervical is reached, when it is resected on the proximal side of the greater occipital, which is the larger of the two terminal branches into which it divides.

The next step is to identify the sub-occipital nerve, which is done by defining the boundaries of the sub-occipital triangle in which the

nerve lies (see Fig. 226); they are the obliquus capitis inferior and superior, and the rectus capitis posticus (posterior) major. When found, the nerve is traced as far back as possible and resected. The final step is to identify and divide the third cervical nerve, which may be done by tracing down the loop between it and the second until the posterior primary division of the third is reached; it is then divided beneath the complexus (semispinalis capitis).

EXPOSURE OF THE BRACHIAL PLEXUS IN THE NECK

Indications. This operation is rarely called for; it may be needed for a direct injury to the plexus, such as a stab, or for a laceration produced by violent traction upon the arm. More rarely still there may be pressure upon the plexus from a supernumerary cervical rib, or possibly from a tumour in the neck.

Operation. This is similar to that for the ligation of the third part of the subclavian artery (see p. 373). The position of the patient is the same as for that operation, viz. the head is turned to the opposite side and the arm is drawn down to its full extent. In a thin subject the cords of the brachial plexus can generally be felt beneath the skin in the supra-clavicular space, and may be exposed by making an almost vertical incision over the lower part of the posterior triangle midway between the adjacent borders of the sterno-mastoid and the trapezius. The external jugular vein will get in the way and may have to be ligatured; if so, this should be done well above the point at which it pierces the deep fascia. As the wound is deepened the plexus comes into view, and the outer border of the anterior scalene muscle can be defined. The transverse cervical artery and vein cross the wound transversely, parallel with the clavicle, and should be pulled downwards out of the way.

Mr. C. A. Ballance showed at the Royal Society of Medicine on May 8, 1908, a child aged 5 years, upon whom he had operated for suture of the upper cord of the brachial plexus which had occurred during childbirth. The deltoid, biceps, brachialis anticus, coracobrachialis, and supinator longus (brachio-radialis) were partly paralysed. The child was ten months of age at the time of the operation, which was in October, 1903. The fifth cervical was found to be ruptured just where it joins the sixth; after the ends had been refreshed there was three-quarters of an inch between them, but by a little dissection the ends came together easily and were sutured with very fine silk. The nerves were identified at the operation by stimulation. The child was

lost sight of immediately after the operation and only came under notice after four years' absence, when the paralysed muscles had completely recovered. In this case ten months had intervened between the injury and operation, and nevertheless the result was perfect. It tends to show that perfect results can be got by suture as long as it is possible to get good response to electric stimulation under an anæsthetic.

CHAPTER III

OPERATIONS UPON THE NERVES OF THE EXTREMITIES

EXPOSURE OF THE MEDIAN NERVE

Indications. The median nerve has frequently to be exposed in order to suture it after it has suffered accidental division. It may be reached in any of the following situations:—

- (i) In the middle of the upper arm.
- (ii) At the bend of the elbow.
- (iii) Above the wrist.

Surgical anatomy. The nerve passes down the arm in close relation with the brachial artery, lying at first to its outer side, then crossing over the front of the artery about its middle, and finally lying to its inner side at the bend of the elbow, where it lies beneath the bicipital fascia (lacertus fibrosus of the biceps) and the median basilic vein. It enters the forearm between the two heads of the pronator radii teres and is separated from the ulnar artery by the deep head of that muscle. In the forearm it lies between the superficial and deep muscles, and at the front of the wrist it lies beneath and somewhat to the radial side of the palmaris longus tendon, between it and that of the flexor carpi radialis muscle.

In the middle of the arm. The operation in this situation does not require detailed notice as it is similar in all respects to exposure of the brachial artery in the middle of the upper arm (see p. 355). The median nerve will be exposed immediately before the artery is seen.

In the front of the elbow. The nerve will rarely require to be exposed in this situation, but, should such an operation be necessary, it is very similar to that for exposure of the brachial artery at the bend of the elbow (see p. 358). The incision, however, should be made about half an inch internal to the biceps tendon instead of close along its inner edge. The nerve will be exposed internal to the brachial artery beneath the bicipital fascia upon which lies the median basilic vein. It usually lies about a quarter of an inch internal to the brachial artery, and if the incision recommended above be adopted the nerve will be exposed directly and the artery may not be seen.

Above the front of the wrist. It is in this situation that the

median nerve has to be exposed most frequently, as it is on the front of the wrist that the injuries to it usually occur. In order to repair damage of long standing to the median nerve it will be necessary to expose that structure where it is healthy and trace it down to the seat of injury. For this purpose it is exposed about a finger's breadth above the transverse crease on the front of the wrist as it is passing beneath the annular (transverse carpal) ligament. It lies either beneath or just to the radial side of the palmaris longus tendon, which can always be identified in the living subject, but which may be somewhat difficult to make out in the cadaver. In these cases a useful guide is the flexor carpi radialis, which can always be felt, and to the ulnar side of which the nerve is situated.

An incision about three-quarters of an inch long is made over the radial border of the palmaris longus tendon, the space between it and the flexor carpi radialis is opened up, and the nerve is seen lying somewhat deeply between them. The nerve is a large structure which may sometimes be mistaken for a tendon, but the difference in its colour will prevent mistakes. In this situation it is becoming somewhat flattened previous to dividing into its terminal branches.

EXPOSURE OF THE ULNAR NERVE

Indications. The ulnar nerve may have to be exposed in any part of its course, but it is generally damaged either in the ulnar groove at the back of the elbow or just above the wrist. In the former situation it is not infrequently involved in fractures or injuries about the elbow, but the most frequent lesion for which operation is required is partial or entire division of the nerve at the front of the wrist, in wounds caused by such accidents as putting the hand through a pane of glass. In recent cases, of course, there will be a wound which only needs to be enlarged in order to find the nerve. When, however, the case is of long standing the wound will have healed, and it will then be necessary to expose the nerve upon the proximal side of the cicatrix and to trace it down to where it becomes involved in the scar tissue. When the nerve is damaged above the elbow there is occasionally no wound, and the nerve has to be found from its anatomical guides.

Surgical anatomy. In the axilla the nerve lies between the axillary artery and vein, deep to them and to the internal (medial ante-brachial) cutaneous nerve. It passes down in front of the triceps to the inner side of the brachial artery as far as the centre of the arm, where it pierces the internal inter-muscular septum along with the inferior profunda (superior ulnar collateral) artery to reach the interval between the olecranon and the internal condyle, where it lies

in a deep bony groove protected by a special arch of deep fascia. It passes into the forearm between the heads of origin of the flexor carpi ulnaris and lies between that muscle and the flexor digitorum profundus, lying to the inner side of the ulnar artery.

The anatomical line of the nerve in the arm is from the junction of the anterior with the middle third of a vertical line let fall from the anterior to the posterior fold of the axilla, down to the groove behind the internal condyle of the humerus. In the forearm the course of the nerve is sufficiently accurately defined by drawing a line from the back of the internal condyle to the radial side of the pisiform bone.

In the upper arm. When the nerve has to be exposed anywhere in the upper half of the arm the operation requires no special description, since it resolves itself into exposure of the brachial artery (see p. 355), upon the inner side of which the ulnar nerve lies.

When it has to be exposed below the middle of the arm an incision is made upon the back of the limb as a prolongation upwards of the ulnar groove at the back of the condyle. The nerve can then be traced to the back of the condyle or to the point at which it pierces the internal inter-muscular septum.

In the forearm. Here the operation for exposing the nerve is similar in all respects to that for exposure of the ulnar artery (see p. 350), internal to which the nerve lies.

EXPOSURE OF THE MUSCULO-SPIRAL NERVE

Indications. This nerve is rarely divided by wounds or stabs, but it is not infrequently damaged in fractures of the shaft of the humerus owing to its close proximity to the bone as it winds round the humerus in the musculo-spiral groove. Its terminal branches may also be implicated in fractures of the external condyle of the humerus.

Surgical anatomy. In the axilla the nerve lies behind the axillary artery upon the subscapularis, teres major, and latissimus dorsi muscles. It passes backwards upon the long head of the triceps to reach the musculo-spiral groove along with the superior profunda artery, winding obliquely outwards and downwards to the lower third of the arm, where it pierces the external inter-muscular septum from behind forwards, and reaches the bend of the elbow in the interval between the brachialis anticus (brachialis) and the supinator longus (brachio-radialis). Beneath the latter muscle it divides into its two terminal branches, the radial (superficial radial) and posterior interosseous (deep radial) nerves. The level at which this nerve divides varies considerably.

The nerve may require exposure either opposite the centre of the musculo-spiral groove, or in front of the elbow.

On the back of the arm. Perhaps the simplest plan is to expose the nerve about the centre of the groove by a vertical incision which separates the fibres of the triceps longitudinally. There are many incisions given, but on the whole this is the simplest and safest method, and it has the merit of being the most useful one in the majority of cases, as it is in fractures about the centre of the bone that the musculo-spiral nerve becomes implicated, either at the time of the accident or subsequently, in consequence of pressure from callus.

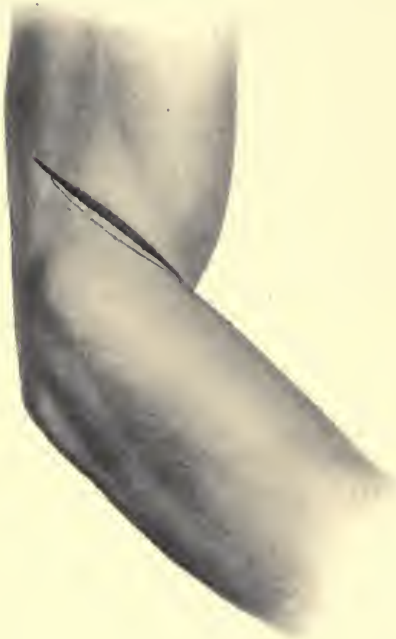

FIG. 227. INCISION FOR EXPOSURE OF THE MUSCULO-SPIRAL NERVE AT THE BEND OF THE ELBOW. The forearm is fully pronated and the elbow is at an angle of 135° . The figure shows that the incision is a prolongation upwards of the radial border of the forearm.

The elbow is flexed to a right angle and the upper arm is held in the vertical position by an assistant. The surgeon makes an incision nearly four inches in length along the middle line of the posterior aspect of the arm, having its centre opposite the centre of the bone, that is to say, on a level with the insertion of the deltoid. The incision is deepened until the triceps is reached, and the muscular and tendinous fibres are then divided vertically, partly by the blade and partly by the handle of the knife, until the bone is reached, when the nerve will be seen lying in the musculo-spiral groove along with the superior profunda vessels, and crossing the field of operation obliquely.

In this operation no muscular fibres are divided and the parts fall together easily after the operation is concluded.

In front of the elbow-joint. Exposure of the nerve in this situation may be required in cases of fracture involving the external condyle and damaging the nerve.

The elbow-joint is flexed to an angle of 135° and fully pronated by an assistant. An oblique incision is made across the lower end of the upper arm, the line being a direct continuation backwards of the outer or radial border of the forearm (see Fig. 227). If this incision be

planned properly, and care be taken to pronate the limb fully, the interval between the supinator longus (brachio-radialis) on the outside, and the brachialis anticus (brachialis) on the inner side, will be hit off with little difficulty. When the interval between these two muscles is found—and it is usually denoted by a fatty interval in which small branches of the superior profunda are seen emerging—the muscles are separated by the handle of the knife, and the nerve is found in the interval

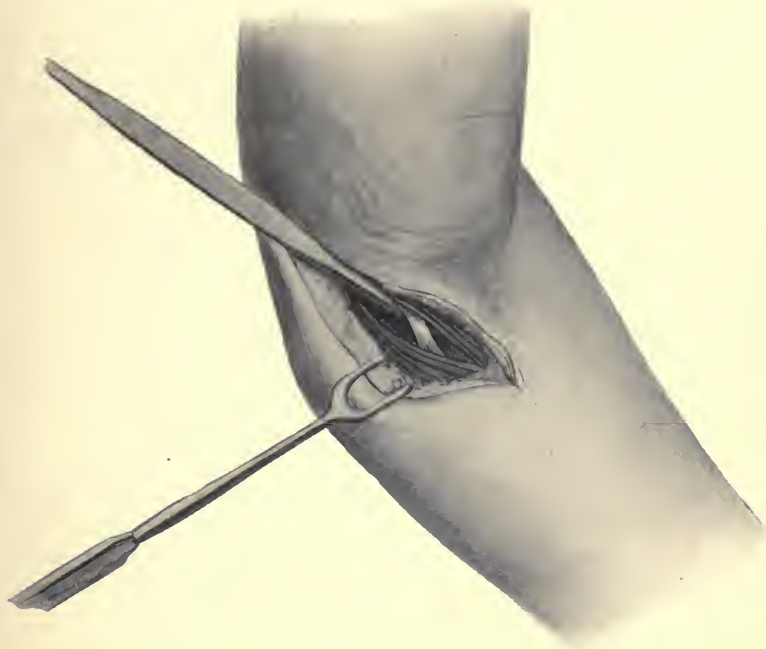


FIG. 228. EXPOSURE OF THE MUSCULO-SPIRAL NERVE IN FRONT OF THE ELBOW. The muscle on the left-hand side is the supinator longus (brachio-radialis), and that on the right is the brachialis anticus. The nerve lies deeply between the two.

between them crossing the incision almost vertically from above downwards (see Fig. 228).

Difficulties. This operation is difficult unless the interval between the two muscles mentioned above be hit off accurately. The supinator longus (brachio-radialis) has a long attachment to the external inter-muscular septum and extends higher up the arm than one is apt to think ; the inter-muscular septum between it and the brachialis anticus (brachialis) easily escapes notice, as the fibres of the two muscles run very much in the same direction. The position recommended above serves to define the supinator longus better than any other, and, if it be used, there should be little difficulty in finding the nerve.

EXPOSURE OF THE GREAT SCIATIC NERVE

Indications. The operation of stretching the great sciatic nerve either subcutaneously or after exposure by operation was formerly much in vogue for the relief of obstinate sciatica. At the present time, however, it is only rarely done, but it may be necessary, occasionally, for cases of simple sciatica which do not yield to medical treatment. For this purpose the nerve is exposed just below the fold of the buttock.

Surgical anatomy. The nerve emerges from the great sacro-sciatic foramen below the pyriformis muscle and extends from that point to its division into the internal and external popliteal branches. The level at which the division takes place varies considerably; it may occur nearly as low down as the popliteal space, whilst sometimes the two branches are distinct from the point of emergence of the nerve from the pelvis.

The surface line of the nerve is from the mid-point between the tuber ischii and the great trochanter to the centre of the popliteal space. In the buttock the nerve lies beneath the gluteus maximus and has the origin of the hamstring muscles internal to it. In the thigh it passes beneath the hamstrings and lies upon the adductor magnus. It is the strongest nerve in the body, and is nearly half an inch in breadth. It is said to be able to withstand a tensile strain of nearly 100 lb. without rupture.

Operation. The patient lies as nearly flat upon his face as the exigencies of the anæsthetic will permit. The surgeon makes an incision four inches long in the line of the nerve (*vide supra*) running downwards from the fold of the buttock. It is important that the incision should not be made higher than this, for the lower edge of the gluteus maximus always extends a full inch below the fold of the buttock, and if the centre of the incision be made to lie over the gluteal fold, as it often is, the gluteus maximus will cover the whole of the wound, and this greatly interferes with exposure of the nerve.

When the fat and the deep fascia of the buttock have been opened up, the coarse fibres of the gluteus maximus are seen running obliquely downwards and outwards. The lower border of this muscle is defined and pulled up with retractors, when the mass of the hamstring muscles will be found lying immediately beneath the incision but on a deeper plane than the gluteus maximus. The outer border of these is defined and the whole mass is pushed bodily inwards, when the firm rounded sciatic nerve is felt lying to their outer side and on a somewhat deeper plane still (see Fig. 229). In a muscular subject it will be necessary to flex the knee in order to relax the hamstrings sufficiently to allow them to be pulled well inwards. The sciatic nerve is easily recognized by

its size and by the fact that it lies in a mass of fat and has comparatively large vessels (comes nervi ischiadici) over it.

A large blunt hook is now passed beneath the nerve, which is cleared by a few touches of the knife, the index and middle fingers are hooked beneath it, and the nerve is drawn well up to the surface. It is quite

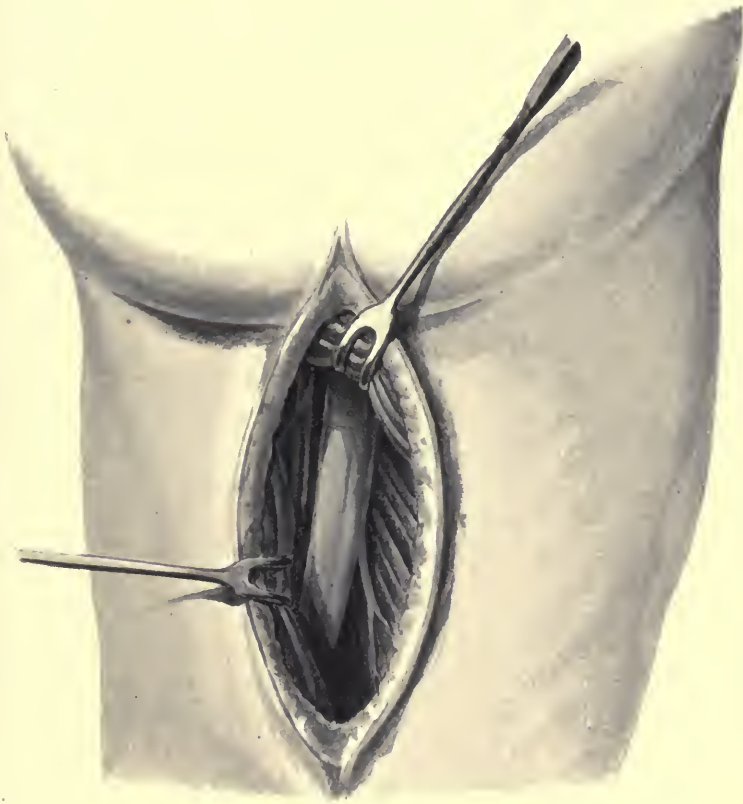

FIG. 229. EXPOSURE OF THE GREAT SCIATIC NERVE. The upper retractor pulls back the lower border of the gluteus maximus. The left-hand one is retracting the hamstring muscles. The great sciatic nerve lies beneath these.

safe to apply sufficient traction on the nerve to lift the limb off the table, but this should be done from the wound towards the extremity rather than towards the spine, as there is then no risk of tearing the nerve from the spinal cord; the nerve should be stretched in both directions, but only about half the pull should be exerted towards the spine. It should be stretched sufficiently to allow two fingers passed beneath it to lie flush with the skin of the back of the thigh. The wound is

closed without a drainage tube. The paralysis produced by the stretching soon passes off.

EXPOSURE OF THE INTERNAL POPLITEAL (TIBIAL) NERVE

This is the direct continuation of the great sciatic nerve, and passes down the centre of the popliteal space to become the (posterior) tibial nerve at the lower border of the popliteus muscles. It may be exposed for the purpose of anastomosing it to the external branch (see p. 428). This nerve is so closely associated with the popliteal artery that the operation for exposing the nerve is similar in all respects to that required for the exposure of the artery. The nerve lies at first to the outer side, then behind, and finally to the inner side of the vessel. If it has to be exposed, the operation will be similar to that for ligature of the popliteal artery at the lower part of the popliteal space (see p. 311).

EXPOSURE OF THE EXTERNAL POPLITEAL (COMMON PERONEAL) NERVE

This terminal branch of the great sciatic lies close to the outer side of the popliteal space and crosses the outer head of the gastrocnemius to reach the neck of the fibula immediately behind or below the tendon of the biceps muscle. The nerve may be felt against the bone about an inch below the insertion of the tendon into the top of the fibula. It may require to be exposed in order to anastomose it into the internal trunk (see p. 428).

Operation. The limb is flexed and rotated fully inwards, and a two-inch incision is made parallel to and half an inch behind the tendon of the biceps, the centre of the incision being over the point of insertion of the tendon into the bone. When the skin has been divided, the limb is flexed somewhat and the nerve will be found behind and below the tendon as soon as the deep fascia has been incised.

EXPOSURE OF THE ANTERIOR CRURAL (FEMORAL) NERVE

This nerve passes into the thigh beneath Poupart's ligament about half an inch to the outer side of the femoral artery, and lies between the psoas and iliacus muscles, the former of which separates it from the artery. It breaks up into its terminal branches about one inch below the ligament, and the incision to expose it should therefore commence above Poupart's ligament and should be about two inches in length, lying one inch external to the mid-point between the anterior superior iliac spine and the symphysis pubis. The nerve will be exposed as soon as the deep fascia has been divided.

SECTION VI

OPERATIONS UPON MUSCLES, TENDONS,
TENDON SHEATHS, AND BURSÆ

BY

FRED^c. F. BURGHARD, M.S. (Lond.), F.R.C.S. (Eng.)

Teacher of Operative Surgery in King's College, London; Surgeon to King's
College Hospital; and Senior Surgeon to the Children's Hospital,
Paddington Green

CHAPTER I

OPERATIONS UPON MUSCLES

MUSCLE SUTURE

Indications. (i) For the repair of muscles divided during the course of an operation.

Familiar examples of this are suture of the sterno-mastoid after ligature of the innominate by the Δ -incision (see p. 366) or of the

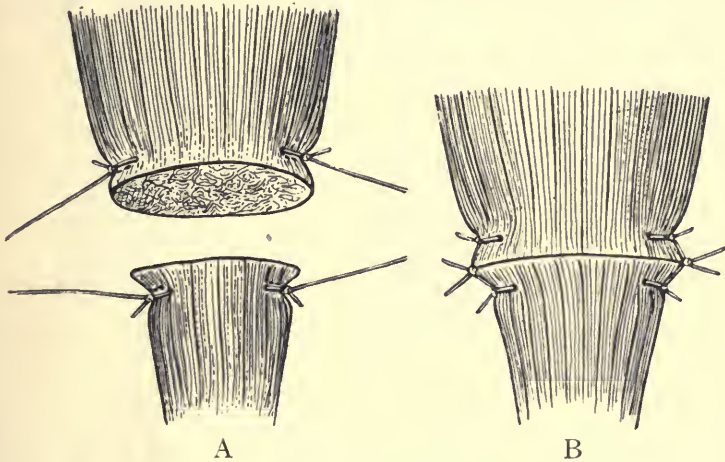


FIG. 230. MUSCLE SUTURES. A shows the method of securing a suture on each side so that it will not tear out between the muscle fibres. B shows the method of approximating the divided ends of the muscle by tying the suture above to the corresponding one below. Quite firm traction can be employed, as there is no risk of the included mass of muscle slipping through the suture.

clavicular fibres of the pectoralis major after ligature of the first part of the axillary (see p. 360).

(ii) For the repair of muscles that have ruptured spontaneously, *e. g.* the biceps, rectus abdominis, &c.

Operation. Muscle is a difficult structure to suture satisfactorily. It is made up of bundles of parallel fibres, and the contraction of the muscle makes the sutures cut their way out very soon unless some special means are taken to prevent it. Practically there is no suture that will withstand the pull of the muscle except one that takes a firm grip of

a portion of the muscular fibres before it is tied. A suture of the kind is seen in Fig. 230, and resembles in all respects that for suture of a tendon. The suture—moderately fine chromicized catgut is the best—is made to transfix a small portion of the edge of the muscle at right angles to its long axis about half an inch from the seat of rupture on one side, and that portion is tied moderately tightly in the suture, the ends of which are left long. A similar suture is now inserted on the opposite side of the rupture, and the ends of this suture are fastened

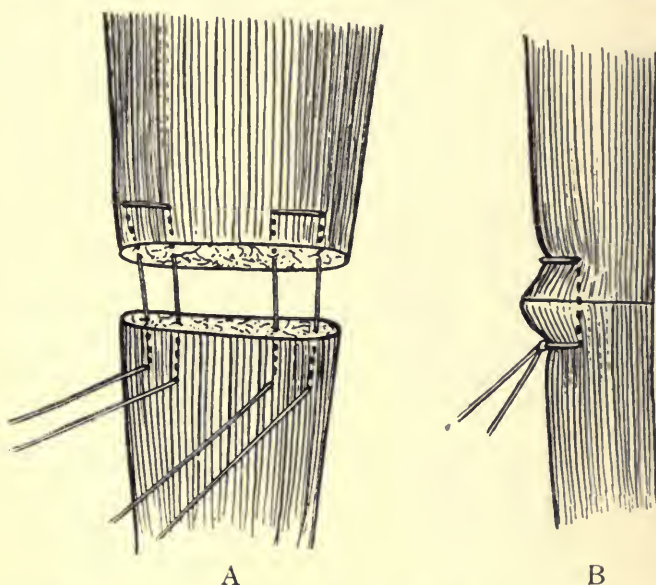


FIG. 231. MATTRESS SUTURES FOR UNITING MUSCLE. A shows the method of introducing these sutures, which are of the ordinary mattress variety. The ends of the muscle are then approximated and the sutures are tied as is seen in B. The effect of tightening the suture is to cause a projection on the muscle as shown in the figure, which prevents the fibres escaping from the grasp of the suture.

to the ends of the former one, the limb meanwhile being put into a position in which the muscle will be relaxed to its utmost extent.

At least two, and preferably four, of these sutures should be inserted in order to take the pull of the muscle. Accurate coaptation may be effected by means of simple through-and-through sutures.

In flat muscles the mattress suture (see Fig. 231) may be useful occasionally, but the one first described will be generally employed. Whenever the muscle is tendinous in parts, the suture should take in the tendinous portion if possible.

There are a few practical points of importance that should be attended to if the best result is to be obtained. The gap in the muscle should

never coincide with the skin incision if this can be avoided, as an adherent scar is very likely to follow, and this interferes materially with the working of the muscle. Therefore, when it is known that a muscle will have to be divided and reunited in the course of any operation, the two incisions must be planned so as to avoid correspondence. When the operation is done for subcutaneous rupture of a muscle, the gap should

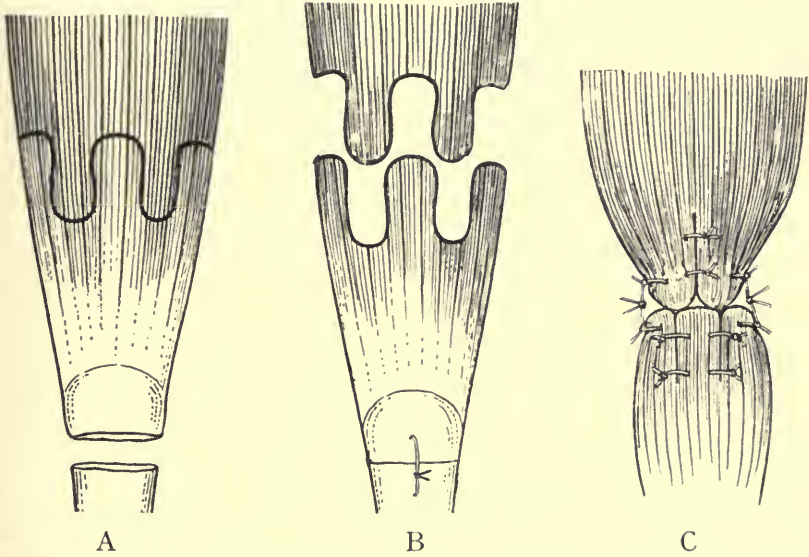


FIG. 232. MUSCLE-LENGTHENING. The method shown is the one described as the 'multiple cone' incision. A shows the manner in which the incision is made across the muscle, B the way in which the lengthening is produced after the incision. C shows the various projections united into one mass on each side of the incision and the two ends of the muscle then sutured by the stitch shown in Fig. 230. It is obvious that no incision through muscular tissue could approach the accuracy depicted in the diagram.

be exposed by raising a flap, the incision for which should be placed at some distance from the actual gap.

The strain on the line of union should be distributed as evenly as possible among the sutures, and a good number of these should be inserted so as to minimize the strain on any individual one. It is not necessary to cut away fibrous tissue between the ends in long-standing cases as it is in nerve suture.

The limb must always be put up on a splint that will relax the affected muscle to the utmost. It should be kept in the fully relaxed position for a fortnight, after which time it may be extended gradually.

MUSCLE-LENGTHENING

A muscle should never be lengthened when its tendon can be got at and treated in the same way; tendons unite much more satisfactorily than do muscles. It may possibly be called for in rupture of the biceps of long standing, where the contraction of the divided ends is extreme, although I have never met with a case in which the ends could not be brought into apposition by other means. It has been advocated for operations for long-standing fractures of the olecranon and patella, but Lord Lister's plan of gradual stretching is much better for the patella; in the olecranon the presence of the triceps aponeurosis makes the operation practically one of tendon-lengthening.

Operation. There are two methods of performing the operation. They are (a) the \wedge -incision and (b) the 'multiple cone' incision.

(a) *The \wedge -incision* is the simpler method and likely to give the better result. It may be used perhaps when there is difficulty in getting the fragments to meet in fractures of the olecranon of long standing (see p. 568). It gives ample lengthening, but the best results are likely to ensue where there is a good deal of fibrous aponeurosis in the muscle.

(b) *The 'multiple cone' incision.* This method is shown in Fig. 232, and is more valuable in theory than in practice. The difficulty is that the incision is through muscle fibre, and is therefore impossible to fashion with accuracy, while the net result is very little, owing to the contraction of the muscular fibres.

CHAPTER II
OPERATIONS UPON TENDONS
TENOTOMY

Indications. Tenotomy, or division of a tendon, may be required :—

(i) For the relief of various deformities due to infantile paralysis. These may occur in any part of the body, but are commonest about the foot. In the majority of cases the tenotomy will be done by the subcutaneous method.

(ii) For the relief of deformities following upon cicatricial contractions from wounds, burns, &c. In these cases the open method should always be employed, as the parts are always distorted by the deformity, and great care is required in the identification of the structures divided.

(iii) For wry-neck of the permanent or non-spasmodic form. In these cases the sternal, and possibly the clavicular, head of the sternomastoid will require division, which should always be done by the open method.

(iv) For deformity resulting from spastic paraplegia. Cases of this kind are often improved by division of the tendons of the muscles that are in a state of spastic contraction ; for example, walking may be greatly facilitated by division of the tendo Achillis.

(v) To prevent tilting of the heel after an operation such as Chopart's amputation ; it is rarely used nowadays for this purpose, however.

A tendon may be divided either by the open or the subcutaneous method. In the former it is exposed by a suitable incision in the skin, and is then divided with an ordinary scalpel. In the latter method a special small knife called a tenotome (see Fig. 233) is introduced through a minute puncture in the skin, and the tendon is divided, the knife being guided merely by the sense of touch. Any tendon may be divided by either of these methods ; formerly the subcutaneous method was almost invariably practised, because it was less likely to be followed by sepsis. It was generally recognized that when air did not gain free access to a wound, suppuration was unlikely to follow, and hence subcutaneous operations became popular. At the present time, however, this has no weight, and the merits of the open and sub-

cutaneous methods have to be considered apart from the question of sepsis. Each has its distinct advantages and disadvantages.

The open method should be chosen :—

(i) When there are important structures in the immediate neighbourhood of the tendon which may be damaged by the tenotome. Examples of this are seen in the case of division of the sternal head of the sterno-mastoid, or of the biceps tendon in the leg. In each case

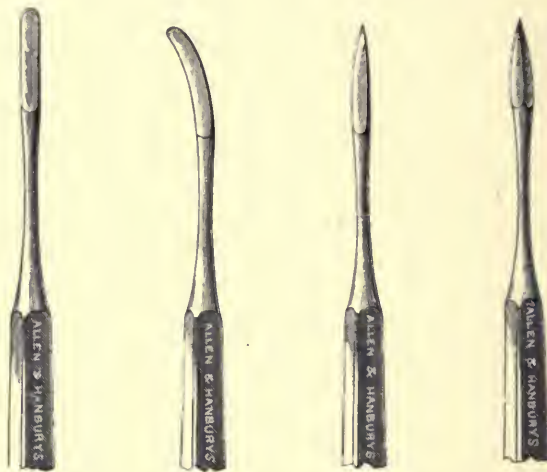


FIG. 233. TENOTOMES. The various forms of tenotomy knives are shown above. From left to right they are :—The straight blunt-pointed form, substituted for the sharp-pointed one when there are important structures to be avoided. Next comes the blunt-pointed curved tenotome, which is useful when a tendon lying over a curved bony surface has to be cut down upon from the front. The next in order is the ordinary sharp-pointed tenotome, and the one on the extreme right is the double-edged variety of the same instrument. The latter is particularly useful for division of ligaments, which it can divide by being moved from side to side.

a subcutaneous operation is fraught with great danger to important structures.

(ii) When division of a particular tendon is only a part of the operation required for the cure of the deformity. It not infrequently happens that, besides the tendon, the fascial structures in the neighbourhood, and sometimes the ligaments of a neighbouring joint, require division before the deformity can be properly corrected. An example of this is seen in wry-neck, where not only may both heads of the sterno-mastoid be affected, but the deep fascia of the neck, and even the sheath of the great vessels, may be so contracted as to require division; this can only be done by free exposure of the parts and most careful dissection. The tendency is to use the open method more frequently at the

present time, as its great advantage is its certainty and safety. It has, however, the disadvantage that it leaves a wound that requires suturing, and is therefore longer in healing and less sightly than the mere puncture left by the tenotome.

The subcutaneous method is exceedingly simple and is quite safe in suitable cases, while at the same time it is effective and leaves no scar. It is pre-eminently the operation for isolated and well-defined tendons which have no important structures in their immediate neighbourhood.

Certain precautions are necessary for due success in performing tenotomy. When it is desired that the divided tendon should subsequently reunite, as, for example, in the case of the tendo Achillis in talipes equinus, it is important that the division should not be practised where the tendon runs in a definite synovial sheath, such as those about the ankle or the front of the wrist. When a tendon is divided in these situations, the plastic material thrown out between the divided ends causes them to adhere to the synovial sheath, with the result that, although the ends may unite, the movement of the tendon is hampered, if not entirely destroyed, by its adhesion to the sheath. If, therefore, it be found necessary to divide a tendon within its synovial sheath, as may be the case, for example, in a contracted wrist, the operation should not be a simple tenotomy, but should be some form of tendon-lengthening, the tendon being exposed by slitting up its sheath, and measures being adopted to elongate it permanently (see p. 493).

DIVISION OF THE TENDO ACHILLIS

This operation is in common use and gives excellent results. It may be done by either the subcutaneous or the open method, the former being the one in almost universal use.

Indications. (i) The chief affection for which the tendo Achillis is divided is talipes equinus. As a rule the equinus is combined with some other deformity, such as varus or valgus, and division of the tendo Achillis may either be done at the time that the varus deformity is rectified, or, preferably, some time afterwards. This on the whole gives better results, as the firm support afforded by the tendo Achillis enables the surgeon to apply the stretching necessary to overcome the varus deformity. The equinus may be either congenital or may be the result of infantile paralysis; in some cases division of the tendo Achillis will be needed for the relief of spastic contraction of the calf muscles.

When the degree of equinus is extreme, and the gap following division of the tendo Achillis will be wide enough to lead to doubt as to whether the plastic exudation thrown out between the divided ends will give sufficiently firm uniting material, it is a question whether it is not better

to abandon simple tenotomy in favour of one of the forms of tenoplasty with the object of lengthening the tendon (see p. 493). Personally, I should be inclined to make use of this latter method whenever the gap after simple tenotomy was likely to exceed three-quarters of an inch in length. It used to be the custom, however, to employ tenotomy, and after it to put the foot up at an obtuse angle to the leg, and only to bring it to a right angle by degrees.

(ii) The tendon has been divided at the end of Chopart's amputation to prevent tilting of the heel. This, however, is rarely necessary nowadays, partly because Chopart's operation is seldom done, but chiefly because the tilting of the heel occurring soon after this operation was mainly due to septic infection of the wound, and this no longer happens. The tendency to tilting at a later date is best avoided by stitching the extensor tendons to the stump.

(iii) Occasionally it may be necessary to divide the tendon in order to reduce a dislocation of the foot as in Pott's fracture, &c.

There are two methods of doing the operation :—

(a) By introducing the tenotome between the skin and the posterior surface of the tendon and cutting towards the tibia.

(b) By introducing the tenotome across the anterior surface of the tendon and cutting backwards towards the skin.

Each method has its own advocates, but there is very little to choose between them. In the former there is a little difficulty in running the tenotome between the tendon and the skin, and there is perhaps a little more risk of damaging the vessels as the last fibres of the tendon are divided. It has, however, the great advantage that it enables the surgeon to divide all tight fascial bands on the anterior surface of the tendon much more completely than is possible by the other method. On the other hand, if the tendon be divided from before backwards, it is easier to pass the tenotome across the flat anterior surface of the tendon and thus to avoid injuring the vessels. But the disadvantage of this method is that contracted fibres of the deep fascia and the tendon sheath may be left undivided, and therefore the operation will not always be as satisfactory as it should be. Moreover, an incautious cut on the part of the surgeon or an involuntary movement on the part of the patient may cause the knife to emerge through the skin and convert the tenotomy puncture into an open wound. In the tendo Achillis this is a distinct disadvantage, as it is apt to be followed by an adherent cicatrix. I prefer to divide the tendon from the skin towards the bone and have never experienced trouble from the proximity of the vessels.

Either operation may be done from the inner or the outer aspect of the limb, but usually the inner side is chosen for inserting the tenotome,

as the vessels are then out of the way of the point of the knife, which necessarily traverses a wider arc than the hilt. In order to avoid damage to the subjacent parts by the point of the knife some surgeons are in the habit of employing two tenotomes, a sharp- and a blunt-pointed one, the latter being introduced flatwise along the sharp one, which is used to make the incision down to the tendon, until it is in position, when the sharp tenotome is withdrawn and the section completed with the blunt-pointed one.

Operation. After the parts have been disinfected, the foot is wrapped in a sterilized towel and an assistant grasps it with one hand, whilst he seizes the calf, which is also wrapped in a sterilized towel, in the other. The limb is either drawn over the end of the table or is well raised from it, and is rotated so that the inner border of the tendo Achillis looks vertically upwards, the outer border of the foot, therefore, being parallel with the surface of the table. The surgeon faces the heel, and, whilst the assistant puts the tendo Achillis on the stretch by bending the front of the foot upwards, he feels for its inner border and inserts a sharp tenotome, which should have a blade half an inch long, through the skin over it about one inch above the top of the os calcis. As soon as the puncture has been made the assistant relaxes the tendo Achillis by depressing the front of the foot, and the surgeon pushes the tenotome, the blade of which should lie flatwise against the tendon, carefully round between it and the skin under the guidance of his left index finger until its point can be felt immediately beneath the skin over the outer border of the tendon. The edge is then turned towards the tendon, and the assistant puts the tendo Achillis on the stretch once more by pressing up the front of the foot as forcibly as possible. The tendon is divided by a series of short cuts mainly with the point of the tenotome. As the division nears completion a definite gap can be felt by the left index finger which is kept on the posterior surface, and the last few fibres give way with a sudden snap, leaving a well-marked interval between the divided ends, so that the surgeon knows that the tendon is completely cut in two. Before withdrawing the tenotome the finger is inserted into the gap and any contracted fibrous bands deep to the tendo Achillis are felt for, and, if present, divided by a few touches with the point of the knife. A small pad of gauze is placed over the puncture in the skin and fastened on with collodion.

Difficulties and dangers. The chief one is a wound of the tibial vessels; this is only likely to occur if too large a tenotome be used, or if the knife be introduced from the outer side and its point be swept through too large an arc during the division of the tendon. The occurrence of this accident is recognized with some degree of

certainly when a pulsating jet of arterial blood issues from the tenotomy puncture. It is easy to stop this bleeding by pressure, but it is probably better to enlarge the wound and find and secure the wounded vessel. This is better than trusting to pressure, as the vessel may be only partially divided and a traumatic aneurysm may follow; this would necessitate a subsequent operation. Moreover, the tenotome may have divided the nerve, which can be sutured forthwith.

The only other complication likely to be met with is that the knife may cut its way out through the skin as the last fibres of the tendon are divided. This is only likely to happen if the division be effected from the deep surface towards the skin, and then only if much vigour be exerted during division, or if the patient be incompletely anæsthetized. Should it happen, the wound must be sutured in the ordinary way.

After-treatment. The limb is put up with the foot at right angles to the leg upon a back-splint with a suitable foot-piece; in three or four days the tenotomy puncture will have healed. The limb may then be put up in some immovable apparatus for a month or six weeks, after which time the child may begin to walk. No violent exertion should be allowed for another month.

DIVISION OF THE TIBIALIS ANTICUS (ANTERIOR) TENDON

After passing through the innermost sheath in the anterior annular (lacinate) ligament this tendon crosses the front of the ankle-joint lying upon the astragalus (talus), scaphoid (navicular), and internal (first) cuneiform bones and the ligaments uniting them, to be inserted into the inner aspect of the internal (first) cuneiform and the adjacent base of the first metatarsal. As it passes beneath the annular (lacinate) ligament it possesses a definite synovial sheath which extends upwards for nearly two inches above the malleolus.

Indications. The tibialis anticus (anterior) is often contracted in talipes equino-varus, and, as it acts as a powerful adductor of the foot, it is usually necessary to divide it in order to overcome the varus.

Operation. The tendon is usually divided between the lower edge of the annular (lacinate) ligament and its insertion into the bone. It can be identified without difficulty and stands out in relief when the foot is abducted. Division is practised about three-quarters of an inch above its insertion into the internal (first) cuneiform, where it crosses the scaphoid (navicular). The tendon is commonly divided from the deep surface towards the skin, and it is usual to employ a blunt-pointed tenotome after the puncture in the skin has been made with a sharp one; this, however, is not a matter of practical importance.

The limb is fixed by an assistant, who stands on its outer side and

grasps the front of the foot firmly with one hand and the leg with the other: he then puts the tendon on the stretch by plantar-flexing and abducting the toes. The surgeon stands on the opposite side and defines the outer edge of the tendon with his left index finger so that he may feel the point of the knife when it is passed across beneath the tendon. The sharp-pointed tenotome is thrust through the skin on the inner or plantar side of the tendon and passed across immediately beneath it, with its blade flatwise to the tendon, until its point is felt beneath the skin on the opposite side by the left forefinger; while this is being done the assistant relaxes the traction on the tendon. The edge of the tenotome is then turned towards the tendon and is made to cut towards the skin by short sawing movements, the tendon meanwhile being put firmly on the stretch again. When two tenotomes are used, the blunt-pointed one is passed flatwise along the sharp one after the latter is in position beneath the tendon; the sharp-pointed instrument is then withdrawn and the section of the tendon completed with the blunt one. The division is accompanied by a distinct snap and the appearance of a gap in the tendon.

The operation is very easy, as the tendon is small and rounded and the movements of the knife can be checked throughout by the left index finger placed upon the skin over it. No important structures are endangered and there is little risk of cutting through the skin when the tendon is divided. Even should this happen, the wound is comparatively small and can be sutured without difficulty. In ordinary cases a small pad of gauze or wool is fastened on with collodion; a few turns of a firmly applied bandage outside this will prevent any subcutaneous collection of blood.

DIVISION OF THE TIBIALIS POSTICUS (POSTERIOR) AND THE FLEXOR HALLUCIS LONGUS TENDONS

The tibialis posticus (posterior) tendon passes down along the posterior aspect of the tibia, occupying the first synovial sheath from its inner border. It passes in a special groove beneath the inner malleolus and the internal annular (lacinate) ligament, in which situation it has a well-marked synovial sheath. It is inserted into the scaphoid (navicular), the cuneiforms, the cuboid, and the second and fourth metatarsal bones. It is in relation to important structures, as external to it lies the tendon of the flexor digitorum longus, with the posterior tibial vessels and nerve immediately to its outer side. These structures lie so close together that an injudicious stroke of the knife dividing the tibialis posticus (posterior) tendon may damage the vessels.

It is the common practice to divide the tibialis posticus tendon above

the annular ligament, an inch or more above the tip of the internal malleolus ; here it is not only free of its synovial sheath, but the vessels are farthest away from it. It is still usually done by the subcutaneous method, but, considering the danger of wounding such an important structure as the posterior tibial nerve, it would seem better in all cases to expose it freely by the open method before dividing it.

Operation. *The subcutaneous method.* The assistant faces the front of the leg and grasps the front of the foot in one hand and the leg in the other ; the limb is rotated outwards so that it rests on the outer side of the foot and the tendon is put on the stretch by dorsiflexing the foot. The surgeon feels for the tendon just behind the inner border of the tibia, and sinks the sharp-pointed tenotome vertically through the skin so that its blade shall pass flatwise between the bone and the tendon. The left index finger is pressed firmly below and behind the tendon so as to define and steady it, and the tenotome is pushed on until it has gone down quite to the level of its deep surface ; the assistant meanwhile relaxes the tension. The cutting edge is now turned towards the tendon and this structure is divided from its deep surface towards the skin, the tendon being put firmly on the stretch once more. A blunt tenotome may be passed into the wound along the sharp one and the actual section of the tendon made with that. The flexor hallucis longus tendon lies so close outside that of the tibialis anticus that it is usually partially divided at the same time ; this is not a matter of much importance, as the muscle is generally contracted and its tendon needs division also.

It is obvious that there is considerable risk of wounding the posterior tibial vessels and nerve which lie close to these two tendons. Although better fortune seems to have followed this operation than might have been expected, it is nevertheless advisable to abandon subcutaneous division in favour of the more certain open method, which can be practised through a very small opening and ensures perfect exposure of the parts, so that the surgeon can see and divide the tendon of either the tibialis posticus or the flexor hallucis longus without the least risk to any other structures.

The open operation is done through a small vertical incision, which need not be more than half or three-quarters of an inch in length immediately over the inner border of the tibia, which can always be felt even in the fattest subjects. The centre of this incision should be two inches above the tip of the internal malleolus, and in making it the internal (great) saphenous vein and nerve must be avoided. The deep fascia of the leg is opened, and the finger-tip inserted into the wound will feel the tendon of the tibialis posticus immediately behind the

inner border of the tibia; this is caught up with a blunt hook and pulled into the wound, when it can be divided with scissors. If the flexor hallucis longus is to be divided also, this can be done by inserting the hook again, and seizing the next tendon to the one divided, which will be the one sought for. This is divided in its turn without any risk whatever to the posterior tibial vessels or nerve.

DIVISION OF THE PERONEI TENDONS

The two peronei tendons pass into the foot behind the outer malleolus, which they groove deeply as they run beneath it. They are contained in a common synovial sheath, the peroneus brevis being the upper of the two tendons. The synovial sheath extends from about an inch above the tip of the malleolus forwards into the foot. The peroneus longus crosses the foot obliquely in a special synovial sheath to be inserted into the under surface of the internal (first) cuneiform and the adjacent part of the base of the first metatarsal. The peroneus brevis is inserted into the tuberosity of the fifth metatarsal.

Indications. (i) The peronei rarely require division for contraction, although this may be necessary in some advanced cases of valgus due to infantile paralysis.

(ii) Much more frequently the peronei are divided as a preliminary to using them for the purpose of tendon-grafting. Sometimes the paralysed peronei have their tendons grafted on to sound muscles, whilst sometimes the sound peronei have tendons of paralysed muscles grafted on to them.

There are no important structures in relation with these tendons, and if simple tenotomy has to be practised both tendons will probably require division and the subcutaneous method may be safely employed.

Subcutaneous division. The assistant faces the limb and seizes the foot in one hand and the leg in the other. He presses up the toes and forcibly inverts the foot so as to put the peronei tendons on the stretch; the foot should rest upon its inner side on a sand-bag. The surgeon feels for the posterior margin of the fibula and introduces his tenotome in a somewhat slanting direction two inches above the tip of the external malleolus, so that the point travels a little backwards parallel with the surface of the fibula, which is somewhat oblique; as he does this, the assistant relaxes his pressure upon the foot so as to relax the peronei and to facilitate the passage of the tenotome between them and the bone. When the point of the knife has been carried well down to the inner edge of the tendons, its cutting edge is turned towards them and they are divided by cutting towards the skin, the tendons meanwhile being put firmly upon the stretch again. Here, as in the former

case, the section may be completed by the blunt-pointed tenotome if desired.

When, however, tendon-grafting is to be employed, or when only one of the two tendons is to be divided, the *open method* must be employed. In this the tendons are exposed either by a small vertical incision directly over the posterior border of the fibula when simple division is to be practised, or by raising a semilunar flap with its base towards the fibula so as to give plenty of room for the tendon-grafting operation (see p. 501). In making this incision and in raising the flap the external saphenous vein and nerve must be looked for and preserved from harm, as they lie just behind the line of the peronei tendons.

DIVISION OF THE HAMSTRING TENDONS

Indications. (i) Division of one or more of the hamstrings is often required for the correction of contraction of the knee due either to injury, operation, or disease. For injury, division of the hamstrings is sometimes required to counteract their contraction in certain cases of fracture in the neighbourhood of the knee-joint, when this prevents the proper apposition of the fragments. In cases of disease the powerful hamstrings flex the knee and pull the tibia backwards and outwards, so that partial dislocation of the tibia on the femur occurs in neglected cases, and division of the tendons is necessary before this can be rectified. Occasionally, also, flexion of the knee occurs as the result of infantile paralysis, but this is not very common. After operations such as arthrectomy in children, however, it is quite common to get flexion of the knee; the tendency to flexion is extreme, and repeated divisions of the hamstrings may have to be performed before a permanently good result is obtained.

(ii) Division of the hamstring tendons may be a preliminary to an operation either for shortening these tendons or for tendon-grafting in infantile paralysis of the extensors of the knee.

Any of the three hamstring tendons may require to be divided, and in addition to them the tendons of the sartorius and the gracilis may need exposure for the purpose of either lengthening them or of grafting other tendons on to them.

Division of the biceps tendon. The biceps tendon is inserted into the head of the fibula and is the strong cord forming the outer boundary of the popliteal space and felt on the outer side of the knee when it is flexed against resistance. The tendon is divided into two parts by the external lateral (fibular) ligament of the knee-joint, and it is also connected with the popliteal fascia by strong fibrous bands running from its posterior border. Immediately along this border runs

the external popliteal (peroneal) nerve, which can generally be felt quite distinct from the tendon as it passes down to the neck of the fibula. It is, however, so close to the tendon as to be easily endangered by subcutaneous division of that structure.

For this reason, if for no other, the subcutaneous operation should be avoided and the open one always practised when any operation upon the biceps tendon is contemplated. The subcutaneous operation will therefore not be described here, as it is dangerous even for simple division, while it is inefficient for cases in which there is any contraction of the surrounding tissues, as is not infrequently the case; it is obviously of no value if the tendon requires lengthening, as it frequently does in cases of contracted knee. In these cases an open incision allows an oblique section of the tendon to be made, after which the ends can be reunited (see p. 493), so that satisfactory union is assured. This should be done in preference to simple tenotomy in all cases in which there is a prospect of getting a movable knee-joint subsequently.

The open operation is done as follows: The limb is laid upon its inner and the surgeon faces its outer side. An incision about two inches long is made directly down upon the tendon if a tendon-lengthening or tendon-grafting is to be done, but one of about half an inch in length will suffice if the operation is to be a simple tenotomy. As the surgeon cuts down on the outer aspect of the tendon, this structure is made to stand well out in relief by attempting to extend the knee, and the tendon is readily defined and cleared owing to its large size. It is then easy to make certain that the nerve is not endangered, and the tendon can be divided with a scalpel, either transversely or obliquely. The finger introduced into the wound then defines any tense bands of fascia in the neighbourhood, especially the ilio-tibial band which lies above and parallel to the biceps tendon. These are then divided through the same incision by pulling the skin edge to one side. This would not be permissible in the subcutaneous operation as numerous articular vessels, as well as the peroneal nerve, would be endangered. In the open operation, however, the vessels can be secured immediately they are divided.

Division of the semimembranosus and semitendinosus tendons. These two tendons form, with the sartorius and gracilis, the inner boundary of the popliteal space. The semitendinosus is smaller and more superficial, and is also placed rather nearer to the middle line of the popliteal space than the semimembranosus: the latter is, however, the largest of the hamstrings. The gracilis and sartorius are more laterally placed and are superficial, and their tendons are not so easily felt. These tendons may require division in the same affections as

division of the biceps is practised for, and this is usually done at the corresponding spot on the opposite side of the popliteal space. In the case of these two tendons there is not the same strong objection to subcutaneous division if a simple tenotomy has to be performed, but even here it is better to employ the open method, as by it fascial bands are easily detected and divided. If the subcutaneous method be adopted, the tenotome should be introduced beneath the tendons and made to cut towards the skin. The steps of the open operation resemble that for division of the biceps.

DIVISION OF THE STERNO-MASTOID

Indications. (i) Division of the muscle just above its origin from the clavicle and the sternum is practised for the cure of permanent wry-neck arising in early infancy. As a rule the two heads of origin of the muscle are affected unequally, the sternal portion being most contracted and becoming converted into a firm fibrous cord which stands out boldly beneath the skin. The shortening is due to the conversion of one or both heads of the muscle into fibrous tissue. The condition is therefore different to that of talipes due to infantile paralysis; there the contraction occurs in the healthy muscle, while in wry-neck it is the damaged one that undergoes contraction. The damage is usually the result of injury during child-birth or it may follow a gummatous infiltration later in life.

(ii) The muscle is sometimes divided in the course of other operations, such as ligature of the innominate artery (see p. 366).

Surgical anatomy. Division of the sterno-mastoid tendon is fraught with more danger to important structures than is the case with any other tenotomy usually practised. Three important veins are found in close connexion with it; close to its deep surface lies the internal jugular just where it joins the subclavian to become the innominate; the external jugular lies close behind its posterior border just before it pierces the deep fascia to join the subclavian vein; and the anterior jugular crosses its inner margin and passes behind it. Another important point has also to be remembered in connexion with this operation; the sterno-mastoid lies in a separate sheath of the deep cervical fascia, and this sheath is stout and often becomes firmly contracted also, so that it requires free division before the deformity can be satisfactorily rectified. Division of the cervical fascia cannot be carried out subcutaneously without risk of wounding one or more of the veins above mentioned, and therefore the subcutaneous operation is one of great hazard and uncertainty. It should be abandoned in favour of the open operation, which can be done with the minimum of risk and with the certainty

that by its means alone proper division of all the contracted structures can be effected safely. The subcutaneous operation will therefore not be described.

Operation. The patient lies with the head thrown slightly back and the chin turned to the affected side ; a small sandbag placed beneath the root of the neck is the best way to put the tight muscle fully on the stretch. The breathing must be unembarrassed so that there shall be no venous engorgement, otherwise the bulging of the large veins at the root of the neck renders the operation dangerous.

Several different incisions may be used to expose the tendon. The

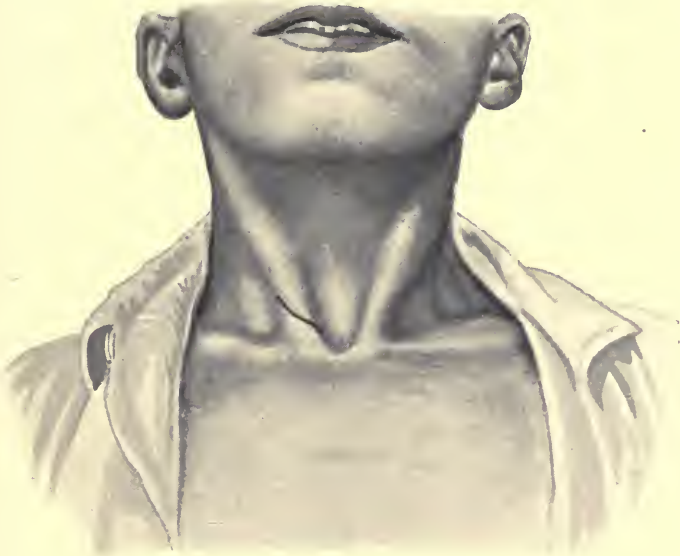

FIG. 234. INCISION FOR DIVISION OF THE STERNO-MASTOID. This incision gives ample room for either transverse or oblique division of the muscle and at the same time does not gape after the operation and leaves an inconspicuous scar.

one that I have found the most convenient on the whole is that shown in Fig. 234, passing obliquely across the lower end of the sterno-mastoid from above downwards and inwards, from the posterior to the anterior margins of the muscle, and terminating just above the sternal notch. Through this incision the whole area involved in the operation can be easily reached, and the resulting wound can be sutured without leaving any noticeable scar, a matter of some moment when the patient is a girl.

The skin and platysma are divided, and the margins of the shortened muscle are defined. Its anterior surface is then cut across transversely

by steady strokes of the point of the knife, cutting from the superficial to the deep aspect of the tendon. There is no need to divide the muscle obliquely, as union between the divided ends is not required unless the entire muscle has to be divided; in that case the incision through the tendon should coincide with that through the skin, and then, when the divided ends have retracted, their extreme ends will just touch and may be sutured (see p. 494).

As the division approaches completion, a gap appears in the tendon and a careful look-out must be kept for the big veins which come into view in their sheath of fascia after the tendon has been divided. They can always be seen before there is any risk of wounding them, and it is a far better plan to divide the tendon from before backwards by cautious strokes of the knife as described above, than to attempt to run a director between the tendon and the veins, which might lead to a wound of the latter as the director passes across behind the tendon.

All the contracted part of the sterno-mastoid should be divided, whether it be one head or both, and when this is done the finger is introduced into the gap between the ends whilst the assistant puts the sterno-mastoid fully on the stretch, and any tight bands of fascia are defined and cautiously nicked with the point of a fine knife. This is the really dangerous part of the operation, as the tight fascial bands are frequently derived from the sheath of the internal jugular vein, and the latter structure may have to be laid bare for some distance before all the tight structures have been divided. It is, however, essential to the success of the operation that this should be done satisfactorily, as otherwise the neck cannot be straightened properly. In all advanced cases, especially in children who have been allowed to reach the age of twelve years or more, it will be found that the sheaths of the common carotid artery and the internal jugular vein are markedly contracted.

When the surgeon has satisfied himself that all resisting structures have been divided, the wound is closed with a few points of fine horse-hair, with Michel's sutures or; still better, by means of a sub-cuticular stitch which gives rise to the minimum amount of scar. Before the wound is closed, all bleeding must be arrested, and the patient should be allowed to come almost round from the anæsthetic; this allows coughing or vomiting to occur, and so tests whether any of the venous branches are oozing; every bleeding point must be tied, as otherwise a very unpleasant hæmatoma is likely to occur. A firm dressing is placed over the wound and tightly bandaged on so as to obliterate the small cavity left at the seat of division. The patient is put back to bed and the head is fixed so as to extend the contracted structures to the utmost, that is to say, the head is turned with the chin towards the affected

shoulder and the occiput towards the opposite side. It is kept in this position by sand-bags or by a suitable head-splint.

After-treatment. After the wound has healed, the patient will require treatment for the purpose of keeping the muscle on the stretch. This may be done partly by means of exercises in which the head is rotated actively or passively so as to stretch the affected muscle, and partly by wearing an apparatus which pulls the head mechanically into such a position as to put the muscle on the stretch; the apparatus may be worn at night, whilst the exercises suffice for the day. If the apparatus has to be worn during the day, as may be the case in severe degrees of the deformity, it need only be worn for the first six or eight weeks; after this time it should be worn at night for two or three months. The after-results are usually good, and if the operation be done before the well-marked hemi-atrophy of the face has occurred, there may be little to show that the trouble has ever existed. Much patience is required in the after-treatment, however.

Dangers and difficulties. These have been sufficiently indicated in the description of the operation; practically the only one of any importance is a wound of one of the important veins in the vicinity of the muscle at the point of section. This accident is very serious in this particular situation as, owing to the influence of respiration and to the position of the veins, there is a great risk of air being drawn in through any puncture made in their wall, with the usually serious and probably fatal result. The accident, however, should never occur if proper care be taken to look out for the veins as the muscle is divided, and particularly if care be taken never to proceed with the division of the muscle or tight structures as long as the patient is coughing or the big veins are congested. Should the vein be wounded, the surgeon should at once put his finger upon the hole, so as to prevent the ingress of air; it may then be easy to pick up the wound in the wall of the vein and apply a lateral ligature to it which is quite efficient and which does not interfere with the circulation through the vessel. The vein will hardly ever be so badly wounded as to require complete ligature or even suture of its walls.

TENDON SUTURE

An operation for uniting the divided ends of a tendon may be called for under the following circumstances:—

(1) Soon after the tendon has been divided or ruptured and before the cut edges have had time to undergo any marked changes. This form of tendon suture is commonly known as 'immediate' or 'primary' suture in contradistinction to

(2) Those cases in which union is not practised until a considerable period has elapsed after the occurrence of the accident; in the meanwhile the ends have undergone definite changes. This is commonly known as 'remote' or 'secondary' suture.

PRIMARY TENDON SUTURE

Indications. (i) Among the cases that most frequently require primary suture are those in which the wrist tendons are divided by accidentally thrusting the hand through a pane of glass and thereby dividing the flexor tendons; division of the flexor or extensor tendons of the fingers by a knife is also of common occurrence.

(ii) Immediate tendon suture is necessary when a tendon has been divided accidentally or designedly during the course of an operation and the ends have to be brought together before its termination.

(iii) Some form of tendon suture has also to be employed in the operation for tendon transplantation (see p. 497).

(iv) In subcutaneous rupture of a tendon the ends should be sutured when the gap between them is large and the muscle concerned is an important one.

(v) After amputations of the fingers it may be necessary to join the flexor and extensor tendons together in order to retain the movements of the fingers.

The particular method of operation adopted for tendon suture will vary according as the divided ends of the tendon can be made to meet or not. In the former case all that is required is the best method of fastening the ends together under the circumstances; *i.e.* the operation is a simple tendon suture. In the second case, however, some form of tendon-lengthening or tenoplasty will be a necessary preliminary to the suture in order to approximate the ends sufficiently to suture them together. Tenoplasty or tendon-lengthening is often required in cases of secondary suture, but is only called for in cases of primary suture when portions of the tendon have been destroyed by the accident, *e.g.* a gunshot wound may carry away a portion of the tendon completely or so destroy it as to render it useless for suture purposes. As the steps of the operation vary according to whether the suture is primary or secondary, the two operations will be described separately.

There are three ways in which tendons can be united to one another; they are:—

- (1) End-to-end union.
- (2) Side-to-side union.
- (3) Lateral implantation.

Of these the end-to-end method is the one almost invariably employed.

It has the advantages that it does not shorten the tendon and that it is the method least calculated to alter its contour, a point of some importance when the latter runs in a definite groove or sheath.

The side-to-side method of anastomosis is excellent from the point of view of the strength of the anastomosis, but it has the great disadvantage that it causes a pronounced bulging at the seat of the anastomosis, and of course it also shortens the tendon to some extent. It is therefore chiefly used when there is a certain amount of slack in the tendon which can be safely taken up.

The implantation method is only used for tendon-grafting; it is peculiarly useful there, as by its means an absolutely firm union can be made that will stand considerable strain without any risk of separation.

Operation. After the wound has been sterilized and, if necessary, opened up sufficiently to allow easy access to the divided tendons, the surgeon identifies the ends and secures them with catch forceps in order to steady them during the act of suturing. Any bruised tissues should be clipped away when the wound is purified, so that there shall be no danger of sepsis occurring. In recent cases there is often some difficulty in defining the proximal end, as the muscle to which it is attached retracts to some extent and so widens the gap between the two ends. This, however, is not a serious difficulty, as the wound can be enlarged to any desired extent when the patient is under the anæsthetic. The chief trouble is in the palm, where there may be difficulty in finding both distal and proximal ends. As a rule the distal end is found fairly easily, as it does not retract, but in the case of the finger tendons, especially when they are divided in the palm, even the distal ends may be retracted out of sight if the tendons happen to be divided when the fingers are flexed; as the patient extends the fingers the distal end of the tendon is pulled up out of sight into the tendon sheath. Should this happen, there is no alternative but to slit up the sheath in the middle line until the tendon comes into view. After union has been effected the sheath is sutured over the united tendon.

It may be possible to bring the divided proximal end into view by squeezing down the muscles of the forearm and firmly flexing the wrist. Should this prove unavailing, however, it will be best to expose the tendon sheaths above the annular ligament, when the tendons can be identified and either pushed down into the palm or pulled down by means of sinus forceps pushed up from the palmar wound. When the wound is at the wrist, however, there is little difficulty in defining both the divided ends after enlarging the wound.

In a case of subcutaneous rupture of a tendon, the gap between the divided ends should be exposed by a curved incision whereby a flap

is raised, so that the resulting scar does not lie over the united ends of the tendon and there is, therefore, no risk of adhesion subsequently.

Suturing the tendons. As a rule no previous preparation or paring of the edges is necessary, as in the majority of cases the tendon will have been cleanly divided by a knife or other sharp instrument; if, however, the ends are ragged, as they may be if the rupture be a subcutaneous one, the edges should be trimmed with sharp scissors, and, if this has to be done, the line of section should be made as oblique as possible without sacrificing an unnecessary amount of tissue. The ends secured in forceps are brought into apposition ready for suture. One of the two following methods may be employed, the first being better suited for round stout tendons, the other for thin flat ones.

(1) *Lateral sutures.* It serves no useful purpose to pass the sutures

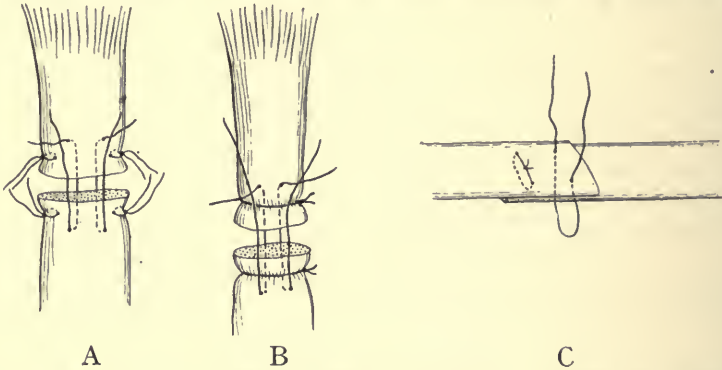


FIG. 235. METHODS OF SIMPLE TENDON SUTURE. A shows the usual method described in the text. In B a constricting suture around each end prevents the vertical sutures from cutting out. C shows the mattress suture for flat tendons; here the ends overlap.

through the whole thickness of each divided end and then to simply tie them together; the sutures cut their way out between the parallel bundles of fibrous tissue and only fray out the end of the tendon. In order to get a union that will stand the necessary strain, some means must be adopted for getting a firm hold on the tendon, so that the ends can be fastened together without fear of the muscular movements tearing out the sutures. The best way to do this in my experience is by means of lateral ligatures (see Fig. 235).

These lateral sutures are passed as follows :—

A fully curved intestinal needle threaded with medium-sized catgut is made to pick up a small thickness of the tendon by introducing it transversely to its long axis about a quarter of an inch above the cut end. The tendinous bundles thus picked up are secured by knotting the suture firmly, and a similar suture is introduced and tied at a corresponding

point in the tendon on the opposite side of the gap. It will be found that the two ligatures can be tied firmly together, and there will be no risk of their being pulled off the tendon to which they are attached. Two, three, or four of these sutures are applied according to the size of the tendon, and they are reinforced if necessary by sutures of the finest catgut, which adapt the edges accurately after the lateral sutures have taken off the tension. It is important to bring the tendon ends into apposition before the sutures are inserted, so as to make sure that each suture on the proximal side lies opposite to its corresponding suture on the distal portion: otherwise the tendon may be twisted upon itself.

This method is an excellent one, and does not cause such a marked bulging at the seat of union as does the somewhat similar plan of tying a ligature tightly around each end of the tendon about a quarter of an inch from the division and then passing a vertical stitch through the whole thickness of the tendon above and below these sutures; the latter prevent the vertical sutures from cutting through the tendon (see Fig. 235). This bulges the ends of the tendon considerably and interferes, therefore, with its proper working.

(2) *The mattress suture.* This is an excellent method for uniting thin flat tendons, such as the extensors of the wrist. It gives a very firm union without much extra tension. The chief objection to the method is that there is a slight bulging at the anastomosis, but this is unavoidable in all thin flat tendons, and is not of great importance. The method of passing the mattress suture is shown in Fig. 235.

The material for suture is a matter of some little importance, as it should be strong enough to hold for some weeks but should be eventually absorbed; if it is not, it may cause irritation of the tissues. Formerly I employed silkworm-gut for this purpose, but I found that, as it never becomes absorbed, it sometimes causes irritation, especially in superficial tendons, and requires removal, and therefore I now use Lister's chromicized catgut, which holds for weeks but eventually becomes absorbed; I have never had any trouble with this material.

When accurate suture has been accomplished, the synovial sheath, if there be one, should be sutured over the tendon with the finest catgut. All bleeding points should be stopped, and in this connexion it is well to remember that an Esmarch bandage should not be used to obtain a bloodless field of operation, as the success of the operation largely depends upon obtaining a wound that is quite dry; the long-continued oozing that goes on after removal of an Esmarch bandage militates greatly against this. The wound should be sutured without a drainage tube, and the limb should be put up with the affected tendons in the relaxed position. Besides the advisability of this position from

the point of view of the relief of tension, it should be remembered that, if adhesions occur between the tendon and its sheath when the muscle is in the stretched position, it is most difficult to restore movement subsequently, as it is impossible to break down the adhesions by further stretching ; if, however, adhesions occur when the muscle is fully relaxed, movement under an anæsthetic will break them down easily. The position should be maintained if possible by the use of some flexible metal splint, so that the limb can be extended gradually during the first fortnight without the necessity for taking it off the splint and disturbing the dressing.

After-treatment. The wound should be dressed at the end of ten days, and the sutures removed. During this time the flexion will be gradually diminished ; the limb is brought straight by the end of a fortnight. Massage and gentle passive movements should be practised as early as possible and active movements from the third week. No trouble arises from the death of the small portion of tissue strangulated by the ligature ; union is firm in about six weeks, and the patient may use the affected muscle freely.

SECONDARY TENDON SUTURE

It not infrequently happens that the patient does not come under the surgeon's notice until some considerable time has elapsed since the occurrence of the accident, and this allows certain permanent changes to occur which necessitate rather different treatment. After the lapse of a week or a fortnight the proximal end of the tendon becomes permanently retracted, owing to the fact that its muscle, which is no longer kept on the stretch by the tension of its tendon, becomes shortened. The surgeon is then faced with two problems—(1) to find the divided ends, and (2) to overcome the shortening just referred to and to bring the ends together without tension.

Finding the divided ends. This is less difficult than it is to find the divided end of a nerve, but it is done in a similar manner. It is advisable to expose the parts by means of a crescentic incision which allows a flap to be dissected up so that the scars in the skin and adjacent parts will not lie over one another, and thus the chances of an adherent cicatrix and subsequent loss of movement are minimized. When there is no sheath to the tendon, a large flap is raised and the muscular fibres are traced to their insertion into the tendon, which is then defined and prepared for union.

When there is a sheath, the tendon is exposed in it well above the seat of the lesion, the sheath is slit up in the middle line with fine scissors, and the tendon is traced down until the divided end comes into view.

The end, which is always adherent, is separated from the surrounding structures and prepared for suturing.

As a rule little preparation is needed before suturing, but when the ends have become rounded or irregular they may be freshened by paring them with a sharp knife. This, however, is not so important as in the case of immediate suture, because there is generally some considerable tension on the ends when an attempt is made to approximate them, and some form of tenoplasty will be required with the object of lengthening the tendon and so avoiding tension (*vide infra*).

When it is possible to bring the ends of the tendon into apposition without too great tension by simple flexion of the joints over which the muscles pass, the procedure is identical in all respects with that for primary suture (see p. 488). It is, however, most important to avoid tension when performing tendon suture, as the contractions of the muscle are liable to cause the sutures to cut out; therefore, when there is any marked tension, it is better to have recourse to tenoplasty or tendon-lengthening in order to bring the ends together without strain (*vide infra*). All the suture knots should be as small as possible and so placed that they are out of the way of friction. When the suture has been completed, the sheath should be united over the tendon with a continuous suture of the finest catgut, if possible. The limb is put up with the muscles fully relaxed and the after-treatment is similar to that for primary suture (see p. 488).

TENDON-LENGTHENING

Indications. The operation of tendon-lengthening may be required—

- (i) As an adjunct to division of tendons which run in synovial sheaths in a contracted limb.
- (ii) As a substitute for tenotomy when the gap left after it would be so great as to make successful union doubtful.
- (iii) In some cases of secondary tendon suture where there is considerable tension upon the divided ends.

Operations. A number of ingenious methods have been devised for lengthening a tendon, but the following may be regarded as the most generally useful. In all cases the section should be made with a very sharp knife or with a skin-grafting razor, and great care must be taken to keep the wound aseptic, as very slight sepsis will lead to death of the portion of the tendon concerned and adhesion of the remainder.

(1) *Oblique section.* This is the simplest plan and is as satisfactory as any. Its usefulness, however, is in direct proportion to the thickness of the tendon concerned. When the latter is large and wide, such as the tendo Achillis, a very oblique section can be employed and con-

siderable lengthening can thus be obtained (see Fig. 236). In the smaller tendons, however, only slight lengthening can be obtained in this way.

(2) *The L-method.* This is a very useful method and gives a firm union. The disadvantage, however, is that it requires a fairly wide tendon for its most useful application; it is very suitable in the tendo Achillis, for instance (see Fig. 237).

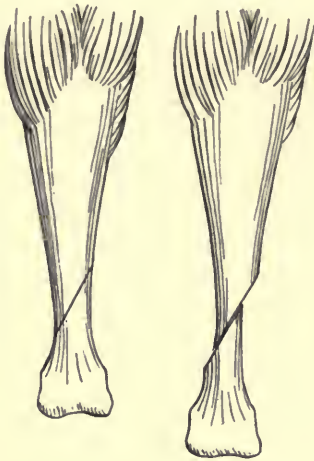

FIG. 236. TENDON-LENGTHENING BY OBLIQUE SUTURE. The amount of lengthening is determined by the obliquity of the suture, which in turn is largely governed by the width of the tendon.

(3) *Reflected slips.* Fig. 238 shows how the slips are reflected and sutured. The tendon may be lengthened by reflecting a slip from one end alone or from both; in the latter case considerable lengthening can be obtained. This method gives a rather weak union, but it has the advantage that a gap of almost any size can be bridged over by means of it; the reflected slips must be regarded more as a conducting than as an actual uniting medium. The union can be reinforced by bridging the gap across with one or two strands of catgut (see Fig. 239).

(4) *Hibbs's method.* Dowd (*Annals of Surgery*, 1906, vol. xliii, p. 280) quotes the following simple method of lengthening a tendon from Hibbs, whose account originally appeared in the *American Medical News*, April 21, 1900. It can, of course, only be practised satisfactorily

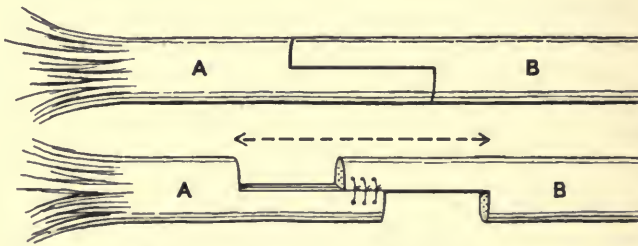


FIG. 237. THE L-METHOD OF TENDON-LENGTHENING. This gives a firm union, as the suture is lateral, not end to end. It requires a moderately stout tendon.

in a broad tendon, and is especially recommended for use in the tendo Achillis. It can be done very rapidly, and, as will be seen from Fig. 240, the tendon is not actually divided at all and therefore no sutures are

absolutely necessary. It is, however, as well to surround the angles of reflection of the flaps with a ligature so as to prevent the reflected portion splitting away.

(5) *Dawbarn's autoplasmic grafting method.* This is an ingenious plan described by Dawbarn (*Annals of Surgery*, vol. xliii, p. 305), and is suited for cases of division of the flexor tendons in the fingers, particularly those in which a portion of both tendons has been completely lost. It

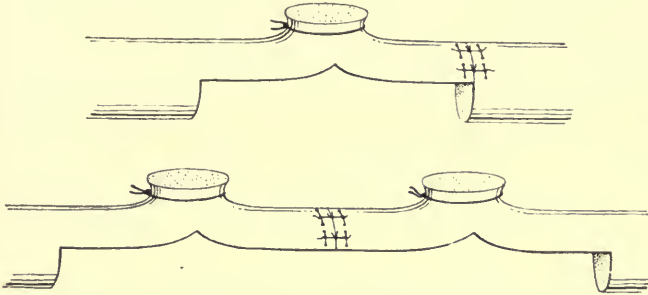


FIG. 238. TENDON-LENGTHENING BY REFLECTED SLIPS. The diagram shows the single and double methods. The reflected slips will be detached by the pull of the muscle unless they are secured by the encircling suture depicted above. The method by which the end-to-end union of the slip is made is seen in Fig. 235.

is not used for simple division, as one of the methods recommended above will suffice for that. When, however, there is a considerable gap, Dawbarn cuts down upon the flexor sheath well above the seat of division, exposes the flexor sublimis and cuts from it by an oblique section a sufficient amount of tendon to fill the gap below. This portion

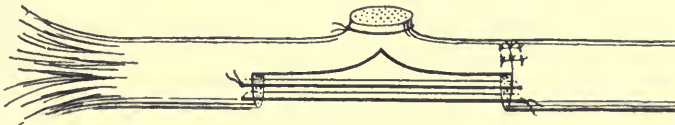


FIG. 239. REFLECTED SLIPS REINFORCED BY CATGUT SUTURES. The catgut sutures are merely used as a framework, not to strengthen the union mechanically.

is then seized with forceps from the wound below and is pulled down into the gap between the two ends of the flexor profundus; into this gap it is sutured after the divided ends of the profundus have been cut obliquely to receive it. The patient thus has a complete flexor profundus tendon whilst the flexor sublimis is sacrificed (see Fig. 241).

(6) *Heteroplasmic grafting.* When the gap is very great and the conditions are such that none of the above methods can be employed, attempts may be made to fill the gap with foreign materials; of these the most likely to succeed is a tendon from one of the lower animals,

a dog, cat, or rabbit being used for the purpose. The graft should be of sufficient length to unite without any tension whatever, and the tendon sheath must be carefully sutured over it. The form of suture employed should be such as to give rise to the least interference with the movement of the tendon (see p. 490). There is a good likelihood of success if no septic contamination occurs when the graft is being

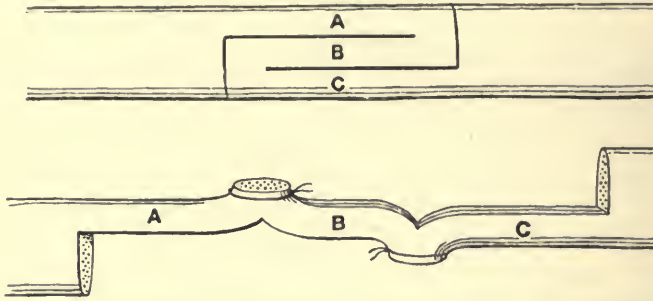


FIG. 240. HIBBS'S METHOD OF TENDON-LENGTHENING. The upper figure shows the incisions, the lower one their effect upon the tendon. The encircling ligatures must be used as before to prevent detachment.

prepared for use, but the method is hardly likely to be used frequently, as the surgeon will rarely meet with a gap in a tendon too large to be closed by one of the preceding methods.

Another plan is to lace the gap backwards and forwards with strands

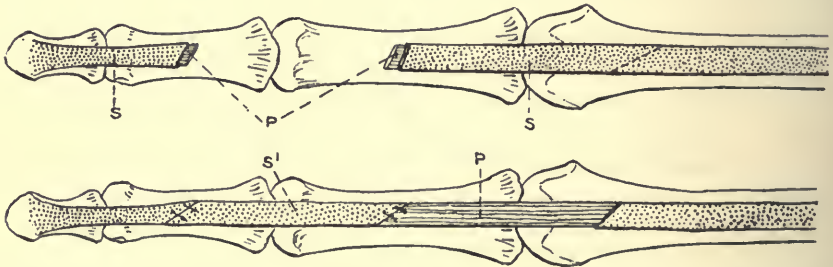


FIG. 241. AUTOPLASTIC TENDON-GRAFTING. This is Dawbarn's method. The flexor profundus, P, is repaired by means of a portion of the flexor sublimis, S.

of catgut so as to form a bridge or supporting medium along which the fibrous tissue may be conducted so as to unite the ends.

TENDON-SHORTENING

Indications. A tendon may require to be shortened in cases of paralysis where there is some slight contractile power left in the affected muscle and it is desired to bring it back to its normal length as

soon as possible. It is called for most frequently in cases of talipes calcaneus.

Methods. There are three chief methods by which a tendon may be shortened :—

(1) A portion may be excised and the divided ends sutured together.

(2) The tendon may be detached from its insertion, a portion removed, and the tendon re-inserted, or

(3) The insertion of the tendon may be shifted bodily.

The second of these methods is probably the most satisfactory, as it is easier to secure a firm fresh attachment of the tendon to bone than it is to get satisfactory bony union after shifting the attachment of the tendon bodily, as is done, for instance, by sawing off the insertion of the tendo Achillis into the os calcis and reuniting it to the bone lower down. These are clumsy and difficult operations, whereas it is quite easy to detach the tendon from its insertion, cut off the requisite length, and re-attach it. The attachment may be done in any way that seems suitable to the operator. When a very firm hold is required, a hole may be bored in the bone, and a stout silk suture passed through this and made to fix the tendon. The limb must be kept in the fully corrected position for at least six weeks afterwards, as otherwise there is a risk of the union stretching. The nutrition is generally poor in these cases.

TENDON-TRANSPLANTATION AND TENDON-GRAFTING

Although tendon-transplantation and tendon-grafting differ in technique, they are only different methods of making a sound muscle discharge the functions of a paralysed one. Tendon-transplantation in the strict sense of the term means transference of the insertion of a tendon from one bony point to another, while tendon-grafting implies the implantation of one tendon into another. Each method has its sphere of usefulness, but the two are often combined in the same case.

True tendon-grafting may be of two kinds. In the first, the tendon of a paralysed muscle is cut across and the tendon of an unparalysed one is similarly treated. The proximal end of the tendon of the unparalysed muscle is then attached to the distal end of the tendon of the paralysed one. In the second case the tendon of the paralysed muscle is divided as before and its distal end is implanted into the tendon of an unparalysed muscle or is joined to a slip from that structure. Occasionally lateral implantations of the two tendons without division may be employed (see Fig. 243).

Indications. The assumption of the functions of a paralysed

muscle by a healthy unparalysed one finds its widest application in cases of infantile paralysis. It is most useful in paralytic talipes, but it may be employed with advantage in paralysis affecting the knee, the elbow, or the shoulder. It is often combined with arthrodesis, or the artificial production of an ankylosed joint, and, in connexion with this operation, it may give most useful results. Thus, a child who has a flail-like lower extremity from paralysis of most of the muscles moving the knee and the ankle may get quite a useful limb after the production of a stiff joint in one of these articulations and the judicious application of tendon-grafting to the muscles moving the other; this

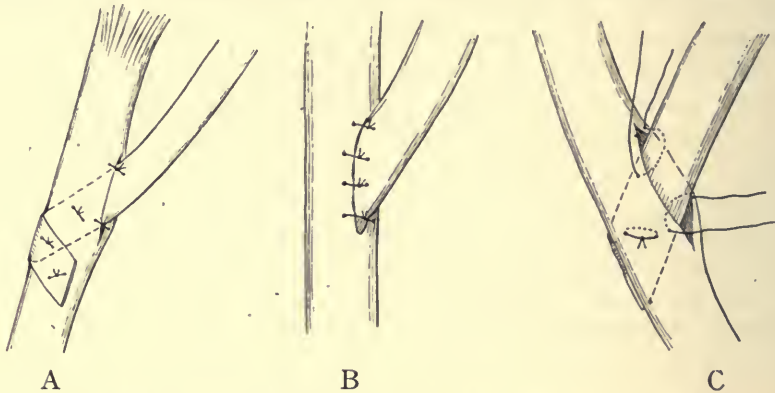


FIG. 242. IMPLANTATION OF TENDONS. A shows the firmest hold that can be obtained. One tendon is split and the other is passed through the slit and wrapped round it. B is simple attachment—a bad way unless the tendons are too short to allow of any other procedure. C is the ordinary implantation of the divided end into a split tendon.

will enable movements of the latter to be performed well enough for the patient to get about with a stick or even without any artificial aid.

Points to be observed in the operation. In order to obtain the best results certain points should be attended to.

(1) The operation should be performed as soon as possible after the paralysis has come to a standstill and the surgeon is able to determine clearly how much healthy muscular tissue is left in the muscles concerned.

(2) Each individual muscle should be tested carefully and its exact contractile power ascertained, as it is important to choose for the purpose of anastomosis those muscles which can act with the greatest power and at the least mechanical disadvantage. Thus, for instance, it is better to make the tibialis anticus replace the extensor hallucis longus or the extensor digitorum longus rather than to bring the tibialis posticus or one of the peronei tendons around the malleolus in order to anas-

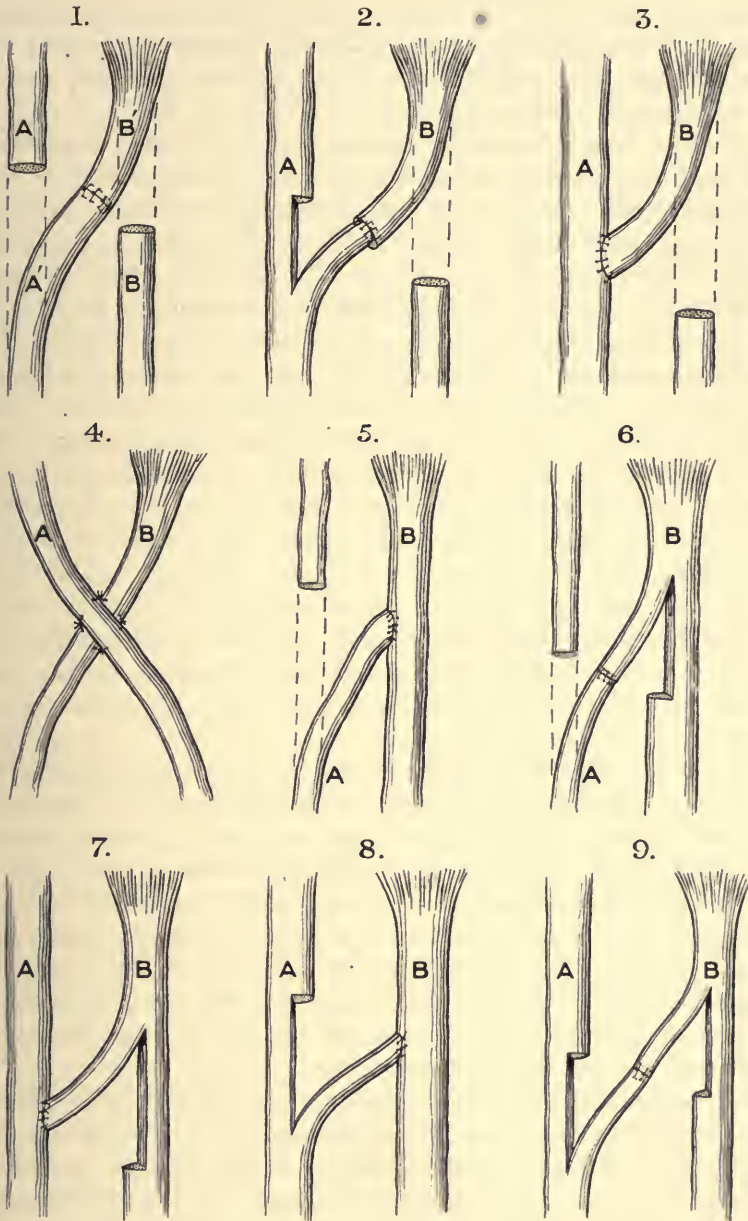


FIG. 243. VARIOUS METHODS OF TENDON-GRAFTING. In each case B is the sound muscle, A the paralysed one. The first three diagrams are the methods in which the sound tendon is divided prior to anastomosis. The last three are those in which neither tendon is divided, as is also 4. In the two remaining figures, 5 and 6, the paralysed muscle has its tendon divided but not the sound one; this is a very favourite method.

tomose it with either of these tendons. It is, however, possible to bring tendons around the malleoli in this fashion if necessary, but this should be avoided if possible, as greater care is required in the after-treatment in order to maintain the mobility.

(3) A very firm anastomosis should be made ; when possible, it is best to split one tendon and pass the other through it. This union may be still further strengthened by wrapping one tendon around the other in the manner shown in Fig. 242, A. A weak union is apt to stretch or to tear out.

(4) Whenever possible, muscles should be employed that have the same nerve-supply as the affected one. That is to say, a flexor tendon should be grafted on to a flexor muscle and an extensor tendon to an extensor muscle. This, however, is not absolutely necessary. A flexor muscle may, for instance, be united to an extensor tendon, and in course of time and by a process of education the functions of the paralysed muscle are assumed by the sound one ; that is to say, a flexor muscle now produces extension. When this is done, however, complete division of the grafting and grafted tendons must be employed ; if the method of uniting the two by a lateral anastomosis or by implanting the distal end of the paralysed tendon into a slip derived from a healthy one be employed (see Fig. 243) the functions of the muscle concerned will be dual and the two functions will be antagonistic and simultaneous in point of time.

(5) It is not always necessary to unite the healthy tendon to the paralysed one. The tendon chosen may be cut across and a new attachment made directly to bone in any spot at which the surgeon thinks the muscle is likely to act at the greatest mechanical advantage. For instance, the tibialis anticus or the extensor longus hallucis can be attached to the outer border of the foot so that a varus position may be remedied thereby. The tendon may be attached to bone at any desired spot by suturing it with silk passed through a hole bored in the bone. The union may be strengthened by catgut sutures passing between the tendon and the adjacent soft parts.

(6) Whatever the method adopted, matters must be so arranged that the foot is in its normal position when the tendon is united and there is neither undue tension nor undue slackness in the anastomosed structures. Care must also be taken, both at the end of the operation and throughout the after-treatment, to see that there is no undue strain thrown upon the anastomosis.

(7) Strict asepsis must be observed throughout, as suppuration is fatal to success. It is important to tie all bleeding points and make sure that the wound is dry before it is finally closed.

Operation. No definite steps can be laid down for the operation as the cases vary so widely. The surgeon will carefully examine the limb, will ascertain which muscles are paralysed and which are healthy, will choose the best available muscle for his purpose, and will then graft it on to the affected tendon or tendons by one of the methods described for tendon suture (see Fig. 243). It may be necessary to make a wide dissection in order to do this, and in all cases it is best to expose the tendons by raising small flaps, so that the seat of anastomosis shall be away from the line of union in the soft parts; this increases the chances of perfect movement subsequently.

When a tendon has to be anastomosed to another at a considerable distance, the raising of a single flap large enough to expose both tendons would entail division of many soft structures, such as veins and nerves; in such a case it is better to make a separate incision over each tendon, and, after preparing and dividing both, to pull the distal end of the one through to the proximal end of the other with forceps passed through the subcutaneous tissue from one incision to the other. The passage of tendons through these new subcutaneous paths does not interfere materially with their mobility.

After-treatment. A great deal depends on successful after-treatment, as all the benefit that can be derived from tendon-grafting may be lost if the limb be put up with the newly-grafted tendon on the stretch, so that the muscle is at a mechanical disadvantage. It should be fixed in a slightly over-corrected position in plaster of Paris or some similar immovable apparatus, where it should be kept for a month or six weeks so as to allow union to take place undisturbed. At the end of that time, the patient may be fitted with a light orthopedic apparatus which does not allow the corrected position to be passed and the faulty one assumed. This should be worn for three to twelve months according to the progress made, and during this time massage and selected active and passive exercises designed to strengthen the affected muscles should be practised vigorously. The essential point for success in this method is to see that the limb is never allowed to fall into its old position of deformity, which it will readily do as long as the union is weak or the muscle is not powerful enough to do its work unless strengthened by suitable apparatus. This precaution is especially necessary when a weak muscle has been made to take the place of what should be a powerful one. It is only by means of cautiously graduated exercises increasing in strength that the muscle is made to hypertrophy so as to fulfil its new functions with any degree of success. It is disregard of this precaution that so often leads to the disappointing results that are occasionally experienced in connexion with tendon-grafting.

Results. After examining a considerable number of cases operated upon by this method I feel that one may fairly come to the conclusion that the method is of considerable value. It must not be expected that it will cure or even greatly improve every case, but when it is judiciously employed and the after-treatment is carefully carried out, there will be some definite improvement in nearly every case for which it is suitable; in some cases, chiefly those of minor degrees of paralysis occurring in isolated but important muscles, the improvement may be most striking. Operation, however, should be performed before the limb has got into an exaggerated condition of deformity if good results are to be looked for with any confidence. Those advanced cases of talipes marked by extensive alterations in the shape of the bones are practically beyond its range of usefulness.

CHAPTER III

OPERATIONS UPON TENDON SHEATHS AND BURSÆ

It is occasionally necessary to perform operations upon tendon sheaths apart from operations upon the tendons themselves, and as these nearly always take the form of removal of the synovial sheath it will be necessary to say a few words about them.

EXCISION OF THE SHEATH OF A TENDON

Indications. The so-called compound ganglion of the wrist, which is really a tuberculous teno-synovitis, will call for excision of the common sheath of the flexor tendons. Tuberculous teno-synovitis is fairly common either as a primary affection, as in the case of the so-called compound ganglion of the wrist, or secondary to disease of the joint, as, for example, teno-synovitis about the ankle and wrist secondary to disease of those articulations.

Operation. The steps of the operation required cannot be given with any exactitude, as they must vary with the particular tendon that is the subject of operation. Certain points, however, should be borne in mind if this operation is to be done successfully, and, as the success that attends a well-planned and properly executed excision of tuberculous tendon sheaths is most gratifying both as regards the extirpation of disease and the restoration of function, it is well to enumerate them in detail.

(a) The area to be operated upon should be exposed freely so that the excision may embrace the entire affected area.

(b) The flap method should be employed where possible, as it avoids a linear cicatrix directly over the denuded tendon and thereby diminishes the chance of adhesion of the two structures and increases the chance of complete restoration of function.

(c) The diseased synovial sheath should be removed entirely with knife or scissors; it should be clipped away cleanly, and no attempt should be made to scrape it away with a sharp spoon or any other clumsy instrument.

(d) The excision should be commenced by defining the synovial layer which lines the tendon sheath. This should be dissected up as far round as possible from one side of the incision into the sheath, and a

similar procedure is then carried out from the other side until the entire synovial lining has been removed, the tendon being hooked up out of its bed while this is done.

(e) After complete removal of the lining membrane of the sheath the tendon itself must be examined, and if it has undergone any definite changes the synovial layer covering it must be dissected away as thoroughly as possible. This, of course, is a matter of difficulty owing to the extreme thinness of the synovial covering in places, and in cases of doubt it is best to err on the side of taking away too much rather than too little, and to remove a slice from the surface of the tendon with a sharp knife so as to make sure that all the disease has been removed. Particular care is required in the upper part where the tendon joins the muscle to see that all the affected synovial covering is removed. If tuberculous deposits be seen on the surface of the muscle itself that structure should be removed widely, as when tubercle finds its way into muscle it spreads rapidly and the chance of recurrence is greatly increased.

Every tendon that requires treatment in this way must be gone over in turn thoroughly. The operation is tedious, but if it be done in this systematic manner the results are remarkably good. The wound is rendered perfectly dry before it is closed, care being taken to ligature all bleeding vessels. The tendons are then laid down in their denuded sheaths and the latter may be sutured over them in some cases. The skin flap is united without a drainage tube and the limb is put up in a position in which the affected muscles are relaxed; that is to say, if the operation has been performed upon the extensor tendons of the hand the hand is put up fully extended, while if the operation has been on the palm the hand is flexed. The object of this is to render it easy to break down any adhesions that may occur after the operation.

Anatomical considerations must dictate the particular form that the incisions shall take. Thus, for instance, if the entire back of the hand has to be operated upon it will be well to raise two separate flaps so as to avoid dividing too much of the cutaneous nerve-supply of the hand. Similarly, when operating upon the flexor tendons the operation will probably be done through a series of incisions, as it is important to avoid injury to the median nerve and its branches in the hand. The anterior annular (laciniate) ligament, however, may be cut through without hesitation in order to facilitate access to the synovial sheath beneath.

Results. These are remarkable in their completeness, if the operation has been thorough and the wound has remained aseptic. All the tendons on the back or the front of the hand may be treated in

the same manner and the patient nevertheless preserve perfect use of the fingers. One patient from whom I removed the synovial sheaths of all the flexor tendons from the first inter-phalangeal joint to above the great palmar bursa in the right hand was enabled to earn her living by teaching the violin; and another, upon whom a similar operation was performed on all the tendons on the back of the hand, plays the piano without the least inconvenience.

OPERATIONS UPON BURSAE

These require no special description, as the operations are simple dissections, the only point of interest being the various incisions necessary in the various situations. Bursæ should always be dissected cleanly out and, as a rule, the incision will be directly over the swelling. In the case of the prepatellar bursa, however, it is well to raise a flap over the bursa, with its convexity upwards, reaching just beyond the upper limit of the swelling. This is done because the scar would be exposed to pressure were it either a median vertical one or a flap with its convexity downwards, as in kneeling the tubercle of the tibia and the adjacent part of the ligamentum patellæ come into contact with the ground.

SECTION VII
OPERATIONS FOR NON-TUBERCULOUS
AFFECTIONS OF THE BONES

BY

FRED^c. F. BURGHARD, M.S. (Lond.), F.R.C.S. (Eng.)

Teacher of Operative Surgery in King's College, London ; Surgeon to King's
College Hospital ; and Senior Surgeon to the Children's Hospital,
Paddington Green

CHAPTER I

OSTEOTOMY

Indications. Osteotomy or simple division of a bone may be required for various purposes.

(i) The most common condition is deformity due to *rickets*. This generally takes the form of a curve of the femur or the tibia, giving rise to genu valgum or genu varum. Some of the more complicated rickety deformities of the lower extremity may also require an osteotomy.

(ii) Osteotomy is often done for the rectification of deformity due to *ankylosis* in a faulty position following hip disease. Here the osteotomy may be through the neck of the bone or in the sub-trochanteric region.

(iii) Osteotomy of the femur has been recommended and successfully practised for the treatment of *coxa vara*. The operation is rarely necessary, however, as simple mechanical means will suffice for a cure in the great majority of cases.

(iv) Osteotomy either of the femur or of the tibia and fibula has been practised by some surgeons, particularly in America, for the relief of the inveterate inward rotation associated with bad cases of congenital *talipes varus*.

(v) Occasionally a simple osteotomy will suffice to rectify *mal-union after a fracture*. As a rule, however, either simple re-fracture suffices, or a more elaborate operation followed by the use of some means of mechanical fixation (see p. 538) is necessary.

Operation. Concerning the operation of osteotomy in general, little need be said. The division of the bone may be done with a saw or a chisel. The usual form of saw is shown in Fig. 244 ; it has a stout cross-cut blade for rapid work and is of sufficient length to get well across the bone. It is blunt-ended, so as not to damage surrounding parts, and is strong enough not to bend or snap in the wound. The chisel or osteotome also seen in Fig. 244 is the pattern introduced by Sir William Macewen and is double-edged and graduated in inches along its side.

Subcutaneous osteotomy. A clean cut is made down to the bone with a stout knife parallel to its long axis. The soft parts are cleared from the surface of the bone by a raspatory, so that the saw can be passed down to the bone flatwise along it. The cutting edge is then turned

towards the bone, which is divided by short rapid strokes. The bone may be sawn through entirely, or it may be fractured after the major portion has been divided by the saw. The osteotome is used in a similar manner.

Done in this way, the operation is almost subcutaneous. It can be made entirely subcutaneous if desired, but the above plan is to be recommended whenever there is any important structure, such as a large vessel or nerve in the immediate vicinity of the bone to be divided. It is better to make a wound large enough to expose the bone; then



FIG. 244. OSTEOTOMY INSTRUMENTS. The upper figure is Adams's osteotomy saw, the lower Macewen's osteotome.

the surgeon can see that he introduces the instrument between the bone and the soft structures.

Open osteotomy. When osteotomy is done through an open incision any suitable kind of saw or chisel may be employed, and the bone ends either remain in position spontaneously or are maintained by some form of fixation apparatus (see p. 538). As a rule the latter is not required for rickety deformities, but it may be called for in the other conditions requiring osteotomy. This form of osteotomy may be divided into two groups, which may be called *linear* and *cuneiform* osteotomy, according as a simple division or a removal of a wedge of bone is practised.

There are certain special forms of osteotomy that call for description; the chief ones are described in the following pages.

MACEWEN'S SUPRA-CONDYLOID OSTEOTOMY

At the present time this operation holds the field for the cure of genu valgum of a certain degree of severity to the exclusion of all the older methods ; no other will be, therefore, described here. It is suitable for cases of genu valgum in which the separation between the malleoli is more than three inches and a half, and in which ossification is progressing actively, so that no improvement of the deformity is likely to be brought about by splints. It is equally suitable for the adult and for the juvenile form of genu valgum, but in exaggerated cases in children it often has to be combined with osteotomy of the tibia, which is generally of the cuneiform type (see p. 514).

Operation. The knee is flexed to an angle of 135° , and a firm sandbag is placed under its outer side, the thigh being somewhat abducted and rotated outwards. It is most important to purify the limb from mid-thigh to mid-calf and to surround the remainder of the extremity securely with sterilized cloths so that neither the surgeon's nor the assistant's hands can come into contact with unsterilized structures during the course of the operation.

An incision is made at the junction of a horizontal line drawn across the thigh a finger's breadth above the upper limit of the external condyle with a vertical one drawn nearly the same distance in front of the adductor tubercle. At this point the knife is sunk straight to the bone and in this situation is fairly sure not to divide any vessel of importance. A broad knife, such as a breast knife, makes an excellent instrument, as it need only be driven straight down to the bone and the osteotome (see Fig. 244) can then be introduced flatwise along its blade until the bone is reached. The knife is then withdrawn, leaving the edge of the chisel held firmly in contact with the bone. Usually the incision through the skin is made parallel with the long axis of the limb, and therefore the osteotome has to be turned through a right angle in order to make the section of the bone. It is grasped as shown in Fig. 245, and by means of light strokes with a mallet or hammer is made to divide the inner and posterior part of the bone first ; then the osteotome is driven forwards and outwards until the outer aspect of the triangular surface of the back of the femur is reached. The compact tissue is easily recognized by its hardness, and consequently the difficulty with which the osteotome penetrates it. In children the cancellous tissue can often be divided by the mere pressure of the hand unaided by a mallet. After two-thirds or three-quarters of the thickness of the bone have been divided the remainder may be fractured. The thigh is grasped

with one hand and the leg with the other and the remaining portion of bone is snapped by bending the limb sharply inwards. As soon as it is felt to give, the limb is brought into the fully corrected position. Osteotomes of different sizes may be used if desired, a smaller one being inserted to complete the division begun by the large one; few surgeons use more than one size at the present time, however, and then only in adults. The cutaneous wound is sutured and the limb is secured in the corrected position by suitable splints.

After-treatment. The limb may, if desired, be put up in plaster

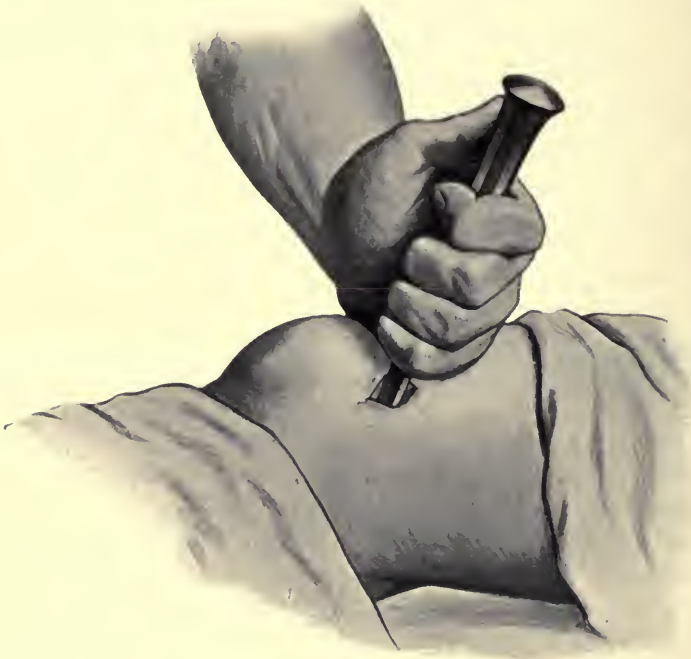

FIG. 245. METHOD OF HOLDING MACEWEN'S OSTEOTOME. If the instrument be held in this manner it is kept perfectly firm and is not likely to slip suddenly and do damage.

of Paris directly, but it is well to delay this for about a fortnight, when the sutures can be removed and any further correction that may be necessary can be made under an anæsthetic and a plaster casing applied whilst the patient is still unconscious. It is somewhat difficult to be sure of getting the limb into perfect position immediately after the operation as the bulky first dressing obliterates landmarks. In small children it may be necessary to take the bandage round the pelvis in order to get sufficient hold. The immovable apparatus should be con-

tinued until firm union has occurred, which should be in about six weeks from the time of the operation. The patient is allowed to get about freely in another month, if firm union has occurred, and, as the operation will not have been performed until the rickety period is passing off, recurrence is not likely; should there be any fear of this, the patient must be fitted with an apparatus preventing recurrence of the deformity but allowing the free use of the knee-joint.

Difficulties and dangers. A consideration of the steps of the operation might lead to the anticipation that there are many difficulties and dangers to be met with. It is extraordinary, however, to see how free it is from complications of any kind, and many surgeons have done many hundreds of these operations without a hitch of any kind. Non-union is practically unknown; the bone surfaces are broad and are never separated, probably because the division is always somewhat incomplete, the periosteum at least remaining intact at some part of the bone. Wound of the knee-joint also seems never to occur, or, if it does, to be quite harmless. Wound of the popliteal artery, which a theoretical consideration of the operation might lead one to think would be a not infrequent complication, rarely, if ever, occurs. Even free bleeding from division of any named branch is rare and is easily stopped either by pressure or, in extreme cases, by enlarging the wound. The only difficulty with which I am personally acquainted is that of not being able to re-introduce the osteotome into the line of bone section after having withdrawn it in order to see whether the bone can be fractured. The best way to avoid this is to divide the bone until very slight pressure will fracture it; this is only learnt by experience. It can also be avoided by imparting to the osteotome movements in the vertical direction, so as to widen the groove that it makes in the bone; this prevents locking and also facilitates the identification of the groove when the instrument has been removed.

Results. The results of this operation are most satisfactory. It is of universal application and few similar operations give such admirable results with such a minimum of risk. It is a perfectly satisfactory treatment for genu valgum of a moderate degree. In the more extreme forms cuneiform osteotomy of the tibia (see p. 514) should be either substituted for or combined with it.

OSTEOTOMY OF THE TIBIA

Indications. (i) Division of the tibia is usually done for deformities due to rickets.

(ii) Badly united fractures with serious deformity resulting in im-

paired locomotion may call for osteotomy ; but this will generally be preliminary to mechanical fixation of the fragments. It is not infrequently required for fractures in the region of the ankle-joint where the direction of the lower fragment is so altered that the body-weight is transmitted at a mechanical disadvantage.

(iii) Osteotomy of the tibia and fibula has been practised for the cure of the persistent inward rotation that accompanies bad talipes equino-varus.

The operation may be done in several ways and in various situations. Thus it may take the form of linear or cuneiform osteotomy, either of which may be performed in any part of the bones, the upper and lower ends being the most common situations—in the upper end for genu valgum, in the lower for the bowing forward of the tibia so common in rickets. The section of the bone may be made in any direction ; as a rule a cuneiform osteotomy by the open method is done for rickety deformities, as the surgeon is thereby able to do very accurate work.

Operation. When cuneiform osteotomy is to be done, the surgeon, having settled the spot at which he will divide the bone, raises a flap over it so that the cicatrix in the skin shall not lie over the bone section. The spot usually chosen for osteotomy of the tibia in genu valgum is just below the upper epiphyseal line of the tibia, while that for the antero-posterior curvature of the lower end of the bone is well above the lower epiphyseal line ; in the latter case the flap is best raised by means of a crescentic incision with its convexity inwards and its extremity lying just over the anterior border of the bone. The flap is raised and the subcutaneous surface of the tibia is exposed over an area corresponding to the base of the wedge that is to be removed from it. The wedge is now marked out either with a few strokes of an osteotome, or with an osteotomy saw ; it is most conducive to neat work to make the preliminary groove with an osteotome, as by it the shape of the wedge can be marked out very accurately and the inclination of its sides can be determined better than by the saw. The actual division of the bone is best effected, however, by the latter instrument, which is introduced into the groove thus made, and the wedge of bone cut cleanly out, the soft parts being meanwhile protected by inserting thin spatulæ between them and the bone. In making the bone section, care must be taken not to damage the anterior tibial artery or nerve, which lie upon the interosseous membrane and are very easily wounded. If there be any doubt as to the exact amount of bone that requires to be removed it is well to take out a smaller wedge than is necessary, as it is easy to remove more bone with a sharp chisel, or to alter the angles of the wedge. Throughout the sawing and chiselling manipulations the limb should be laid on its outer side upon a firm sand-bag.

When the wedge has been removed, the fractured surfaces are brought into apposition, and this should rectify the deformity. In an adult the fibula must be divided before this can be done, and this can be accomplished through a small vertical incision below the neck of the bone, which is bared with a rugine and either nipped across with bone forceps or partly sawn through with an Adams's osteotomy saw, and then fractured by bringing the limb into position. In young children, however, the fibula is so elastic that it offers no obstacle to the reduction of the deformity, and even in older children, although this elasticity may be troublesome, it can be overcome by over-correcting the deformity and creating a greenstick fracture. Bleeding is rarely troublesome although there may be free oozing from the medulla ; this, however, always stops as the two bone surfaces are squeezed together when the deformity is rectified.

It is often difficult to remove the exact amount of bone necessary to get complete reduction of the deformity at the first attempt. The surgeon should not be satisfied with the result, however, until he has obtained rectification of the deformity and accurate coaptation of the fractured surfaces ; for the finishing touches a sharp chisel is invaluable. When the bone surfaces are brought together, it is important to see that no flap of periosteum becomes turned in over the ends of the bone. No fixation apparatus is ever necessary for rickety cases. Operations performed for mal-united fractures are separately dealt with (see p. 550). All bleeding should be carefully arrested and the wound sutured without a drainage tube. Only a small amount of dressing is applied, so that the surgeon is able to see the outline of the limb, and can therefore apply the retentive apparatus more accurately than if the leg were enveloped in a large mass of dressing. The simplest plan of putting up these cases is to apply a light plaster of Paris casing, fixing the knee and ankle. This will require to be taken off when the stitches are removed ; some form of Croft's removable casing answers admirably.

The other method is to secure the limb in splints, which may either consist of a back and two side splints with a foot-piece at right angles, or a roll of Gooch's splinting in which the limb is so fixed with pads that the corrected position is properly maintained. Of these methods the former is the more suitable for all cases in which the surgeon is sure of his asepsis, and the patient is old enough not to soil the casing with urine. The other method is useful in quite young children, as soiling of the apparatus is easily detected and can be prevented from doing harm by changing the dressings.

After-treatment. The first dressing is left untouched for a fortnight, when an anæsthetic is administered, the sutures are removed, and the limb put up in a plaster of Paris casing, which fixes the knee and

ankle joints. This is kept on for a month, when the bone should have united. It will, however, be necessary to keep the child off his feet for a period of nearly two or three months longer, unless the case be one in which all signs of rickets have passed off and the bones have undergone full ossification.

SUB-TROCHANTERIC OSTEOTOMY OF THE FEMUR

Osteotomy of the neck of the femur and trans-trochanteric osteotomy are described separately (see p. 636).

Indications. Sub-trochanteric osteotomy of the femur may be done for :—

(i) *Deformity following ankylosis in hip disease.* Division of the neck of the femur or of the great trochanter is theoretically a better method of relieving this condition than is division of the shaft of the femur below the trochanters, and should be preferred whenever it is feasible. There are many cases, however, which can now be detected by the X-rays, in which the fusion of the femur to the pelvis is so extensive that division of the bone below the trochanters is a simpler and more satisfactory method.

(ii) Sub-trochanteric division has been employed for the cure of *coxa vara*, the object being to rotate the shaft of the femur round its long axis and so overcome the eversion of the foot, the two fragments being united by some suitable mechanical apparatus. This operation, however, is not likely to find extended favour for this purpose. The risk of deformity or of non-union can never be ignored, while no operation is ever called for in young children, and in adults cuneiform osteotomy of the neck of the femur (see p. 636) is preferable.

Operation. This is quite simple. The level of the lesser trochanter is about two inches below the top of the greater, and therefore the osteotome should be applied about half an inch or more below this spot. A vertical incision about an inch and a half long is made over the outer surface of the femur with its centre opposite the above point and carried down to the bone. The osteotome is then introduced flatwise along the blade of the knife, turned at right angles to the shaft of the bone, and made to cut across horizontally from the outer to the inner side, dividing first the compact bone of the front and outer aspects of the shaft and then that in the neighbourhood of the *linea aspera*. When two-thirds of the bone have been divided, the remainder should be snapped by carrying the limb inwards until it is felt to crack; the deformity is then rectified, and the limb is put up in an immovable apparatus after the wound has been sutured. The best apparatus is that recommended for use after operations on the neck of the femur (see p. 641).

CHAPTER II

OPERATIONS FOR OSTEOMYELITIS AND ITS SEQUELÆ

FOR ACUTE INFECTIVE OSTEOMYELITIS

Operation. As soon as the diagnosis is established, a very free incision must be made over the affected bone under full anæsthesia. The periosteum must be divided freely, the incision reaching well above and below the affected area ; it is of the highest importance that it should be free enough to allow all the pus to escape. When the pus between the periosteum and the bone has been evacuated careful examination must be made to see whether the abscess has burrowed round the bone laterally, and, should this be the case, the periosteum is divided transversely also, or suitable counter-openings are made to establish free drainage. It is not sufficient to make a free opening anteriorly, as pus may continue to burrow around the bone in spite of this.

In all cases of acute infective osteomyelitis it is always well to open the medulla when any quantity of pus is found beneath the periosteum, as the disease frequently commences in the centre of the bone. A good plan is to remove a circle of the compact tissue of the bone with a half-inch trephine, so as to permit a satisfactory inspection of the medullary canal. If no pus be found, the cavity may be swabbed over with a saturated solution of chloride of zinc and lightly packed with iodoformed gauze ; then there will be scarcely any risk of the infection spreading from the surface to the deeper parts.

If, however, pus be present in the medulla, the whole of the cavity containing it should be freely exposed by cutting away all the bone over the suppurating area with a gouge, trephine, or chisel according to the taste of the operator. The cavity is thus laid bare from end to end and is lightly packed with iodoformed gauze ; it will drain satisfactorily if the packing be only loosely applied. It is not advisable to use a sharp spoon to remove the suppurating medulla, as is so often done ; the procedure is not likely to eradicate the entire diseased area, and only serves to destroy any osteogenetic portion of the medulla that has so far escaped destruction by the suppurative inflammation. So long as the pus is not under tension, it will drain satisfactorily, and the least damage results if simple but ample drainage be established.

If the suppuration in the medulla extends up into the epiphysis,

the cavity in which the pus lies must be opened up equally freely, and that portion of the epiphysis overlying the abscess cavity must be sacrificed without hesitation.

At the original operation, no attempt should be made to remove bone for any other purpose than mere drainage, except in the rare cases in which the shaft of the bone is completely detached both from the epiphyseal lines above and below and from the periosteum circumferentially. This involves the death of the entire shaft of the bone, and the dead diaphysis can be lifted out from its periosteal bed with advantage, as regeneration of the bone will then occur better than if it were left to form a sequestrum. Failing this, however, no attempt should be made to remove bone except for the purpose of drainage, as it is impossible to tell at the time of the operation how much bone has been destroyed; this important point can only be ascertained by waiting.

After-treatment. The limb should be kept at rest upon a splint, and should be syringed out daily, or oftener according to the amount of discharge, with peroxide of hydrogen solution (ten volumes per cent.), after which it may be lightly stuffed with iodoformed gauze. The formation of healthy granulation should be promoted by all means possible. For this purpose light packing is better than firmly stuffing the wound.

SEQUESTROTOMY

Indications. Sequestrotomy may be required for the relief of several conditions; thus:—

(i) It may be necessary for the removal of a sequestrum resulting from acute infective osteomyelitis.

(ii) After traumatic septic necrosis a sequestrum may have to be removed, for instance, from an amputation stump or from a compound fracture.

(iii) In 'quiet' necrosis sequestrotomy will be necessary.

(iv) Syphilitic necrosis is often followed by the formation of a large sequestrum which demands removal by surgical means.

(v) In tuberculous necrosis a sequestrum, although occasionally capable of absorption, should be removed whenever its presence is diagnosed, as this greatly increases the chances of a cure and hastens recovery.

The steps of the operation for removal of a sequestrum vary according to the nature of the disease that has led to the production of the sequestrum that it is designed to remove, and accordingly three methods will be described:—

(a) For removal of a sequestrum following infective osteomyelitis.

(b) For removal of a deep-seated sequestrum resulting from 'quiet' necrosis or syphilis.

(c) For removal of a tuberculous sequestrum.

REMOVAL OF A SEQUESTRUM FOLLOWING ACUTE INFECTIVE OSTEOMYELITIS

In these cases the most important question is *the period at which to operate*. It is essential that the whole necrotic area should be removed at the operation and that no sequestra should be left behind to prolong healing and necessitate a second operation; therefore, operation should not be practised until the surgeon is able to ascertain fairly accurately how much of the bone is dead and requires removal. Quite apart from the inadvisability of prolonged waiting from the point of view of the patient, who is confined to bed meanwhile and has to have frequent dressings, it is very important to intervene as early as possible, because the prospects of regeneration of new bone to take the place of the sequestrum are directly proportionate to the shortness of time that has elapsed between the occurrence of the necrosis and the removal of the sequestrum. The reason of this is that when necrosis occurs the periosteum is stripped from the bone by the inflammatory exudation and after a short time becomes covered with granulation tissue which has a high osteogenetic power. If this osteogenetic function be allowed time to come into full play it surrounds the necrosed bone with a rigid sheath of new bone of a more or less permanent character. Unlike normal bone, growth can only take place from the periosteal surface of this newly-formed bone, and no endosteal increase is possible; therefore the cavity in the ensheathing layer of bone in which the sequestrum lies does not fill up from the interior.

Operation in recent cases. From these considerations it follows that it is of great practical importance to remove the necrosed bone before it has become a true sequestrum, that is to say, before the dead portion has become locked in and buried by new periosteal bone. If this can be done while the periosteum is still soft and plastic, that structure can be made to approximate itself to the remaining normal bone, with which it becomes fused, so that no cavity is left. The practical result to be deduced from this, therefore, is that in every case a sequestrotomy should be done at the earliest moment at which it is possible to tell how much of the bone is dead.

This power of regeneration is very remarkable, and extraordinarily good results have followed removal of the entire shaft of the tibia for acute infective osteomyelitis at the time of the original operation. The periosteal walls fall together, the small cavity thus left is filled

with osteogenetic granulations, and a new tibia, which in the course of time becomes sound and almost of the normal size, takes the place of the old one. This is in marked contrast to the hopelessly unsatisfactory results that often follow removal of a sequestrum for the same disease when the dead bone has been allowed to remain *in situ* bathed in foul pus for many weeks or months; even after removal of the sequestrum in these cases a foul discharging cavity may persist for the remainder of the patient's life.

The period at which the demarcation between the living and the dead bone can be made out clearly will vary with the bone affected. Thus it may be possible to be certain upon this point in some cases within a month, while it takes more than two months in other cases—such, for instance, as the femur. The exact time for operating is rather difficult to tell, but the most careful efforts must be made to ascertain it. An X-ray photograph may give valuable help in defining the limits of the necrotic area, but the most important test is to determine the period at which the periosteum begins to undergo ossification, as it is then sufficiently plastic to be moulded into position. It may be taken as a safe rule that ossification in the periosteum does not advance far until the line of demarcation between the living and dead bone is fairly established. The onset of ossification may be ascertained by feeling the small spicules of bone in the vascular periosteum; these may occasionally be felt with the finger, or a probe or needle may be made to rub against the bone spicules, or some of them may be actually scraped away with a sharp spoon and examined microscopically. It cannot be too strongly insisted that every care should be taken to determine the time at which the operation should be performed, as the patient's future comfort may depend largely upon the right time being chosen.

Operation. The whole of the affected area must be exposed freely by any incision or incisions that seem most suitable for the purpose. Any sinuses present should be included in the incision if possible, their orifices being surrounded by an elliptical incision so that they can be removed completely. The periosteum is divided throughout the length of the incision and turned back carefully with a rugine (see Fig. 246). All unnecessary violence in reflecting the periosteum must be avoided, as it is upon the vitality of this structure that the chances of a successful result depend. Lateral incisions into the periosteum may be made, if necessary, so as to reflect it without undue bruising.

When the dead bone has been fully exposed in this manner it is removed by whatever method seems to be most satisfactory. If it be small and quite free it can be pulled out by necrosis forceps, otherwise a chisel or gouge may be required. If there be any doubt as to whether

any portion is dead or not, it is best to remove that portion in order to make sure; it is always better to remove more than is absolutely necessary rather than too little. If necessary the whole thickness of the shaft of the bone must be taken away without the least hesitation. Excellent results have been obtained after limited resection of the whole breadth of the shaft in this way; this will not often be necessary, but it may be done fearlessly when there is a doubt as to whether the whole thickness of the shaft has perished or not.

After removal of the dead bone the cavity is flushed out so as to remove clot and to enable the operator to see whether any spicules of bone have been left behind. The wound is then irrigated with a solution of peroxide of hydrogen (ten volumes per cent.) and the two sides of the periosteal cavity are brought together as closely as the conditions will allow and, if necessary, are sutured together. Ample drainage must be provided; this is a point of the highest importance. The limb is put up in some



FIG. 246. FARABEUFS RUGINES. The ends, which are straight or curved, are strong and as sharp as chisels. They can be used with great precision.

immovable apparatus, of which the best is a splint of malleable iron secured to the limb by plaster of Paris bandages so arranged that the wound is fully exposed and accessible for the purpose of dressing, without the risk of any discharge getting between the skin and the plaster and giving rise to dermatitis. The *after-treatment* is similar to that for the preceding operation.

Results. The results can be fairly described as excellent. New bone is thrown out quickly and a solid mass of periosteal bone takes the place of the dead portion; this eventually becomes moulded to the shape and size of the bone that it replaces. These really good results, however, can only be expected to occur when the affection arises in one of two parallel bones; for example, in the leg or forearm. If the whole extent of the femur or the humerus be affected there is no sound bone to act as a splint and the risk of shortening and deformity is very great. Extension would have to be used after operation, and great care taken to prevent rotation of the lower end of the bone upon the upper. It is only reasonable, therefore, to think that the best course of procedure in these cases is to wait until a sufficient splint of new periosteal bone has formed before the sequestrum is removed; the operation is described below. The risk of shortening and deformity is thereby

reduced, but on the other hand the great advantage of rapid healing and reconstruction of the affected bone is greatly jeopardized.

It occasionally happens that small sequestra form again during the after progress of these cases. This may be due to small spicules of the original sequestrum having been left behind or to the occurrence of further necrosis due to sepsis. These, however, are easily removed, especially when their presence and situation can be accurately made out by means of the X-rays.

Operation in long-standing cases. These cases are less frequently met with than they were, as early operation is now the rule; in them the sequestrum is deeply placed, being walled in on every side by masses of new bone, and lying in a cavity lined with foul granulations often riddled with sinuses. Although it may be easy enough to remove the sequestrum, the outlook is bad in the extreme, as there are few tasks in surgery harder than to bring about the closure of a large septic bone cavity. The reason for this is that the cavity possesses little or no osteogenetic power and is therefore incapable of obliterating itself by the growth of ossifying granulation tissue. The osteogenetic functions of the medulla are destroyed quite early by the septic inflammation, and no further encroachment of the healthy medulla upon the affected area can take place owing to the blockage of the medullary canal by a mass of septic granulations and ossified material. We thus get a rigid cavity incapable of spontaneous obliteration, and some special means will be necessary to effect its closure.

It will be seldom possible to raise a satisfactory flap over a bone that is the subject of long-standing septic necrosis, because the limb will be riddled with sinuses, the pus finding its way out through the so-called 'cloacæ' in the newly-formed periosteal bone and thence through the skin. The best plan is to make one or more longitudinal incisions, including in them if possible the openings of all the sinuses in the skin, the edges of which should be surrounded by elliptical incisions and removed. The incisions go down to bone throughout and the periosteum should be reflected over the entire area that the sequestrum is known to occupy. The latter is then exposed with a chisel or gouge, beginning from one of the cloacæ and working upwards and downwards until the entire sequestrum is laid bare. When the sequestrum involves nearly the whole length and thickness of the shaft of the bone, the ensheathing layer of newly-formed periosteal bone might be so damaged as to render the limb liable to fracture if sufficient bone were removed to expose the sequestrum fully. Under these circumstances it is customary to expose one half of the sequestrum, cut it across with powerful cutting-pliers or with a Gigli's

saw (see Fig. 25), and then to remove the exposed half, and afterwards pull the other half down into the trough thus left, whence it can be removed in its turn. Careful examination must be made to see that all the dead bone has been removed.

After removal of the dead bone the foul granulations by which it has been surrounded are scraped away, and the cavity resulting is douched with peroxide of hydrogen solution (ten volumes per cent.), after which undiluted carbolic acid is applied freely to its walls so as to purify it as thoroughly as possible. The skin is then brought together over the cavity by a few interrupted silkworm-gut stitches, but ample drainage should be provided for at both ends of the wound. The limb is put on a splint, and peroxide of hydrogen solution is used freely in the after-treatment. Under these conditions it may be possible to get gradual obliteration of the cavity if the disease has been only superficial and enough of the ensheathing layer has been removed. If, however, a persistent sinus should remain, one of the following methods for obliteration of bone cavity must be employed :—

OPERATIONS FOR THE OBLITERATION OF SEPTIC CAVITIES IN BONE

Closure of a cavity in bone is practically impossible as long as sepsis persists, and obviously the first step in the treatment is to secure asepsis ; otherwise the cavity will discharge indefinitely. Sometimes it is fairly easy to make a cavity of this kind aseptic, but sometimes it is impossible. The easy cases are those where there is a single sinus leading directly into the cavity through an opening wide enough for the discharge to escape freely. When the cavity is small and the bone is large, as, for instance, when a sinus leads into a minute abscess in the head of the tibia, the possibility of removal of the septic area is increased.

In all cases every attempt must be made to eradicate sepsis before the operation for closure is undertaken. A free outlet for septic discharges must be secured, undermined areas of skin must be slit up, sinuses opened, drainage tubes of large size inserted, and an oxidizing agent such as peroxide of hydrogen employed. The cavity may be filled up from time to time with 1 in 20 carbolic solution, which is left *in situ* for ten or fifteen minutes so as to prolong its effect, and the cavity may be scraped with a sharp spoon from time to time under local analgesia, followed by the application of undiluted carbolic acid to its walls.

The operation for closure of the cavity may be undertaken when it is apparent either that the amount of sepsis is practically negligible or that

the improvement under the above treatment has come to a standstill. Its object is twofold; it aims first at making the cavity aseptic and then at securing its obliteration.

The parts must be purified with the most scrupulous care. All sinuses should be plugged with wool impregnated with liquified carbolic acid, which must not be allowed to run over the sound skin. When this has been done, the skin around is purified in the usual manner, and then the orifice of each sinus is included in an elliptical incision and the entire sinus removed right down to the bone. Suitable incisions for exposure of the affected area are then carried down to the bone and the soft parts are turned back. These incisions will generally be parallel to the long axis of the cavity.

When the cavity has been properly exposed, the surgeon attempts to make it aseptic. The only really satisfactory method of doing this is entire removal of the walls of the cavity for a sufficient distance beyond the area of sepsis. With this end in view the cavity is first swabbed out with liquified carbolic acid to destroy the more superficial organisms, and its extent is accurately defined with a probe; then all the walls of the cavity are removed with a mallet and chisel or gouge for a full quarter of an inch all round. The operation is practically similar to mortising a hole in wood, and the portion that is to be removed should be marked out on the surface of the bone in the same way before any is cut away. The chief difficulty lies in removing the floor of the cavity efficiently, but in cases of doubt there is no objection to going right through the bone and removing the compact tissue on the opposite side. The ordinary carpenter's mortising chisel is a useful tool for this purpose; in any case fine instruments should be used and great care must be taken to avoid fracturing the bone, as the amount removed will always be rather large compared with the thickness of the bone.

If the situation and size of the cavity allow of this procedure being carried out satisfactorily, it follows that it results in the production of an aseptic cavity; this is treated in the manner recommended on p. 528. Should it fail, however, the surgeon should try one of the following plastic operations before he considers the serious alternative of amputation or the vexatious one of abandoning active treatment in favour of lifelong drainage.

Plastic operations upon bone cavities. (I) *Bevelling off the edges of a cavity.* When a cavity in bone cannot be closed by the formation of tissue from within, the simplest alternative is to endeavour to effect its closure by causing the soft tissues outside to adhere to its walls and thus to produce a skin-lined depression in the bone. This may be done in some cases in a very simple manner. Thus when there is a long bone

with a deep cavity running throughout the greater part of its length, and this cavity cannot be made to close in any other way, it may be converted into a broad flat groove or depression, into which the skin and subcutaneous tissues can be pressed so that they lie in close apposition with the bone, to which they will adhere in the course of healing. This method is specially suited for cavities in the tibia, and many successful results have been obtained in this way. The diagram (see Fig. 247) explains how it is done. The method has the great advantage that complete asepsis is not essential for its success ;

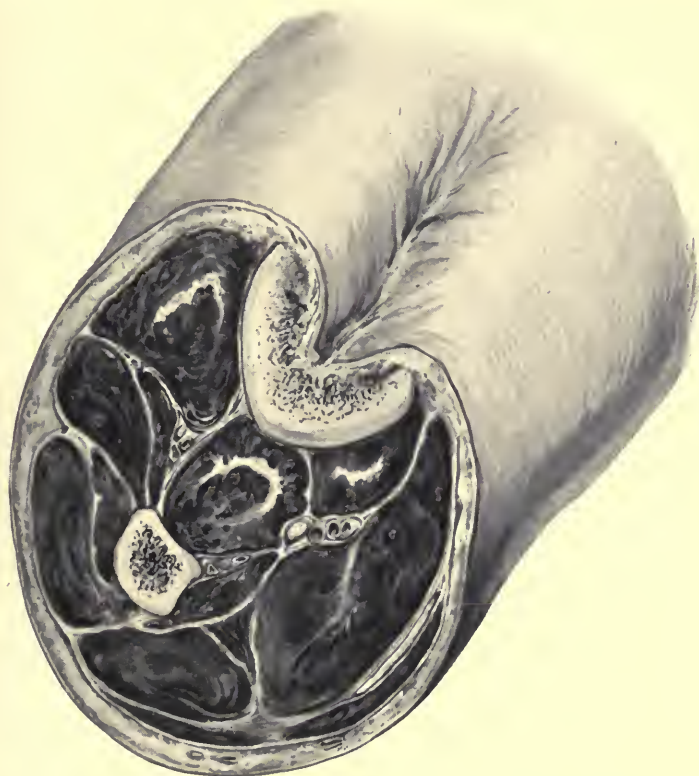

FIG. 247. OBLITERATION OF A CAVITY IN THE SHAFT OF THE TIBIA. The diagram shows how the soft parts are pressed down into the groove into which the cavity has been converted.

should suppuration occur, the soft tissues will still adhere if satisfactory drainage be provided.

(2) *The use of skin flaps or skin grafts.* This method is similar in principle to the preceding one, and may be adopted for those cases in

which the depth at which the bone is situated or the size or shape of the cavity prohibits satisfactory bevelling of its edges. It may be employed, for instance, in the case of the femur, where the depth of the gutter in the bone from the surface is so great that the skin cannot be made to reach down to it. Under these circumstances Thiersch's skin grafts may be tried, or a skin flap fashioned from the thigh and retaining its connexion with it by means of a pedicle may be turned into the gap and pressed well down into contact with the bone. An abscess cavity in the head of the tibia may sometimes be treated in a similar manner. It cannot be said, however, that this method is very successful as a rule. Generally the amount of sepsis present or insufficient blood-supply of the flap brings about death of the graft.

(3) '*Stopping*' the cavity with foreign substances. A favourite plan with many surgeons is to make the cavity aseptic and then fill it with some foreign material, just as a tooth is stopped, and finally to bring the soft parts together over it and secure primary union. This is theoretically a simple plan, but the weak point in it is the difficulty of securing asepsis in these cavities and the certainty of failure if a foreign body be introduced into a septic cavity.

The first method suggested for stopping these cavities was the use of decalcified bone, or sponge rendered thoroughly aseptic. This was supposed to form a soft trabecular framework in which the blood-clot was caught and underwent organization. I have tried decalcified bone in many cases and have been almost invariably disappointed with the results. The slightest amount of sepsis causes it to deliquesce and escape from the wound, whilst in an aseptic case it is not necessary (see p. 528).

The more recent plan is the stopping introduced by Von Mosetig Moorhof of Vienna. This is a sterilized iodoform wax (iodoform, sixty parts; spermaceti, forty parts; and oil of sesame, forty parts). This is heated until it is fluid, and is poured, while still hot, into the cavity, which has been previously scrupulously dried.¹ It finds its way into all the crevices of the cavity and effectually stops it and then hardens *in situ*. The stopping should be made flush with the surface of the bone, and the soft parts are then brought together over it. Most surgeons advise that a drain should be left in, but this should not be necessary if asepsis has been secured.

This method has been strongly advocated, and much success has been reported by Von Moorhof and others. Personally I have had

¹ Professor Silbermarck of Vienna takes the precaution of drying the bone cavity previous to the introduction of the wax by means of a hot-air blast from a special apparatus. This is to allow intimate penetration of the wax into the bone spaces, which restrains bleeding, and thus is antagonistic to sepsis.

disappointing results, and, from a number of cases that have come under my notice, my conviction is that when it is possible to obtain a really aseptic cavity it is easy to obliterate it by merely bringing the soft parts over it, but that every method of treatment is likely to fail when sepsis remains in the cavity. It is to the question of securing asepsis that the surgeon must devote his attention rather than to the particular method that he employs for obliterating the cavity.

REMOVAL OF A SEQUESTRUM DUE TO SYPHILITIC OR THE SO-CALLED 'QUIET' NECROSIS

These operations may be divided into those upon aseptic and those upon septic cases ; the operations upon the latter have been described above. This distinction is of practical importance, for whereas it is comparatively easy to expose and remove a sequestrum in an aseptic case so as to secure primary union and permanent healing afterwards, the conditions are quite different in the case of septic necrosis.

Operations upon aseptic cases. Before operation is undertaken, the exact position, shape, and size of the sequestrum should be ascertained, if possible by means of a stereoscopic radiogram ; this will help to determine to which aspect of the bone the sequestrum is nearest. The incision is planned according to the data thus obtained, and, if possible, exposure of the cavity containing the sequestrum should be effected by means of a flap that will cover the opening in the bone, so that the wound may be closed without drainage ; the risk of leakage and subsequent septic infection is thereby greatly reduced.

The knife should go down to bone throughout when marking out the flap, so that the periosteum can be raised along with the flap when this is reflected. If for any reason it is impossible to do this satisfactorily, the flap should be raised first and the periosteum then incised crucially and turned aside with a rugine over the area of bone to be removed. The flap must be large enough to allow the sequestrum to be removed without risk of doing damage or of leaving portions of dead bone behind. The bone over the sequestrum is cut away with a gouge or chisel until the sequestrum is entirely exposed and can be lifted out of its bed with sequestrum forceps. The cavity left is carefully dried (for which purpose a few drops of adrenalin are excellent), so that it can be seen whether any spicules have been left behind and whether there is any granulation tissue that needs removal. An attempt is then made to secure primary union (*vide infra*), which often succeeds in these aseptic cases.

OPERATIONS FOR THE OBLITERATION OF ASEPTIC CAVITIES
IN BONE

Indications. These operations are not confined to cases in which a sequestrum has been removed. After the removal of a myeloid sarcoma from a bone, for instance, a cavity is left which requires special measures for its closure.

The surgeon not infrequently excavates a deep trench in a long bone for the relief of pain in chronic osteitis and leaves a cavity comparable to that from which a sequestrum has been removed. This requires to be closed.

After a chronic abscess in the head of the tibia has been opened it is important that the cavity should be obliterated at once.

Operation. Many methods have been employed for this purpose; the majority of them are referred to in connexion with the closure of septic bone cavities (see p. 524). In my experience, however, they are rarely necessary in aseptic cases. The simplest method of obtaining closure here is to bring the soft parts together over the cavity, which is allowed to fill with blood-clot; healing of the soft parts occurs and is followed by gradual organization of the blood-clot. Many surgeons, in referring to this method, reject it on the ground that primary union is very difficult to attain under these circumstances, and that the wound almost invariably breaks down. This is altogether opposed to my experience. I have treated a number of bone cavities due to all the causes enumerated above with success by this method. Out of fourteen cases of which I have records, only one failed to heal by primary union; that was a myeloid sarcoma of the lower end of the femur in a young lady, which left a cavity in the condyles nearly the size of the closed fist after it had been enucleated. The hæmorrhage at the operation was profuse, and the oozing when the wound was sewn up was more free than was desirable. The result was a small subcutaneous hæmatoma, the contents of which were let out by separating the edges of the wound, and a sinus, discharging serum, remained for rather more than six weeks after the operation. This, however, then healed soundly and permanently without suppuration, and the patient has remained well up to the present time, a period of nearly four years. Careful examination of cases that have failed lead to the conclusion that the causes of failure are two in number, either sepsis, which is the more common cause, or too free oozing, which leads to the formation of a hæmatoma that has to be drained and is difficult to keep aseptic.

The preliminary steps of the operation have already been described (see p. 524). Absolute dryness of the wound should be effected before

bringing the soft parts together over it. Exposure to the air often suffices to check the bleeding, but, should this fail, a few drops of adrenalin chloride (1 in 1,000) poured into the cavity will suffice. The cavity is watched to see the rate at which it fills with blood. If this occurs slowly, clotting will go on *pari passu*, and, by the time the cavity has filled, the soft parts may be sutured closely over it. No drainage tube should be inserted; the pressure of the dressing serves to check venous oozing. The limb is put upon a splint, elevated somewhat, and, unless complications arise, is not dressed until the tenth day, when the stitches may be removed and the wound should be healed.

REMOVAL OF A TUBERCULOUS SEQUESTRUM

Tuberculous sequestra may be septic or aseptic. The main steps of the operations differ in no essential feature from those in the corresponding group of operations already described, and it will therefore be unnecessary to go further into the matter here. The whole subject of the operations for tuberculous disease of bone is dealt with by Mr. H. J. Stiles. The chief essential is removal of all the bone that is the seat of tuberculous mischief; the infection often reaches a considerable distance beyond the sequestrum. It is better to remove too much than too little. As tuberculous sequestra usually occur in the flat bones or the epiphyseal ends of the long bones there need not be any great difficulty in securing obliteration of the cavity left if the disease be completely eradicated and the wound kept aseptic. In tuberculous disease of the flat bones the operation of choice will generally be excision of the bone affected. This, however, is fully dealt with in Mr. Stiles's article upon operations for tuberculous disease of bones, where indications, methods, and results will be found.

BONE-GRAFTING

Indications. Portions of bones are not infrequently lost as a result of either accident or disease, and for many years attempts have been made to supply these deficiencies by grafting into the gap thus left fresh bone derived either from the same patient or from one of the lower animals. Hitherto this procedure has not met with uniform success, but the more general application of aseptic precautions is giving rise to much improvement in this respect.

Operation. There are two principal ways in which a gap in a bone may be obliterated, viz. by the *autoplastic method*, in which the bone

to fill the gap is furnished by the patient himself, and by the *heteroplastic method*, in which the bone is derived from one of the lower animals. The first method will only be very rarely used, as it will not be worth while to obtain enough bone for the purpose from the patient himself when it is so easy to obtain enough from one of the lower animals.

An interesting and novel application of the autoplasmic method is reported by Huntington (*Annals of Surgery*, 1905, vol. xli, p. 249); it is the case of a boy, æt. seven, who had a gap of five inches in his tibia after osteomyelitis. The limb 'hung loose, flail-like and utterly useless'. The fibula was sawn on the level of the lower edge of the upper part of the tibia remaining (*i. e.* the upper end of the gap), and the upper end of the lower portion of the fibula was pushed inwards and attached to the lower end of the upper part of the tibia remaining. The fibula was then approximately one-third the diameter of the normal tibia. 'Union was tolerably slow, but solidification was finally noted six months later.' This left a leg in which there was only one bone, and this consisted of the upper part of the tibia above and the fibula below. The child was allowed to walk about, but as there was much eversion of the foot from the obliquity of the fibula, that bone was sawn across below and the lower end of the upper portion joined to the upper edge of the lower end of the tibia, about three months later. This left a bone consisting of the tibia in the upper part, fibula in the middle, and tibia in the lower part. The result was good; there was three-quarters of an inch shortening, but the boy walked without support and was able to take part in school games.

In the heteroplastic method, the bone to fill the gap is supplied from one of the lower animals, freshly killed for the purpose. The principal objection to grafting in portions of the long bones of animals, such as rabbits, cats, and dogs, is that the bone is very slender and is difficult to secure in place, so that it is only possible to lay the bone in a trench, and the limb must be kept extended so that it does not get displaced. Various attempts have been made to graft large portions of the long bones from the larger animals, such as the horse, ox, and sheep, or even the corresponding bone from the human subject in amputation cases, so that the portion inserted may be firmly secured to the bone that it is intended to reinforce, and the limb after the completion of the operation may then resemble one in which operation has been done for ununited fracture.

A very interesting case is quoted in the *Annals of Surgery*, 1906, vol. xliv, p. 792, showing (1) that a large portion of a bone may be successfully grafted whole, and (2) that the bone need not necessarily be living bone at the time of its introduction. The case was recorded by Rausch

and Schoneberg, who grafted 9 cm. of the entire thickness of a tibia into a gap in the tibia of a patient from whom a myeloid tumour had been removed. The graft was taken from an amputation, and, after the necessary length of the bone had been cut and dissected out, it was boiled before its introduction into the body of its new host, where it was secured by ivory pegs. The wound united by primary union, but amputation of the limb had to be performed nine months later for recurrence of the myeloid tumour, and the condition of the limb was then ascertained by dissection. 'The portion of the tibia grafted in had grown firmly in place and was covered by new periosteum from which sprang its nutrient vessels; it had also united firmly to the bone at either end.'

This successful case opens up great possibilities in the way of bone-grafting, as, if experience should show that bones that have been boiled can be successfully implanted in this manner, the cause which undoubtedly played the greatest part in the failures of past years, namely, the inability to keep the graft sterile, can be avoided. The necessary manipulations entailed by procuring, preparing, and inserting the graft are very difficult to carry out without causing any contamination, whereas nothing is easier than to procure a graft beforehand and make it absolutely sterile by boiling immediately before its introduction.

Concerning the actual steps of the grafting little need be said. A suitable bed is made for the graft, and this should be lined by any periosteum available. The ends of the bone above and below should be refreshed to meet the graft and the latter secured in place according to its nature. If it be derived from a cat, dog, or rabbit, it will probably be much smaller than the bone it is to reinforce, and it will suffice to lay in one or more pieces and close the soft parts over them. If the graft is equal in diameter to the bone to be grafted they may be fixed together with wire or any other suitable mechanical fixation apparatus. If the graft be taken from one of the lower animals and be not boiled (*vide supra*) the stringent precautions observed in obtaining a nerve-graft (see p. 425) must be observed.

After-treatment. This will be identical with that of an ununited fracture (see p. 547).

CHAPTER III

OPERATIONS UPON FRACTURES

OPERATIVE interference in fractures may be required under a variety of circumstances. Thus the broken ends may have to be fixed immediately after the occurrence of the fracture, either in compound or simple fractures; on the other hand, operative interference may not be required until some considerable time has elapsed, when the operation will be necessary to rectify union of the bone in bad position or to remedy want of union. Thus we distinguish—

1. Operations upon recent fractures, including those upon (*a*) simple and (*b*) compound fractures, and
2. Operations upon fractures of long standing, including operations for (*a*) mal-union and (*b*) non-union.

OPERATIONS UPON RECENT FRACTURES

Indications. These include the operations which are performed before union has taken or has had time to take place. They will be—

(i) Operations undertaken as a matter of routine for certain fractures which cannot be treated satisfactorily otherwise; for example, those of the patella and the olecranon in which the line of fracture is transverse and the separation is marked. According to some surgeons, all oblique fractures of the tibia and the fibula also call for immediate operation; their view is that the obliquity of the fracture renders satisfactory apposition by splints impossible, and therefore the patient's ability to earn his living is seriously diminished. There is, however, no definite proof that such a statement is warranted; this subject is referred to more fully below.

(ii) Operations upon compound fractures in which the wound communicates freely with the fracture, and

(iii) Operations undertaken with the object of reducing a deformity which is irreducible by any other means, as in some cases of Pott's fracture and others in the region of joints.

(iv) Operations undertaken for the fixation of fragments that it is impossible to keep in apposition by any other means. This important group will include many, if not all, fractures involving an articular cavity.

Before proceeding to describe the various operations in use it will be advisable to say a few words with regard to the present state of opinion of the advisability of operating upon fractures.

Operations upon recent simple fractures. Certain points are no longer in dispute. Thus all surgeons are agreed that *no fracture should be operated upon if it can be got into good position and maintained there by other means.* There is no doubt that operations upon fractures both recent and of long standing are still amongst the serious operations of surgery, and rank high among the cases in which asepsis is difficult to secure. The excessive extravasation of blood, the bruising of the parts, and the prolonged and often powerful manipulations necessary to secure and maintain apposition, all favour infection of the wound, and the operation, therefore, is not one to be undertaken by any one who is at all doubtful of his ability to secure perfect asepsis. It is essential, therefore, that operative interference should be limited to cases in which it is absolutely necessary. At the present time the success or failure of endeavours to set a fracture can be checked with accuracy by the X-rays, which should be employed in all cases of fracture both for diagnosis and for ascertaining the results of treatment. The appearances produced by the X-rays, however, may be extremely misleading if the ordinary single negative or a screen be used, and the only way to obtain really reliable knowledge of the actual condition of affairs is to make use of good stereoscopic plates, which define the relative positions of the fractured surfaces with great accuracy, so that the surgeon can base upon them not only his decision whether to operate, but the exact steps of the operation and even the position of the incision.

Another point upon which agreement is now general is that *all those fractures should be operated upon in which there is no possibility of getting the fragments into good apposition by any other means.* The chief examples of this class are those transverse fractures of the patella and olecranon in which it is almost impossible to secure accurate adaptation and quite impossible to secure bony union by any other measures than operation.

After deducting these two large groups of cases there remains the still larger one about which there is some dispute at the present day. One school of surgeons holds that operation is called for in every case in which the apposition is not as good as could be reasonably expected after mechanical fixation of the fractured ends. Those who hold this view insist that an oblique fracture of the tibia and fibula should be operated upon at once, since it is practically impossible to get a fracture of this sort into really accurate apposition. Similarly, in fractures of the femur the fractured ends can seldom be got into accurate apposition and, although union occurs readily in the great majority of cases, a certain amount

of shortening always results. Those who advocate early operative interference hold that most, if not all, fractures of the femur should be treated by immediate operation for these reasons. On the other hand, there are surgeons of experience who never interfere in cases of simple fracture of this type unless they are called upon to do so either on account of faulty union or non-union.

The safest line of practice probably lies in a middle course between these extreme views, but the real difficulty is to determine which cases should be submitted to operation and which are best left alone. As already indicated, this difficulty is greatly diminished by the employment of stereoscopic radiograms. By means of them it becomes easy to ascertain the exact position of the fragments, and a fairly sound conclusion may therefore be arrived at as to whether union is likely to occur, and whether the patient is likely to have a useful limb when it does occur. Radiography has proved very valuable in this respect in recent years, and, thanks to it, certain general lines of treatment are beginning to be agreed upon.

Opinion is steadily inclining to the view that all *fractures implicating articular surfaces* should be operated upon without delay. These cases are very difficult to deal with from the point of view both of coaptation and fixation. Fractures of the elbow-joint, for example, are exceedingly trying in this respect, but the subsequent usefulness of the joint is such an important matter that no effort should be spared to obtain success. The results obtained from early operation in articular fractures, although by no means perfect yet, are nevertheless greatly superior to those obtained without it.

Among the cases that present the greatest difficulty are *fractures of the shaft of the femur*. Here, after splint treatment, union can be rarely obtained with less than an inch shortening, which necessarily means a permanent deformity to the patient, and if this were the only point to be considered it would therefore appear advisable that all fractures of the shaft of the femur, except perhaps those in elderly patients, would be better treated by immediate operation than by splints. But there are other considerations to be taken into account before this view can be accepted. Thus, for instance, it is well known that the operation is not free from danger; many cases of suppuration have occurred after an operation of this kind in the hands of most able surgeons, and even fatal results have been known. Even with the strictest aseptic precautions the operation has its own special risks, which can easily be understood when the mechanical difficulties of exposing, drilling, and uniting the fractured ends are remembered. Moreover, the question of sepsis is not the only difficulty. After the ends have been fixed in

a perfectly satisfactory manner, the least laxity in the after-treatment may allow the fractured bone to bend at the seat of union, and deformity and shortening, as severe as that for which operation was practised, may ensue. This is most likely to occur when the operation is done some time after the accident and the muscles have become irritable and contracted, so that besides the initial difficulty of getting the ends into apposition, muscular spasm after the operation is very likely to reproduce the faulty condition.

My personal experience leads me to advocate operation within the first week after the fracture, provided that the patient be strong, and that a stereoscopic radiogram shows imperfect apposition and definite overlapping. The fractured ends will be more easily cleared and drilled, and the muscles will not have become contracted; apposition, therefore, will be facilitated, and it will be much more easy to keep the limb straight afterwards by suitable extension. In feeble elderly people, on the other hand, operation should only be practised if there be much shortening or if a stereoscopic radiogram show such a great displacement that in all probability there is a considerable amount of muscle intervening between the fractured surfaces.

Multiple fractures will generally require operative interference, as it may be exceedingly difficult to get more than one fracture into proper apposition without it. A radiogram, however, will be the best method of determining this point.

Fractures combined with dislocation will almost always call for operation. Certain fractures, such as those of the clavicle, the shaft of the humerus, the ribs, and the metacarpal bones, very rarely call for operative interference, and then generally only for some complication.

The question of mechanical fixation. There is a general impression that an operation upon a fracture necessarily means that mechanical measures should also be taken for fixation of the fragments. Although this is necessary in the majority of cases, it is not by any means invariably so. It is obviously better to avoid the presence of foreign bodies in the wound unless they are absolutely essential, and therefore all forms of fixation apparatus should be abandoned when the conditions allow of it. The chief factors that will influence the decision on this point will be the size and direction of the fractured surfaces. Broad transverse fractured surfaces do not tend to become displaced after correct coaptation has been secured; perfect apposition may also be secured without risk of displacement when the fragments are rough and serrated, and the serrations can be made to fit into each other accurately so as to restore the bone to its normal contour. Under these circumstances the muscular tone will keep the fragments in apposition, and only ordinary care in

putting up the limb on a splint is required to prevent recurrence of the deformity. When, however, the fractured surfaces are very oblique and cannot be interlocked, some form of mechanical fixation is necessary.

Finally, it may be said that the more care and skill a surgeon spends on the coaptation of the fractured ends and the application of splints under full anæsthesia, the less frequently will operative interference be called for.

The time at which to operate. Extended experience convinces me that when a fracture requires operation the sooner this is practised the easier it is to do, and the better the final results are. Early operation implies that the fractured ends are much as they were when the fracture occurred, and it is therefore easy to turn out the clot from around the seat of fracture; since the bone ends are in their normal rough condition they can be fitted accurately together, and due advantage can be taken of any interlocking projections that may be present. This ensures absolute accuracy in adapting the fragments. Delay in operation, on the other hand, means that the soft parts become œdematous and infiltrated with adherent blood-clot, the muscles become tonically contracted so that it is difficult to stretch them sufficiently to obtain proper coaptation of the broken ends, and considerable violence has to be employed, a point of great importance when the difficulty of keeping some of these cases aseptic is remembered. When callus is forming, the fractured ends get rounded off and are less easily adapted, and there is more chance of displacement recurring even when mechanical fixation is employed. The infiltrated muscles are also in a state of irritation, and may give rise to trouble after the operation from their tendency to contract. For the last two years I have been in the habit of operating much earlier than was formerly the case, and the greater facility with which the operations can be carried out under these circumstances has impressed me strongly with the desirability of operating within a week of the fracture, and, if possible, within the first three days. This period is quite long enough to determine whether operative measures are likely to succeed; indeed, with a good X-ray installation it should be possible to arrive at a definite conclusion as soon as the result of a determined attempt to set the fracture under anæsthesia has been ascertained, so that there should be no excuse for delaying operation unnecessarily.

Operation. An essential point in all these cases is to secure thorough disinfection of the field of operation and its vicinity. The entire limb should be shaved and purified with the greatest care. It is difficult to foresee what parts of the limb will have to be manipulated by the surgeon or his assistants, and from what I have actually seen, I am convinced that a potent cause of the frequent occurrence of sepsis in these cases is

contact with unpurified skin during the manipulations necessary for coaptation of the fracture. It is impossible to tell beforehand what difficulties may be met with in any given case, and a careful observer will often notice that the hands come into contact with parts that have not been purified previously, owing to the impression that the case would be easier than it turns out to be in practice. Therefore the whole limb should be purified, and that part of it not concerned in the operation should be wrapped up in sterilized cloths firmly fastened on by pins or sterilized bandages.

The next point of importance is that the incision or incisions to expose the fracture should be free, and so planned as to allow of access to the seat of fracture with the least possible amount of injury to the soft parts. In the case of the thigh the incision will be usually on the outer side, whilst the ulna is best reached along its subcutaneous border, and the radius along its posterior aspect. Some modification of these incisions may be necessary after an inspection of stereoscopic radiograms. Very free incisions are required, because it may be necessary to employ wires, nails, screws, or some other form of fixation apparatus, and this cannot be done with ease except through an incision that exposes the bone ends freely, and allows them to be manipulated without undue bruising of the soft parts. Moreover, the surgeon will find it mechanically much easier to deal with the fracture if he has the soft parts incised sufficiently; few things are more difficult than to get the fractured ends into apposition through an insufficient incision.

All blood-clot is turned out and the periosteum over the broken ends is retracted to each side, and any soft structures intervening between the fractured ends are got out of the way. The finger is introduced into the wound and feels the fractured surfaces and notes their relative displacement. Traction must then be made upon the limb by an assistant so as to bring the fractured surfaces to the same level, and, when this has been done, the surgeon puts the fingers of one hand into the wound so as to ascertain the movements of the fractured surfaces, whilst with the other he manipulates the limb so as to get them into accurate apposition. It should always be possible to obtain this in recent cases, except when there is great comminution. The fractured ends are rough, and the surfaces can be made to fit accurately as soon as the muscular contraction is overcome. This may be very difficult, however, in muscular subjects, but deep anæsthesia and skilful manipulation will generally succeed. After coaptation has been obtained, the extension is relaxed, and the tension of the muscles should keep the fractured ends in apposition if they have been made to fit, and if the line of fracture be not too oblique. If they betray any tendency to slip

out of place they can be fixed with Peters's bone forceps (see Fig. 248), while preparations are made to fix them permanently.

When there is no tendency to displacement after the fractured surfaces have been got into apposition, the limb is held immovable by the assistant whilst the soft parts are brought together over the seat of the fracture and the wound is closed without a drainage tube. A light sterilized metal splint is then moulded to the limb and incorporated in the dressings. Outside this a firmer splint of wood may be applied if necessary, but in the upper extremity light splints only are necessary.

Methods of mechanical fixation. When it is necessary to fasten the fragments together one of the following methods must be employed :—

(1) *Absorbable sutures.* Many American surgeons make use of sutures of absorbable material, such as catgut or kangaroo tendon, in order to avoid leaving permanently in connexion with the fracture a foreign



FIG. 248. PETERS'S BONE FORCEPS. The forceps are fixed in position by the screw on the handle, and the drill is inserted between the limbs of the upper blade. The blades are interchangeable and are made for use on different bones.

body that may give rise to trouble at some later period. Trouble from this cause has been known to happen in many cases, and the objection to unabsorbable materials, therefore, is a perfectly valid one. The drawback to the use of absorbable sutures is partly that they are not strong enough to bear the strains to which they may be exposed in certain cases, and partly also that an elastic material such as catgut or kangaroo tendon is not rigid enough to keep the ends of the larger bones in proper contact. For fractures such as those of the patella and olecranon, for which American surgeons frequently use them, they are hardly to be recommended, as they cannot be relied upon to stand enough strain. For the few cases in which the object is rather to prevent lateral displacement than shortening of the limb they may be advantageously employed; for example, for fractures of the fibula where the tibia is not broken.

(2) *Unabsorbable sutures.* The principal unabsorbable sutures are silk and wire; of these, *silk*, although strong enough to bear any strain to which it may be exposed, is generally too pliable to secure perfect apposi-

tion. It may, however, be used for cases of transverse fracture of such bones as the patella, or particularly the olecranon, when the subject is not unduly muscular. In a muscular subject a silk suture strong enough to bear all the strain to which it would be liable would have to be so stout as to approximate to the gauge of wire. The only advantage it offers over wire is that the knot is not so prominent, and therefore less likely to cause irritation and require removal.

Silkworm-gut is hardly to be recommended in any case. Its strength is not much greater than stout silk, its pliability is very similar, and the

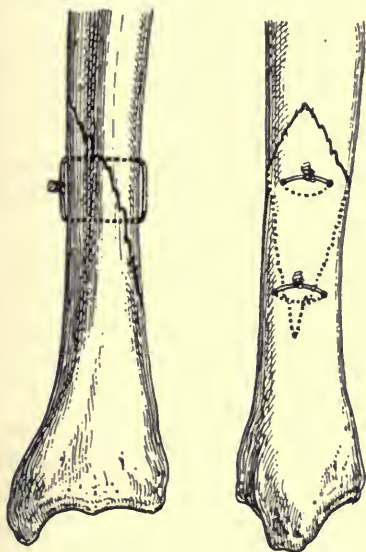


FIG. 249. WIRE SUTURES FOR OBLIQUE FRACTURES. This shows the simplest method of inserting the wires. There are many other ways which it is unnecessary to illustrate. With a stout wire twisted firmly practically no displacement is likely to occur.

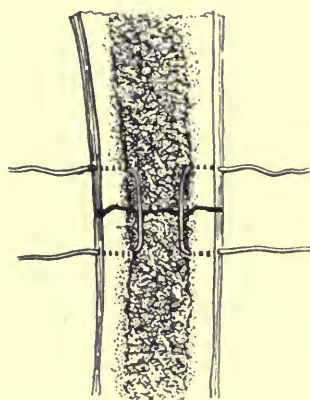


FIG. 250. WIRE SUTURES FOR TRANSVERSE FRACTURES. It is obvious that these sutures can only restrict but not abolish lateral displacement.

irritation caused by the ends of the knot are greater than those of silk, closely approaching that of wire.

Wire is perhaps the most generally useful of all fixation methods for bone. It is usual in England to employ pure silver wire of various gauges, No. 4 to No. 7,¹ according to the various bones that have to be wired. Thus, for the femur No. 7, for the tibia No. 6, for the patella No. 5, and for the olecranon, radius, ulna, and fibula, No. 4 is sufficient. In America, aluminium bronze wire is advocated by many surgeons, and is very pliable. The advantages of wire are considerable. It is pliable and

¹ This is the French catheter gauge.

easily introduced without undue disturbance of the bone ends. It is strong and gives a firm hold in suitable cases, and it is singularly free from liability to septic infection and extrusion. In certain cases it is the ideal method of treatment, particularly in oblique or irregular fractures, where the wires can be introduced as shown in Fig. 249. In cases of transverse fracture, however, the wire has to be introduced as depicted in Fig. 250, and under these circumstances there may be slight transverse displacement in spite of the wire, and, besides that, lateral bending may occur if there be much lateral strain. This is sometimes a matter of great importance in single bones like the femur and the humerus, and for them other methods may be required; but for the bones of the forearm, the pelvis, and the clavicle, as well as the patella and the olecranon, wire is on the whole the best and most easily managed method of fixation.

(3) *Screws, nails, and pegs of metal or ivory.* Reasoning from the analogy of carpentry, the easiest and best method of fastening two bone surfaces together is clearly by nails, pegs, or screws. Mr. Arbuthnot Lane has advocated plated screws with a cylindrical shank instead of the tapering one found in the ordinary screw; holes are bored in the bone for their reception nearly the size of the shank, which is then screwed home in the ordinary way, a cavity being countersunk for the head.

The advantage of screws is the ease and rapidity with which they can be applied and the firm union which can be obtained by them at the time of the operation, although even here much care must be exercised in choosing the direction in which the screw is to be driven, the exact size of screw to be used and the drill that makes the hole for it, in order to avoid splitting the bone. The weak point in the method, however, is that bone is a living structure, and the immediate result of the insertion of a foreign body into it is to set up irritation accompanied by rarefaction of the bone, so that the means upon which the screw relies for its approximating powers, viz. the binding power of its thread, is lost in a few hours; for all practical purposes the screw action is then lost, and it becomes a mere metal peg. This may not be a matter of great importance when the screw is driven into the bone at right angles to its long axis, as in fastening one condyle of the femur to the other in a fracture involving the knee-joint, but when the hold of the screw depends entirely upon the action of its thread, as, for instance, in the case of a fracture of the olecranon, the pull of the muscles may easily bring about wide separation of the fragments after the first twenty-four or forty-eight hours. I have seen this in several cases, the radiogram showing the screw loose and protruding from the bone into which it had been firmly screwed at the time of the operation.

Nails and tacks are often used, but generally in association with some

form of plate or collar which they fasten to the bone. Long nails are, however, sometimes used, and are perhaps more useful than screws for a fracture in which they can be introduced at right angles to the pull of the muscles; they are less likely to split the bone. They have been used with success in fractures into the knee and elbow joints, and particularly in the case of fractures of the neck of the femur in which they are driven into the outer surface of the great trochanter, and made to traverse the whole length of the neck whilst the fractured ends are held in position.

Ivory pegs are also advocated by some and have a definite sphere of usefulness. More than once I have successfully used the old plan of inserting an ivory peg between the two fragments in the long axis of the bone as shown in Fig. 251, after other methods had failed. The few cases in which this plan will be more useful than any other are those in which the fracture is near an articular surface, particularly the ankle or wrist joint, and the lower fragment is so small that no efficient traction can be made upon it, and a metal plate or collar cannot be satisfactorily applied owing to the difficulty of exposing the lower fragment sufficiently.

Metal pins, such as steel knitting-needles, are sometimes very useful in fractures into the knee or elbow joint, particularly the latter, and in some cases of fracture of the neck of the femur. The best way to employ them is to have the parts held firmly in accurate apposition

and then to drill the fragments from side to side and to pass one or more long steel pins or knitting-needles through the drill holes, leaving the ends projecting from the wound; the pins are removed at the dressing ten days later. This method is most suited for those cases in which other means of mechanical fixation would cause a projection on the articular surface that would interfere with free movement; it is, therefore, occasionally very useful in comminuted fractures involving the elbow-joint. The chief difficulty, however, is boring the hole for the pins. The only really satisfactory way of doing this is by means of a long drill driven by an

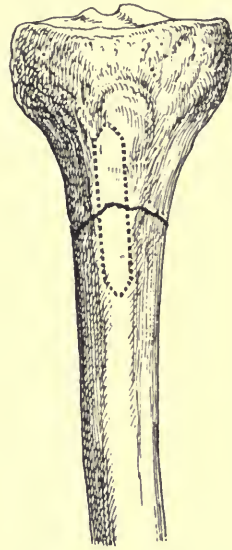


FIG. 251. BONE PEG FOR THE FIXATION OF FRACTURES. The peg is inserted into the centre of the bone. The chief difficulty is to get it into position, as the ends have to be widely separated. It is less suitable for the position in which it is shown in the figure than those mentioned in the text.

electric motor ; this penetrates the bone rapidly and without requiring any force, and thus there is little risk of displacement of the fragments. Otherwise it is difficult to avoid causing displacement from pressure of the drill if the boring be done by hand.

(4) *Metal plates and collars.* Metal supports at the seat of fracture, in the form either of plates or of a collar surrounding the entire bone, have been used for some time and have recently become very popular. My colleague, Sir Watson Cheyne, was one of the first to employ this method

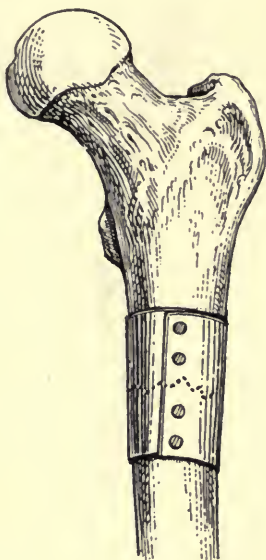


FIG. 252. METAL COLLARS FOR THE FIXATION OF FRACTURES. The metal is often perforated with holes beforehand. The best plan, however, is to wrap the collar round the bone so that its ends overlap and then punch holes through the overlapping ends into the bone. This clinches the collar and gives a firmer hold.



FIG. 253. METAL PLATES FOR THE FIXATION OF FRACTURES.

in the case of the femur, and it has given good results in many hands. Obviously the most workmanlike method is to surround the bone with a metal collar, which may be of sheet zinc or aluminium perforated with holes in the necessary places, and fastened on by tacks or screws of the same metal as the plate so as to avoid setting up any electrolytic action (see Fig. 252). The application of a collar is comparatively easy in single round bones like the humerus and the femur. For a triangular bone like the tibia the method may be modified by tacking on two or

more metal plates in a similar manner (Fig. 253) without surrounding the bone entirely. Stouter bone plates of the form shown in Fig. 254 may be used with screws, or the plate may be furnished with points like staples (see Fig. 255).

The advantage of this method is that it prevents transverse displacement; if the plate extend on to the bone for half an inch on each side of the line of the fracture, displacement is very unlikely to occur. The

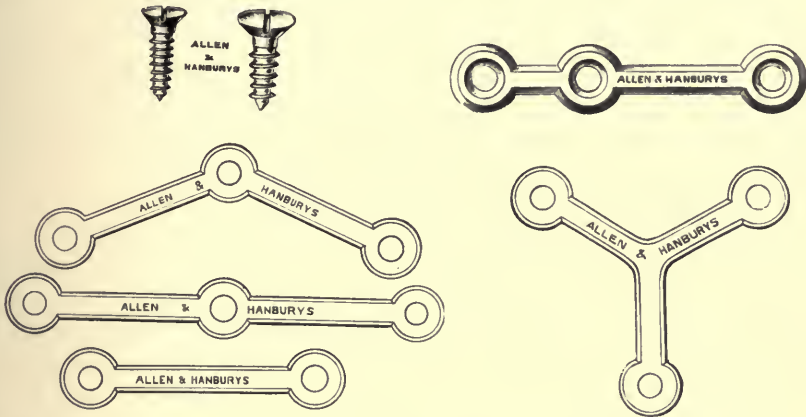


FIG. 254. SCREWS AND PLATES FOR FRACTURES. The plates are fastened on with the small screws seen above.

method is likely to find its most useful application in cases of ununited fracture of the femur in which the muscles have become permanently shortened; the great difficulty here is to get the ends in apposition, and it is most important to keep them there when once this has been done.

(5) *Bone clamps and similar special instruments.* Parkhill's ingenious instrument or some modification may be of value in certain cases, although most surgeons will agree that it is rarely necessary in simple frac-



FIG. 255. BONE STAPLE-PLATE FOR FRACTURES. These plates give an excellent hold. They are screwed on to the bone.

tures, and it is admittedly difficult to apply properly. The clamp must be left projecting from the wound included in the dressing, and the risk of sepsis, therefore, is not to be denied. It might be used advantageously for compound fractures of the femur or the tibia in which there is difficulty in maintaining apposition by other methods. It gives a very firm hold, and is therefore valuable in muscular subjects, especially those who are liable to be attacked by delirium tremens. It keeps the bone ends

in apposition until the exudation around has had time to fix them, and after its removal no foreign body is left in the wound. The risk of necrosis is therefore considerably diminished.

Operations upon recent compound fractures. Although it is not absolutely essential that all cases of compound fracture should be operated upon, yet a large majority of the cases will require some form of operative interference, and there is not nearly so much divergence of opinion as to which cases should be submitted to operation, and which should be treated without it, as there is in the case of simple fractures. Broadly speaking, it may be said that all cases should be operated upon in which the wound communicates freely with the fracture, and in the majority of these it will be advisable not only to trim and purify the soft parts and the fractured surfaces, but also to use some mechanical means to fix the broken ends.

Operation. In the first place, the wound and a considerable area of skin must be purified with great care. The success of the operation depends upon this, and no effort should be spared to secure complete asepsis. On the whole I have found that the best plan is to plug the entire wound tightly with cyanide gauze wet with a 1-1,000 solution of biniodide or perchloride of mercury until the surface of the gauze lies flush with the skin. The latter structure is then purified in the ordinary manner, but with the most scrupulous care and for a wide distance around the wound, the parts beyond the purified area being wrapped up in sterilized towels. The gauze packing is then removed from the wound, and this is opened up in any direction that may be necessary to give free exposure of the deeper parts. All blood-clot is turned out with the fingers or washed away with a stream of mercurial solution, and then the whole surface of the wound is inspected thoroughly, and any badly damaged tissue is snipped away with scissors. After this has been done, the whole raw surface is mopped over with undiluted carbolic acid, care being taken to see that no recesses of the wound are overlooked. Finally, the bone ends are exposed, and if they be dirty or have protruded from the wound they are not only scrubbed with a nail brush and a 1 in 20 carbolic lotion, but the superficial layers of the fractured ends are gouged or chiselled away, and undiluted carbolic acid is applied to the surface left; it is unnecessary, however, to do this unless the fractured ends have been obviously infected. Efficient drainage must be provided, either through the original wound or through suitably placed counter-openings.

This method of treating the wound may appear somewhat heroic and in some cases is possibly unnecessary, but it must be remembered that in the first place primary union is never aimed at in these cases; owing to the risk of infection it is unwise to suture the wound without

securing ample drainage, and therefore the irritation produced by the acid on the tissues is of little moment. In the second place, it is a matter of common knowledge that all the factors most conducive to sepsis are present in these cases, and that slight septic infection generally ends most disastrously. The muscles are badly bruised and are in a state of constant irritation, they retract and leave large irregular spaces in which blood collects and coagulates, and moreover the interior of the bone communicates with the wound; an infection of this area spreads rapidly, and is very serious.

After drainage has been provided for, the question arises whether or not fixation apparatus should be used to secure the fractured ends.

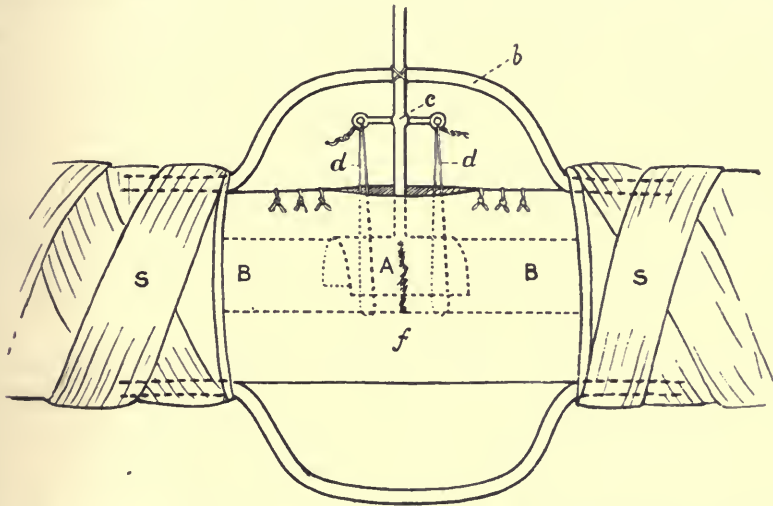


FIG. 256. WILLARD BARTLETT'S SPLINT FOR COMPOUND FRACTURES. This is fully described in the text.

This point will be largely influenced by factors similar to those governing their use in simple fractures. The use of any unabsorbable fixation apparatus in compound fractures may be followed by necrosis requiring the removal of sequestra and the fixation apparatus should the primary attempt at securing asepsis fail, and therefore many surgeons prefer to dispense with them whenever this is possible; when it is absolutely necessary to resort to them they use either absorbable sutures, such as catgut or kangaroo tendon, or some easily removable form of apparatus, such as metal pins that project from the wound or Parkhill's bone clamps.

The object of the removable forms of fixation apparatus is to keep the bone ends in apposition until sufficient consolidation has occurred to warrant their removal; this is then effected with the least possible disturbance to the structures about the seat of fracture.

Willard Bartlett (*Annals of Surgery*, 1906, vol. xliii, p. 381) figures an ingenious splint (see Fig. 256) which he used for a compound fracture of the humerus in which it was very difficult to maintain apposition after coaptation had been obtained. It consists of a silver plate, *A*, bent into a semicircle so as to make a half-collar which is placed like a saddle over the upper surface of the humerus, *B*, at the seat of fracture, *f*, after coaptation of the ends. To prevent this collar or saddle being displaced upwards, a vertical metal rod, *c*, is fastened to it, and this projects through the wound in the soft parts and can be secured to a bar, *b*, fixed in an interrupted plaster of Paris splint, *s*, or to a projection from any other form of splint upon which the limb may be put up. This saddle effectually prevents the fragments from being displaced upwards, and as a rule this will suffice, but, if the fragments betray any tendency to become displaced in spite of this, two loops of silver wire, *d*, can be carried around the under surface of each fractured end, pulled taut and fastened to a horizontal arm from the vertical rod. This presses the fractured ends firmly against the metal saddle and keeps them fixed. The apparatus is a good one, is sterilizable, and is easily made or modified to suit individual cases; it can be applied without any serious disturbance of the structures about the seat of fracture. It should be left in place for three weeks, when the wire loops are removed by traction, whilst a week later the metal saddle is dispensed with. The apparatus is surrounded by the dressing, and it is well to keep the external wound packed fairly widely, otherwise it will be difficult to extract the metal saddle. In a case reported by Bartlett good union resulted with perfect position in spite of the wound becoming septic. It has given excellent results in my hands in a case of compound fracture of the humerus, the position being perfect and union uneventful. It is only called for when other methods that do not involve the use of a removable apparatus are inapplicable.

After-treatment. The most satisfactory form of splint for these compound fractures is a plaster of Paris casing. In order to get proper access to the wound for the subsequent dressings, the splint should be arranged with a wide interruption opposite the seat of fracture (see Fig. 256). If these plaster casings are suitably designed and properly applied they are very safe and efficient splints, but it is important that the interruption should be wide enough to prevent all risk of discharge soaking away underneath the casing. The interruption can be formed by two or three strips of malleable iron, the ends of which are incorporated in the two portions of the casing and the centre parts bent out sufficiently to allow the dressings to be applied beneath it.

OPERATIONS UPON FRACTURES OF LONG STANDING

Operations for ununited fracture. Indications. All ununited fractures require operative interference. The chief difficulty, however, is to know when any given case falls into this category. By the term 'ununited fracture' is meant a fracture in which consolidation will not occur spontaneously, but the difficulty is to know exactly when incomplete or defective union becomes true non-union. In times past operation was never undertaken until after the lapse of some months, and until it was quite certain that consolidation could not be induced by any method of non-operative treatment. In this way much valuable time was wasted that might have been saved by early operation. Not infrequently too the surgeon found on exposing the fractured ends that union without operation had been hopeless from the first. It may safely be said that operation should be had recourse to as a rule much earlier than was formerly the case. It may also be said with fairness that, with the possible exception of operations upon the femur which are notoriously rather more difficult to keep aseptic, operation adds nothing to the patient's risks in skilful hands, while it diminishes the length of his convalescence.

The following statements fairly represent the present state of surgical opinion :—

(i) All cases should be operated upon without delay that show thin pointed atrophied bone ends and an entire lack of callus a month after the injury. This condition is made out easily with the aid of good stereoscopic radiograms.

(ii) Every case of fracture in which consolidation has not occurred at the end of two months from the receipt of the injury should be submitted to operation provided that there is no progressive improvement made under non-operative measures, and that there is no constitutional disease to contra-indicate it. In the case of the femur this period might be extended to three months.

Operation. The steps of the operation resemble those for similar operations in simple fractures (see p. 536), but are much more difficult owing to the contracted condition of the muscles and the alterations that have taken place in the bone ends and the soft parts around.

Complete exposure is the essential for success in these difficult and tedious operations. Without it, it is very difficult to ascertain the exact condition of affairs and to determine the best treatment to adopt, while the various manipulations necessary to get the bone ends together and

fix them are only possible after violence, which causes undue damage to the tissues.

The incision will generally be in the long axis of the bone and on that aspect of the limb where it will involve the least damage to the soft parts, but the determination of the exact seat and number of the incisions can be most satisfactorily arrived at after an inspection of stereoscopic radiograms.

When the seat of fracture has been reached, the soft parts must be separated from the bone all round if it should be necessary to employ some form of mechanical fixation, as otherwise it will be impossible to manipulate properly when wires or screws have to be inserted. In doing this the periosteum should be detached from the bone in the immediate vicinity of the fracture. When there is no need to use fixation apparatus it is not necessary to clear the soft parts from the deep surface of the fracture. The callus is divided as nearly as possible along the original line of fracture, and the bone ends are prepared for union. The line is easily made out by moving one fragment upon the other and inserting a knife or chisel between them.

At this stage of the operation two distinct groups of cases may be differentiated. In the first there is simple non-union without displacement, while in the second the non-union has resulted from the displacement. The treatment differs in the two cases.

(a) *Simple non-union without displacement.* Here it is obvious that no fixation apparatus is required, since there is no displacement to correct. Therefore it will be sufficient to expose the anterior and lateral surfaces of the fracture only; the posterior aspect can be left undisturbed. These cases are not very satisfactory except in the rare cases when non-union has followed want of proper immobility during repair. When the fragments are in apposition and are kept on suitable splints and still non-union results, there is generally some constitutional cause at work, and the operation is apt to be followed by non-union also.

The first object in these cases is to remove all soft tissues between the ends of the bone. The next is to refresh the bone surfaces so that active repair may be encouraged. For this a saw is unnecessary; a broad chisel will do. I have found it an excellent plan not to remove the portions of bone thus pared off, but to crush them down firmly into the small gap between the refreshed ends, and I am under the impression that better success is obtained in this way than by simply leaving the refreshed ends in apposition. If the fracture be in the forearm or the leg, and both bones be involved, a similar procedure is carried out in the second bone through a similar incision.

(b) *Non-union accompanied by displacement* of the fragments calls for

more elaborate treatment. After the ends have been cleared of soft tissues, they should be sawn so as to fit as accurately to one another as possible. Generally the surfaces of the fracture are oblique, and it may often be possible to fashion a projection in one end to fit a corresponding depression in the other; this is an excellent aid to stability if it can be done, but the limb should not be shortened unduly in order to obtain it. The sawing may be done *in situ* by a keyhole saw (see Fig. 257) or Gigli's wire saw, but more accurate work will be done by making the incision free enough to turn the ends of the bone out before sawing them. This step also facilitates the application of the fixation apparatus which will always be required in these cases.

The chief difficulty in ununited fractures accompanied by displacement is to get the ends of the bones together. The shortening of the muscles and soft parts is of long standing and is very difficult to overcome. Much may be done by persistent and powerful traction exerted by an assistant,

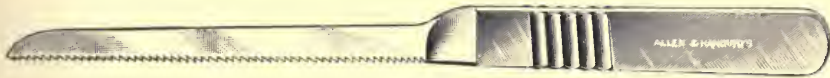

FIG. 257. KEYHOLE SAW FOR BONE.

accompanied by the division of tight bands that start into relief under the finger as the traction proceeds, though here the greatest care is necessary to avoid damage to important structures. When there is any projecting edge in one fragment to fit into a depression in the other, they may be made to engage by bending the limb at the seat of fracture, hitching one fragment against the other, and then straightening the limb again; this exerts a most powerful leverage, especially in the case of the femur, which generally gives the most trouble. In fractures of this bone in which the fractured surfaces are smooth and oblique and offer no surfaces that can be entangled, I have been successful by surrounding one fragment with a metal collar standing up nearly an inch beyond the end of the bone and, after fastening this firmly in position with tacks or nails, flexing the limb at the seat of fracture as before, hitching the end of the uncollared fragment into the rim of the collar surrounding the other one, and then straightening the limb again. This forces the two ends of the bone together inside the metal collar, by which they are surrounded and firmly held, while screws or tacks are inserted between the collar and the second fragment, thus keeping all secure.

In fractures of the leg and forearm, traction will generally suffice to bring the fractured ends into apposition provided that they have been freed before traction is made. The methods of mechanical fixation have been described already (see p. 538), and the surgeon

will employ whichever he thinks best adapted to the particular case before him.

Every visible bleeding vessel is ligatured, and any persistent oozing may be stopped by the application of adrenalin. The soft parts are brought together over the seat of fracture by buried sutures of chromicized catgut, the skin is united without a drainage tube, and the limb is immobilized upon a splint.

Operations for mal-union. Indications. (i) The removal of unsightly masses of bone or those causing hindrance to the free use of the limb.

(ii) Fractures that have united with great angular deformity and are both unsightly and crippling owing to the shortening produced.

Operation. In the first group of cases the operation is comparatively simple. The steps of it are merely exposure of the seat of fracture and removal of the offending masses of bone without interfering with the union.

It is in the second group of cases, however, that the surgeon finds the greatest difficulties of all the operations upon fractures. To increase the length of a limb shortened by union of a fracture with great displacement requires great resource, much patience, and considerable strength; sometimes all these qualities fail to attain the object in view.

The fracture, after exposure, must be reproduced by dividing the uniting medium, and it is here that the surgeon will show his resource by making the line of bone section in such a way that the cut surfaces will lock into or rest firmly against one another when they are got into apposition.

Getting the surfaces into apposition may call for much patience and much exertion. The plans already recommended for ununited fracture may be tried, and will probably succeed unless the shortening be very great and the line of fracture very oblique, but it is quite common to have to put up with a certain amount of permanent shortening.

After-treatment. This is the same for all cases. A plaster of Paris casing, applied while the patient is still under the anæsthetic and given time to set before he is allowed to come round, will be the best method of securing perfect immobility after the operation. The splint will need interruption to allow of the application of dressings. After the stitches have been removed, a casing can be made to cover the whole limb uninterruptedly.

Results. On the whole these are not so good as theoretical considerations would lead one to expect. It is difficult to give figures, but probably all surgeons of experience in these cases will admit that union is often much delayed after operations for non-union, and in

quite a fair proportion may never occur. This is most common in young children and in the cases characterized by pointed atrophied bone ends and an entire absence of callus. The most untiring efforts may fail in these cases and amputation be the only alternative. In one case I operated five times by five different methods unsuccessfully.

There is some risk of sepsis still attaching to these operations upon the femur even in skilled hands. This of course should be a preventible occurrence.

In operations for mal-union the results may also be disappointing, inasmuch as it may be impossible to restore the limb to its normal length, although any angular deformity present before operation may be remedied successfully.

SECTION VIII

OPERATIONS FOR NON-TUBERCULOUS
AFFECTIONS OF JOINTS

BY

FRED^c. F. BURGHARD, M.S. (Lond.), F.R.C.S. (Eng.)

Teacher of Operative Surgery in King's College, London; Surgeon to King's
College Hospital; and Senior Surgeon to the Children's Hospital,
Paddington Green

CHAPTER I

GENERAL CONSIDERATIONS

It will be best to discuss briefly the general considerations applying to each type of operation practised upon joints, reserving for special description in subsequent pages special points in these operations upon individual joints.

ARTHROTOMY

Arthrotomy or simple incision of a joint is useful in many affections and is much more frequently resorted to at the present day than at any previous period in the history of surgery. Formerly, to incise a joint of any size was to imperil its movements and possibly to entail amputation of the limb or loss of life. Owing to the complexity of most of the joint surfaces and the number of recesses in connexion with them they are difficult to drain and, should sepsis occur, the results are likely to be more serious than they would be in a wound that can be drained freely.

Indications. (i) Arthrotomy is often required for simple *exploration* of the joint in order to determine the nature of the lesion and to settle the appropriate treatment.

(ii) In *suppurative arthritis* a free incision must be made into the joint in order to establish effective drainage.

(iii) Arthrotomy is called for in cases of *acute non-purulent effusion* of rheumatic, gonorrhœal, or traumatic origin in which the effusion refuses to respond to other measures and threatens to weaken the joint permanently by overstretching its ligaments. It is especially indicated in those cases in which there is any doubt as to the exact nature of the case, as the possibility of some internal derangement must always be borne in mind.

(iv) For the extraction of a *movable body* in the joint, or in the rarer cases of a foreign body.

(v) At the present day arthrotomy is probably most frequently practised as a preliminary to the removal of a *displaced semilunar cartilage*. It is also a preliminary to the operations for various other internal derangements of the joint.

Operation. In all cases the most scrupulous care must be taken to disinfect not only everything that comes into contact with the wound

but also a wide area of the patient's skin. In nearly all these cases the surgeon desires to have the joint moved in some particular direction during the course of the operation so that he may obtain better inspection of or better access to certain parts of the joint. For this purpose the assistant has to bend the joint, and it is quite common to see him grasp the limb by some portion that has escaped purification prior to the operation; this mistake of course may lead to very serious consequences. The limb on both sides of the joint should be securely wrapped up in sterilized cloths bandaged firmly on so that they cannot get displaced.

The position of the limb and the surgeon and the site and length of the incision will be determined partly by the individual joint and partly by the particular object of the operation; this is dealt with more fully in connexion with the individual joints. In all cases it is important to arrest all hæmorrhage before the joint is opened, and it is well to distinguish between the capsule of the joint and the synovial membrane and open each by a separate incision. In the earlier stages of the operation, before the joint has been incised, the use of chemical antiseptics is admissible, if the surgeon be in the habit of employing them. When, however, the synovial cavity has been opened, all chemical antiseptics should be abandoned, as their use is likely to irritate the synovial membrane; sterilized salt solution at a temperature of 100° F. should be substituted.

All manipulations of the joint cavity should be of the gentlest description consistent with the object in view. The edges of the synovial membrane may be caught in fine-toothed catch forceps and held apart by an assistant. If retractors be used they should be blunt hooks, and no force should be employed. All manipulations inside the joint should be done with forceps if possible, and the finger should only be introduced if it be absolutely necessary; in this way unnecessary bruising is avoided. All traction should be as light as possible and any incisions should be cleanly made with instruments as fine as is consistent with the effective performance of their duties.

When the object of the operation has been attained, great care must be taken to see that bleeding from the joint cavity has ceased entirely before the synovial membrane is sutured. Hæmorrhage generally ceases readily, except when an artery has been wounded, and this should be picked up and tied. Exposure to the air or douching with saline solution at a temperature of 115° F. usually suffices to stop oozing quickly; it is inadvisable to employ drainage if it can be avoided. The articular cavity should be closed in two separate layers if possible; one suture of the finest catgut taking up the cut edges of the synovial membrane,

the other, rather stouter, approximating the incision in the capsule ; the skin wound is sewn up separately. When possible a flap should be raised over the proposed incision in the capsule, so that when the wound is sutured the cicatrices in the various structures do not correspond.

ARTHROPLASTY

From the early days of surgery it has always been an important object to obtain mobility in ankylosed limbs. Many plans have been adopted and much time and trouble have been expended, but it must be confessed that the results have hitherto been disappointing. Within recent years, however, the work of Murphy has opened up wider possibilities in this direction. Briefly stated, his method may be said to imitate by art what occurs in nature when an ununited fracture results from the interposition of soft structures between the fractured ends.

Operation. The actual details of the operation will vary with the individual joint for which the operation is done, but generally speaking the steps of the operation are as follows:—The joint is fully exposed by whatever incision may be most suitable. The union between the bones is divided by knife, saw, or chisel according to the nature of the uniting medium. The articular surfaces are then shaped in any way that the surgeon may think will best facilitate movement, the most essential point being that the surfaces are chiselled or scraped until they are perfectly smooth. The next step is to see that there are no contracted structures that will interfere with the desired movements of the joint, and with this object attempts are made to carry the limb through the full range of the movements desired. This is done by the assistant whilst the surgeon examines for the presence of tight bands or ligamentous structures and divides them freely. If the obstacles to movement be contracted muscles, their tendons should be lengthened instead of being divided.

The contraction preceding the ankylosis may have been so great that vessels or nerves may be endangered by the straightening process. Here it will be a consideration whether the limb should be gradually stretched by extension and the arthroplasty finished at a subsequent date when the limb is straight, or whether sufficient bone should be cut away to enable the limb to be brought into the desired position without endangering these important structures. This question will be largely determined by the joint in question. For instance, the sacrifice of bone in the upper extremity is a matter of small importance as compared with the lower extremity, in which it affects locomotion considerably.

The most important part of the operation is the means adopted

for maintaining the movement thus obtained, and the work of Murphy holds out considerable promise in this direction. A thick layer of the neighbouring soft structures is detached in the form of a flap corresponding in its dimensions to the cross-section of the joint, and is laid in between the bone ends and fastened in position by sutures. The origin of this flap is not a matter of great importance, but it should contain plenty of fat and areolar tissue. This substance seems to be most suited for promoting movement, as it develops bursaë readily, and in practice it has been found to answer the purpose better than anything else. The incision in the capsule is closed without a drainage tube.

After-treatment. Passive movement is begun as soon as possible. When the ligamentous connexions between the articular ends have not been divided too freely it may be practised from the third or fourth day; when the contrary is the case a week or ten days should be allowed to elapse. At first passive movement will have to be done under gas, but it must be persisted in regularly and the range of movement should be steadily increased; this should be accompanied by massage. The object is to develop a fairly thick layer of connective tissue between the two joint ends, and the formation of a bursa in this to act as a synovial cavity. Very promising results have been obtained by persevering attempts in this direction.

This method is not certain in its results and is often painful in practice, and many attempts have been made to supply a smooth articular surface resembling the normal one. For this purpose cartilage has been grafted from the ribs on to the prepared bone ends, but hitherto with only moderate success. The most remarkable results, however, have been reported by Professor Lexer, of Königsberg, who has transplanted entire articular surfaces bodily with a truly remarkable degree of success. In two cases he resected the entire articular surface of the knee for ankylosis, and grafted into the gap of three fingers' breadth thus made the corresponding articular surfaces from a freshly amputated human limb. In one case the graft was united by nails, in the other by wire. In both cases union was immediate and quite firm. In the first case there was a range of flexion of the joint up to 45° five months after the operation; the second case was too recent to report as to movement.

Besides this complete substitution of the joint surfaces, Lexer reports several partial substitutions, all of which are said to have been quite successful. In one case the entire upper end of the tibia was grafted into the gap left after resection of that part of the bone for cystic central sarcoma. Five months after operation lateral movement was absent and flexion and extension were nearly normal. It is worthy of note that in this case the end of the bone from a right leg was grafted into

the gap in the patient's left leg and yet movement was not interfered with. In another case the lower end of the femur and one condyle were substituted for the upper end of the humerus, the end of the bone being surrounded by the capsule fastened by a purse-string suture. The shaft of the humerus and the graft were pegged together by means of the fibula from the amputated leg thrust into the medulla of the two bones (see Fig. 251). Lexer also reports an excellent result from replacing the phalanx of a finger with one from a toe (*Surgery, Gynecology, and Obstetrics*, 1908, vol. vi, p. 601).

ARTHRODESIS

This operation is the converse of the one just described and has for its subject the replacement of an unduly movable joint by a stiff one.

Indications. The aim of this operation is to produce ankylosis in a paralysed and flail-like joint, and so to allow movements to be carried out in a limb which were previously impossible. The operation is applicable in both extremities, and is called for in bad cases of infantile paralysis in which it is impossible to restore movement by tendon-grafting or muscle-transplantation. Thus it may be very useful to stiffen a flail knee-joint, as the patient will then be able to walk, provided that there be enough power left in the muscles moving the ankle to allow the weight to be borne upon that joint without its giving way. Similarly, by fixing a flail shoulder-joint the upper extremity may be moved by the scapular muscles, or by fixing a flail elbow the hand may be rendered much more useful.

Operation. The operation has for its object removal of the articular cartilage so as to leave large areas of raw bone, which are then brought into apposition and kept immovable until bony union has taken place between them. Removal of the cartilage is best effected with a chisel, and the operation should be done with the least possible damage to the soft parts, so as not to weaken the limb more than is necessary. The steps of the operation for the exposure of the articular surfaces must of course vary with the joint operated upon.

Results. The limb is kept rigid until firm bony union has occurred. Unfortunately, however, although this would probably follow in healthy subjects, it may not occur in these cases, possibly owing to defective nutrition of the parts. However, union may occur later on if the limb be kept in some light casing. Even when the operation fails to secure firm bony union the patient's condition is often considerably improved. Fibrous union takes the place of the useless flail-like limb,

and at the worst some light splint has to be employed in place of the cumbersome and heavy metal apparatus that would otherwise have to be worn.

ARTHRECTOMY

The term arthrectomy strictly implies the removal of the joint surfaces. As the term is generally applied at the present day to removal of tuberculous disease from a joint it is therefore somewhat of a misnomer. Strictly speaking, operations such as excision and arthrodesis are also arthrectomies. The term is a bad one and should be banished from surgical terminology; its true significance being the extirpation of tuberculous disease from a joint, it does not fall into the scope of this article and will be dealt with by Mr. Stiles.

EXCISION

By excision of a joint is understood the removal of the articular surfaces.

Indications. In non-tuberculous cases this operation is done chiefly for extensive injury to the bones entering into the formation of a joint. It may also be required for a dislocation which is not reducible by other methods, or to rectify ankylosis by producing a movable joint or by removing the deformity. The primary object of the operation in non-tuberculous cases is to remove the articular ends of the bone in order to produce either mobility or stability, or, in cases of extensive injury, to preserve a limb which would otherwise have to be amputated. The synovial membrane is only excised in so far as it is removed along with portions of the bone. Operations of this type are done in adults for tuberculous disease of the joints; they will be dealt with by Mr. Stiles.

As these operations vary entirely according to the joint affected, no general rules apply to them, and each individual joint will be treated separately in the following chapters.

CHAPTER II

OPERATIONS UPON THE WRIST-JOINT

THE only operation of importance in connexion with the wrist-joint is excision. The joint may be opened in an operation for a badly united Colles's fracture, but in that case the operation is not primarily one upon the joint itself.

EXCISION OF THE WRIST

Indications. Complete excision of the wrist will scarcely ever be required for any condition save tuberculous disease—a condition that does not come into the scope of this article. Partial excisions are, however, not infrequently practised for fractures of various carpal bones, the knowledge of which is becoming increased by the use of radiography. When these fractures are compound, the bones, or portions of them, may be extracted by enlarging the existing wound; otherwise one or both of the incisions recommended by Lord Lister (*vide infra*) may be used.

Operation. Several methods of excising the wrist have been introduced; of these only Lord Lister's will be described here, as it is an excellent dissecting-room exercise, and may also be used for a partial excision in cases of injury. It is described as follows by the late Mr. Timothy Holmes (see Holmes's *System of Surgery*, vol. iii, p. 748):—

‘An incision is made commencing in front over the second metacarpal bone internal to the tendon of the extensor secundi internodii pollicis, and running along the back of the carpus, internal to the same tendon, as high as to the base of the styloid process of the radius. The soft parts, including the extensor secundi internodii and the radial artery, being cautiously detached from the bones external to this incision, and the tendons of the radial extensors of the wrist being also severed from their attachments, the external bones of the carpus will be exposed. When this has been done sufficiently, the next step is to sever the trapezium from the other bones with cutting-pliers, in order to facilitate the removal of the latter, which should be done as freely as is found convenient. The operator now turns to the ulnar side of the incision and cleans the carpal and metacarpal bones as much as can be done easily. The ulnar incision is now made (see Fig. 258). It should be very free, extending from about 2 inches above the styloid process down to the middle of

the fifth metacarpal bone, and lying near the anterior edge of the ulna. The dorsal line of this incision is then raised along with the tendon of the extensor carpi ulnaris, which should not be isolated from the skin, and should be cut as near its insertion as possible. Then the common extensor tendons should be raised, and the whole of the posterior aspect of the carpus denuded, until the two wounds communicate quite freely

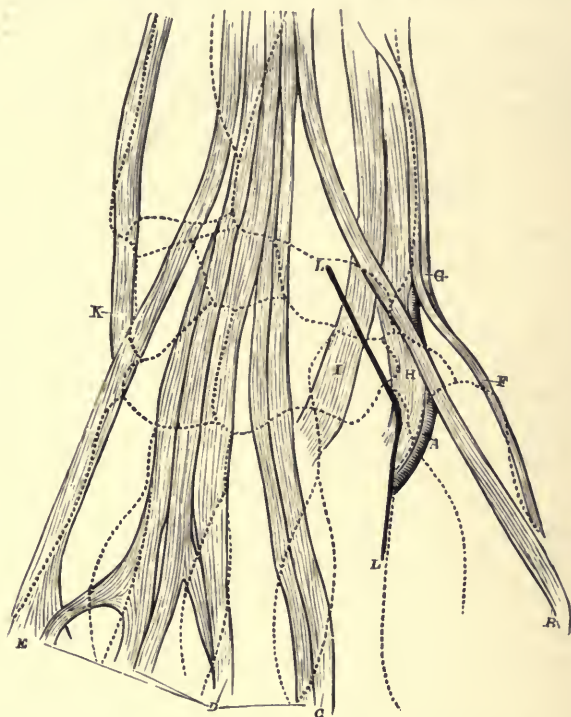


FIG. 258. STRUCTURES CONCERNED IN LISTER'S EXCISION OF THE WRIST (Holmes's *System of Surgery*). A, The radial artery; B, Tendon of the extensor secundi internodii pollicis; c, Metacarpal of index finger; Tendons of—D, Extensor communis digitorum; E, Extensor minimi digiti; F, Extensor primi internodii pollicis; G, Extensor ossis metacarpi pollicis; H, I, Extensor carpi radialis longior and brevior; K, Extensor carpi ulnaris; L L, Line of radial incision.

together; but the radius is not as yet cleaned. The next step is to clean the anterior aspect of the ulna and carpus, in doing which the pisiform bone and the hooked process of the unciform are severed from the rest of the carpus, the former with the knife, the latter with the cutting-pliers. In cleaning the anterior aspect of the carpus, care must be taken not to go so far forward as to endanger the deep palmar arch. Now, the ligaments of the internal carpal bones being sufficiently divided, those bones are to be removed with blunt bone-forceps. Next the

end of the ulna is made to protrude from the incision, and is sawn off, as low down as is consistent with its condition, but in any case above its radial articulation. The end of the radius is then cleaned sufficiently to allow of its being protruded and removed. If this can be done without disturbing the tendons from their grooves, it is far better. If the level of the section is below the upper part of the cartilaginous facet for the ulna, the remainder of the cartilage must be cut away with the pliers. The operator next attends to the metacarpal bones, which are pushed out from one or the other incision and cut off with the pliers so as to remove the whole of their cartilage-covered portions. The trapezium bone, which was left in the early stage of the operation, is now carefully

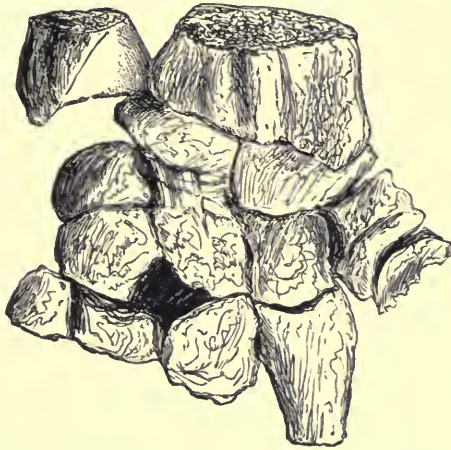

FIG. 259. THE PARTS REMOVED IN EXCISION OF THE WRIST BY LORD LISTER'S METHOD (*Holmes's System of Surgery*).

dissected out, so as to avoid any injury to the tendon of the flexor carpi radialis or to the radial artery, and the articular surface of the first metacarpal bone is then exposed and removed. Lastly, the cartilaginous portion of the pisiform bone is taken away; but the non-articular part is left behind, unless it is diseased, in which case it should be removed entire. The same remark applies to the hooked process of the unciform.

'The operation is one of the most tedious and difficult in surgery, but it appears to me to give very satisfactory results, and therefore should, I think, always be adopted in such cases as are favourable for any operation at all. It is advisable, if not necessary, to put on Esmarch's bandage; so that the view of the parts should not be obscured by blood. It is also very desirable to break down any adhesions which the tendons may have formed while the patient is under anæsthesia previous to the operation.

‘No tendons are necessarily divided in this operation except the extensors of the wrist, for the flexor carpi radialis is inserted lower down than the point at which the metacarpal bone is usually divided.

‘In order to ensure motion, particularly in the fingers, passive movements should be performed from a very early period after the operation. For this purpose, Mr. Lister places the limb on a splint with the palm of the hand raised by a large wedge of cork, fixed below it; so that the joints of the fingers can be moved without taking the limb off the apparatus. Special arrangements are made for keeping the splint steady, and for preventing displacement of the hand to either side. Careful and methodical passive motion should be used to each several joint—to those of the finger and thumb almost from the day of the operation, and to the wrist as soon as the parts have acquired some firmness, each movement, pronation and supination, flexion and extension, abduction and adduction, being separately exercised; and the patient should be encouraged to make attempts at voluntary motion as early as possible. In order to exercise the fingers, the portion of the splint which supports them may be removed, while that on which the wrist is received is still left. Finally, when the rigid splint is left off, some flexible support is still to be worn for a long time.’

Lord Lister was always careful to provide against stiffness of the thumb in the adducted position by having a notch or deep groove cut in the lateral aspect of the splint, so that the thumb could hang down well away from the other fingers. The functional results after the operation are very fair, but a moulded wristlet must be worn for several months in order to counteract the tendency to displacement of the hand to the radial side.

CHAPTER III

OPERATIONS UPON THE ELBOW-JOINT

ARTHROTOMY AND DRAINAGE

Indications. (i) The elbow-joint is not infrequently the seat of *acute suppurative arthritis*, which is often of traumatic origin and follows septic wounds about the point of the elbow, leading to suppuration in the olecranon bursa and subsequent infection of the joint. It is also occasionally attacked in the course of pyæmia, but is rarely affected in acute infective osteomyelitis.

(ii) In *compound fractures of the olecranon* acute suppuration often occurs, owing to the direct nature of the injury and the certainty of infection of the joint, and will necessitate arthrotomy and drainage.

Operation. As a rule the joint can be drained effectually through vertical incisions in the posterior part of the capsule on either side of the olecranon. That on the inner side must carefully avoid the ulnar nerve; that on the outer side should be just behind the external intermuscular septum and extend downwards far enough to open the radio-humeral joint. As a rule this will give sufficient drainage, but if necessary the soft parts may be raised from the front of the internal condyle and the capsule exposed and the joint opened from the front also.

The limb should be put up on a light sterilizable metal splint with the elbow at right angles, and it will be well to practise continuous irrigation of the joint with normal saline solution circulating through the drainage tubes. Should this be impracticable the joint should be immersed in a large arm-bath containing normal saline solution or boric lotion frequently renewed.

If this fail to drain the joint satisfactorily, a vertical incision should be made down to the bone as for excision (see p. 570). The triceps tendon is split centrally as in that operation, and the olecranon process is chiselled across at its base and removed, the wound being left open widely, so as to secure efficient drainage. The limb is placed in an elbow-bath.

OPERATIONS FOR INTRA-ARTICULAR FRACTURES

Operations for fractures involving the articular surfaces of the lower end of the humerus almost invariably require operative interference if

the functional result is to be satisfactory. Owing to the complicated nature of the articular surfaces the least irregularity will give rise to limitation of movement.

Operation. The exact incision will be determined mainly by the nature and extent of the fracture, which in its turn can only be satisfactorily ascertained beforehand by means of stereoscopic radiograms. The best method of access will generally be by vertical incisions along the supra-condylar ridges reaching well down the condyles, so as to expose the lateral aspects of the lower end of the humerus. In the majority of cases it will probably be necessary to make an incision on each side. The soft parts are carefully peeled off the capsule front and back, so that the joint can be opened, the fracture examined, and the fractured surfaces got accurately into apposition and held there whilst the lower end of the bone is drilled from side to side by a long fine electrically-driven drill; fixation pins are then made to transfix the fragments from side to side. The exposure of the lower end of the humerus may have to be very free, especially in the case of a T-shaped fracture into the joint. In all these cases the soft parts should be peeled off the capsule first and the latter then incised freely; at the end of the operation the incisions in the capsule are sutured. In fractures involving the articular ends of the bone it is almost always necessary to pass the fixation pins from side to side, as nothing can be applied to the articular surfaces for fear of causing a projection upon them that would interfere with movement. When there is a T-shaped fracture, however, it will be necessary to fix the reconstructed articular end to the shaft after pinning the condyles together in this fashion, and this may be done by the application of plates, wires, tacks, or any other fixation method that the surgeon may deem most advisable (see p. 538). After fixation has been accomplished, the joint is kept steady in the position in which it is to be put up, which will generally be at right angles, and the wound is then sutured and a splint applied that takes a firm grip of the limb, but is hinged at the elbow to allow of flexion and extension. A metal excision splint is a useful form, as it allows flexion and extension of the elbow and pronation and supination of the forearm to be practised.

After-treatment. The chief difficulty in the after-treatment is to promote union between the fragments whilst avoiding stiffness in the joint; with this end in view the most careful attention must be paid to the after-treatment. Pronation and supination should be practised from the first, but the limb should remain undisturbed on the splint for about ten days, when the sutures may be taken out. From this time onwards careful passive movements of the elbow-joint must be practised. This should be done at first while the limb is on the splint, the region of

the fracture being steadied with one hand whilst the other grasps the forearm and flexes and extends the elbow gently. In about three weeks' time the range of movement may be increased considerably, and in a month the patient should be practising movements for himself.

OPERATIONS FOR FRACTURE OF THE OLECRANON

Indications. Operative interference is not so essential for fractures of the olecranon as it is for those of the patella, because the results of non-operative treatment in the former cases are not entirely unsatisfactory. All healthy persons under forty years of age who are the subject of the fracture of the olecranon accompanied by marked separation of the fragments, however, should have the fragments fixed by operation. For those to whom the strength of the limb is important, operation is necessary. In many cases, however, admirable mobility and even a fair amount of power follow non-operative treatment.

Operation. In all its essential details this resembles that for fracture of the patella (see p. 613). There are a few points, however, in which the two operations differ.

The incision should be crescentic or horseshoe-shaped, with its convexity upwards and its upper limit just above the point of the olecranon. Its lower extremities should be about half an inch below the line of fracture. The flap thus marked out is turned down and the olecranon bursa and the fracture are exposed. All clot is turned out and the joint is cleared of blood by irrigation with saline solution. Apposition is quite easy and it is unnecessary to pass the wire, or whatever uniting medium is employed, through the articular surfaces. The bone is drilled from its posterior subcutaneous surface to the middle of the fractured surface, care being taken to see that the point at which the drill emerges on the fractured surfaces corresponds on the two sides. This can be ensured by bringing the fractured surfaces into apposition when the drill is protruding through the first hole and making its point mark a depression in the opposite fractured surface. A silver wire (No. 4 French catheter gauge) is introduced through the drill holes and twisted as for fractured patella. It brings the fragments together accurately without any part of it being within the joint cavity.

Wire is probably much the best material for fastening these fractures. It should be of the gauge recommended above, and it is well to cut a shallow groove or recess in the subcutaneous surface of the olecranon, in which the twist can be embedded so as to be quite out of the way of pressure of any kind. If this simple precaution be taken there will be no necessity

to remove it on account of irritation. Screws and nails introduced through the upper surface of the olecranon parallel with its long axis and driven into the shaft of the ulna have been much advocated and employed. I have used them more than once and have been disappointed with them, although the result on the operating table was excellent. The softening of the bone that a foreign body like a screw sets up almost immediately weakens it as a uniting medium, and it is not uncommon to find a certain amount of separation occur in a few days' time and to see the screw pushed out from the bone.

After-treatment. The limb should be put up almost fully extended on an internal splint with a hinge at the elbow. Flexion should be increased gradually during the first fortnight, when the stitches may be taken out, and gentle massage and passive movements employed. At the end of three weeks the patient should be encouraged to move the limb freely for himself, and in a month from the operation the functions of the limb should be completely restored.

Operations for fractures of long standing. These operations are very rare indeed nowadays and do not call for any extended notice, as they follow exactly the lines for similar operations upon fractures of the patella (see p. 622). If necessary for coaptation the triceps tendon, which is fairly thick, can be lengthened (see p. 472).

OPERATIONS FOR DISLOCATIONS

Indications. Operation may be required for a dislocation of the elbow-joint which has passed unrecognized owing to excessive effusion in the neighbourhood of the injury, which has been deemed to be due to a fracture. Unless a radiogram be obtainable the existence of a dislocation may not be ascertained for a long time, when it may be impossible to reduce the dislocation after a careful trial under full anæsthesia. As a rule reduction may be effected safely within six weeks from the date of the injury, and it should always be attempted up to that time. After that, however, the adhesions may become so dense that the force required to break them down may fracture the humerus or stretch the ulnar nerve unduly, giving rise to paralysis; for dislocations that have lasted longer than this operation is advisable without attempting reduction first.

Occasionally it may be necessary to operate upon dislocations of recent origin. This will probably be due to the fact that the coronoid process or some other portion of the articular surface has been fractured, and either causes recurrence of the dislocation or mechanically prevents reduction. These cases strictly come under the heading of operations for fractures involving articular surfaces and are dealt with in exactly

the same way, the dislocation being easily reduced before the fractured surfaces are fastened together.

In cases of unreduced dislocations of long standing, the operation will often take the form of an excision, as it may be impossible to get the dislocated surfaces into proper position. Reduction of the dislocation, however, should be possible, provided that sufficient exposure of the parts is obtained and that there is no fracture of the articular surfaces complicating reduction by altering the joint surfaces.

Operation. The best exposure of the joint is obtained by two vertical incisions, one over each condyle. The inner one should be about five inches long, the outer slightly less, as it must not extend lower down than the head of the radius for fear of damaging the radial nerve. By careful dissection the soft parts are raised from the front of the capsule, which is left intact, and a thin flexible spatula is passed beneath them from the inner to the outer incision so as to lift them out of the way. This gives perfect access to the front of the joint, and it may then be possible to effect reduction by traction, checking its effects by the fingers in the wound placed over the front of the joint. If this fail, the soft parts are peeled from the capsule behind as far as the margin of the olecranon, and the joint is opened on the inner side by dividing the remains of the internal lateral ligament. The finger can be then passed into the joint and the condition of affairs ascertained. Any tight structures should be divided, and traction should then bring the bones into position without any risk of doing damage either to the vessels or the ulnar nerve.

After reduction the joint is closed as accurately as possible and the elbow and forearm are supported in a large sling. Movement is practised early and vigorously. It will probably be necessary to move the limb frequently under anæsthesia.

EXCISION OF THE ELBOW

Indications. (i) The affection for which excision of the elbow is most frequently done is *tuberculous disease*; this is dealt with by Mr. Stiles, and the operation for it will not be described here.

(ii) *Injuries to the elbow* frequently require partial or complete excision of the joint. These are generally fractures involving the condyles, which have united with the fragments in a faulty position or with superabundant callus.

(iii) *Unreduced dislocations* may require excision of the joint, but as a rule this will not be called for unless they are complicated by a fracture of the articular surfaces, which prevents proper reduction of the dislocation (*vide supra*).

(iv) The most common non-tuberculous affection for which excision of the elbow is required is *ankylosis*. The results of excision of the elbow, both with regard to the range of movement obtained and the power that can be exerted, are so satisfactory that a patient may always be safely advised to undergo excision with the object of substituting a movable elbow for a stiff one, provided that he has reached the age when growth in the bones has ceased. Excisions prior to this age are apt to be disappointing, owing to the large amount of bone thrown out subsequently; this limits movement considerably, and may even reproduce the ankylosis.

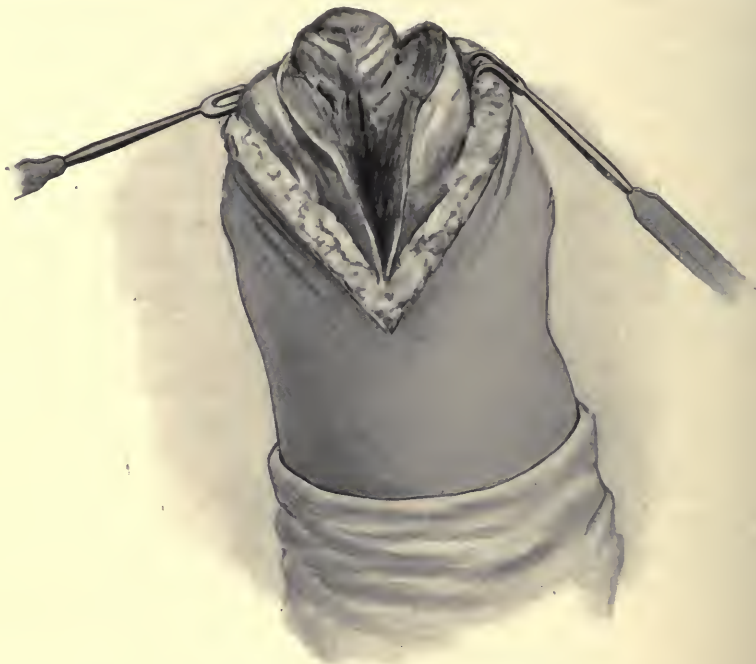

FIG. 260. REFLECTION OF THE SOFT PARTS IN EXCISION OF THE ELBOW. The triceps aponeurosis is being turned off the condyles.

(v) In *acute suppurative arthritis* the joint may have to be drained by a modified excision of the joint, namely, removal of the olecranon (see p. 565).

(vi) A *fracture of the head of the radius* may necessitate a partial excision of the joint; this will be limited to removal of the fractured portion of the bone.

(vii) *Unreduced dislocation of the radius* will necessitate a similar procedure.

Operation. Only one form of operation, that by the classical

vertical incision of Langenbeck, will be described here. This is, on the whole, the most suitable method for most of the conditions enumerated above; other methods, which are more suited for tuberculous disease, will be described by Mr. Stiles.

The assistant holds the limb so that the upper arm is vertical and the elbow is flexed at an angle of 135° , while the surgeon, standing on the affected side, makes an incision four inches long with its centre over the tip of the olecranon in the middle line of the limb. This incision should go down to bone throughout, the lower half reaching the subcutaneous

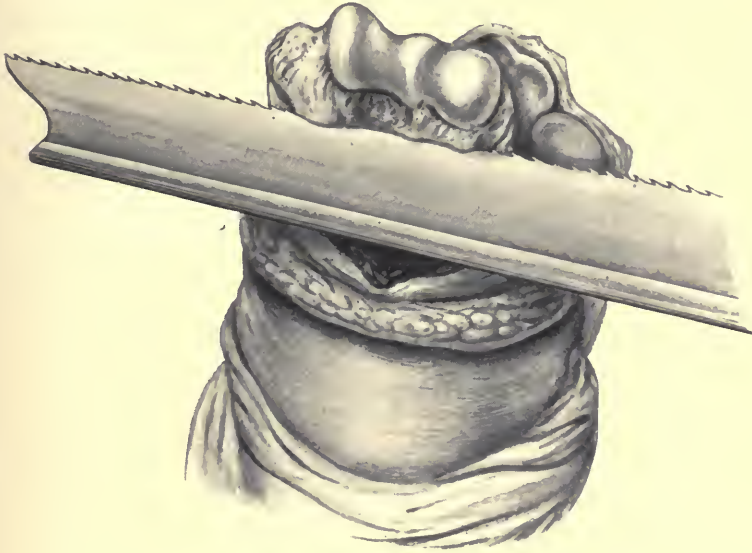

FIG. 261. SAWING THE HUMERUS IN EXCISION OF THE ELBOW. The saw is applied above the level of the condyles.

surfaces of the ulna and the olecranon, whilst the upper half opens the joint and enters the olecranon fossa of the humerus (see Fig. 260). The tendinous expansion of the triceps and anconeus is now turned off each side of the olecranon, partly with the point of a stout short-bladed knife kept closely in contact with the bone, and partly with a Farabeuf's rugine (see Fig. 246), which is excellent for this purpose. The beginner is apt to damage the soft parts unduly by scraping at them with the rugine to the entire exclusion of the use of the knife. The latter is a most useful instrument provided that the surgeon knows how and where to use it, and that he keeps command over it lest its point slip and cut across the expansion of the triceps, which would seriously interfere with the functional results of the operation. As the soft parts are turned off the

sides of the olecranon the posterior ligament of the joint is reached and opened, and while this is being done the assistant extends the limb somewhat, so as to relieve the tension on the soft parts. Each condyle is cleared in turn, and, when the soft parts have been turned sufficiently far forward to clear the front of the condyle, the joint is fully flexed, so that the bones project through the incision. The lateral ligaments are now divided and this allows the bones to come apart. By flexing the elbow acutely the lower end of the humerus is made to project freely from the wound, and, after clearing its lower end from the soft

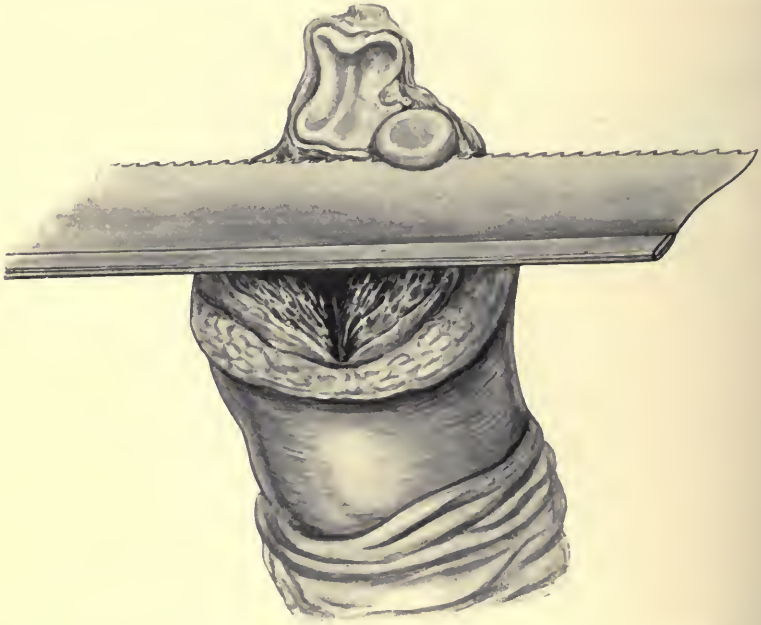


FIG. 262. SAWING THE RADIUS AND ULNA IN EXCISION OF THE ELBOW. The saw is applied above the level of the orbicular ligament.

parts by a few touches of the knife, the saw is applied just above the level of the condyles (see Fig. 261) and the whole of the articular surface is removed.

The articular ends of the bones of the forearm are next removed. They are cleared by a few touches with the point of the knife and are made to protrude prominently from the soft parts by the assistant, who thrusts them up by grasping the wrist. The saw is applied just at the commencement of the head of the radius, so as to preserve the slightly expanded portion of the neck which retains the bone in the orbicular ligament (see Fig. 262). This structure should be carefully preserved from

injury during the operation ; should it have been divided, it should be sutured before the wound is closed. Retention of the movements of pronation and supination largely depends upon the integrity of the orbicular ligament and the retention of the neck of the radius in its grasp. All bleeding points are secured, and, if any sharp projecting points have been left on the humerus, these are removed with a gouge or cutting-pliers.

The result of the removal of bone is the production of a gap of two inches or more between the ends of the bones. This may appear a formidable amount to the inexperienced operator, but, as a matter of fact, the mistake made is nearly always that too little is removed, and the result is more likely to be a stiff elbow afterwards than a flail one. The vertical incision through the triceps is brought together by a few fine catgut sutures and a drainage tube is inserted into the joint. The limb is put up in the almost fully extended position, with the forearm midway between pronation and supination, upon an internal splint furnished with an adjustable hinge at the joint. It is also well to provide a hand-piece, which is capable of rotation.

After-treatment. The arm is raised upon a pillow, slightly away from the side. The drainage tube should be removed in forty-eight hours, and after that the dressing need not be disturbed until the stitches have to be removed, which will be in about fourteen days. The movements of pronation and supination should be practised passively from the day after the operation, and flexion and extension may be begun after the first dressing, viz. about the third day. The range of the movements must be increased regularly, and after the removal of the stitches the patient should be encouraged to move the arm as fully and as frequently as possible.

Results. The results of this operation are in all respects excellent, provided it be done after the age at which growth ceases. Before that time the vigour of the reparative process is very great, and large amounts of bone are thrown out both in the region of the triceps tendon and the lower end of the humerus, and defective movement is frequently the result. In a typically good case there is perfectly good movement, and the only drawback is some loss of power when forcible movements, especially extension of the forearm, are attempted.

ARTHRODESIS

The earlier steps of the method of excision described above are eminently suited for the operation of arthrodesis. The access to the joint is excellent and the triceps, being paralysed, offers no difficulty in peeling

the soft structures off the condyles. When the lateral ligaments have been divided and the end of the humerus protruded through the wound (see p. 572) the cartilage should be removed from the ulna, except that of the radio-ulnar joint and the corresponding amount from the lower end of the humerus; this is best done with a gouge. The cartilage in contact with the head of the radius should be left intact and none should be removed from the head of the radius. The limb is then fixed at right angles in a plaster of Paris casing.

CHAPTER IV

OPERATIONS UPON THE SHOULDER-JOINT

ARTHROTOMY AND DRAINAGE

Indications. The shoulder is not a frequent seat of suppurative arthritis, either pyæmic or secondary to acute infective osteomyelitis of the humerus or scapula; it may, however, have to be drained for either of these conditions.

Operation. The joint is difficult to drain from the front, owing to the obliquity of the insertion of the capsule, which extends much further down on the inner than the outer side. It will be necessary, therefore, to make a counter-opening at the most dependent spot in all cases. This will be on the axillary aspect of the joint, and care will be needed to avoid damage to the important structures in that region.

The first step is to open the front of the joint, and here there will be some difficulty, owing to the necessity of avoiding injury to the tendon of the biceps, which would cause serious disability subsequently. The only safe plan is to dissect down upon the front of the joint with care and deliberation, exposing the parts fully and ascertaining the whereabouts of the structures to be avoided. An almost vertical incision downwards for about two inches from just in front of the acromion process will give good access. The deltoid fibres are separated and the muscles inserted into the outer tuberosity are exposed. By incising them vertically downwards in the line of the skin incision the joint will be opened well outside the biceps tendon, which will lie in its groove undisturbed. Its position can be felt by the finger in the wound, and if necessary it can be drawn out of harm's way by rotating the limb firmly inwards. A drainage tube is inserted into the joint beneath the acromion.

A second incision for through-and-through drainage will be required, and this must be made at the most dependent spot in the axilla. It is not easy to hit off this spot exactly as the conformation of the joint makes it difficult to pass forceps across from the previous incision. Perhaps the best plan is to raise the arm above the head so as to render the head of the humerus as prominent in the axilla as possible, and then to cut down upon this by an incision about two inches long just below the axillary vessels. These are identified and pulled upwards so as to expose the capsule below and behind. The head of the bone can be

made out by the finger in the axilla. The capsule may be opened by cutting down directly upon the head of the bone; this may be facilitated by bringing the arm down, and passing a long pair of dressing forceps across the joint from the upper incision and making their points protrude beneath the capsule so that they can be cut down upon and made to seize the drainage tube and pull it into position.

OPERATIONS FOR FRACTURES INVOLVING THE SHOULDER-JOINT

Indications. Owing to the small portion of the bone contained within the capsule of the joint and to the fact that the commonest form of fracture, viz. that through the surgical neck, is outside the joint, arthrotomy is not often called for in connexion with fractures of the upper end of the humerus. Moreover the articular surfaces are in such loose apposition that slight irregularities do not materially impair the movements of the joints. However, fractures such as those of the anatomical neck, as well as those of the great trochanter, will generally require operative treatment in order to secure the best possible result. These cases are now recognized more quickly and more certainly than they were formerly, owing to the great assistance afforded by stereoscopic radiograms. By means of them it will generally be possible to tell not only the cases that should be operated upon, but also the most suitable position for the arthrotomy incision.

Operation. Into the steps of the operation it is unnecessary to go in detail. It will consist of two parts—arthrotomy, followed by removal of the detached portion of the bone or fixation of it in place by some of the mechanical methods already described (see p. 538). The incision for exposure of the joint will vary according to the precise affection for which the operation is done. For a fracture of the anatomical neck the incision advised for use in the reduction of dislocations (see p. 578) is perhaps the most useful, while for fractures involving the greater tuberosity the one beneath the acromion (see p. 573) will lead down to the seat of injury more directly. The treatment of the fracture after the joint has been opened will be determined by the conditions present. If the head of the bone be separated it is as well to remove it entirely, gouging and smoothing off the fractured surface left, so that movement may be unimpeded afterwards. The question of some form of arthroplasty (see p. 557) will have to be considered in this connexion. For any other form of fracture mechanical fixation will probably be required and the most appropriate method should be adopted (see p. 538). The joint should be closed without a drainage tube.

After-treatment. The chief point is to promote early movement. The arm should be carried in a sling only, and passive movement should be practised from the first few days and pushed vigorously.

OPERATIONS FOR DISLOCATIONS OF THE SHOULDER

It may become necessary to have recourse to operative measures for the reduction of a dislocation at various periods after the receipt of the injury. It is usual to divide the operations into two classes, viz. those done while the dislocation is recent, and those for dislocations of long standing. This is, however, not a good plan, as the distinction between recent dislocations and those of long standing is rapidly disappearing with the advance of aseptic surgery, and the conviction is growing that no dislocation should be allowed to reach the stage in which it may be said to be an unreduced dislocation of long standing. Radiograms will clear up doubts as to the nature of the condition and the remedy for it is becoming more widely agreed upon; it is, that the joint should be opened and an attempt made to replace the head of the bone as soon as a fair trial of reduction by manipulation under an anæsthetic has been made and has failed. Operation will be required for :

Indications. (i) All cases of dislocation complicated by fracture of the upper end of the humerus. These cases should be operated upon directly they come under notice. The prospects of obtaining a good result are directly proportionate to the celerity and thoroughness with which operative restoration is performed. The procedure will be re-position of the head, suture of the capsule, and mechanical fixation of the fragments.

(ii) All cases of dislocation complicated by fracture of the glenoid cavity. This accident has only received just recognition since radiographic examination has become the rule. It is likely to lead to a crippled joint unless early operation be practised for the removal of detached bone and suture of the torn structures.

(iii) Any dislocation that cannot be reduced after two or three careful attempts at reduction under full anæsthesia. These, of course, will be recent cases. Operation should be practised within the first week, preferably within the first three days.

(iv) Any unreduced dislocation that has lasted for less than six weeks after a careful attempt at reduction under anæsthesia has failed. The attempt should be by manipulation only, and operation should be carried out forthwith if it fails; this avoids further adhesions which would make an operation carried out at a later period more difficult.

(v) All cases of dislocation that have lasted longer than six weeks

without any previous attempt at reduction, provided that the patient's age, health, and degree of disability render an operation advisable. In this connexion it is well to remember that some patients have excellent, though limited, use of the arm in spite of the unreduced dislocation, and that operation will not always improve upon this. In old and fat people the restoration of function is often very defective, especially when the head of the bone cannot be replaced and the joint has to be excised.

Operation in recent cases. In recent cases very little difficulty may be met with, except when there is an extensive fracture complicating the dislocation. A very good incision is that suggested by Mr. Keetley (*Lancet*, 1904, vol. i, p. 211), following Tiling and Paulet, along the anterior margin of the deltoid, just external to the cephalic vein, from the clavicle nearly to its insertion. The anterior fibres of the deltoid are separated along the line of the incision, and a transverse cut is made from its inner edge for about two or three inches through the deltoid half an inch below the clavicle and acromion. This latter part of the incision is not always necessary in recent cases, but it is very useful, as by employing it the whole area concerned in the dislocation can be exposed quite satisfactorily and without causing any risk to the nerve-supply of the deltoid, which it is very important to preserve intact.

When this incision has been well retracted, the dislocated head of the bone will be seen, and, if the case be one of simple dislocation unaccompanied by fracture (as a radiogram will demonstrate), the arm should be manipulated for reduction by an assistant while the surgeon ascertains and overcomes any obstacle to reduction, such as the tendon of the subscapularis, by pulling it aside. When reduction has been accomplished, the rent in the capsule is sewn up if it can be reached, the deltoid, if cut, is sutured (see p. 469), and the wound is closed without a drainage tube. The arm is bound lightly to the side and the elbow supported in a large sling. Passive movements, while the arm is supported by the sling, are practised from the first. After the sutures have been removed, the elbow is supported in a sling for another week, but overhead movements should not be allowed for a month after operation for fear of recurrence of the dislocation. Abduction can be restricted by fixing a strap round the thorax and another round the arm, and connecting them with a light chain of suitable length.

When a fracture complicates dislocation it will be necessary to remove any loose fragments of bone from the joint cavity if the fracture involve the glenoid cavity, after which the treatment is as above, care being taken to smooth down any rough surface of bone left. When the fracture is in the upper end of the humerus, the dislocation is first reduced and the rent in the capsule sutured, after which the fragments are fixed

by mechanical means (see p. 538). Some difficulty may be experienced in handling the upper fragment when reducing the dislocation if the fracture be high up, since it is difficult to get a hold upon it. This may necessitate the use of special forceps (see Fig. 248); in one case I was successful after transfixing the head of the bone with a drill which served as a handle to manipulate the bone with. After successful reduction and fixation, the limb is put up as for fracture of the neck of the humerus, the wrist being supported by a sling and the shoulder-joint fixed by a moulded cap of poroplastic material or gutta-percha, the elbow being allowed to hang unsupported.

In the *after-treatment* the condition of the shoulder-joint must not be overlooked, and it will be necessary to guard against stiffness by practising free passive movement from an early date, steadying the seat of fracture carefully meanwhile. It is very difficult to obtain a perfectly satisfactory result in these cases; much depends upon the thoroughness with which the passive movements are carried out.

Operations for unreduced dislocation. When the dislocation has remained unreduced for a long time the operations for its cure are really two in number, viz. re-position of the head of the humerus in the glenoid cavity or excision of the joint. As it is impossible to tell beforehand which of these methods is likely to be successful, and as in practice the surgeon always attempts to replace the head of the bone before he convinces himself that it will be necessary to excise it, these two operations will be described as portions of one procedure.

The purification of the soft parts in these operations, as in the corresponding ones upon the hip, must be both thorough and extensive. The entire pectoral, scapular, and axillary region must be shaved and cleansed and the upper limb must be secured in sterilized towels, for the manipulations are likely to be severe and prolonged, and the hands have to be carried well under the back in order to fix the scapula.

For exposure of the operation area no incision is better than that advised by Keetley (*loc. supra cit.*). The anterior fibres of the deltoid are split and the posterior fibres are divided by a horizontal incision outwards below the clavicle, enabling the muscle to be pulled backwards from the upper end of the bone, thus exposing the displaced head lying beneath the coracoid process, where it will have contracted dense adhesions and have formed a false joint. Before there will be any chance of getting the head into the glenoid cavity, the muscles passing from the scapula to the humerus, which are all shortened, must be separated. The best way to do this is, as Keetley advises, to chisel off the greater tuberosity with the muscles attached to it and to divide the coracoid process with the coraco-brachialis arising from it. The

tendon of the biceps may be divided by a very oblique section if necessary, and the lesser tuberosity with the insertion of the subscapularis may also be detached if its tendon cannot be hooked out of the way. The soft structures forming the new false capsule must be opened up freely and the head and neck of the bone separated from the adjacent soft parts. This is the most difficult stage of the operation, since the axillary vessels and nerves may be closely adherent to the inner surface of the neck. By keeping very close to the bone and using Farabeuf's sharp rugines (see Fig. 246), this danger will be got over. Finally the glenoid cavity is examined, and if it be filled up by the remains of the capsule, which has fallen over and become adherent to its anterior surface, as will probably be the case, it must be removed with knife and scissors before the head is put in place.

Nothing now remains to be done but to attempt to replace the head of the bone in the glenoid cavity. How this is to be done each operator must determine for himself. It should be by manipulation methods if possible, after dividing any structures that oppose reduction and can be divided with impunity. Pulleys were frequently used and are still advocated, but it seems more reasonable to submit cases obstinate enough to demand such extreme force, to some form of excision. Powerful bone forceps, retractors, and levers may be required to lift the head of the bone on to the glenoid surface. When it is there, manipulations will complete the reduction. If the head of the bone should have undergone distortion from traumatic arthritis, as it may have done in cases of very long standing, it will be necessary to pare it away and leave it very smooth and of proper shape. Redundant capsule must be cut away, but any that is likely to come in useful in the formation of a new capsule should be retained.

If the attempts at reduction are successful, the next step is to restore the various muscular insertions that have been divided. The tuberosities are fastened in place with tacks, the coracoid process is wired on, and the biceps tendon sutured if it has been divided. The deltoid fibres are sutured (see p. 469) and any remnants of capsule are brought together to form a new capsule for the joint. The wound is closed without a drainage tube, and the *after-treatment* is similar to that for recent cases (see p. 579) except that the convalescence will be longer.

If these attempts at reduction fail, however, there is no alternative but to excise the joint (*vide infra*). In several reported cases the wound has been closed after it was found that reduction could not be effected, but this only serves to make the patient's condition worse than it was before, and excision is probably preferable.

After the head of the bone has been sawn (see p. 585) the raw surface

is rounded off and made as smooth as possible, and it will be well to practise arthroplasty (see p. 557) by bringing in a flap of soft parts over the cut surface so as to encourage movement subsequently. The detached muscular attachments are fastened in place once more (*vide supra*) and divided tendons and muscles sutured. The *after-treatment* is similar to that of excision generally (see p. 585), except that passive movement must be begun earlier and persevered in more energetically, under full

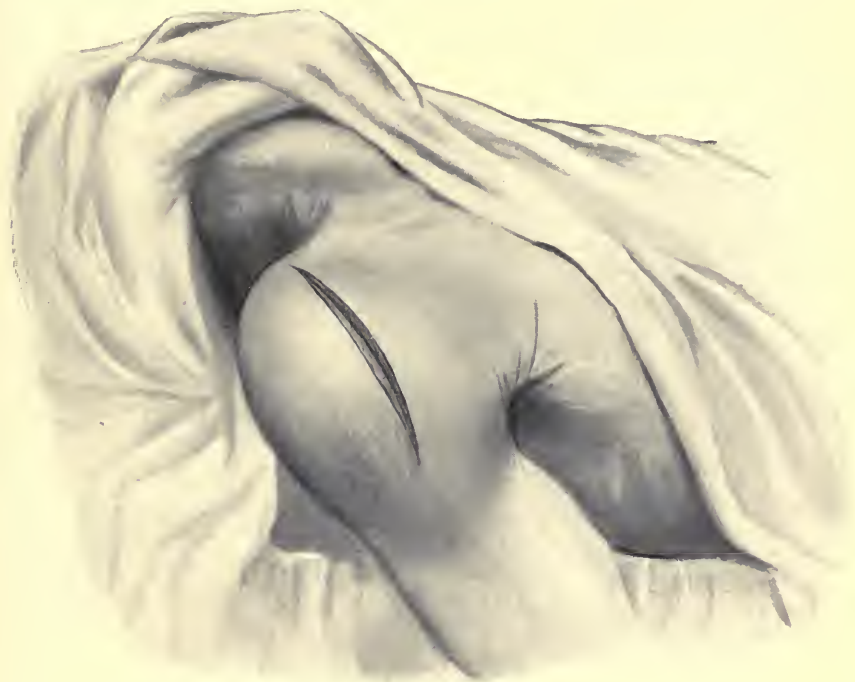

FIG. 263. INCISION FOR EXCISION OF THE SHOULDER-JOINT. This is the anterior incision described in the text. The limb is in the position in which it should be held when the incision is made.

anæsthesia, if necessary, on account of the readiness with which adhesions form in the disorganized joint.

EXCISION OF THE SHOULDER

Indications. (i) *Tuberculous disease* of the joint is the affection for which this operation is most frequently performed. This does not come within the scope of the present article, however.

(ii) *Compound fractures* of the upper end of the humerus may occasionally be best treated by excision in order to preserve the movements of the joint.

(iii) *Unreduced dislocations* of long standing that resist all attempts to get the head of the bone into the glenoid cavity may be treated by excision and a wider range of movement thereby assured.

(iv) *Ankylosis* of the shoulder in a young subject is often a fit subject for excision with the object of obtaining a range of movement that is unobtainable without it. The operation should not be undertaken for this purpose, however, without a careful selection of cases,

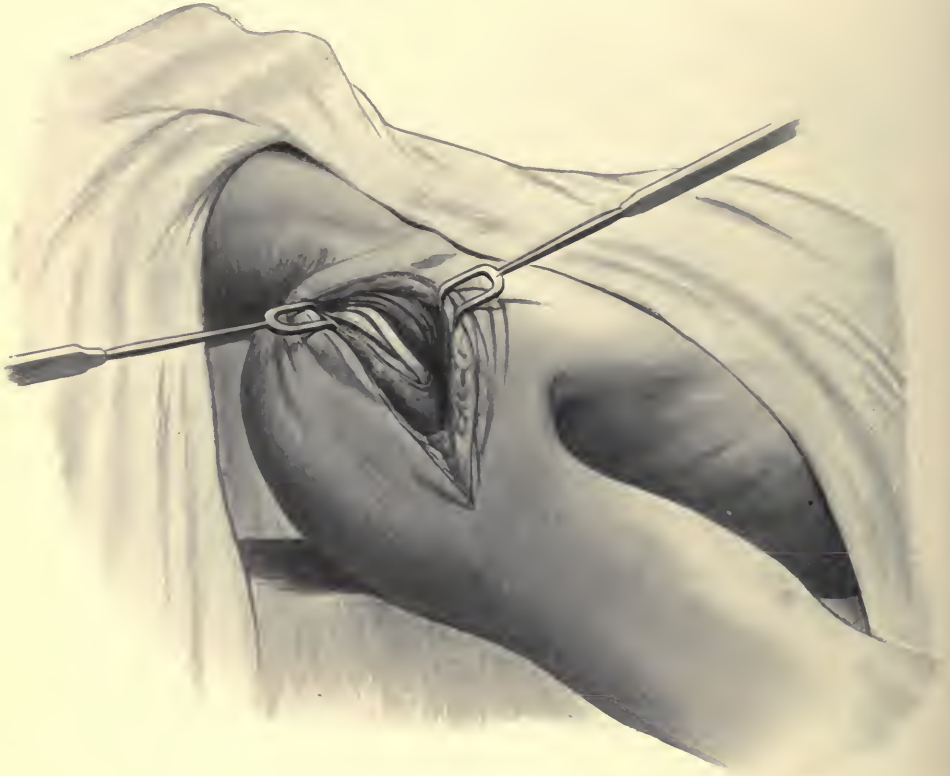


FIG. 264. PRESERVATION OF THE BICEPS TENDON IN EXCISION OF THE SHOULDER-JOINT. The tendon has been lifted out of its groove.

as the functional results are not nearly so good in elderly subjects as in younger people.

Operation. (a) **For injury.** An incision five inches long (see Fig. 263) is begun upon the clavicle above the coracoid process, and carried downwards and outwards along the anterior border of the deltoid, which is separated from the clavicular portion of the pectoralis major by the cephalic vein. The latter is drawn to the inner side along with the

pectoralis major, while the deltoid is drawn outwards. The front portion of the deltoid will probably have to be detached from the clavicle, and some of the branches of the acromio-thoracic artery ligatured.

When these muscles have been retracted, the outer surface of the capsule of the joint is exposed ; in the lower part of the wound the

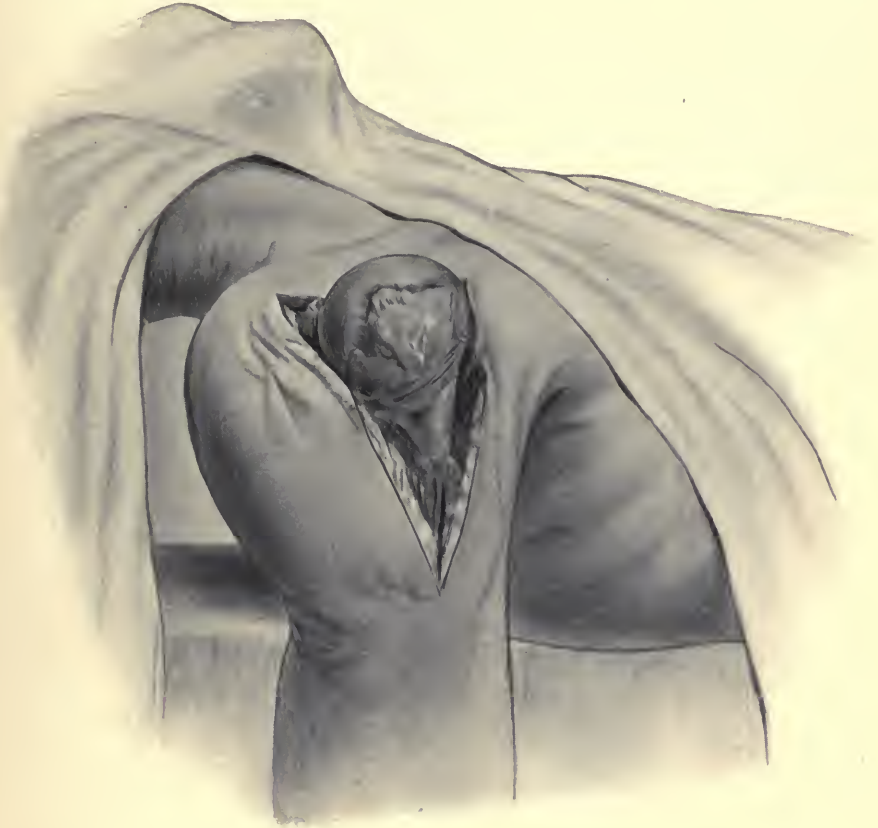

FIG. 265. DISARTICULATION OF THE HEAD OF THE HUMERUS IN EXCISION OF THE SHOULDER-JOINT. The arm is vertical and the head of the bone can be pushed well up out of the wound.

tendon of insertion of the pectoralis major is seen. The arm is rotated inwards and the sheath of the biceps tendon is opened along the outer lip of the bicipital groove. The sheath is slit up to the edge of the glenoid cavity, and the biceps tendon is freed and drawn inwards (see Fig. 264). The tendon must be carefully preserved throughout the operation. The incision into the sheath of the biceps tendon opens

the capsule of the joint, and the next step is to separate the attachment of the tendons inserted into the upper end of the humerus, viz. the subscapularis into the lesser tuberosity, the supraspinatus, infraspinatus, and the teres minor into the greater tuberosity. This is done by means of vertical cuts close to the bone made parallel to the bicipital groove,

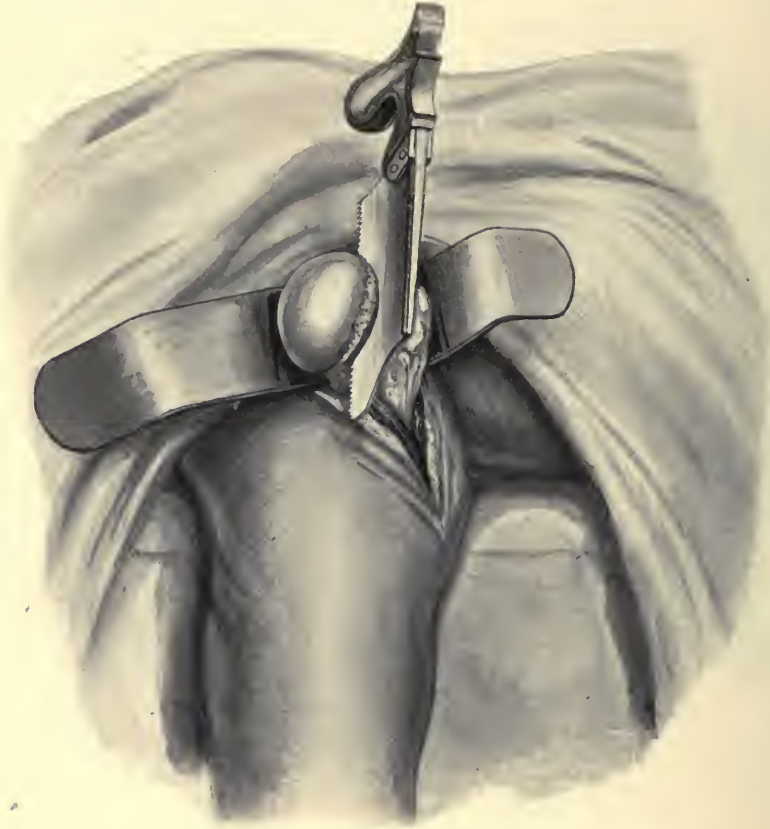


FIG. 266. SAWING THE HEAD OF THE HUMERUS IN EXCISION OF THE SHOULDER-JOINT. The soft parts are protected by a spatula.

the humerus being meanwhile rotated first outwards and then inwards; No transverse cuts should be made in the capsule, as it is essential for a good result that it should be detached undamaged. While this is being done, the assistant holds the arm nearly horizontal and at right angles to the trunk. When the humerus must be exposed farther downwards, the anterior and posterior circumflex arteries and the circumflex nerve, which surround the surgical neck, must be borne in

mind, and the former if necessary ligatured. The nerve must on no account be injured.

The head of the bone can now be made to project from the capsule and should be pushed up out of the wound by the assistant (see Fig. 265). In determining how much bone to remove in these cases the surgeon is guided by the desire to get free movement, since there is no disease requiring to be removed. A free removal of bone may be practised if care be taken to preserve those portions of the tuberosities into which the rotators of the bone are inserted. The saw is applied parallel to and just outside the line of the anatomical neck (see Fig. 266). Whatever the amount of bone removed, the line of section should be obliquely from without downwards and inwards, so as to avoid any projecting edge against the axillary vessels or nerves. When the section is complete it is well to go over the whole of the inner aspect of the cut surface and pare this down with a gouge or a burr, so that it is as smooth as possible and presents no prominences that will interfere with movement. It is also an excellent plan to fashion a flap from the soft structures around and fasten it over the raw bone surface in order to promote movement subsequently (see p. 557). Foreign substances, such as thin sheet rubber or gold foil, have been used with a similar object.

The remaining steps of the operation are concerned with the closure of the wound. Before this is done the insertions of the supraspinatus, infraspinatus, and teres minor are sutured to the greater tuberosity and the tendon of the subscapularis to the lesser with stout catgut. The biceps tendon is replaced in its groove and its sheath is sutured over it. A drainage tube should be inserted into the joint cavity, as a large 'dead' space is left in which blood would otherwise collect. A small pad is placed in the axilla to prevent the head of the humerus being drawn inwards, and the elbow and forearm are supported in a sling. The arm is fastened lightly to the side.

Passive movements are begun from the first and the patient is encouraged to swing his arm about in the sling as much as he can. The support should be removed from the elbow about the third or fourth day, the sling only taking in the wrist.

(b) **For unreduced dislocation.** This has been already referred to separately in connexion with the operations for unreduced dislocations (see p. 580).

(c) **For ankylosis.** There is often considerable difficulty in these cases owing to the want of proper exposure of the parts. The anterior oblique incision described above does not give enough room for the very important soft structures on the inner aspect of the joint to be

properly protected while the head of the bone is being sawn or chiselled through *in situ*, as it has to be in cases of ankylosis. When the head of the bone can be protruded from the wound, as it can be in ordinary cases, there is no risk to the axillary structures, but when division has to be effected in ankylosed cases the saw or chisel may easily do very serious damage. Even when a Gigli's saw is employed and is introduced by pulling it round the bone with the aid of a suitably curved director insinuated between the soft parts and the inner aspect of the joint the procedure is difficult, as it may be hard to protrude the humerus from the wound after simple division of the ankylosis. Therefore an operation that will give the fullest exposure of the joint with the least damage to the functional powers of the muscles subsequently is greatly to be desired.

Kocher's posterior resection. On the whole these conditions are better fulfilled by the posterior method introduced by Kocher. The following is his description of the operation (*Textbook of Operative Surgery*, translated by Stiles, 1903, p. 376):—

‘The skin incision is carried from the acromio-clavicular joint over the top of the shoulder and along the upper border of the acromion to the outer part of the spine of the scapula (root of the acromion), and from thence downwards in a curved direction towards the posterior fold of the axilla, ending two fingers' breadth above it. The upper limb of the incision passes through the superior ligament right into the acromio-clavicular joint (the strong fibres of which are divided), and in the rest of its course divides the insertion of the trapezius along the upper border of the spine of the scapula. The descending limb of the incision divides the dense fascia at the posterior border of the deltoid, and exposes the fibres of the latter. The thumb is now introduced beneath the smooth under surface of the deltoid so as to separate it from the deeper muscles (with which it is connected merely by loose cellular tissue) up to its origin from the acromion, and its posterior fibres are divided. The finger is now carried along the upper border of the infraspinatus muscle so as to free it opposite the outer border of the spine and the root of the acromion.

‘In a similar manner the supraspinatus is detached with a blunt dissector from the upper border of the spine of the scapula, in order that the finger may be passed from above underneath the root of the acromion. The root of the acromion, which is now freed, is chiselled through obliquely, and, along with the deltoid, is forcibly pushed forwards with the thumbs over the head of the humerus.

‘In chiselling through the bone care must be taken not to injure the suprascapular nerve which passes under the muscles from the supraspinous into the infraspinous fossa; the nerve is also protected by

the transverse ligament of the scapula. It is desirable before chiselling the bone to bore the holes required for the subsequent suture.

‘Instead of dividing the root of the acromion, the formation of the posterior flap may be simplified by merely detaching the scapular origin of the deltoid subcortically: this allows of very firm union subsequently.

‘After reflecting the acromio-deltoid flap, the head of the bone is readily accessible in its upper, outer, and posterior aspects, covered by the tendons of the external rotators, viz. the supraspinatus, infraspinatus, and teres minor muscles. The posterior surfaces of these muscles are also exposed. An incision is now made over the head of the bone, and in order to avoid unnecessary injury this must be done accurately. The arm being rotated outwards, a longitudinal incision is carried down to the bone in the coronal plane. Commencing at the upper part of the posterior lip of the bicipital groove, it extends upwards through the capsule along the anterior edge of the insertions of the external rotator muscles and over the highest part of the head of the humerus, so as to expose the tendon of the biceps as far as its attachment to the upper edge of the glenoid cavity. The insertions of the external rotators are now separated from the greater tuberosity and drawn backwards. The biceps tendon is freed from its groove and drawn forwards, so that its sheath may be inspected.

‘In this way the entire head of the humerus and the glenoid fossa can be freely exposed, and if it is not necessary to do a complete excision, the anterior wall of the capsule and the insertions of the anterior muscles can be preserved. In other cases the insertion of the subscapularis into the lesser tuberosity is detached upwards and inwards.

‘The circumflex vessels and nerve which come out from under the teres minor can be preserved: indeed, if the operation be properly performed there need be no fear of injuring them.’

When the upper and back part of the joint has been freely exposed in this manner it becomes a much easier task to protect the soft parts on the anterior and inner aspects of the joint and to divide the bone. On the whole it is perhaps best to perform the section with a broad chisel which is sunk into the line of ankylosis, which can always be identified. A few gentle strokes with the hammer and a little manipulation of the arm by one assistant while another fixes the scapula will generally suffice to mobilize the head of the humerus. Fine spatulæ can then be slipped down behind the neck of the bone and the rest of the operation carried out as for an ordinary excision (see p. 585).

ARTHRODESIS

Indications. In the rare cases in which the muscles passing from the scapula to the humerus are paralysed, it will be a considerable help to the patient if his shoulder-joint can be fixed firmly enough to enable the scapulo-thoracic movements to be substituted for those of the shoulder. This can be done to some extent by arthrodesis, but it must be confessed that the results may be disappointing since the bone surfaces cannot always be kept closely enough in contact for firm bony union to occur, and this is required if the arm is to be useful. The leverage is so great that fibrous union soon stretches. Close approximation of the denuded articular surfaces is difficult to maintain, owing to the dependent position of the limb and the fact that the muscles maintaining apposition in the normal joint are paralysed here. Mechanical fixation (see p. 538) may be employed with advantage.

Operation. The first stages of the operation will be the same as for an excision (see p. 582). It is immaterial what incision is used for the purpose. The oblique anterior one recommended above is as good as any, but in this case a large deltoid flap may be raised, if desired, as this muscle will be paralysed by the affection for which the operation is done, and there is therefore no objection to injuring it, as there is in the ordinary excision operation.

When the head of the bone has been protruded from the wound (see Fig. 265), the cartilage is carefully removed from the whole of it with a chisel. Besides this it will be advisable to flatten the rounded surface of the head somewhat so as to ensure a broad surface of contact when it rests against the glenoid cavity; otherwise, it will only touch at one point. As these operations are generally done in growing children, it will be unsafe to use the saw for this purpose, as the epiphyseal line might be injured; more delicate and certain work can be done with the chisel.

The next point is to remove the cartilage from the glenoid cavity. This is rather difficult to get at, but removal must be thorough and methodical, and is best done with a gouge. An electrically-driven burr is an excellent instrument, and it has the further great advantage that a flat surface can be made of the glenoid cavity to fit accurately against the flattened head of the bone.

The two raw surfaces of bone are now placed in apposition, and I have found it best to fasten them together in order to prevent them falling asunder and to promote bony union, which is very essential. A simple and satisfactory plan is to transfix the head of the bone with

a steel pin driven in through the greater tuberosity and passing through the head of the humerus and the glenoid cavity well into the neck of the scapula. The end of the pin protrudes through the wound and can be enveloped in the dressings and removed when union has occurred. The humerus is held in apposition to the glenoid cavity by the assistant while the peg is being driven in, and care must be taken to see that it is somewhat inwardly rotated while this is being done, otherwise it will be difficult to bring the forearm to the chest afterwards.

EXCISION OF THE SCAPULA

Indications. (i) *For sarcoma of the bone.* This is practically the only condition that is likely to require complete excision of the scapula, although parts of the bone may be removed for other conditions.

(ii) *For necrosis of the scapula.* This results from acute infective osteomyelitis in young subjects and may require a partial excision of the bone ; it is, however, hardly ever likely to demand complete removal.

(iii) The scapula is removed together with the entire upper extremity in the *interscapulo-thoracic amputation* of Berger (see p. 151). This, however, is a special operation which is not really excision of the scapula.

Operation. Various incisions may be employed ; the one in most common use is a vertical incision along the vertebral border of the bone, from the superior to the inferior angle, joined by another along the whole length of the spine of the scapula as far as the tip of the acromion. This gives two triangular flaps which are dissected up and down. I personally prefer a somewhat Γ -shaped incision, the upper horizontal limb of which is longer than the lower and extends from the tip of the acromion to the superior angle of the scapula. The lower crosses the lower angle and is about four inches long. The mid-points of these two incisions are joined by an incision, which marks out two rectangular flaps which are dissected up inwards and outwards, and which expose the entire scapular area to view.

It is a great advantage to retain a portion of the acromion if this can be done with safety, but it is rarely advisable to do so since the bone is usually removed for a periosteal sarcoma. If a part of the acromion is to be left behind, it is divided at the desired spot with a saw or chisel, otherwise the incision extends right into the acromio-clavicular joint. When the operation is done for growth, the various muscles attached to the scapula must be removed as completely as possible ; when this is not the case, however, they may be cut long. This is only really important as far as the deltoid and the trapezius are concerned ; if they can be cut long they may be sutured together at the end of the operation with

great advantage to the patient. The scapular muscles are of course not needed after the scapula has been removed.

After the flaps have been well reflected, the first muscle to be divided is the deltoid, beneath the fibres of which the fingers can be thrust so that the muscle may be hooked up and divided at its origin from the acromial spine, or its scapular fibres can be separated from the clavicular ones, and removed entirely down to their insertion. The tendons inserted into the upper end of the humerus are now cut through in order, beginning with the subscapularis and going on to divide the tendon of the biceps, the supraspinatus, the infraspinatus and the teres minor. The insertion of the teres major will also have to be severed. The circumflex nerve must be preserved, if possible, but the dorsalis scapulæ artery and perhaps the posterior circumflex will be exposed and should be ligatured at this stage.

The fingers are now passed beneath the fibres of the trapezius, which is lifted from the acromion, and its insertion into the spine of the scapula divided throughout. Beneath the anterior fibres of the muscle the acromial branches of the acromio-thoracic artery must be secured. This renders the borders of the scapula freely visible and the muscles which attach the bone to the trunk are then divided in regular order. Beginning along the upper border from the neck of the bone, the omohyoid will be detached and the suprascapular artery ligatured at the same time; then the levator anguli scapulæ will be cut away from the upper angle of the bone and the posterior scapular artery will be ligatured. This only leaves the rhomboids and the serratus magnus connecting the bone with the trunk, and these are divided in turn, the posterior scapular giving no trouble as it has been already divided. This separates the bone entirely, with the exception of the structures attached to the coracoid process and the front portions of the capsule of the shoulder-joint; the latter is easily divided, the finger being hooked round the neck of the scapula, which is pulled up so that the capsule is rendered prominent and can be divided. The soft parts are then pushed carefully away from the front of the neck and the under aspect of the coracoid process. This is the really difficult part of the operation, as the first part of the axillary artery and vein lie in close connexion with this structure. If the surgeon be doubtful of his ability to clear it without damaging these vessels, the coracoid process may be cut across at its base with a pair of cutting-pliers, and then dissected out. With care it is, however, easy to push the structures away sufficiently to render evident the tendons of the coraco-brachialis and the pectoralis minor, which are detached from the bone, and the latter is then removed.

The flaps are brought together, a large drainage tube is placed at

the most dependent spot, and the dressings are firmly bandaged round the thorax so as to obliterate any space in which blood might collect.

Difficulties and dangers. If done as above described there will be little risk of bleeding, which is the chief danger in these operations. The great point is to secure perfect exposure of the parts, to divide the muscles *seriatim*, and to know where to look for the principal vessels.

Results. The results are excellent ; the patient retains all movements of the limb, with the exception that he is unable to abduct the arm above a right angle from the trunk.

CHAPTER V

OPERATIONS UPON THE ANKLE-JOINT: OPERATIONS UPON THE TARSAL BONES AND JOINTS

ARTHROTOMY AND DRAINAGE OF THE ANKLE-JOINT

THE ankle is a difficult joint to drain effectively, since it is divided into two parts by the astragalus, which projects up into the tibio-fibular arch and separates the posterior sac between the tendo Achillis and the astragalus (talus) almost completely from the anterior one between that bone and the extensor tendons.

Indications. Fortunately suppuration in the ankle-joint is rare and drainage is not often required.

(i) *Acute suppurative arthritis*, either of pyæmic origin or due to acute infective osteomyelitis of the os calcis or the bones of the leg, will require the freest possible drainage.

(ii) *Compound fractures into the ankle-joint*, particularly the variety known as Pott's, are not infrequently followed by acute suppuration, since from the nature of the injury the wound may be contaminated with dirt which escapes the cleansing processes.

Operation. There are two chief methods for arthrotomy and drainage. Of these the simpler plan is to make free incisions on each side of the joint front and back, and to pass tubes through from side to side; this should succeed unless the infection be very virulent or the case be seen too late.

Simple arthrotomy. An incision is made behind the external malleolus, avoiding the sheaths of the peronei tendons, and the posterior ligament, which will be distended with the pus in the joint, is exposed and opened. Through this opening dressing forceps are passed across the back of the joint and made to project behind the inner malleolus; here the points are cut down upon and a drainage tube is pulled through from side to side across the back of the joint. In making this incision the tendon sheaths behind the inner ankle and the posterior tibial vessels and nerve must be avoided. The best way to do this is to dissect down with a blunt instrument after the skin has been divided until the points of the dressing forceps are reached. Similar incisions are next made in the front of the joint and a drainage tube is drawn

across from side to side in that situation. The tendon sheaths should not be opened and the dorsalis pedis must be avoided. The drainage through these tubes can be supplemented by continuous irrigation if desired.

Excision of the astragalus. In bad cases, however, it will be necessary to lay all the recesses of the joint into one large cavity if drainage is to be effectual, and this can only be done by excising the astragalus (talus). This method of treatment has been strongly advocated by Bolton (*Ann. of Surg.*, 1906, vol. xlv, p. 959); it is of course a drastic one since the utility of the foot must be permanently impaired by it, but it must not be forgotten that this will also probably be the case whenever there is suppuration in the ankle, and it is an open question whether the functions of the joint after excision of the astragalus are not better performed than after drainage followed by ankylosis with the foot in the right-angled position. In any case operation is imperative unless the temperature drops and the general conditions undergo amelioration after simple drainage practised as recommended above; no time must be lost, and the astragalus should be removed (see p. 598) as an alternative to amputation of the leg.

The wound must be left widely open, and it will be well to make a counter-opening on the inner side and insert a large tube. The large cavity left by the removal of the astragalus may be mopped out with a saturated solution of chloride of zinc, so as to hinder septic absorption from the freshly cut surfaces, and then lightly packed with strips of gauze for the first three days, after which the large drainage tubes alone will suffice. The chief care must be to keep the foot from becoming displaced on the leg.

ARTHROTOMY FOR THE TREATMENT OF FRACTURES INTO THE ANKLE-JOINT

Indications. (i) *Recent Pott's fracture.* In certain cases operative interference is required for recent Pott's fractures. These will comprise all compound fractures, and those simple forms in which reduction under an anæsthetic cannot be effected satisfactorily.

(ii) *Dupuytren's fracture or fractures of the astragalus* are frequently followed by such severe disability as to render operative interference imperative. Now that stereoscopic radiograms can show the exact displacement of fractures in this situation, immediate operation will probably be resorted to in future for all these cases, while it is comparatively easy to rectify displacements or to remove detached portions of bone which might otherwise give rise to much trouble and possibly

interfere with a satisfactory result from operation subsequently. Hitherto operation has been largely confined to cases of long standing, accompanied by great disability.

Operations for compound Pott's fracture. The seat of fracture and the ankle-joint should be fully exposed after the parts have been purified. The method of purification resembles that for compound fractures, being essentially thorough purification of the skin, after shutting off the joint cavity from the surface by means of a gauze plug, with subsequent removal or disinfection of soiled surfaces in the deeper structures. The wound, which is practically always on the inner side of the ankle, should be enlarged for the purpose of disinfection and exploration, and this gives the opportunity of discovering and removing soiled tissues both in the soft parts and the bone, and also enables the dislocation accompanying the fracture to be properly reduced and the fractured internal malleolus fastened in its normal position by means of tacks or a metal plate (see p. 540). Should the bone not be fractured, but only the internal lateral ligament torn, this structure should be sutured accurately. Provision must be made for drainage in case the purification of the soft parts does not suffice to prevent infection, but no opening should be left over the region of the fracture in the tibia if this can be avoided; the skin wound should be sewn up completely and a counter-opening for drainage made at a more dependent spot. If skin has been cut away in this region the raw surface that would otherwise be left may be covered by sliding a flap from the skin of the leg above. Healing will probably be more rapid if the seat of fracture about the malleolus and the mechanical fixation apparatus are covered with healthy skin.

Operations for simple recent Pott's fracture. Operative interference will be required when the surgeon cannot effect complete reduction of the dislocation under an anæsthetic. These cases are comparatively rare; they are generally due to the interposition of some structure between the bone surfaces, such, for instance, as the tendon of the *tibialis posticus* (posterior) or a portion of bone, generally a fragment of the internal malleolus or of the astragalus. This not only prevents reduction but interferes materially with the subsequent usefulness of the foot.

The objects of the operation will not be limited to getting the astragalus into position; the fractured surfaces of the tibia should also be fastened together. A good incision is a curved one with its concavity forward, commencing just in front of the inner border of the tibia, about two inches above the joint level, curving around the tip of the internal malleolus, and extending as far forward as the tubercle of the scaphoid (navicular). The incision is deepened down to the bone, taking care

to avoid damage to the tendon of the tibialis posticus (posterior), and the joint is opened through the fracture at the base of the internal malleolus, or, if that does not exist, through the ruptured internal lateral ligament. The parts are fully retracted and the cause of the difficulty in reduction is ascertained. Should this be the tendon of the tibialis posticus (posterior), this is hooked out of the way with a retractor, and the astragalus pushed into place. If it be a loose piece of bone, this is removed, if small, and the surface from which it has been detached is smoothed off with a gouge or burr; if large, it is re-attached to the surface from which it was broken.

The final stage of the operation consists in fastening the internal malleolus back into place or suturing the rent in the internal lateral ligament, according to which lesion is present. The wound is closed without a drainage tube, and the foot is put up at right angles to the leg in plaster of Paris, in a slightly inverted position, so as to relax all the structures on the inner side of the foot. The sutures are removed at the end of ten days, and passive movement and massage are begun, if necessary, under an anæsthetic within the first few days.

Operations for simple Pott's fracture of long standing are required when there is considerable deformity and disability, as the patient is frequently crippled and unable to follow his employment. The outward dislocation associated with this deformity throws the weight of the body upon the inner border of the foot and flattens its arch; this, combined with partial ankylosis of the joint, gives rise to much pain and disability.

The ankle-joint must be opened and an attempt made to restore the bones to their normal positions. A stereoscopic radiogram helps greatly to determine what the condition of affairs is, and therefore what procedure is most likely to be effectual. Not infrequently the inability to reduce the deformity is due to the internal malleolus having become deflected outwards and united to its base in that position. This will necessitate exposure of the joint from the inner side, through the incision recommended above, and detachment of the malleolus, after which attempts must be made to rectify the outward displacement of the astragalus. This may require re-fracture of the fibula in order to allow its lower end to be rotated upon the inferior tibio-fibular ligaments, so that the astragalus may carry with it the external lateral ligament and the tip of the malleolus as it is pushed inwards. If this can be done, the result will probably be satisfactory; it will be necessary to smooth down with a gouge any callus about the base of the malleolus and then to fasten the tip of that process in position with tacks or bone plates.

In many cases, however, this theoretically ideal operation cannot be performed, as the two articular surfaces will not work accurately together,

in spite of all attempts to make them do so. Under these circumstances there is the choice of two methods:—

(a) To pare down the articular surfaces until the astragalus rests in the tibio-fibular arch with the foot in its normal position, so that the patient can bear his weight upon the normal points of support. In order to do this, the fracture in the fibula will certainly have to be reproduced so as to allow the external malleolus to be pushed inwards into proper position. The bone surfaces that have been pared to make away the astragalus (talus) fit must be rendered as smooth as possible, and it is a good plan to fasten over the raw surfaces thus left a flap of the fatty structures from the immediate neighbourhood; this facilitates movement in the joint subsequently (see p. 557). The foot is put up strictly at right angles to the leg, and should be kept rigid for the first ten days, after which time careful movement may be begun; the greatest care must be taken to see that there is no lateral deflexion of the foot.

(b) The other alternative is to excise the astragalus (see p. 598). This operation gives a movable ankle but rather a weak joint in an adult; in children, in whom the functional results are excellent, these fractures rarely, if ever, occur.

Operations for fractures of the astragalus. The steps of the operation cannot be given in detail, as they depend so largely upon the condition of affairs present. The joint may be exposed through an internal or an external incision (see p. 598), or by both combined, and the subsequent steps are similar to those described for Pott's fracture. Detached portions of bone should be removed, if small, or fastened back into place, if large, and the most careful attempt should be made to restore the condition of the joint as accurately as possible. It may be necessary to excise the astragalus entirely (see p. 598).

ARTHRODESIS

Indications. Arthrodesis of the ankle-joint may be usefully employed in cases of advanced infantile paralysis in which all the muscles around the joint are paralysed, giving rise to a flail-limb that is unable to bear the patient's weight. By means of apparatus it will of course be possible to prevent the joint from collapsing when weight is put upon it, but this is cumbrous and expensive, and may prove too much for the patient's strength, especially when there is also paralysis of some of the muscles moving the knee. Under these circumstances a more useful limb can be obtained if the ankle-joint be steadied by producing ankylosis.

Operation. The joint may be opened by the lateral incisions described below (see p. 598), but in these cases it is quicker to open the joint by a transverse incision across the front, dividing some, or if necessary all, of the extensor tendons. The muscles moving these are paralysed, and they are therefore useless, but if desired, it is easy to identify and suture them at the end of the operation. The anterior route gives better access, and it is important in these cases to remove the cartilage as completely as possible; this is done with a chisel or gouge, which clears the articular surfaces of the tibio-fibular arch, the malleoli, and the astragalus as completely as possible. The bony surfaces are then put back into apposition, the wound and the divided tendons are sutured, and the limb is put up in plaster of Paris with the foot strictly at right angles to the leg. The stitches are removed in ten days' time and an immovable plaster casing is then put on; it should be worn for nearly six months after the operation.

Results. The chief difficulty is to obtain firm bony union. Fibrous union is obtained in many cases, and when bony union does occur it may be extremely slow.

EXCISION OF THE ANKLE-JOINT

True excision of the ankle as distinct from excision of the astragalus on the one hand and arthrotomy for fractures on the other is never performed save for tuberculous disease. By the term is meant complete removal of the articular surfaces, both bony and synovial; this will be dealt with by Mr. Stiles.

OPERATIONS UPON THE TARSAL BONES AND JOINTS

EXCISION OF THE ASTRAGALUS

Indications. Excision of the astragalus (talus) alone is fairly often done, although it is most frequently practised as a part of the modern form of excision of the ankle. Apart from excision it may be done:—

(i) *In cases of injury.* These may be either severe comminution of the bone or such extensive contamination of it with dirt that there is no hope of avoiding sepsis otherwise.

(ii) *In extreme talipes equinus following infantile paralysis.* Here the pointing of the foot gradually protrudes the astragalus from the tibio-fibular arch, with the result that the bone becomes too broad in front to enable it to be returned beneath it when the tendo Achillis is divided; in order to get the foot at right angles to the leg the astragalus must either be removed or so cut down as to allow it to pass into position. As these cases are usually met with in children in whom the functional

results of removal of the astragalus are extremely good, it is better to remove the bone than to pare it down.

(iii) *In cases of extreme congenital talipes varus.* In order to overcome the extreme deformity it may be necessary to remove the astragalus (talus), after which the foot can be got into good position.

Operation. The incision that I have used most frequently for

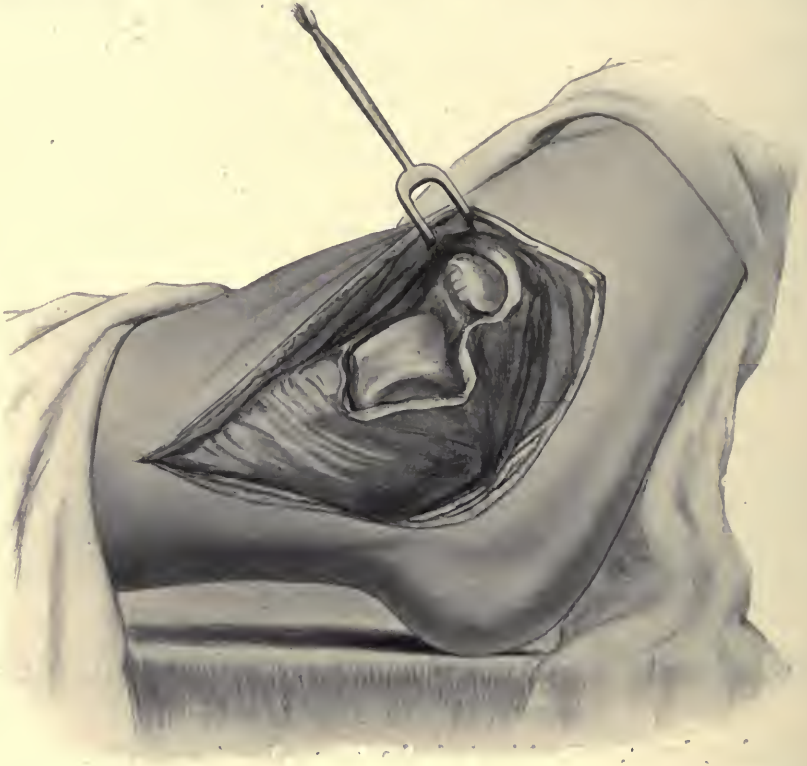


FIG. 267. INCISION FOR EXCISION OF THE ASTRAGALUS. The peronei tendons have been divided by an oblique section. The ankle-joint has been opened as well as the astragalo-scapoid joint.

the above conditions is a crescentic one over the outer ankle, commencing immediately behind the fibula two and a half inches above the tip of the external malleolus, extending down to the tip of that structure and forwards along the outer aspect of the foot as far as the prominence on the base of the fifth metatarsal (see Fig. 267). This incision is deepened, and the structures in front of it are dissected up for a short distance in the form of a flap. The foot is now plantar-flexed and everted in order to relax the peronei tendons, which are then

separated from the back of the fibula, turned out of their groove beneath the external malleolus, and entrusted to an assistant, who keeps them out of danger beneath a hook. This may be very difficult, and a much easier plan is to divide the tendons by an oblique section and suture them at the end of the operation. The external lateral ligament is divided and the incision carried forwards so as to expose the head of the astragalus (talus) and open the joint between it and the scaphoid (navi-

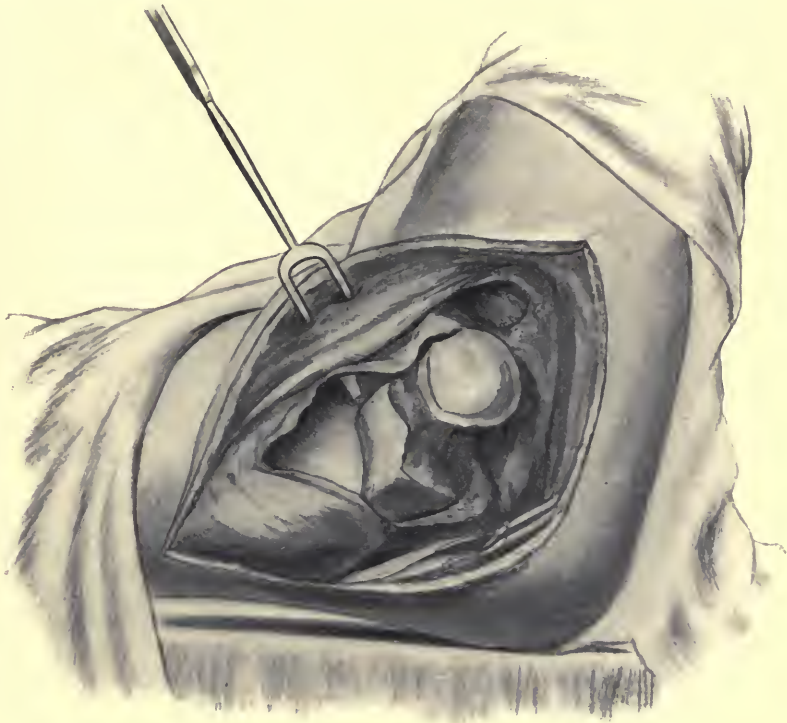


FIG. 268. EXPOSURE OF THE ASTRAGALUS. The head of the bone has been separated from the scaphoid and the interosseus ligament has been divided.

cular). In order to do this the foot is forcibly inverted and the toes bent inwards. When the astragalo-scaphoid (talo-navicular) joint has been opened, the point of the knife can be passed along the under surface of the former bone and made to divide the interosseous ligament between the astragalus (talus) and the os calcis (calcaneus), when the former bone can be made to start up prominently in the wound by further inverting the foot, which is dislocated inwards almost completely (see Fig. 268). The head of the astragalus (talus) is seized in lion forceps, and a few touches of the knife will remove it altogether (see Fig. 269).

The os calcis (calcaneus) is then brought up against the malleoli, and in young children will fit fairly well without much risk of dislocation. In adults, however, the projection of the sustentaculum tali makes the bone too broad to fit beneath the malleoli, and it is well, therefore, to pare down the articular surfaces so as to make them fit. A portion may be taken off each side of the os calcis (calcaneus), and the articular surfaces of the malleoli may also be cut away, but the whole of the

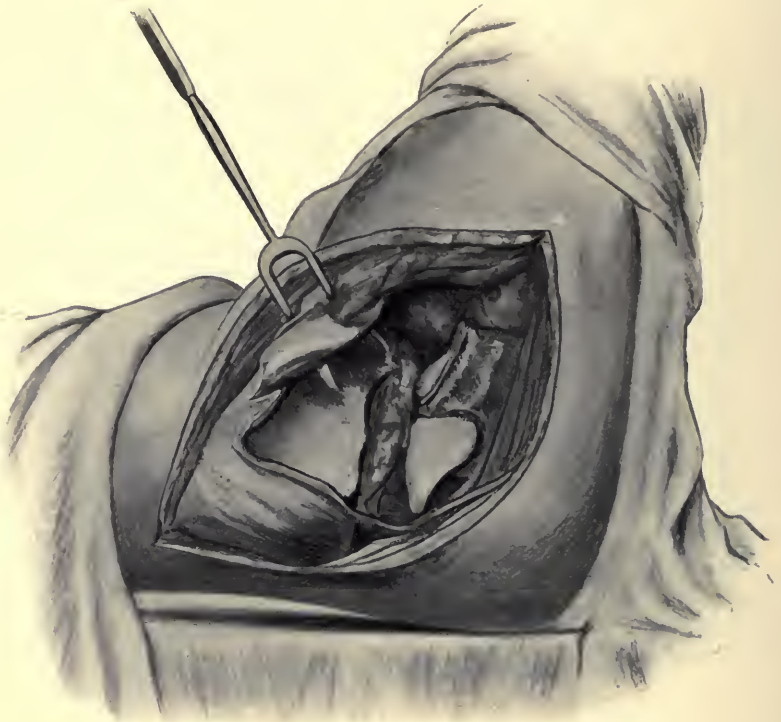

FIG. 269. REMOVAL OF THE ASTRAGALUS. The articular surfaces of the tibia and the os calcis are seen, as well as the divided interosseous membrane.

sustentaculum tali should not be removed, as it is required for the support of the tibialis posticus (posterior) tendon passing beneath it.

The wound is closed without a drainage tube, and the limb should be put up in a plaster of Paris casing; there must be no lateral deflexion of the foot, which should be at right angles to the limb. Throughout the after-treatment the most important point is to see that no lateral displacement of the foot occurs, and for this purpose a plaster of Paris casing strengthened with metal at the sides should be used for the first

three months, followed later on by an apparatus with lateral irons and a hinge at the ankle-joint. This will have to be worn for nearly two years in the case of a child; an adult will probably have to wear it for a much longer period.

Excellent results follow the simpler method of excising the bone after dividing the extensor tendons, and the operation is preferred by some to the one described above. A large flap is made upon the front of the ankle with its convexity downwards towards the toes. The incision reaches from one malleolus to the other, and its lowest point is on a level with the tubercle of the scaphoid. All the tendons are divided over the front of the joint, and the dorsalis pedis artery and the anterior tibial nerve are cut across and the ankle-joint opened from the front. This gives very free access to the astragalus, which is first freed from its attachments to the lateral ligaments of the ankle-joint and then from the scaphoid (navicular) in front. In order to remove the bone it is then only necessary to divide its connexions with the os calcis (calcaneus). The ends of the extensor tendons are identified and united at the end of the operation; speedy union occurs in aseptic cases and there is no loss of power on this account.

EXCISION OF THE OS CALCIS

Indications. (i) *For tuberculous disease.* The operations for this condition will be described by Mr. Stiles.

(ii) *For injury.* Severe comminuted fractures of the os calcis (calcaneus), especially when they are compound, will require an operation in order to secure the best results. This, however, will usually be only a partial excision.

(iii) *For new growths of the bone.* In the majority of cases an amputation of the foot will be the safer procedure, but in innocent tumours and in myelomata the bone may be excised and the progress of affairs watched.

Operation. The operation is difficult, owing partly to the want of elasticity in the cutaneous structures, but chiefly to the difficulty of dissecting out the sustentaculum tali. A good method of gaining free access to the bone is by making a vertical incision along the outer edge of the tendo Achillis, beginning an inch and a half above the upper edge of the os calcis (calcaneus) and reaching down to just above the outer margin of the sole. A second incision is carried at right angles to the first, horizontally round the back of the heel and along the outer border of the foot, from a point a finger's breadth behind the internal malleolus to the tuberosity of the fifth metatarsal bone.

This incision gives two large flaps, of which the upper is dissected off the posterior and outer aspects of the os calcis first. In doing this

the tendo Achillis is divided above, the external lateral ligament on the outer aspect of the bone, and the ligaments of the calcaneo-cuboid joint in front. The lower or plantar flap is now raised as far as the flexibility of the skin permits, and then the foot is firmly inverted, the peronei tendons are hooked out of the way, and the calcaneo-astragaloid (talo-calcaneal) joint is opened and the firm interosseous ligament divided. The remaining ligaments of the calcaneo-cuboid joint are cut through, and all that remains to be done is to sever the attachments of the bone on the inner side. In order to do this in the easiest way the foot must be very forcibly inverted and the tendon of the tibialis posticus (posterior) looked for as it passes under the sustentaculum tali in its special groove. It is raised from this and held out of the way with a hook. When this has been done, the knife is passed along the inner side of the bone from end to end, dividing the internal lateral ligament of the ankle and the ligaments connecting the os calcis (calcaneus) and astragalus (talus) on the inner side. A few touches of the knife then complete the removal of the bone.

A drainage tube should be inserted in the large and irregular cavity thus made. The cavity soon shrinks up, and the patient can walk well upon the heel provided that a small pad be placed beneath it. The stump is quite sound in about six weeks.

CHAPTER VI

OPERATIONS UPON THE KNEE-JOINT

REMOVAL OF DISPLACED SEMILUNAR CARTILAGES

Indications. In cases of recurrent displacement of the semilunar cartilage operation is now a safe and easy way of putting an end to a troublesome and often crippling affection. For a first or even a second attack it is not necessary to operate, since careful massage and suitable movements will often bring about a permanent cure; should the displacement recur in spite of this, however, early operation is indicated, since by it the displaced cartilage (which is practically always the internal one) can be removed and subsequent attacks prevented. The functions of the joint are unimpaired after removal of the cartilage, provided that this be done before the affection has lasted long enough for the recurrent inflammatory attacks to set up chronic changes in the joint resembling those of osteo-arthritis; in such cases removal of the cartilage will not necessarily be followed by complete restoration of the functions of the joint.

Operation. Various incisions may be used to expose the inner tuberosity of the tibia, along the upper border of which lies the cartilage. This should be felt for carefully before the skin incision is made, and the examination should be repeated before the capsule is opened by putting the finger on the joint and flexing and extending it. It is easy to mistake the level of the knee-joint, and, although this is not of much importance in other operations on the knee, in this particular one the difference of a quarter of an inch in the level of the incision in the capsule changes the operation from a simple to a difficult one.

In this operation, as in all of those upon the knee-joint, the limb should be purified from mid-thigh to mid-calf and wrapped up securely in sterilized cloths so that the assistant's hands cannot come into contact with unsterilized parts during the manipulations of the leg that may be necessary during the operation.

The surgeon faces the inner side of the knee, which should be semi-flexed and outwardly rotated. He makes an incision exposing the upper border of the inner tuberosity of the tibia from the inner margin of the ligamentum patellæ backwards to the junction of the inner with the

posterior surface of the tibia. A very useful incision for this purpose is a crescentic one with its convexity forwards. This gives a flap which can be extended backwards by prolonging the horns of the incision if necessary ; the advantage of this is that the skin incision does not lie over that in the capsule. Before raising the flap small cuts or scratches may be made across the incision so as to identify the corresponding points when the flap has to be sutured at the end of the operation, by which time its outline will have become somewhat altered. If preferred, however, a transverse or a vertical incision may be made. The vertical incision is parallel to the vessels and nerves of the limb and so saves them from injury, but it is rather difficult to get proper exposure through it unless it be very long, and a second incision posterior to the first may be required in order to get at the cartilage satisfactorily.

The flap is dissected back and the capsule of the joint over the inner condyle exposed. After all bleeding points have been ligatured, the capsule is opened by a horizontal incision parallel to and about a quarter of an inch above the upper margin of the inner tuberosity of the tibia, which should be carefully defined by the finger ; the capsule only should be divided and not the synovial membrane. There is often free bleeding from the articular arteries in doing this, and this should be checked before proceeding further. The synovial membrane which is thus exposed is caught up with fine-toothed forceps and snipped through with scissors in order to open the articular cavity, and the incision is enlarged sufficiently to give a good view into the joint.

The condition of the internal semilunar cartilage can now be made out by retracting the edges of the wound in the capsule ; the limb will have to be flexed rather acutely to display the front of the joint well. Various lesions of the cartilage, such as detachment from its insertion or transverse or longitudinal ruptures, partial or entire, may be met with ; but these are of little importance, since the only effective method of treatment is to remove as much of the cartilage as can be got at through the incision in the capsule.

In order to remove the cartilage, its convex edge, which will have been torn away from the head of the tibia by the accident, is seized in catch forceps, and the cartilage is raised and, if necessary, separated from its lateral attachments so that a pair of fine curved scissors can be slipped round its anterior extremity and made to divide its attachment in front, if that has not already been separated by the original injury. This is seized in forceps and the back part of the cartilage is put upon the stretch, freed by scissors, and divided as far back in the joint as the scissors can reach. The whole operation can be done without any further interference with the joint than the introduction of the scissors

into it. Very little bleeding accompanies the intra-articular part of the operation; it is easily stopped by douching the joint with hot saline solution. Some surgeons make a point of removing the entire cartilage, but this is a much more difficult matter, and, as far as my experience goes, is not necessary. The simplest way of doing it is to make a second small incision in the capsule just behind the condyle and to divide the posterior end of the cartilage through that, as it would weaken the joint unduly to divide the capsule and the internal lateral ligament over the whole of the cartilage.

When all bleeding has been arrested, a fine catgut suture unites the cut edges of the synovial membrane. A somewhat stouter one sutures the capsule, after which the skin wound is brought together with a separate suture. Outside the dressings the joint is enveloped in a thick mass of wool, bandaged on firmly so as to exert an elastic compression which will prevent effusion and restrict movement. No splint is needed; the knee is slightly flexed and the limb is elevated upon a comfortable pillow.

After-treatment. The patient may move his limb inside the dressing if he desires to do so. After a week a lighter dressing may be substituted and the patient encouraged to move the limb more freely. The sutures are removed on the tenth or twelfth day, and vigorous active and passive movements should then be employed. Perfect use of the limb should be regained within three weeks from the operation.

Difficulties and dangers. The chief danger is *sepsis*, the risk of which cannot be over-estimated. No one should perform this operation who is not confident of commanding complete asepsis throughout. Should sepsis occur, the joint must be opened immediately and drained freely (see p. 607). Another danger is *hæmorrhage* into the joint at the close of the operation, which may easily happen unless the surgeon be careful to secure every bleeding point as he goes on. It is always best to apply a ligature to all of these, as very slight bleeding in the joint may give rise to anxiety as to the progress of the case and a definite retardation in convalescence; the patient may be left with a distended capsule, for which prolonged treatment may be required. It is sometimes difficult to find the displaced cartilage; this generally results from incising the capsule too high above the cartilage. In order to get properly at the cartilage the joint has then to be opened unduly freely, and some weakness of the capsule may result. The best way to avoid this is to palpate the parts well while the joint is being moved after the skin incision has been made. The sharp edge of the tibia is unmistakable and will guide the surgeon to the right spot.

It occasionally happens that the joint remains weak for some little

time after the operation. This is only likely to occur when the patient has had recurrent attacks for a long time before seeking surgical aid. The interior of the joint at this stage will show a widely thickened and inflamed synovial membrane, and this condition may persist for a considerable time after removal of the exciting cause. In these cases massage and exercises designed to strengthen the thigh muscles and thereby tighten up the capsule are most beneficial.

ARTHROTOMY AND DRAINAGE

Indications. The knee-joint rarely requires to be drained for any affection other than suppurative arthritis. It has been proposed to incise and drain the knee-joint as treatment for gonorrhœal or simple acute rheumatism, with the view of relieving tension, alleviating pain, and promoting restoration of function more rapidly than can be done by non-operative measures. The only experience that I have in this direction is in connexion with gonorrhœal rheumatism. On five occasions I have incised freely a knee-joint which was acutely distended as the result of gonorrhœal arthritis, and in all the cases the relief of pain was very striking. In four out of the five the swelling had subsided completely within six weeks, and the functions of the joint were left unimpaired. In the remaining case the synovial membrane remained thickened for three months after the wound had healed.

Operation. The knee is a difficult joint to drain, and drastic measures have been proposed in order to effect this. In early days a large drainage tube was passed through the joint from side to side beneath the patella. A useful improvement upon this was the plan of effecting drainage by continuous irrigation, while more recently the late Mr. Harold Barnard (*Clin. Soc. Trans.*, vol. xxxvi, p. 150) proposed a very thorough drainage scheme for this complex joint. The most radical method is excision of the articular surfaces so as to open up the joint cavity and to obliterate most of its recesses. This method can hardly be recommended at the present day however. Its chief result will be to open up large areas of cancellous bone to septic infection. A better plan would be to adopt the line of treatment suggested and practised by Mr. Eve (*loc. sup. cit.*), who cut across the front of the joint, divided the patella, and flexed the knee fully so as to expose the recesses of the joint. Such a method must of course result in a stiff limb, and nothing but the desperate state of the patient would justify recourse to it. It is hardly likely that such extreme measures would be called for when infection has followed a surgical operation, such as removal of a semilunar cartilage, or wiring of the patella. Here the surgeon

would be alive to the nature of the case very early, and less radical measures should suffice to secure recovery with a more or less movable limb. It may therefore be advisable to divide the operations for drainage of the joint into two groups: those in which the infection is slight, *e. g.* those in which the infection follows a surgical operation, and those in which the infection is severe, as in neglected cases of injury to the joint, or those accompanying infection from acute infective osteomyelitis.

In cases of mild infection. These probably form the majority of cases met with in practice at the present day, and good results may be looked for if the treatment be undertaken early enough and be sufficiently thorough. Effective drainage may be obtained by opening the joint by two free vertical incisions, each about a finger's breadth from the edge of the patella and reaching from the level of its lower margin to a full inch above its upper border. This exposes the front and lateral aspects of the joint fully, and enables the surgeon to inspect the interior and to ascertain the extent of the subcrural pouch above the patella, whereby he can judge whether it is necessary to employ direct drainage of this space. If so, a pair of dressing forceps is thrust from one of the lateral wounds to the upper limit of the pouch and its points are cut down upon through the skin in the middle line; a large drainage tube is drawn through from this opening in the skin and made to project through one of the lateral incisions, generally the inner one. In the majority of cases it is well to drain the outer side of the joint also, and this can be done by passing down a pair of sinus forceps over the outer condyle to the lowest limit of the joint and thrusting them through the capsule in that situation. An incision is made through the skin over the points of the forceps and a drainage tube introduced from behind into the outer recess of the joint. In doing this care must be taken to divide only the skin with the knife, otherwise the external popliteal nerve may be endangered. A large tube is passed across the front of the joint from the inner to the outer incision beneath the patella, and the joint cavity can be drained freely in this manner in the majority of cases. The tubes can be arranged so as to permit of continuous irrigation of the joint, the fluid being run into the joint through the tube above the patella or through one end of the tube passing across the front of the joint. Before the first dressings are applied the whole of the interior of the joint should be flushed out freely with sterilized salt solution.

In cases of acute infection. In the cases suited for the preceding operation the infection is mainly in the front and lateral aspects of the joint, but in the more severe ones there is a tendency for the posterior sacs to be acutely infected, and it is difficult to drain these from the

front. The late Mr. Barnard (*loc. sup. cit.*) drew attention to the importance of these synovial sacs which contain the corresponding condyle. They lie between the head of the gastrocnemius and the bone, and the outer pouch sends a prolongation along the popliteus. He strongly advocated separate incisions for the drainage of each of these sacs. On the inner side the prominent inner condyle can be cut down upon when the limb is extended and forceps, carrying a drainage tube, can be introduced into the joint. On the outer side a vertical incision should be made between the biceps tendon and the outer head of the gastrocnemius just behind the external popliteal nerve, going through skin only. The capsule of the joint over the condyle is exposed with a blunt dissector, incised, and a drainage tube inserted. In addition to these incisions, drainage of the front of the joint should be effected by vertical incisions on either side of the patella and a median one above it for draining the subcrural pouch. Mr. Barnard noted the frequency with which pus under pressure spurted out from the outer posterior pouch when it was incised.

After-treatment. The dressings require to be changed frequently, and it is a good plan to employ peroxide of hydrogen (10 vols. per cent.) at each dressing. As the discharge diminishes, the drainage tubes are gradually shortened and finally withdrawn. Passive movement is begun as early as possible, the limb meanwhile being kept upon a splint in order to prevent the contraction which the powerful hamstring muscles would otherwise produce. The most important point in the after-treatment is to keep the patella from becoming adherent to the front of the condyles, and this must therefore be moved freely at each dressing. It is remarkable that excellent functional results have been obtained in this manner even after the most severe infection.

REPAIR OF THE CRUCIAL LIGAMENTS

This operation is a very rare one, and has, as far as my knowledge goes, only been performed once (Mayo Robson, *Clin. Soc. Trans.*, vol. xxxvi, p. 92). The joint was opened by a curved incision across the front, dividing the ligamentum patellæ about its middle. Both the crucial ligaments had been torn from their upper attachments and had to be stitched in position with catgut sutures. The anterior ligament was fastened to the synovial membrane and adjacent tissues on the inner side of the external condyle; the posterior had to be split in order to lengthen it, and was fastened by sutures to the synovial membrane and cartilage on the outer side of the inner condyle. The patient made an uneventful recovery with perfect use of his limb. He was seen six years after the operation, when the abnormal mobility present before

the operation had been entirely lost, and there was no interference with movement except some limitation of flexion, the knee becoming fixed when it was flexed just beyond a right angle. There was fine creaking felt in the joint on movement, and the patient said it was more liable to pain in damp and cold weather.

This operation seems worthy of being added to the list of recognized surgical operations, since the injury is by no means as uncommon as might be thought. I have recently seen two cases resulting from severe hunting accidents in which, however, the degree of disability was not extreme enough to demand operative interference in a well-to-do patient. The description of the above case, however, shows that in those who follow laborious occupations the operation has a definite field of usefulness. The patient operated upon by Mr. Mayo Robson was a miner and followed his occupation from the time of his discharge from the Leeds Infirmary without any trouble.

REMOVAL OF THE SYNOVIAL MEMBRANE OF THE KNEE

Indications. The joint is frequently opened for the removal of diseased synovial membrane. As a rule, however, this affection is tuberculous, and the operation for this condition does not fall within the scope of the present article and is dealt with by Mr. Stiles.

The synovial membrane, however, or a considerable part of it, may not infrequently have to be removed for other reasons. Thus it may become hypertrophied and covered with papillary outgrowths, which give rise to so much inconvenience in locomotion as to call for active surgical interference. This affection may be diffused over almost the whole of the synovial membrane, or it may be limited to a few spots, generally in the neighbourhood of the inner condyle and the margin of the patella. This condition is apparently distinct from the ordinary osteo-arthritis. Occasionally the joint is opened for the removal of osteophytic outgrowths or polypoid masses of synovial membrane occurring in osteo-arthritis and acting as a mechanical obstruction to movement.

Operation. As a rule it is well to open the joint by a free incision, and for this purpose none is better than a long vertical incision about a finger's breadth to the inner side of the patella. This gives admirable access to the whole of the inner side and most of the anterior part of the joint, and the synovial membrane can be dissected out with ease and accuracy. Should it be deemed necessary, a similar incision can be added on the outer side of the patella, and any portion of the affected synovial membrane on the front of the joint that cannot be reached from the inner wound may be removed from that.

It is needless to say that the most scrupulous attention must be paid to disinfection of the skin. The whole of the joint must be purified carefully front and back, and the limb above and below securely wrapped up in sterilized towels, as it will be necessary to move the joint frequently during the course of the operation. It is well to raise the skin as a flap, so that the incision in it does not lie directly over the incision in the capsule. The steps of this part of the operation are similar to those for removal of a displaced semilunar cartilage (see p. 603).

When the joint has been incised, its interior is inspected and the particular portion of the synovial membrane that has to be removed is identified. This patch should then be marked out by carrying an incision around it with the knife or scissors, and the whole thickness of that part of the synovial membrane should be dissected off. This is generally effected best with blunt-pointed scissors, which serve both as cutting and dissecting instruments. An attempt should be made to remove the affected area in one mass, however large may be the extent of synovial membrane that has to be removed. After removal, all bleeding points are ligatured with fine catgut, and any oozing is stopped by douching the joint freely with sterilized salt solution at a temperature of 115° F. When all the bleeding has ceased, the incision in the joint is closed accurately, the capsule being united by a separate fine continuous catgut suture; no drainage tube is employed. The dressing should consist of a roll of gauze, which is wound round the limb so as to prevent swelling from extravasation of blood. No splint is required.

After-treatment. The patient is encouraged to bend his knee from the first, and massage and passive movements should be employed, beginning at the end of the first week. When the stitches are removed, the massage should be vigorous and the patient should be encouraged to walk at as early a date as possible.

Results. The results of some of these cases are really remarkable. I have on several occasions removed almost the whole of the excisable portion of the synovial membrane for a papillary non-tuberculous synovitis which had resisted all previous treatment for many months, and was the source of complete incapacity to the patient. The pain and swelling were not only cured, but perfect movement in the limb resulted without any difficulty whatever and without any necessity for the use of passive movements under an anæsthetic. With complete asepsis and the use of non-irritating lotions the most extensive raw surfaces may be left in contact within the joint without impairing movement.

OPERATIONS FOR INTRA-ARTICULAR FRACTURES

Although strictly speaking operation for the fixation of a fracture about the lower extremity of the femur is practically always in the nature of an arthrotomy in that the joint is always incised, yet as a rule the operation itself is performed mainly outside the joint, and the chief interest in the case centres in the approximation of the fragments rather than the technique of the joint surgery. Occasionally it may be necessary to open the joint freely for the treatment of a fracture of the spine of the tibia, in which case the operation will be very similar to that for suture of the crucial ligaments (see p. 608). A very important fracture involving the knee-joint is that of the patella, the operations for which it will be well to consider here.

OPERATIONS FOR FRACTURE OF THE PATELLA

There are several operations for fracture of the patella, all of which have for their object the close approximation and fixation of the fragments so that true bony union shall result.

Indications. Much difference of opinion has occurred during the last twenty years as to the indications for operative interference in fractures of the patella. Even at the present day there are still surgeons who consider that the age of the patient and his occupation should influence the question whether an operation should be done or not. Neither the age of the patient nor his occupation should determine the question. The only points of real importance are the nature of the fracture and the patient's ability to undergo any ordinary operation.

In a fit subject for operation, any fracture of the patella, either recent or of long standing, which is of the transverse variety and is accompanied by separation of the fragments should be operated upon, as this condition of affairs inevitably ends in fibrous union and probably in considerable disability of the joint. The stellate or longitudinal fractures which are readily differentiated by the X-rays, and which are not accompanied by any marked separation of the fragments, are excluded from this category; in them excellent bony union usually results without operation.

As the steps of the operation, and to some extent its results, differ somewhat according to whether the operation is done for recent cases or those of long standing, these two groups will be described separately.

OPERATIONS FOR RECENT FRACTURES

Before discussing the methods by which a fractured patella may be united, it is important to consider the question of *when to operate*. Some difference of opinion still exists upon this point, but the tendency is in favour of early, if not immediate, operation. It would appear reasonable that the sooner the joint is opened, the blood cleared out of it, and all bleeding points secured the better; moreover, the sooner the broken ends are brought into apposition the more accurately they fit, and this to some extent makes the operation easier, as the surgeon sees exactly what he has to do, and his view is not obscured by the blood-clot which clings very tenaciously to the fractured surfaces when the injury is a few days old. It was formerly thought that sepsis was more likely to occur if operations were carried out immediately after receipt of the injury; this was attributed partly to the inflammatory reaction following the injury, and partly to the difficulty of securing perfect asepsis of the skin. While it is now recognized that the first objection has no foundation in fact, the second one, namely, the difficulty of securing asepsis, may be of importance in certain cases. The skin over the front of the knee is rough, thick, and, in labouring men, often deeply ingrained with dirt, so that it may be a matter of extreme difficulty to get it into a condition approaching that of sterility, except after prolonged saturation of the superficial layers of the epidermis with antiseptics so that they can be actually scraped off and the surface beneath purified. Personally, it is my invariable custom to operate upon all these cases as soon after they are seen as is convenient, but in the case of a labouring man whose skin is thick and dirty there is no objection to postponing the operation for two or three days, so that in the meantime cleansing methods may have a fair chance. The old rule, however, of leaving the case for ten days or a fortnight until most of the effusion has become absorbed should not be followed. This is a bad rule, as it allows coagulation of the effused blood to take place and the clot to become so closely adherent to the broken bone and the torn synovial membrane that it is difficult to remove it without doing more damage to the delicate articular structures than the joint should be exposed to.

In preparing the limb for operation it should be shaved from mid-leg to mid-thigh and thoroughly scrubbed with ether soap, followed by 1 in 20 carbolic lotion, which has a considerable power of penetrating epidermis. A compress of sterilized gauze, wet with 1-2,000 sublimate solution, should then be bandaged over the knee and kept from evaporating by gutta-percha tissue placed outside. This forms a wet dressing, which

is removed in six hours, and the skin again scrubbed with ether soap and hot water, followed by another application of the wet 1-2,000 sublimate dressing, and a final purification with ether soap and 1-500 sublimate solution is carried out just before the operation. This method of purification applies to ordinary cases; in labouring men with dirty horny skin it should be repeated every eight hours until the operation takes place, and it should be done at least three times.

Operation. The only operation of which I have personal experience is that rendered classical by Lord Lister. I have always found it give such excellent results that I have never been tempted to practise any other.

Lord Lister's method. The surgeon and his assistants should wear gloves, and all instruments, sponges, &c., should be wrung out of sterilized salt solution. As little interference with the structures of the joint as possible should be permitted, and everything should be done with the greatest gentleness.

The best *incision* is a semilunar one, with its convexity upwards and its extremities on a somewhat lower level than the fracture. The left thumb and forefinger are placed on either side of the patella at a distance of about three-quarters of an inch from its margin and about half an inch below the level of the fracture, and between these two points the convex incision is marked out, its upper limit reaching just to the upper border of the patella. This gives a flap the cicatrix of which is nowhere exposed to pressure. In order to facilitate accurate suture of the flap at the end of the operation I always make two or three small cross cuts when marking out the incision at the commencement of the operation, so that the corresponding points on the two sides of the incision can be easily recognized when the flap has to be sewn up. The flap is turned down by a few touches of the knife; it rarely requires much dissection, as the first incision usually opens into the distended prepatellar bursa, which communicates with the fracture; a few small vessels will require clamping. The turned-down flap is covered with gauze while the fracture is inspected; this usually occurs about the junction of the lower with the middle third of the bone, and is prolonged on either side as a considerable rupture of the capsular ligament. As it is important to get a good view of the interior of the joint in order to wash out clot and effect accurate coaptation, the capsule should be incised on either side if the fracture of the patella has not already ruptured it.

The next step is to wash away all blood and clot from the fractured surfaces and the surrounding tissues, and to see how many pieces the patella is split into; it not infrequently happens that the lower fragment

is split up into two or more portions. All bleeding points should be secured, and before drilling the bone the surgeon determines whether he will put in one or two wires, and how thick the wire shall be. When the fracture is a simple transverse one, consisting merely of an upper and lower fragment, the latter being of reasonable size, I have always found

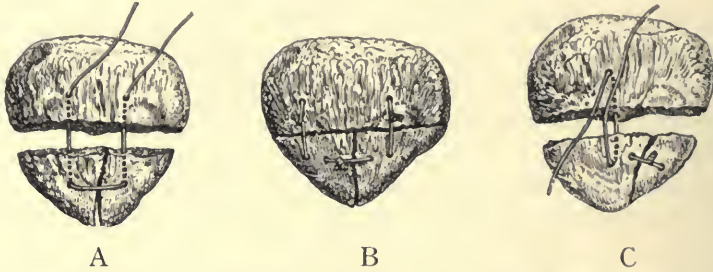


FIG. 270. METHODS OF INSERTING SUTURES IN COMMUNATED FRACTURES OF THE PATELLA. A shows a mattress suture applied so as to approximate three fragments. B shows the same fragments secured by three separate sutures, while C shows a good method when only a small portion is chipped off the lower fragment. Here the larger one is approximated by the usual stout median wire and the small portion is united to it by a fine lateral one.

it sufficient to use a single median wire of gauge No. 5 (French catheter scale).

When, however, the patella is split into three fragments, it may be necessary to use more than one wire. A simple method of fastening three fragments together by one wire is by means of a mattress suture



FIG. 271. BONE DRILL FOR WIRING. There is a large groove in the end of the drill which serves as a guide for the passage of the wire (see Fig. 272).

(see Fig. 270), which takes a secure hold on all three. Occasionally it may be necessary to use three sutures (see Fig. 270), a fine wire to join the lower fragments together and two stouter ones to join the united lower ones to the upper. In either of these cases the wire used need only be of gauge 4, as the strain upon it will not be so great as when a single median wire is employed.

Drilling the bone is best done by means of an electrically driven drill, as the high speed at which the drill runs enables it to penetrate the fragments with the least amount of damage to the joint structures and the least application of force; the surgeon is, therefore, able to direct

the shaft of his drill more accurately and with less chance of deflexion. The most difficult part of the operation lies in drilling the fragments so as to make the drill-holes correspond exactly to one another on the fractured surfaces. If a hand-drill be used Fig. 271 shows the usual pattern. The bone is drilled from its anterior surface to the fracture. Before doing this, it is advisable to make a small incision through the soft parts covering the bone, and to push them away from the spot at which the drill will enter and from which the end of the wire will have to emerge; it is convenient to keep the edges of this little cut apart by catching them in

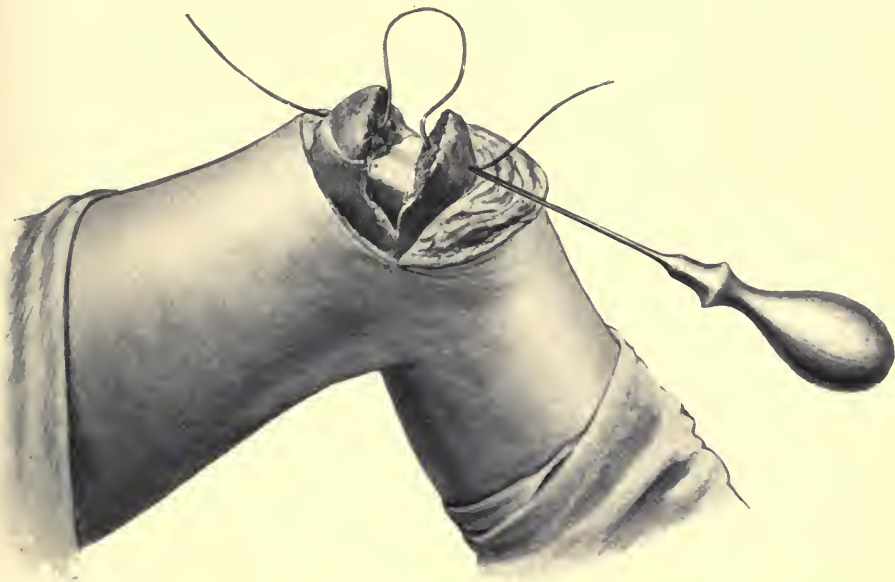

FIG. 272. PASSING THE WIRE IN FRACTURE OF THE PATELLA. The loop into which the wire is bent is shown. The wire is being guided through the lower fragment along the groove of the drill.

forceps. Unless this be done, the end of the wire as it emerges from the hole in the bone may be caught in the soft tissues and burrow its way through them for some distance without emerging directly.

The drill is made to penetrate the upper fragment first and passes from its anterior aspect to the fractured surface. It is entered nearly half an inch above the line of fracture and emerges from the fractured surface just in front of the articular cartilage (see Fig. 272). The lower fragment is drilled in a similar manner, the drill being entered on the anterior surface of the bone as near its apex as possible and made to

appear on the fractured surface exactly opposite the hole in the upper fragment and just in front of the articular cartilage. The wire passing through the fragments, therefore, will be outside the articular cavity.

After a little practice it is easy to make the two holes on the fractured surfaces correspond, but for a beginner a simple way of ensuring regularity is to drill the lower fragment first in the manner described above and then to bring the lower fragment into careful apposition while the drill remains *in situ*; if the drill be pushed on slightly, a depression is marked on the fractured surface of the upper fragment. The drill is then withdrawn from the lower fragment and entered at the puncture thus made on the fractured surface of the upper fragment and made to penetrate the fragment from below upwards instead of from above downwards as just described.

When introducing the wire certain precautions are necessary to ensure a good result. A portion of the wire about one foot long is carefully unrolled and straightened, and one end cut somewhat obliquely with cutting-pliers. Great care must be taken to avoid kinking, as a kink in stout wire of this sort is almost impossible to obliterate without removing the wire entirely. In order to introduce the wire, therefore, the portion to be used is made quite straight and one end is introduced through the upper fragment from its anterior aspect and made to emerge through the opening on the fractured surface. The fragment is rotated so that this surface looks well upwards, and the wire is pulled through until only about four inches remain projecting from the anterior surface of the patella. The remainder of the wire is then bent into an easy curve so that it can be carried through the lower fragment from the fractured surface to the anterior aspect (see Fig. 272). If the grooved hand-drill (see Fig. 271) be employed this may be used to guide the wire as it emerges from the front of the lower fragment.

When wire has been passed, its ends are grasped in suitable forceps and firm traction is made upon them in opposite directions. This straightens out the wire and allows an assistant to push the two fragments threaded upon it closely together; when they have been made to meet, the ends of the wire are brought together, twisted round in two complete twists over the upper fragment (see Fig. 273), and the ends cut short with cutting-pliers. The section of the wire should be very oblique, and the ends are hammered down with a fine punch so that they are buried beneath the soft tissues over the front of the patella; a small slit should be made for their reception. If this be done carefully the ends will be buried effectually, and it is unlikely that the wire will require removal subsequently.

All that now remains to be done is to bring together with catgut

sutures the rent in the capsule on either side of the fracture and the torn fibrous tissues over the front of the bone. The knee is dressed with gauze loosely rolled around the limb from below upwards so as to exercise a certain amount of compression, but not too much, and outside this is applied a large amount of wool bound on fairly tightly so as to exert good elastic compression and to act to some extent as a splint. No splint is required ; it is sufficient to restrain any involuntary movement of the limb by the

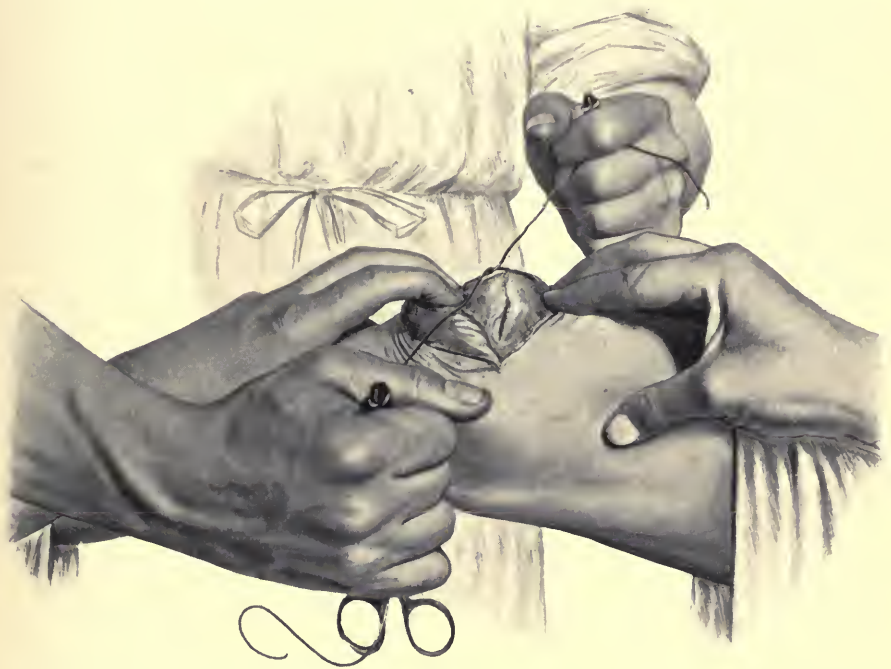

FIG. 273. TWISTING THE WIRE IN FRACTURE OF THE PATELLA. The fragments have been pushed together along the wire.

use of sand-bags for the first few hours. Two or three pillows should be placed beneath the limb so that the hip is flexed at an angle of about twenty degrees.

After-treatment. The patient is not discouraged from moving the leg in bed if he desires to do so ; he will probably keep it rigidly stiff for the first week, after which he will gradually attempt some movements ; he should be encouraged to do this more and more, so that after the first ten days he will be able to effect a fair amount of flexion. The wound need not be inspected until the end of the first week, when a collodion dressing may be applied and the wool around the limb diminished, in

order to allow the patient to move the limb more freely. The stitches may be removed on the tenth day, and the patient may get up between the tenth and fourteenth day. From the fourteenth day onwards I have always been in the habit of allowing my patients to get about with the aid of a stick, trusting entirely to the wire to retain the fragments in position. The patients readily regain the use of the limb, and usually are walking about quite well without any artificial aid at the end of a month from the operation. It is a good plan, however, to have them fitted for the first six weeks or so after the operation with an apparatus that does not allow more than twenty degrees of flexion, so as to prevent any sudden strain from stumbling, &c.

Barker's method. Lord Lister's operation is so simple, so efficacious, and so successful in the hands of a really aseptic surgeon, that it is hardly necessary to do more than mention other methods that have been adopted for procuring close bony union. In the earlier days of the operation methods of securing the fragments without interfering with the interior of the joint were devised. These cannot be recommended; no surgeon should attempt to operate upon these cases who is desirous of shirking interference with the joint cavity. The only other method that will be described is that of Mr. Barker (*Brit. Med. Journ.*, 1896, vol. i, p. 963).

This was introduced with the idea of simplifying the operation and reducing the time spent upon it to a minimum. It is done as follows:—

A narrow-bladed knife with its edge upwards is thrust through the middle of the ligamentum patellæ and is made to cut upwards on to the lower edge of the lower fragment, which is meanwhile steadied between the left thumb and index finger. The blade of the knife is made to penetrate the joint and, on withdrawal, it enlarges the skin wound upwards to the extent of two-thirds of an inch. Through this opening a special needle (see Fig. 274) is thrust into the joint, the cavity of which it is made to traverse posteriorly to the two fragments, and its point is made to emerge through the tendon of the quadriceps extensor muscle immediately above the upper margin of the upper fragment and strictly in the middle line. When the point of the needle appears beneath the skin it is cut down upon and exposed. A knife is then introduced into the joint alongside the needle, with its cutting edge downwards, and made to divide the quadriceps aponeurosis down to the upper edge of the upper fragment of the patella strictly in the middle line. A stout silver wire of a thickness equal to a No. 1 English catheter is then hooked into the eye of the needle as shown in Fig. 274, and the latter is withdrawn and unthreaded. This leaves one end of the wire emerging from the incision above that bone. The unthreaded needle is now entered again at the

lower aperture and is made to pass in front of the two fragments as close as possible to them, until its point emerges from the upper incision in the skin. The end of the wire emerging from this incision is now hooked into the eye of the needle, and the latter, carrying the wire with it, is withdrawn and unthreaded. Both ends of the wire now emerge from the lower incision in the skin and the wire itself encircles the fragments, passing first behind, then around the top of the bone, and finally in front of the two fragments, to emerge at the lower opening (see Fig. 274).

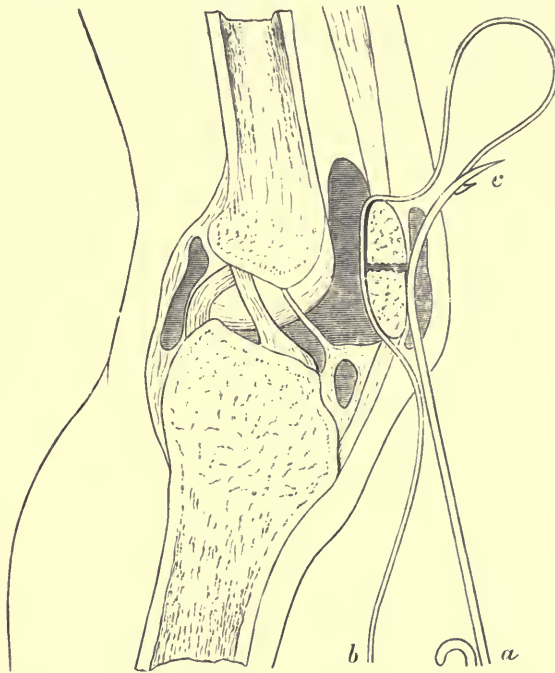


FIG. 274. BARKER'S METHOD OF SECURING FRACTURES OF THE PATELLA. The needle *a* is about to be withdrawn, carrying with it the end of the wire *c*, *b* being the lower end of the posterior wire. (*Barker.*)

The fragments are now finally and firmly adjusted by the assistant, who pushes them closely together and sees that there is no rotation of either upon its vertical axis. The surgeon takes the ends of the wire, which are secured in suitable forceps so as to give a good hold, and carries the posterior wire upwards and to the right of the anterior one, which is pulled directly downwards. This brings the fragments firmly together, and all that remains to be done is to twist the wire together. This is done by carrying the operator's left hand, in which is the posterior wire, across to the right, and the operator's right hand, which carries the anterior wire, to the left, so that a complete twist

is made. This is repeated three times, and the ends are then cut about half an inch long. The twisted wire is drawn through the puncture in the skin and the ends of the twist are buried in the soft parts over the ligamentum patellæ.

There are one or two precautions necessary for success in this operation. It is a method suited only for recent cases, and the sooner after the accident it is practised the better; it is much easier to approximate the fragments with certainty and accuracy immediately after the receipt of the injury.

Another point of importance is that the fragments should be accurately adjusted before the wire is introduced. The operator grasps each fragment separately and rubs the fractured surfaces against each other so as to dislodge all blood and foreign material from between them, until he gets the characteristic firm bony grating; he then knows that the fractured surfaces are clear, and ready to be coated. During the passage of the wire advantage may be taken of the incision into the joint to squeeze out from its cavity as much of the fluid blood as possible.

After-treatment. Immediately after the operation passive and even slight active movement is employed. No splint should be used, and massage should be adopted from the first. It is quite possible to practise this from the day following the operation, as there is no large wound to interfere with it. The small wound made by the operation is covered by small antiseptic pads, which may be secured in position by collodion. The whole operation is said by Mr. Barker not to take more than five minutes from beginning to end. In discussing its merits, its author, while acknowledging the success of the open method in his own hands as well as in those of others, advocates this particular measure from the point of view of saving time. If, therefore, a case is met with in which it is considered inadvisable to give a general anæsthetic, and in which spinal analgesia cannot be employed, this method would appear to be superior to the one previously described. Such cases, however, must be exceedingly rare, and there can be no doubt as to the superiority of the open method for permitting accurate coaptation, removal of clot, and investigation of a possibly complicated fractured surface.

It will be seen that this method really requires equally rigid observance of antiseptic details, and the mere fact that the knee-joint is not laid widely open, as in the former case, must not lead the surgeon to think that he may therefore neglect any of the precautions so essential in dealing with wounded joints.

OPERATIONS FOR FRACTURES OF LONG STANDING

Indications. Surgical interference in fractures of the patella of long standing is only practised to overcome disability of the limb. There are three principal classes of cases in which operation may be called for :

(i) Cases of *re-fracture of the patella after previous wiring*. These may be looked upon as practically recent fractures.

(ii) Cases marked by a *wide gap between the fragments* filled in with fibrous tissue. This condition is not uncommon after non-operative treatment, and in such cases the gap may either be very wide from the first, or the union, which at first was close and satisfactory, may gradually stretch owing to the inability of the fibrous union to bear the strain put upon it. The mere size of the gap between the fragments is not necessarily any criterion as to the necessity for operation or not ; the important point is the functional value of the limb. In considering the question of whether to operate on cases of long-standing fracture of the patella, it is important to remember that, quite apart from the question of sepsis, the operation is by no means as easy as it is in the recent cases, and that therefore, in a patient of fairly advanced years with a wide gap between the fragments but a fairly useful limb, it may be a rash procedure to interfere, since the amount of permanent shortening of the muscles present renders the after-treatment necessarily long and the prognosis somewhat uncertain.

(iii) Cases in which the gap between the fragments, although slight, shows distinct evidence of *widening*. Unless the patient be too advanced in years, it is best to interfere at once in these cases and unite the fractured surfaces in the hope of getting firm bony union. The results of operation at this period are more satisfactory than when further stretching has taken place.

Operation. The steps of the operation are exactly similar to those for recent fractures up to the exposure of the fragments. In cases of long standing, changes will have occurred in the fractured surfaces which will interfere with the process of union if they are simply placed in apposition ; the bone surfaces require to be refreshed by cutting a thin slice from each fragment with a chisel or saw. If the conditions allow of it these surfaces should be cut at right angles to the long axis of the bone ; in any case the two surfaces should be parallel to one another. The fragments are then drilled as described above (see p. 614). It is here that the greatest care is required, as the bone is soft and fatty owing to non-use, and too much traction upon the wires will make them cut their way out of the bone. One way of avoiding this very unpleasant accident is to make use of a mattress suture, as originally suggested by Sir Hector

Cameron, and this is an excellent method when the size of the fragments allows (see Fig. 270). The contraction of the quadriceps must also be overcome and reduced to a minimum, and this may offer so great a resistance that it may even be necessary to divide its tendon partially. Before any attempt is made to draw the fragments together it is important to see that the upper fragment is freely mobile. The finger is passed between it and the condyles of the femur, and any adhesions are broken down so that the bone moves freely and can be pulled down. The assistant then extends the knee fully and flexes the extended limb upon the pelvis so as to relax the quadriceps to the utmost. The surgeon takes one fragment in each hand and pushes them together forcibly until they come into contact. If this can be done it will be safe to pass a wire in the ordinary manner; the steps of this are identical with those for recent fractures (see p. 614). If, however, the fragments will not come together satisfactorily in spite of manœuvres of this sort, the surgeon has to make his choice of measures designed for still further relaxation. Three methods are open to him:—

- (a) Division of the quadriceps extensor tendon.
- (b) Division and lengthening of the quadriceps muscle.
- (c) Approximation of the fragments in two stages.

Of these, division of the quadriceps extensor tendon is of very slight value as, in order for it to be effective, the patella must be cut away from its attachments very freely, and its blood-supply and consequently the union of the fragments are thereby seriously endangered. Lengthening the quadriceps muscle gives a more satisfactory result, and may perhaps be the method of choice when the patient is young and the muscular development is good (see p. 472). In elderly subjects, however, it is somewhat difficult to get proper restoration of muscular power after the somewhat weak muscles have been divided.

Another suggested method is to chip off the tubercle and the attachment of the ligamentum patellæ to the tibia, and thus displace the lower fragment upwards and lessen the gap. This operation is more fascinating in theory than useful in practice, and gives very little gain.

For the majority of cases the approximation of the fragments in two stages, as proposed and practised by Lord Lister, is on the whole the soundest in principle and in practice. His description of it, quoted from the *British Medical Journal*, 1908, vol. i, p. 849, is as follows:—

Realizing that a method practised by M. Lucas-Championnière, who, finding himself unable to approximate the fragments, contented himself with connecting them with a long wire and left the wire in position, was open to objections as a permanent arrangement, Lord Lister determined to adopt it as a temporary expedient in order to stretch the quadri-

ceps, and, when the stretching had been brought about, he operated a second time and brought the fragments together. The case he describes is that of a woman who had sustained a fracture of both patellæ four years previously. There were five inches of separation on the left side and the upper fragment was very small. On the right side, however, the upper fragment was of good size and the separation less, and the following operation was performed on it :—

‘I made two short longitudinal incisions (A B and C D) over the two fragments (shown in dotted line) (see Fig. 275), and having exposed them by a little dissection, drilled two holes in the upper one, and passed through them, from without inwards, the ends of a piece of the usual

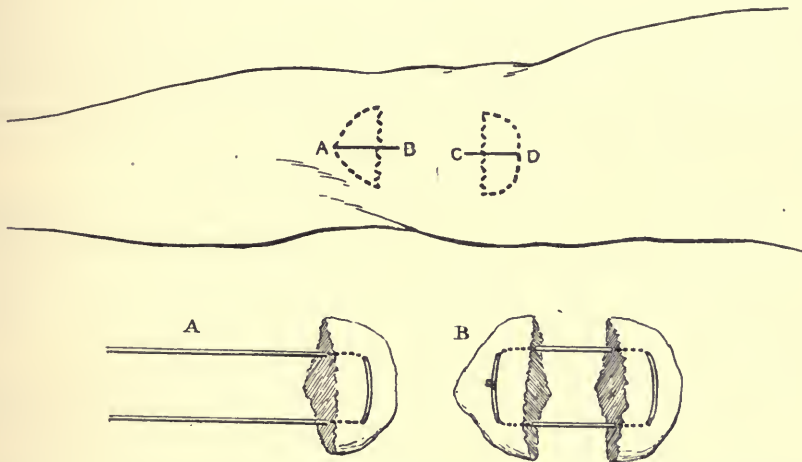


FIG. 275. LORD LISTER'S OPERATION FOR UNION OF A FRACTURE OF THE PATELLA OF LONG STANDING WITH WIDE SEPARATION OF THE FRAGMENTS.

stout silver wire, so that, when the ends were pulled upon, the middle of the loop of wire would press upon the surface of the fragment (see Fig. 275 A).

‘Next, passing into the lower incision a blunt instrument (a broad raspatory), I detached from the front of the femur the soft parts lying between the incisions, consisting, of course, only of skin and fat, as the muscle was absent at that part. Then passing a strong pair of forceps from the lower incision under the skin till their blades appeared in the upper incision, I seized the ends of the wire and drew them down into the lower incision. I then drilled two holes in the lower fragment and passed the ends of the wire through them from within outwards, and, after drawing the upper fragment well down, secured them in the usual way and cut the ends short. The immediate result, so far as the frag-

ments were concerned, is indicated in this diagram (see Fig. 275 B). The incisions in the skin were then brought together by sutures and a dressing (the double cyanide gauze) applied.

'In drawing down the upper fragment I found a great advantage from the use of a very strong sharp hook, the point of which was inserted in the tendon of the quadriceps at its attachment. By this means I was able to exert much greater traction upon the bone than can be done by simply pulling upon the wire; and, in order to relax the quadriceps as much as possible, the limb was placed in the vertical position before the fragment was pulled down. The dressing having been put on, a trough of Gooch's splint was applied to the limb still in the elevated position, and the same attitude was maintained as the patient was removed to the ward, and continued by attaching the end of the splint to a rope connected with the tripod and pulley used in applying Sayre's plaster of Paris jacket. This position of the limb did not cause the patient material inconvenience, and after two or three days the rope was slackened a little so as to allow the end of the splint to come down every two days or so, till the limb could be placed quite horizontal.

'This preliminary operation is of the simplest character, no paring of the broken surfaces being done at this stage, and there being almost no bleeding and no shock. The wound having healed (I need hardly say without suppuration), the patient was allowed to leave her bed, and left the hospital soon after to practise using the limb.

'Before long she was readmitted, and the second operation was performed. The lower cicatrix was opened and the wire removed, and two interrupted wire sutures placed in the tracks of the previous continued one: the fragments, of course, being this time pared to clear them of fibrous tissue of new formation and produce smooth surfaces for coaptation. This was all satisfactorily effected, though not without the use of the powerful hook and the vertical position of the limb. The result was restoration of the use of the joint in a manner so satisfactory that I determined to try the same procedure in the other limb. The only difference which I made in this case was that, as the upper fragment was too small to bear drilling, I passed the ends of the wire, in dealing with that fragment, through the tendon of the quadriceps just above the upper border of the bone: the lower fragment, which was, of course, very substantial, being drilled as in the other limb. By this means, aided by the vertical position of the limb and the hook, I was able to bring down the upper fragment very satisfactorily, so much so that I did not feel it needful to have the patient use the limb in walking before proceeding to the second operation, but did this before she left her bed, soon after the wounds had healed. In the second operation I applied

two interrupted sutures, passing them, as in the first operation, through the track in tendon and bone which the first wire had occupied.'

After-treatment. The after-treatment of all these cases, whatever be the operation, is similar; it consists in securing at first the maximum relaxation of the quadriceps extensor by fully extending the knee-joint and flexing the extended limb upon the pelvis at an angle of 45° or less. The flexed position is maintained for a fortnight or longer, but it is relieved by gradually lowering the limb every two days by a few degrees until, at the end of the fortnight, it lies flat on the bed. Massage should then be begun and carefully practised for another ten days, at the end of which time cautious passive movements may be performed, but flexion must be very carefully carried out, as otherwise the tension upon the wires may be too great. The patella should, however, be kept from adhering to the condyles of the femur by moving this bone from side to side repeatedly, and these movements may be practised from the time that the wound has healed.

EXCISION OF THE KNEE

Indications. By excision of the knee is meant removal of the articular ends of the bone with or without the entire synovial membrane. The operation may be required for several conditions:

(i) *For tuberculous disease.* This is by far the most important condition for which excision of the knee is done. Operations for tuberculous disease of the joints, however, do not fall into the scope of this article and are dealt with by Mr. Stiles.

(ii) *For injury.* A true set excision of the knee is very rarely indeed performed for injury at the present day. Operative interference in cases of compound fracture involving the knee now takes a much more conservative form. If mechanical fixation of the fragments is deemed impossible or inadvisable the operative measures will probably be limited to removal of small portions of bone, followed by strenuous attempts to preserve the movements of the joint, which of course would be entirely lost after a set excision of the knee on account of the firm bony ankylosis that follows it.

(iii) *For ankylosis in a faulty position.* When the knee has become firmly ankylosed, either in the flexed or the hyper-extended position, the deformity will call for rectification, and this will generally take the form of an excision. The milder forms of these deformities may be remedied by a linear osteotomy, but as a rule the deformity is so great that an excision of the joint, which in reality, however, is a cunciform osteotomy, will be required before the deformity can be satisfactorily

remedied. It must be noted that excision necessarily involves the epiphyseal line in these cases, and therefore the operation should not be undertaken in those who are much under the age of twenty-one.

(iv) *For arthrodesis.* This operation (see p. 559) is very useful in many situations. In the knee, however, it is open to the serious objection that, although it gives a firm basis of support, a stiff leg is very objectionable to many and, except when a patient's means or vocation render the operation essential, some form of apparatus will probably be preferred.

(v) *For intractable suppurative arthritis.* This has been given as an indication for excision of the knee for many years. It seems, however, one of the worst possible methods of treatment for such a serious affection. Although excision may open up the joint cavity effectually and render its recesses accessible, yet it exposes a patient already gravely ill to the serious risk of infection of the large cancellous bone surfaces by virulent organisms, and it is hardly surprising that a high mortality has attended these cases in the past. Unless arthrotomy and drainage (see p. 606) are successful in bringing down the temperature and relieving the symptoms amputation should be preferred.

Operation. The chief question in excision of the knee for affections other than tuberculous disease is the best method of obtaining access to the articular ends of the bones. Clearly this is by a transverse incision across the joint over the middle of the patella, followed by division of that bone, and this is the best plan if there be no objection to division of the patella. When the operation is done in order to secure ankylosis it is immaterial whether the patella be divided or not, and therefore in the operation for arthrodesis it will be best to open the joint by this transverse incision, sawing across the patella. When operating for ankylosis in a faulty position, also, this incision will be the best. In cases of injury, however, the patella should not be divided unless this step will greatly facilitate the work, since the necessary wiring of the patella afterwards may add in some degree to the tendency to ankylosis when a movable joint is desired. In these cases of excision or partial excision for injury arthroplasty (see p. 557) may be usefully employed.

When the patella is to be preserved intact, a curved incision (see Fig. 276) extending from the back of one condyle to the corresponding point on the back of the other is made across the front of the knee. The surgeon stands somewhat to the right of and facing the knee, which is flexed at an angle of 135° . He places his left thumb and middle finger upon the two points mentioned above, and carries his knife over the front of the joint in a bold sweep with its convexity downwards, crossing the ligamentum patellæ close to its insertion into the tubercle of the

tibia. This incision is carried down to the deep fascia all round and the patella is raised in the large U-shaped flap thus marked out. This may be done either by cutting across the ligamentum patellæ about its centre and dissecting it and the patella up after opening the knee-joint, or by chiselling off the insertion of the ligament into the tuberosity of the tibia. On the whole the latter method is probably preferable, as it ensures firmer union subsequently, since the bony surfaces unite readily when replaced in contact, whereas the tendinous structures are more difficult to unite satisfactorily. The patella and the flap are raised together, the capsule of the joint being opened freely right back to the posterior limits of the incision. As this is done the assistant bends the knee and renders the articular surfaces visible. There is often free bleeding from the articular arteries, which, however, is easily controlled either by pressure forceps or by under-running and tying the bleeding points with fine catgut. The subsequent steps of the operation will vary with the condition for which the operation is being performed.

(i) **In cases of excision for injury** two courses are open. The first is to excise the articular surfaces in the orthodox manner so as to leave large surfaces which subsequently become firmly united by bone, giving the patient a stiff but strong leg.

Extensive removal of the articular surfaces. In order to do this the crucial ligaments are divided, which allows the tibia to be separated from the femur and the lower end of the latter bone to be projected from the wound. A few touches of the knife divide the remnants of the lateral ligaments and clear the end of the femur for the application of the saw. The posterior ligament, with the popliteal vessels behind it, is pushed back out of the way and is protected by a spatula which is passed in behind the bones.

The saw is applied parallel to the transverse plane of the condyles, and, in order to make the section through the shaft from front to back in the right direction, it is held so that the plane of its blade corresponds

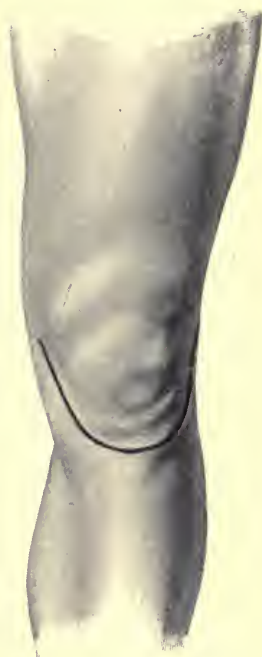

FIG. 276. INCISION FOR EXCISION OF THE KNEE.

with the transverse plane of the long axis of the leg when the joint is at an

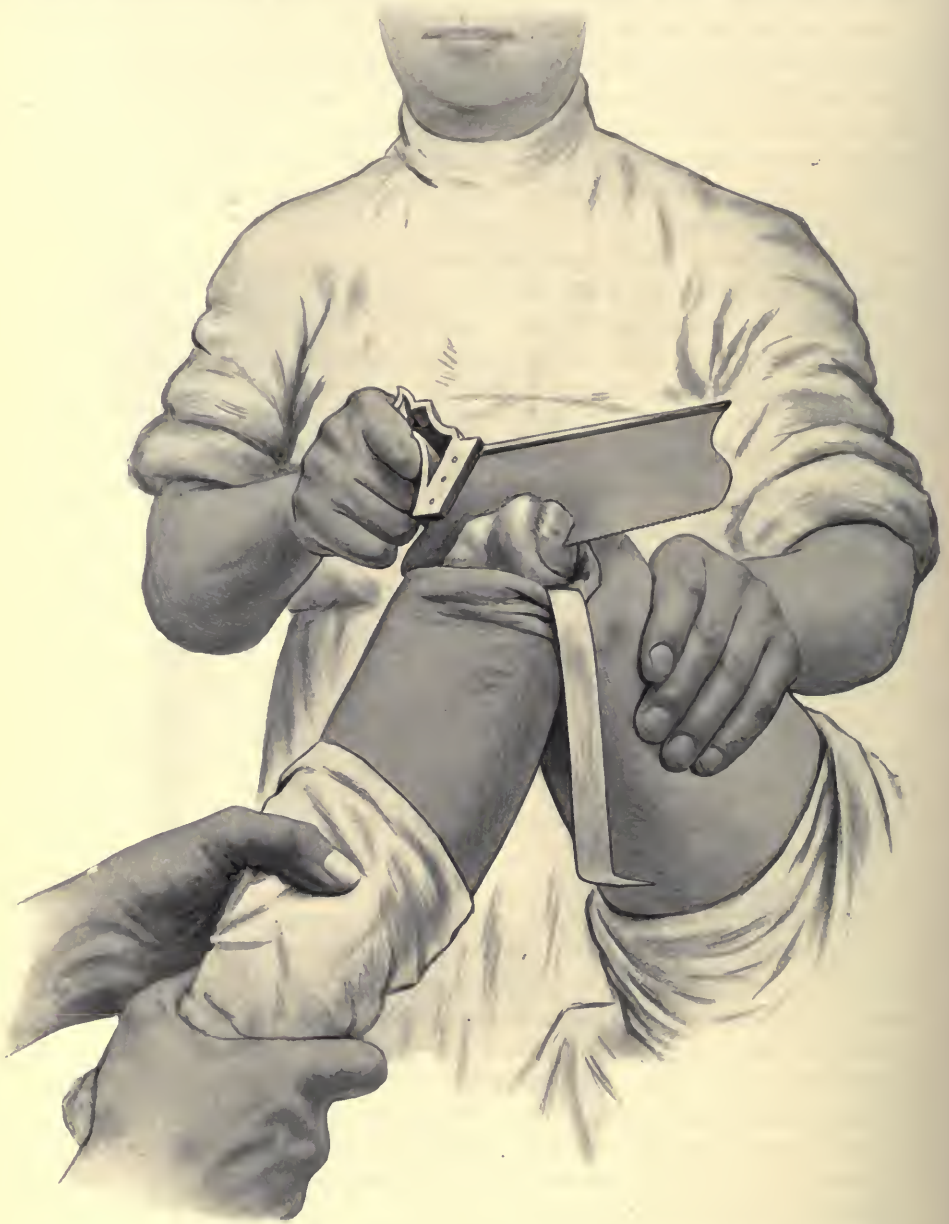

FIG. 277. SAWING THE CONDYLES OF THE FEMUR IN EXCISION OF THE KNEE. The retractor guards the soft parts at the back of the joint from injury.

angle of 135° (see Fig. 277). The amount of bone removed will vary accord-

ing to the affection for which the excision is done. The less taken away

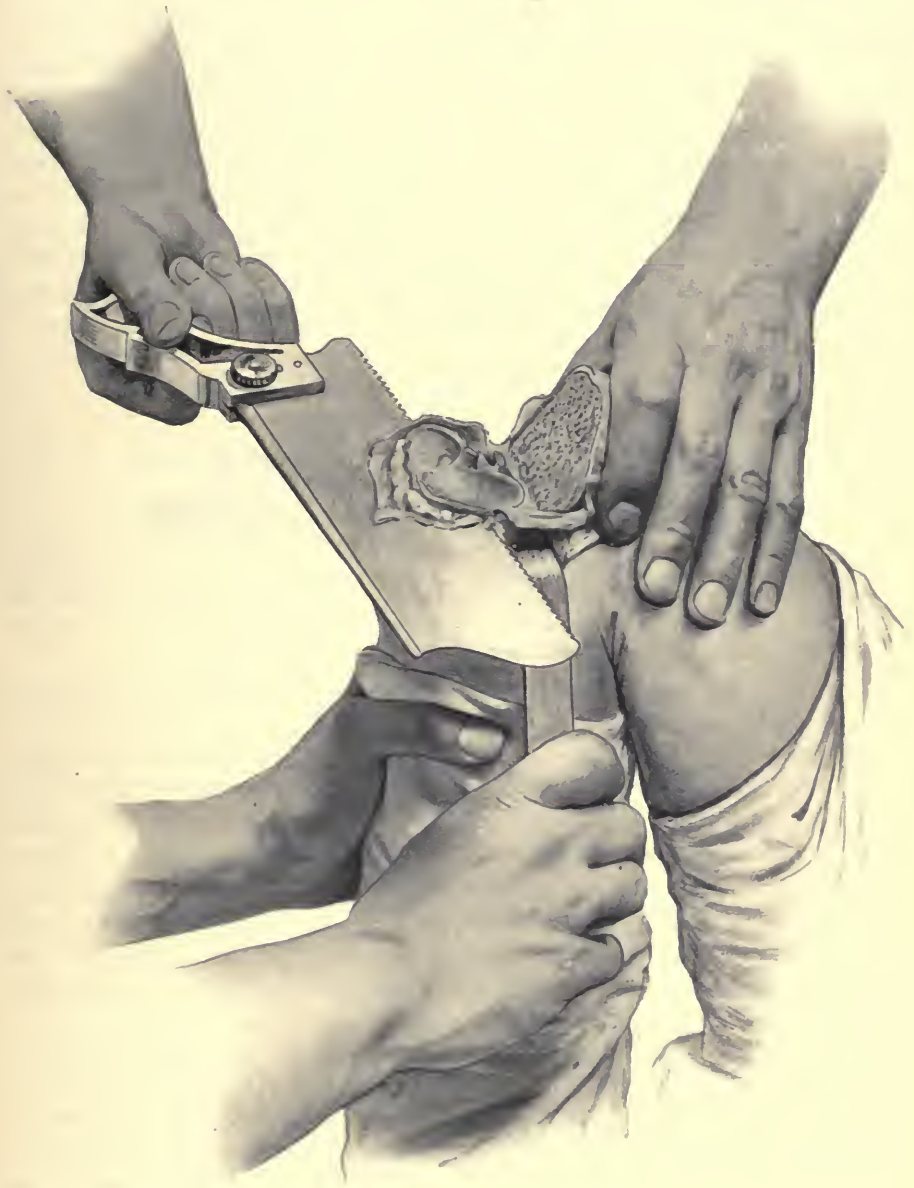

FIG. 278. SAWING THE TIBIA IN EXCISION OF THE KNEE. The sole of the foot rests flat upon the operating table.

the better, since the shortening is thereby minimized. It is never necessary

to apply the saw high enough to remove the entire cartilaginous surface on the front of the femur.

The head of the tibia is now cleared, the leg being held vertical with the sole of the foot planted firmly upon the table. It is only necessary to clear the extreme top of the tibia so as to cut a level surface; this will remove most of the cartilage together with the semilunar cartilages and the projecting spine of the tibia. The structures behind the knee-joint are not endangered in this part of the operation, as they are at some distance from the posterior margin of the articular surface. The saw is applied from before backwards, and its blade is held strictly horizontal (see Fig. 278). If the bone section has been made accurately



FIG. 279. HOWSE'S EXCISION SPLINT. The splint is of metal and can be sterilized. The narrow posterior bar lies behind the popliteal space, so that the region of the operation can be inspected without removing the splint. The latter may be fixed on by means of plaster of Paris or waxed bandages.

the cut surfaces should fit exactly when applied together, giving the knee a slight inclination inwards.

The wound is now closed, but previous to doing this many surgeons are accustomed to fasten the bone ends together by some mechanical means, such as wires, pegs, pins, or screws. There is no objection to using any of these means should it be thought desirable. The only reason that can be urged against them is that they are not necessary and there is a possibility of their having to be removed at some later date. I never use them and have never experienced any need for them. If the limb be put up accurately and immovably on a splint there is no risk of displacement, and bony union takes place rapidly and satisfactorily.

Various splints are employed; I prefer a roll of Gooch's splinting in which the limb is wedged with suitable pads. An excellent method is to employ Howse's excision splint (see Fig. 279), in which the limb can be fixed firmly and need not be disturbed for dressings. A similar splint can be made by placing a malleable iron bar along the middle line of the popliteal space and incorporating its ends in plaster of Paris bandages which surround the ankle and leg up to the middle of the calf below and the upper two-thirds of the thigh above. This leaves the whole area of the operation exposed for the change of dressings. At the

present day, however, this is of slight importance, as the dressings can be left undisturbed for three weeks, when the sutures may be removed without any risk of displacing the bone surfaces.

Union follows the usual course and the patient should be able to walk on the limb comfortably in six weeks.

The use of the Esmarch bandage is frequently advocated for this operation. I have no hesitation, however, in strongly condemning its use. It is essential for success that all bleeding shall have ceased when the limb is put up, so that there may be no collection of blood beneath the skin, no drainage tube employed, and no chance of sepsis. If the Esmarch bandage be employed, the oozing after its removal is persistent and difficult to stop. It has been advised that firm pressure by means of a bandage drawn as tightly as possible over a large mass of wool and dressing should be applied before the Esmarch is removed, so as to check the bleeding by pressure. This plan is not advisable; however efficient it may be in checking serious bleeding a certain amount of blood must necessarily be extravasated into the soft parts, and all recent experience shows the risk of sepsis from such a procedure. When no tourniquet is used the bleeding vessels can be caught up and tied as they are met with, and a dry wound at the end of the operation is thereby assured.

When only a portion of the articular surface is to be removed the chief aim will be to retain the movements of the knee. As little of the bone as possible is removed, the gouge and chisel being used in such a way as to leave the raw surfaces of bone quite smooth and of such a shape as to interfere least with movement. In order to prevent union between the raw bone surfaces some method of arthroplasty (see p. 557) may well be adopted. A flap of sufficient size, with a wide base so as to secure proper nourishment and containing as large a proportion of fat as possible, is fashioned if possible from the extra-articular structures, turned in over the raw surfaces, and fastened by fine sutures to any suitable adjacent structures. Throughout the operation the object should be to damage the joint structures as little as possible. The joint is closed as after simple arthrotomy (see p. 556), and the limb should not be put up on a splint; a firm mass of dressing should be applied to check synovial effusion, and the patient should be encouraged to move the limb.

Gentle attempts at passive movement may be made from the first, but after the fourth or fifth day it will be well to commence regular movement under anæsthesia. This will probably have to be repeated about twice a week for some time, but great pains should be taken to promote movement. Massage and passive and active movements should be practised freely and frequently.

(ii) **Excision for arthrodesis** does not require so extensive a removal of bone, as the object of the operation is to secure a stiff joint with the least amount of shortening. This can be done by merely removing the cartilage from the articular surfaces with a broad chisel or gouge. The joint is opened by a trans-patellar incision and the latter bone is sawn across. This gives good exposure of the joint, so that it may be possible to remove the cartilage without dividing the crucial ligaments, which is an advantage, as it prevents dislocation backwards of the tibia upon the femur; this, however, is not of great importance, since most of the muscles are paralysed in the cases for which arthrodesis is done and will therefore have little influence.

The cartilage should be removed from the under surfaces of each condyle with a broad chisel; some amount of bone must be taken away also in order to get a sufficiently large bony area to unite with that of the tibia. It is also well to remove all the cartilage from the patella and from its articular facet on the front of the femur. The posterior ligament is not interfered with, nor are the posterior fibres of the lateral ligaments. The two halves of the patella are united by two moderately stout catgut sutures at the end of the operation; these are sufficiently strong for the purpose, as there is no tendency to separation of the fragments owing to the paralysis for which the operation is done. The limb should be put up in the extended position in a plaster of Paris splint, which may be applied either immediately after the operation or as soon as the sutures have been removed. The tendency in these cases is for non-union to occur, and the limb may have to be kept in a rigid casing for many weeks.

(iii) **Excision for ankylosis in a faulty position.** A transverse incision should be made across the prominent angle of the deformity, and the patella divided if it be adherent to the bone. If, however, the patella be even partially movable, the incision should run below the bone and the ligamentum patellæ should be detached from its insertion into the tibia, the patella being turned upwards in the flap.

When the operation is done in young children the union between the bones will rarely be entirely bony, and it will often be possible to divide it with a chisel or knife, aided by forcible flexion of the limb. This greatly facilitates the operation, as the operator can clear the articular ends and can see exactly how much bone should be removed; the operation is also simplified, because the structures in the popliteal space can be then effectually protected from injury. No attempt should be made to straighten the limb forcibly after the ankylosis has been broken down; such a procedure is likely to end disastrously to the structures in the popliteal space, which are often shortened and adherent in their new position. Enough bone must therefore be removed in order to allow the

limb to be straightened without stretching them unduly. To do this it will probably be necessary to encroach upon the epiphyseal line of the femur, and therefore, as has already been pointed out, this operation should not be undertaken in young children or in any one under the age of eighteen. The subsequent steps of this form of the operation are exactly similar to those just described. Occasionally it may be possible to straighten the limb after removing so little bone that it will be worth while to attempt to obtain a movable joint by means of arthroplasty (see p. 557).

When the ankylosis is completely bony it will be necessary to do a cuneiform osteotomy and remove a wedge from the knee with its base forwards. The difficulty in this part of the operation is to avoid damaging the structures in the popliteal space, either when dividing the bone or when straightening the limb subsequently. The bone should be exposed by a transverse incision across the most convex part of the limb. The patella should be sawn across if it lies beneath the incision, and in any case should be removed entirely. The seat of ankylosis should be bared completely so as to allow the surgeon to estimate the amount of bone that must be removed. In case of any doubt on this point it is well to remove less than is actually necessary, as it is easy to remove more towards the end of the operation with perfect safety. In order to guard the structures in the popliteal space the soft parts are separated from the bone just around the lateral margins of the tibia opposite the point at which the apex of the wedge is to be situated, and a narrow spatula is inserted along the posterior surface of the bone on each side between it and the soft parts. The bone can now be sawn without risk of damaging the popliteal structures, since the spatula protects the soft parts laterally and the bone will fracture before the section is complete. When this has happened there is no further risk to the structures in the popliteal space, as the soft parts can be pushed back from the bone with rapidity and safety. The opposite side of the wedge is then sawn through and the desired portion of bone is removed. The limb is cautiously straightened, and if the surfaces then fit without any projection backwards in the popliteal space or tension on the posterior ligament the wound is closed and the case is treated as an ordinary excision (see p. 630). If, however, there be a projection of osteophytic outgrowths backward into the popliteal space these must be carefully trimmed away. If there be any undue tension on the structures behind, more bone must be removed until a perfect fit is obtained.

CHAPTER VII

OPERATIONS UPON THE HIP-JOINT

ARTHROTOMY OF THE HIP

Indications. The hip-joint may be exposed and opened for a large number of conditions, of which the following are the most important :—

(i) *As a preliminary to excision of the joint.* Excision of the hip is rarely performed for any other than a tuberculous affection of the joint ; this is part of the subject dealt with by Mr. Stiles. Excision of the joint for injury is very rare indeed ; if it be required, as possibly it may be in military surgery, it will probably take the form of an arthrotomy, followed by piecemeal removal of fragments of bone and smoothing off of the portion remaining. Excision may be necessary in septic suppurative arthritis due to acute epiphysitis or pyæmia ; the head of the bone may have to be removed in order to allow satisfactory drainage to be established.

(ii) It forms the first stage of the operation for re-position of a *congenital dislocation of the hip* by the open method (see p. 647).

(iii) When it is desired to rectify *ankylosis of the hip* in a faulty position it is often employed as a preliminary to division of the neck of the femur or a trans-trochanteric division of the bone.

(iv) It must be done in all those cases of *intra-capsular fracture* of the neck of the femur in which it is desired to fasten the fragments together (see p. 637).

(v) It is a preliminary stage of a cuneiform osteotomy of the neck of the femur for *coxa vara* (see p. 636).

The steps of the operations appropriate to each of the above conditions are described separately, but to avoid unnecessary repetition the operation for exposure of the neck of the bone, which is common to them all, will be described first.

Operation. The patient lies flat on his back and the surgeon stands on the outer side of the limb. It is most important that the entire thigh and buttock should be thoroughly purified and the thigh securely fastened in a sterilized towel, as free manipulation of the limb will probably be required during the course of the operation.

The incision begins at the anterior superior iliac spine and runs downwards and inwards for four or five inches parallel with the outer edge

of the sartorius, in the interval between it and the tensor fasciæ femoris. This intermuscular space leads at once down to the neck of the bone without division of any important structure. There may be fairly smart bleeding from the anastomosis of the external circumflex when the neck of the bone is reached, but this is easily stopped. The finger defines the anterior surface of the neck of the femur, when the muscles are well retracted and the capsule of the joint is opened by an incision parallel to the long axis of the neck ; whatever further steps are necessary can then be undertaken. As these vary considerably they will be described separately.

DRAINAGE OF THE HIP-JOINT

The first step towards securing efficient drainage of this joint is to remove the head of the bone. In acute suppurative affections this may be quite easy, owing to dislocation having taken place. In that case, after the joint has been opened as described above, the neck is sawn *in situ* and the head removed. The sawing is accomplished with an Adams's osteotomy saw (see Fig. 244) or a Gigli's wire saw passed round the neck of the bone, and should be done without disturbing the parts until the section of the neck is complete. The head can then be turned out with a large raspatory, and this gives free access to the front of the joint. In order to provide satisfactory drainage, however, it will be necessary to perforate the posterior part of the capsule and to insert a large drainage tube, which will project posteriorly through the skin in the post-trochanteric region. For this purpose an incision is made in the posterior part of the capsule large enough to allow the passage of a pair of long dressing forceps, which are thrust through it and made to perforate the soft parts over the back of the joint until they can be clearly felt beneath the skin of the buttock about midway between the tuber ischii and the great trochanter. They are then cut down upon through an incision about two inches long and made to protrude through the skin. Their blades are cautiously dilated and the orifice in the posterior aspect of the capsule is increased until a drainage tube as large as the thumb can be grasped by the forceps and pulled into the joint from the gluteal wound. The chief danger in doing this is in damaging the sciatic nerve, which lies in close relation to the back of the hip-joint. The only safe method is to employ large dressing forceps and to insinuate them carefully through the tissues ; they then pass to one side of the sciatic nerve, which escapes damage. The drainage tube should be long enough to pass through the joint from front to back, and the openings in it should be so arranged that one of them is at the most dependent part of the joint cavity.

The articulation is washed out thoroughly and may be douched with peroxide of hydrogen solution (10 vols. per cent.) with advantage. Antiseptic dressings are applied front and back, and a weight extension of four or five pounds should be put on so as to keep the joint cavity as widely open as possible for the purpose of drainage and also to prevent the tube being compressed by the pull of the muscles forcing the neck of the bone into the acetabulum.

As soon as drainage is satisfactorily established, which will be in about three or four days, portions may be gradually cut off the tube by pulling it out of the posterior wound and removing a quarter of an inch at each dressing, until the anterior end of the tube lies flush with the opening in the posterior part of the capsule. The anterior wound can safely be allowed to close, but drainage from the posterior wound should be kept up until all discharge has ceased, when the tube may be gradually shortened and the extension of the limb dispensed with.

OSTEOTOMY OF THE NECK OF THE FEMUR

The neck of the bone is exposed in the usual manner (see p. 634); the neck of the femur may be divided with the saw or a wedge of the bone may be removed.

Simple osteotomy. This is done with Adams's subcutaneous osteotomy saw with the minimum disturbance of the soft parts, which are protected above and below the neck by the interposition of a thin metal spatula. The section of the bone should be made as near the trochanter as possible, in order to leave a wide surface for subsequent union if this should be desired; if the section be made in the immediate neighbourhood of the head of the bone, union may not be obtained subsequently, owing to separation of the fragments. In this connexion it may be remarked that Mr. Robert Jones of Liverpool is in favour of what he terms a trans-trochanteric incision, extending obliquely from the top of the greater to the lesser trochanter; this gives a broad surface for bony union after rectification of the malposition for which the operation has been done.

Cuneiform osteotomy. This may be required for *coxa vara*. At the present day, however, this affection will rarely require operation, as extended experience tends to show that all cases in young children are amenable to treatment by appropriate splints. In them, moreover, this particular operation could have no sphere of usefulness, as the neck of the femur is too small a structure to be satisfactorily treated in this way. Should it be necessary, however, to operate upon these cases in adults, which is doubtful, cuneiform osteotomy of the neck of the

femur would be the operation of choice. The neck of the bone is exposed as described above, and more particularly that part of it from which the wedge is to be removed ; this is best determined by previous stereoscopic radiography. As a rule the base of the wedge will be at the junction of the upper with the anterior aspect of the neck. With an Adams's osteotomy saw the surgeon marks out a wedge of a suitable size and performs the section either partially or entirely with this instrument ; if there be any difficulty it may be finished with a few strokes of a broad chisel. The assistant then rotates the limb into the position in which the two cut surfaces fit one another accurately, and it is then seen whether this position returns the limb to its normal position ; if not, more bone is removed to make the surfaces fit accurately when the limb is lying flat on the table with the anterior surface of the patella looking vertically upwards.

It is well not to remove any large portion of the posterior aspect of the neck, which may be retained as a sort of hinge to prevent displacement of the divided surfaces, and it is generally advisable to make use of some method of mechanical fixation to the same end ; long pins or nails driven in through a separate incision over the outer surface of the great trochanter, when the limb is held in position by the assistant, answer admirably (see Fig. 280). The after-treatment will be similar to that of fractures of the neck of the femur (see p. 641).

OPERATIONS FOR FRACTURES OF THE NECK OF THE FEMUR

Indications In theory, operative measures designed to secure accurate approximation and fixation of the fractured surfaces are called for in all cases of intra-capsular fracture, owing to the very unsatisfactory results obtained by any other method. Occasionally, it is true, actual bony union may occur, but even this is likely to be followed by much impaired mobility of the limb, either from mal-union or from the presence of osteophytic outgrowths in the region of the head of the bone. Any operation, therefore, that can bring the fractured surfaces into accurate apposition and keep them there should be welcomed as an improvement. The truth is, however, that operative interference in fractures of the neck of the femur is often very difficult to carry out and disappointing in its results. There are many reasons for this.

In the first place the hip-joint and the neck of the femur in the adult are deeply placed, covered by structures of importance, and therefore difficult of access in a wound which does not lend itself to manipulation. It is only in spare subjects that the joint is near enough to the surface to be at all amenable to surgical procedures with ease.

A second point is that the nature of the fracture renders accurate apposition of the fragments difficult to obtain and even more difficult to maintain. When the line of fracture is near the head of the bone there is no leverage by which this can be got into good position, and even if this can be done, the subjects in which this fracture occurs have such rarified and brittle bony tissue that a fixation apparatus has not a really fair chance of keeping the fragments together. The leverage exerted by the weight of the limb is so great that displacement is very likely to occur.

Thirdly, even if union does occur, it is apt to be accompanied by the formation of so large a callus about the seat of the fracture that the movements of the limb may be seriously hampered by the mechanical contact of the callus with the acetabulum.

Finally, it must never be forgotten that the subjects of these fractures are always elderly and frequently in bad health and subject to chronic bronchitis. To them operative interference that entails the administration of an anæsthetic for a long period, and the necessarily prolonged convalescence and confinement to bed, means a risk that is not justified if good results can be obtained with early massage and the employment of a suitable splint. My own experience leads me to limit operative interference to patients who are comparatively young, spare, healthy, and active, and in whom the desire to be restored to the full vigour of life makes them willing to run some slight degree of risk.

Operation. Before operating, it is important to obtain a knowledge of the exact condition of the fracture, and for this purpose stereoscopic radiograms are essential.

The parts are thoroughly and widely purified in the usual manner, the trochanteric region and the buttock having special care devoted to them. The joint is opened and the fracture exposed in the manner already described for exposure of the neck of the bone (see p. 634). The incision should be free, and wide retraction will be required to expose the seat of fracture. A radiogram is most useful in indicating the direction in which exposure is most needed. It will probably be impossible to see the whole extent of the fracture, and it may be difficult to get the limb into proper position for fixation unless the surgeon has a clear notion of it.

In effecting apposition the greatest difficulty may be experienced in dealing with the proximal fragment, viz. the head of the bone and the adjacent portion of the neck. The distal fragment should be got out of the way by rotating the limb so as to make it clear the inner end of the fractured neck, and thus enable the surgeon to get at the head of the bone.

This must now be rotated so that, when the fractured surfaces of the neck are in apposition, the lower extremity will lie flat upon the bed with the foot pointing upwards. As there are no muscles attached to the head and neck of the femur it will remain in any position it is put, but it is often difficult to get a sufficiently firm hold of it to rotate it into the desired position.

The next step is to manipulate the lower limb so as to get the fractured surfaces into good apposition before fixing them. This is done by an assistant under the direction of the surgeon, who places the forefinger of one hand in the wound so as to ascertain the position of the fractured surfaces and the other hand upon the trochanter. When the fracture is in good position the limb is steadied and the fragments are fixed. This is the most important and the most difficult part of the operation, as the least movement may cause considerable displacement, which can neither be discovered nor rectified subsequently. Any means that may suggest themselves to the surgeon for fixing the fragments temporarily in position pending their permanent fixation should be adopted. On one occasion I have been lucky enough to be able to grasp the fragments in powerful bone forceps, such as Peters's (see p. 538), which have steadied them sufficiently to enable the neck to be drilled and pegged satisfactorily. On another occasion, when the fracture was somewhat oblique from before backwards, a bradawl run between the two fragments from front to back steadied the fracture until the long pins were inserted for permanent fixation.

Permanent fixation is best secured by pegs, pins, screws, or nails driven through from the outer surface of the great trochanter along the long axis of the neck well into the head of the bone. The application of wires, pins, screws, or nails to the neck itself is hardly to be recommended, since the leverage of the lower limb is likely to tear them from their place, while any foreign body projecting from the neck of the bone may mechanically interfere with the movements of the joint. On the whole I have found the best fixation apparatus to be stout steel knitting-needles or screws. I prefer knitting-needles, one end of which is sharpened and the other somewhat expanded so that it may be driven in with a hammer if necessary. This end projects through the skin, is enveloped in the dressings, and can therefore be removed when the surgeon deems it necessary. In order to introduce pins or screws, a vertical incision should be made over the outer surface of the great trochanter near its base, and the whole thickness of this structure is bored with a drill of suitable size from its outer surface right along the neck of the bone and into the head almost up to the cartilaginous surface. It is a good plan to make this incision in the skin and

to drill the trochanter and the outer part of the neck before apposition has been effected. The drill is made to penetrate the neck of the bone until its end just projects on the fractured surface, and as soon as the two fragments have been got into apposition it is driven on into the head of the bone and the fractured surfaces are thereby fixed. By adopting this plan it is easy to tell how far into the neck and head of the bone the drill may go with safety. The screw or pin is introduced for the requisite distance, and the fracture should then be firm (see Fig. 280). When a screw is used it is important that it should be exactly the right length, and therefore a number of different lengths should be at hand.

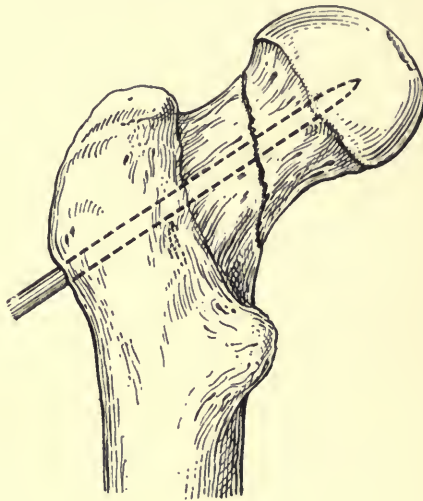


FIG. 280. DIAGRAM ILLUSTRATING THE METHOD OF PINNING FRACTURES OF THE NECK OF THE FEMUR.

Steel pins should be about eight inches in total length. If they are used, it may be possible to run in two pins parallel to each other so as to give an extra firm hold. An electrically-driven drill is of the greatest service in drilling the bone; it requires no force, and the whole attention of the assistant can be directed to keeping the limb in position without having to resist the force which the surgeon must exert in using the hand-drill.

From this time onwards the limb must be kept absolutely immovable in the corrected position, and this is one of the chief difficulties of the operation. The operation is greatly facilitated if some measures are adopted similar to those recommended for the application of a plaster of Paris splint after the operation for the re-position of congenital dislocations of the hip (see p. 651). This consists essentially in propping

the patient's pelvis on a suitable support, like a bootmaker's last, so that plaster of Paris bandages can be applied immediately the wound is closed, which should be done by an assistant, the surgeon making himself responsible for the position of the limb from the time that the pegs are inserted to the time the patient is put back to bed. If the pelvis is raised in this manner and the thorax is elevated to a corresponding height upon pillows, the application of an immovable apparatus is quite simple; if necessary, the foot can be supported on a suitable telescopic rest standing on the floor. The plaster of Paris bandage should take in the knee and should be the usual figure-of-eight spica around the pelvis. It is put on exactly as for the congenital hip operation (see p. 651), and the limb is enveloped in a bandage of boric lint under the plaster casing.

The patient is kept under the anæsthetic until the plaster has set and is left upon the table until it is moderately dry. He is then put to bed with the utmost care. No care and attention bestowed upon the later stages of these operations, including the transference to bed, can be too minute, and personal experience convinces me that it is upon the proper observance of them that the success or failure of many of these cases depends.

After-treatment. The patient should be propped up in bed as soon as possible. The hip-joint is of course fixed, but a good range of movement is allowed in the lumbar region, and this should be utilized to the full. The wound need not be looked at until about the eighteenth day, when an anæsthetic should be given, the plaster casing removed, the stitches taken out, and a fresh plaster applied; this should again take in the knee for about a week or more, after which the portion embracing the joint can be cut away so that the knee can be bent. The patient should be got up on crutches with a patten on the sound foot as soon as possible after this plaster has been applied. It will probably be possible to dispense with the plaster casing at the end of four or five weeks, but the patient should still go about on crutches with a patten on the sound foot for another three or four weeks, during which time massage and passive movements of the affected limb are employed; after this, weight may be gradually borne upon the limb.

EXCISION OF THE HIP-JOINT

There are three principal routes by which this operation can be performed, viz. by an anterior incision, which has already been dealt with fully in connexion with arthrotomy (see p. 634), and will be considered again by Mr. Stiles in connexion with tuberculous disease of the hip;

by a posterior incision, in which the structures behind the joint are divided and the back of the articulation exposed ; or by the external route, by which both surfaces of the joint can be investigated.

Of these methods the anterior route has already been described in so far as it falls within the scope of the present subject. The posterior route sacrifices muscles whose functions the surgeon is anxious to preserve if possible ; as a compensation for this it offers a very direct approach to the joint and good drainage. It might be called for in very bad tuberculous cases, but it will rarely be necessary for a non-tuberculous affection. The excision by the external incision is therefore the only one that will be described here.

EXCISION OF THE HIP-JOINT BY AN EXTERNAL INCISION

This is the method perfected by Kocher (*Operative Surgery*, trans. by Stiles, 2nd Ed., p. 360), from whom the description of the operation is taken.

Indications. There will be few non-tuberculous affections of the hip that will call for excision.

(i) In cases of bad *injury* to the joint in military surgery accompanied by extensive comminution of the upper end of the bone, it may be advisable to expose the entire neighbourhood of the joint and deal freely with it by excision.

(ii) In chronic cases of *suppurative arthritis* accompanied by sinuses and much caries the anterior incision will not suffice for proper access and safe drainage, and the external route will be preferable.

Operation. The following description follows that of Kocher very closely:—The surgeon stands on the outer side of the limb and the patient is rolled over well on to the sound side. The incision (see Fig. 281) is a somewhat curved one, running over the outer surface of the great trochanter from its base to its anterior superior angle ; thence it passes obliquely upwards and backwards, following the direction of the fibres of the gluteus maximus. Over the outer surface of the trochanter the knife divides branches of the external circumflex artery and the dense aponeurotic insertion of the gluteus maximus, while it divides the fibres of the gluteus maximus in the upper part of the incision. At this stage some vessels of considerable size will be divided and must be ligatured. The insertion of the gluteus medius is seen at the outer side of the great trochanter and that of the gluteus minimus at its anterior border ; these are detached from the bone and turned forwards. The anterior surface of the neck is now exposed, the limb being flexed and rotated outwards, and the ilio-femoral ligament is separated from the anterior inter-trochanteric line. The dissection is next carried out

on the posterior surface; the capsule is incised along the lower border of the tendon of the piriformis, the latter structure being detached from its insertion into the inner surface of the trochanter and turned backwards along with the external rotators; the periosteum covering the inner surface of the trochanter is reflected along with the muscles enumerated above.

Kocher recommends this particular method of approach because

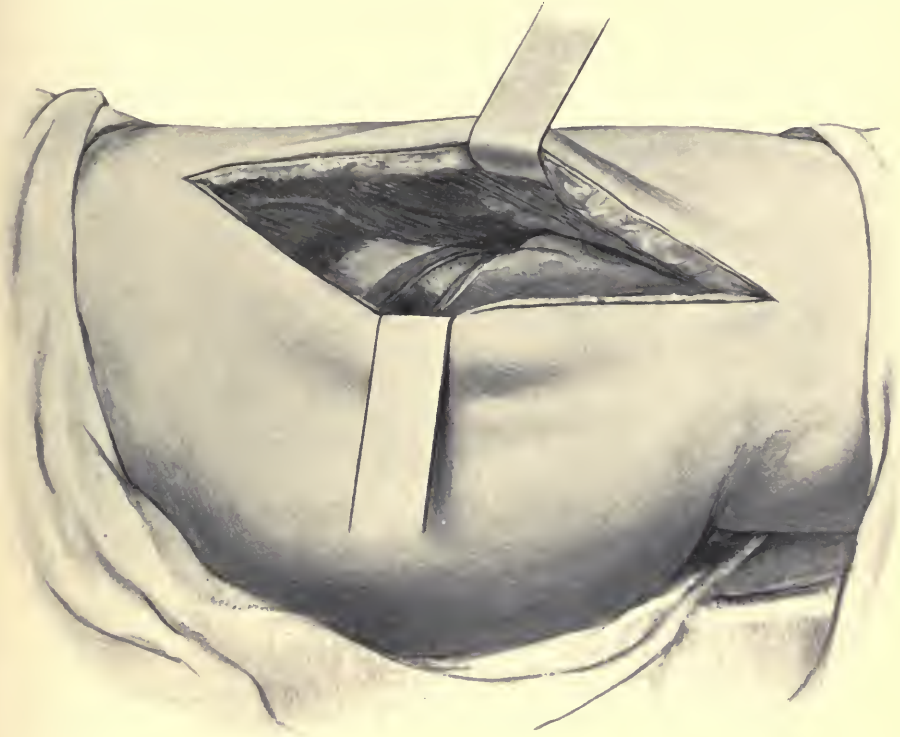


FIG. 281. EXCISION OF HIP BY KOCHER'S EXTERNAL INCISION. The muscles are separated from their attachments, exposing the neck of the bone and the capsule of the joint.

the gluteus medius and minimus muscles supplied by the superior gluteal nerve are drawn forwards and upwards towards the tensor fasciæ femoris, which has the same nerve-supply. All these muscles play an important part in the future abduction of the thigh. The gluteus maximus, the piriformis, and the obturators, which are supplied by the inferior gluteal nerve, are drawn downwards. When the joint is approached by this incision, admirable exposure of the entire posterior, external,

and anterior surfaces of the head and neck of the femur is afforded, as well as of the trochanter itself. There is very little bleeding. Branches of the internal circumflex artery will be divided in front of the neck of the femur, while the transverse branch of the external circumflex artery may also need to be ligatured as it winds round the base of the trochanter under the vastus externus. The ligamentum teres is reached and divided by cutting on to the head of the bone through the cotyloid

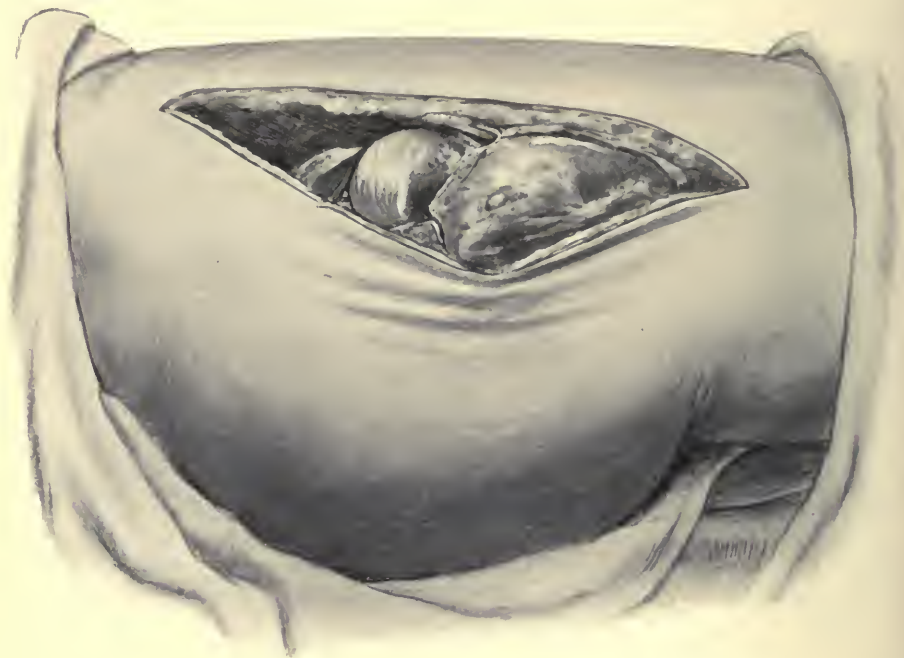

FIG. 282. EXPOSURE OF THE HEAD OF THE FEMUR IN KOCHER'S EXCISION OF THE HIP. The capsule has been opened and both sides of the neck are rendered easily accessible.

ligament from behind and below, while an assistant fully adducts, flexes, and rotates the limb inwards. The head is thereby dislocated backwards and the acetabulum rendered visible.

This free exposure enables the necessary manipulations to be carried out with ease. In cases of injury these will be removal of the shattered portions of bone and resection of the neck to the extent required to make the surfaces smooth. No more bone should be removed than is actually necessary, and the trochanteric part of the neck should be rounded off as accurately and as smoothly as possible with chisels or

gouges, in order that it may, if possible, take the place of the head of the bone which has been removed. In suppurative arthritis the neck should be sawn through quite close to the head and well rounded off after the latter has been removed. After all bleeding has been stopped, the displaced muscles are secured in position by sutures. In cases of injury the wound should be closed, without a drainage tube if possible; a tube will only be needed in compound fractures. In cases of suppurative arthritis the wound should be flushed out with 1 in 2,000 biniodide lotion, followed by a solution of 10 vols. per cent. of peroxide of hydrogen, and it is a good plan to swab the entire raw surface over with a saturated solution of chloride of zinc in order to retard the spread of the infection to the freshly cut surfaces. A large drainage tube is then inserted into the most dependent part of the joint.

After-treatment. Extension by means of weight and pulley, beginning with 4 to 5 lb., should be employed for the first fortnight; care must be taken to prevent eversion of the foot. In aseptic cases the sutures are then removed and the patient may get about on crutches, for the first fortnight in a Thomas's hip-splint and afterwards without it. In six weeks or two months after operation weight may be borne gradually upon the stump. In septic cases the drainage tube is gradually shortened until healing occurs. Much the same line of treatment is adopted as in aseptic cases, but the convalescence will be longer.

OPERATIONS FOR TRAUMATIC DISLOCATIONS

In recent cases. Strictly speaking, these operations may be divided up into those performed for recent dislocations and those for similar injuries of long standing. It is, however, rare for a recent dislocation to require operative treatment for its reduction, as manipulation under an anæsthetic almost invariably succeeds. Occasionally, however, this is not so, especially when the dislocation is complicated with a fracture either of the acetabulum or of some portion of the head or neck of the bone. Under these circumstances, which should be diagnosed with certainty by means of a stereoscopic radiogram, it will be necessary to expose the joint and effect reduction without delay.

Exposure of the joint for this purpose should be by the anterior route, since that gives the best access; the dislocation, if not primarily a posterior one, will certainly have become converted into one by the manipulations undertaken for its reduction, and the posterior route is unsuitable when the head of the bone lies behind the acetabulum. The operation need not be described in detail, since it follows the lines

already laid down for exposure of the neck of the femur (see p. 634). When the head of the bone has been exposed, the finger is introduced into the wound and the necessary manipulations for the reduction of the dislocation according to Bigelow's instructions should be carried out; any source of obstruction can be detected and removed or pulled aside. It ought not to be necessary to divide the Y-ligament or any important structures in these recent cases.

After reduction has been effected, the wound is sewn up and the limb is steadied by a long Liston's splint for about a week after the operation, when the patient may be fitted with a Thomas's hip-splint and allowed to get about on crutches. Passive movements should be begun from the second or third day and gradually increased in range and vigour. The patient should be able to walk upon the limb within a month of the operation.

In cases of long standing. It is difficult to fix the exact time at which operative interference should be preferred to attempts to reduce the dislocation by manipulations, but it is best to give the benefit in any case of doubt to operative interference, as the risk of damage to the head of the bone or to important parts in the neighbourhood during manipulation is very considerable owing to the powerful leverage that can be brought to bear by means of the lower extremity. It is probably advisable to operate upon any case of unreduced dislocation that has lasted for more than two or three weeks. The exposure of the joint adds little to the severity of the operation, while it undoubtedly simplifies re-position, since this can be performed under the direct guidance of the finger in the wound.

The operation should be done through an anterior incision. The posterior route is unsuitable because the head of the bone is always dislocated behind the acetabulum and will interfere with access to that cavity if the posterior route be chosen. The acetabulum is easily inspected through an anterior incision, on the other hand, especially if the incision be prolonged upwards so as to detach the muscles from the outer side of the ilium, and it can be prepared for the reception of the head of the bone if necessary.

There are two principal difficulties in the operation which are directly proportionate to the severity of the injury and the length of time that the dislocation has remained unreduced; they are—partial obliteration of the acetabulum and adhesions around the joint. Most writers on the subject mention the fact that the acetabulum is occupied by fibrous tissue which must be removed before the head of the bone can be got into place. The amount and consistency of this soft tissue will depend largely upon the length of time that has elapsed since the dislocation, and therefore

this serious difficulty in the operation is likely to disappear as earlier operation becomes the practice.

The presence of dense adhesions around the joint may give rise to great difficulty in replacing the head of the bone. Here again the difficulty will be proportionate to the length of time that the dislocation has remained unreduced. The adhesions may have to be divided widely, and in doing this the position of the various important structures in the neighbourhood of the head of the neck of the bone must be remembered. If the adhesions be only trivial they may be broken down by rotating the limb freely in all directions. It is better to do this after the joint has been exposed, as any bleeding it causes can be checked at once. The capsule may have to be incised freely before the head of the bone can be got into position, since it will be much contracted and distorted. The principal structure that interferes with reduction is the Y-ligament, which may have to be partially or entirely detached from the neck of the femur before the head of the bone can be got back into place. In some of the published cases the rim of the acetabulum has been found to be fractured and portions have been removed. The head of the bone should be got into place if possible by manipulation methods rather than by traction, but it may be necessary to employ firm traction of this kind by means of pulleys; this, however, will only be called for in cases of long standing with extensive adhesions and considerable shrinkage of the ligamentous structures. In cases like this the whole upper extremity of the femur may need to be separated from its muscular attachments. The ligamentum teres is torn and as a rule cannot be traced.

After the head of the bone has been got into place the remains of the capsule are sutured over it and the soft parts are brought together as accurately as possible with buried catgut sutures. The wound is sutured without a drainage tube and the limb is steadied by a long Liston's splint. The after-treatment is similar to that for recent cases (*vide supra*).

OPERATIONS FOR CONGENITAL DISLOCATIONS

There are two principal methods for replacing a congenital dislocation of the hip, viz. Lorenz's so-called 'bloodless' method, and the open operation. The former appears to be the more popular procedure at present, but in so far as it must necessarily be uncertain, since the surgeon can only guess and not see what he is doing, it is probable that, as surgeons gain more confidence in their power to treat large wounds in this region with safety, open operation will take its place, since it does with certainty what the misnamed 'bloodless operation' can only do by guess. With regard to bleeding, there is no doubt that less blood is shed in the open

operation than in the so-called 'bloodless method'; in the latter case free bleeding takes place into the tissues. Lorenz's method will not be described here, since it is not, strictly speaking, a surgical operation any more than is the setting of a fracture or the reduction of an ordinary dislocation.

Indications. (i) Operative measures are called for in congenital dislocations in children under four in which a careful attempt at re-position by Lorenz's method, checked by stereoscopic radiograms, has failed.

(ii) Operation is also required for all cases in children over the age of four as a primary measure. In these cases the alterations in the joint are so marked that experience upon the operating table shows it to be practically impossible to get the head of the bone properly into the acetabulum without a definite surgical operation. If Lorenz's manipulation be practised unsuccessfully the disturbance of the soft parts produced by it is so great as to interfere materially with the prospects of an open operation.

Operation. The writer is in the habit of dividing the operation into two stages. The first stage is the subcutaneous division of the shortened adductor muscles, which invariably offer considerable resistance to reduction and to the maintenance of the limb in position when the dislocation has been reduced. In order to avoid the severe bruising and extravasation of blood following Lorenz's manipulations the adductors are divided near their origin from the pelvis by a few sweeps of a tenotomy knife, which is inserted over the muscles as they are put on the stretch by abducting the limb. This is done a week before the main operation is undertaken, and the small wound will then have healed.

The most scrupulous care must be bestowed on the purification of the skin in these cases, and the only safe way is to purify the whole extremity as well as the groin and the buttock, as the manipulations during the operation are numerous and prolonged. The limb is enveloped in sterilized towels bandaged firmly on with a sterilized bandage wet with 1 in 2,000 biniodide solution. The child must lie upon sterilized cloths, and a sterilized towel should be pinned firmly round the waist so that there shall be no risk of the hands of the surgeon or his assistant coming into contact with unsterilized parts.

The incision, which is seen in Fig. 283, commences just below the anterior superior iliac spine, and is carried downwards and inwards between the outer margin of the sartorius and the adjacent edge of the extensor fasciæ femoris for about three inches. This incision is generally prolonged upwards parallel to and just over the outer edge of the iliac crest for about three inches. The incision below opens up the intermuscular interval which leads at once down to the neck and head of the bone. As a rule the finger feels the rounded head projecting for-

wards, as the dislocation in these young children is practically always of the anterior variety. The incision is deepened above so as to divide the extensor fasciæ femoris from its origin from the outer aspect of the ilium. This gives excellent exposure of the whole hip area, and the capsule is then incised over the head of the bone, which is made to protrude forwards through it.

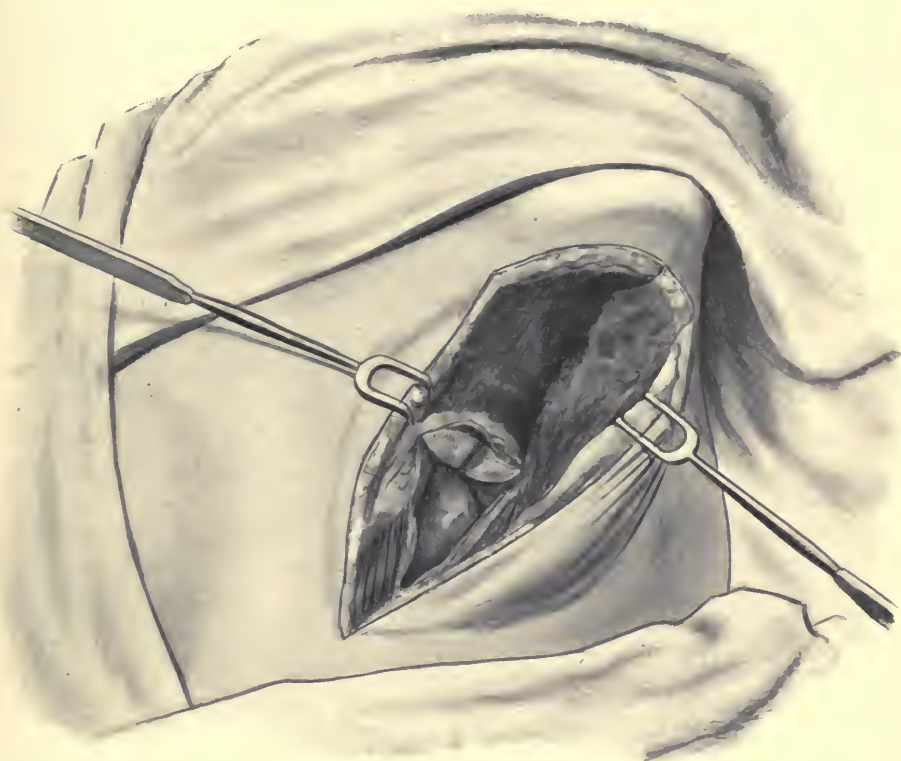


FIG. 283. ANTERIOR INCISION FOR EXPOSURE OF THE HIP-JOINT. The neck of the bone is seen exposed and the cotyloid ligament divided. The incision has been prolonged above so as to detach the tensor fasciæ femoris from its origin.

On introducing the finger through the capsule it will be found that the head of the bone has been lying in a diverticulum above and in front of the acetabulum. The latter can always be identified by the finger and there is invariably a strong band derived from the Y-ligament stretched over its anterior aspect. Between this band and the subjacent edge of the acetabulum the head of the bone has to pass before the dislocation can be reduced. The surgeon now takes the limb in

one hand and attempts to reduce the dislocation, keeping the index finger of the other hand in the acetabulum as a guide. The best way to attempt reduction is to flex the limb fully and then to abduct it to its fullest limit, circumducting the whole limb outwards whilst doing so. This manœuvre is very like that practised for the reduction of an ordinary dislocation. No set instructions can be given for these manipulations, however, as they will vary with the alterations that have taken place in the neck of the femur. As a rule this is inclined unduly forward, so that when the head of the bone is in the acetabulum the limb is in a position of marked inward rotation. It will often be necessary to detach part of the capsule from the front of the acetabulum before the aperture becomes sufficiently large for the head of the bone to pass into it. There is never any doubt as to when reduction has been effected; the head of the bone slips in with a loud click and the joint at once becomes stable and remains so as long as that position is maintained. When the head is allowed to slip out of the acetabulum there is the characteristic sucking noise, and the finger is always able to examine the joint and see if the bone is in position or not.

When reduction has thus been attained, the position of maximum stability is determined; this is the position in which the head of the bone remains in the acetabulum with the least risk of displacement, and the limb must be kept in this position throughout the rest of the operation and must be immobilized in it subsequently. This position is often similar to that in which the limb is put up after Lorenz's manipulations, but it is not by any means always so; it is chiefly dependent upon the direction of the neck of the femur. In the last case in which I operated the limb was in a position of extreme inward rotation after reduction of the dislocation. It is nearly always necessary to keep the knee flexed in order to relax the tension of the hamstrings, which are otherwise apt to shoot the head of the bone out of the acetabulum.

The limb is entrusted to the assistant, who keeps it rigidly in the correct position. As long as this position is maintained there is no fear of dislocation recurring, and the child can be moved about with ease. The least alteration of the position, however, is apt to result in a sudden reproduction of the dislocation. The wound is now closed; before doing this I usually excise as much as possible of the redundant capsule, which is now unnecessary as the head of the bone is in the acetabulum. The edges of this are brought together with stout catgut and this forms a further barrier against reproduction of the dislocation. The soft tissues are brought together over the front of the joint with a few buried catgut sutures, and the wound is sutured completely without a drainage tube after every bleeding point has been tied.

Before sewing up the wound, the child is lifted on to the special support fixed to the table that Lorenz employs for the application of his plaster casings, and is held steady on this by an assistant, folded blankets or pillows being placed under the thorax to render the trunk horizontal. It is important to do it at this stage of the proceedings, since recurrence of the dislocation might occur from a clumsy movement on the part of the assistant, and if this occur before the wound is sewn up it is quite simple to reduce the dislocation under the guidance of the finger in the wound.

The dressings are applied and fastened in position by a few turns of a sterilized spica bandage. A pair of woollen combinations is then drawn on, and outside this a plaster of Paris spica is applied, taking in the knee in the flexed position. Before applying the bandage stout whip-cord, which has been steeped in melted beeswax, is laid over the combinations in the positions in which the casing is to be sawn for subsequent removal. These serve as guides for pulling through a Gigli's wire saw, which is the speediest and best method of removing the casing. The ends of the cord should project for several inches above and below the spica so that they may be tied together after the plaster has set, and then there will be no risk of their being pulled out. The spica is strengthened over the flexure of the knee and the front of the groin by applying strands of tow, which are teased out in plaster cream; this gives the bandages a toughness that prevents them from cracking. The child is kept under the anæsthetic during the application of the plaster and is not allowed to come round until it has set, when the edges are trimmed off and he is put back to bed.

After-treatment. The stitches are removed at the end of a fortnight. In order to do this the plaster of Paris casing must be removed. Another casing is applied immediately, and the utmost care must be taken to keep the limb in its original position throughout the removal of the plaster and the stitches and the application of the fresh casing. The child should always be under anæsthesia, from which it is not allowed to recover until the bandage has set. Fresh casings will have to be applied at intervals of two or three months, the limb meanwhile being brought down into its normal position by degrees, as each fresh plaster is applied. The knee is not included in the bandage after the first four months, and at the end of the first six months the child may be allowed to get about, the limb being still somewhat abducted. If the heel of the boot on the sound side be a little thickened it will tend to diminish the chance of the head of the bone slipping out of place. For further information upon this subject the reader may consult a paper by the author in the *Brit. Med. Journ.*, 1903, vol. ii.

SECTION IX
PLASTIC SURGERY

BY

T. P. LEGG, M.S. (Lond.), F.R.C.S. (Eng.)
Surgeon to the Royal Free Hospital

CHAPTER I

GENERAL PRINCIPLES : SKIN-GRAFTING

PLASTIC SURGERY is the method by which a surgeon attempts to remedy some deformity or to restore, as far as possible, a lost portion of the body. It is also the means by which a surgeon attempts to repair an organ, or some part of it essential to the carrying on of its proper function, which may have been accidentally damaged or injured as the result of some operative procedure. For centuries, plastic operations on the face have been performed. The operation of rhinoplasty appears to have been known to and practised by the ancient Egyptians. The Indian method dates from very early times, and the Italian (Tagliacotian) method from the year 1597, but it is only since the early part of the last century that the development of plastic surgery may be said to have taken place. In 1869 Reverdin published his method of skin-grafting ; afterwards, Thiersch, using large grafts, obtained more satisfactory results and further added to the advancement of this branch of surgery, which until quite recent years was concerned with the restoration of a defect which was on the surface of the body. At the present time the internal organs have plastic operations performed on them, and even the blood-vessels have been successfully sutured after having been partially divided.

GENERAL PRINCIPLES

Sound and rapid healing is essential for the successful performance of plastic operations. The patient must be in the best possible state of health, and the neighbouring tissues free from disease. These operations must be deferred, therefore, till such conditions are present. Failure to obtain the desired effect by the first operation makes subsequent attempts less likely to succeed, as such failures always leave behind scar tissue. The best results are obtained with fresh, healthy structures, and though it is possible to succeed even when a certain amount of scar tissue is present, the ultimate result is never so satisfactory as when working with the normal tissues. In some cases scar tissue may have to be utilized, but it can never be relied upon ; in other cases, the local conditions may render a repetition of the operation impossible ; moreover,

it is possible that an unsuccessful plastic operation may leave the patient in a worse condition than that before it was attempted.

An attempt to do too much at one operation is another source of failure. It is better to avoid trying to attain the total restoration of a defect when the tissues are scanty and to proceed by stages rather than to risk a complete failure as the result of one operation. By a series of operations, and by allowing a sufficiently long interval to elapse

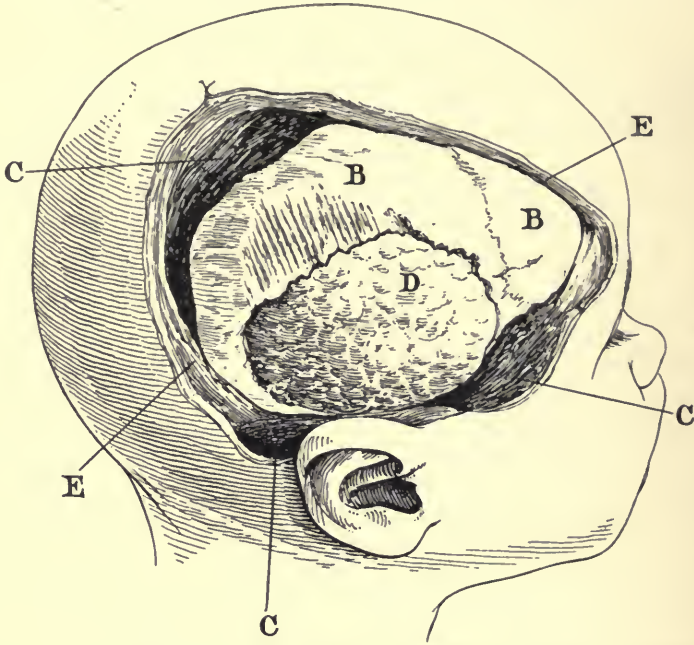


FIG. 284. CLOSURE OF A LARGE DEFECT BY MEANS OF FLAPS. The patient was a boy aged two years, who had a large part of his scalp torn off as a result of a street accident. B, B are the cranial bones. D is the dura mater exposed by the removal of a large part of the squamous portion of the temporal bone, which was extensively fractured and depressed, and ingrained with dirt. The dura is shown covered with granulations. C, C, C are the deeper tissues of the scalp and pericranium; E, E, the edges of wound in the scalp. (From a photograph.) See also Fig. 285.

between them, it is sometimes possible to make use of the same tissues over again. It is courting failure to attempt plastic surgery on the aged or very feeble, or in the neighbourhood of active disease, *e.g.* syphilis or tubercle, but provided these diseases are cured or quiescent, excellent results may be obtained.

Septic infection is another potent cause of failure, and therefore special attention must be paid to the details of asepsis in these operations.

Methods of cutting and using flaps. Each particular case has to be treated on its merits, success often depending on the ingenuity of the operator. Flaps must be thick and include the subcutaneous tissue, but not as a rule the deep fascia, so that their vitality is not impaired. Besides the skin, flaps containing other structures, such as

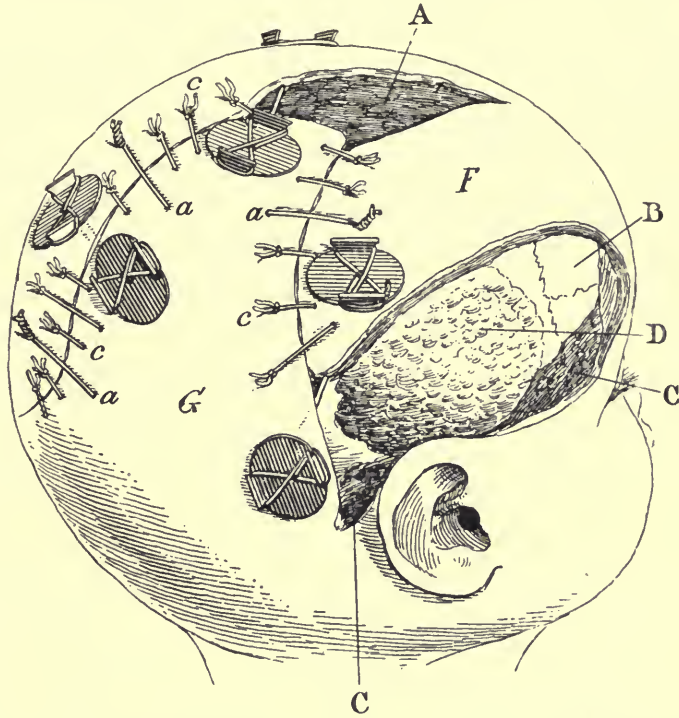


FIG. 285. METHOD OF CLOSING A LARGE DEFECT BY MEANS OF FLAPS. (*Author's case.*) The incisions marking out the flaps are parallel to the lines of the vessels. The flap F was taken from the fronto-parietal region, and the flap G from the occipital region, each being glided into its new position. They contained all the layers of the scalp except the pericranium, A, which is exposed. *a, a, a* are silver wire sutures; *c, c, c*, silkworm-gut sutures. The method of using silver wire and lead buttons is also shown. By subsequent operations the defect was closed more completely. (*From a photograph.*)

bone or periosteum, are occasionally employed, as in some of the operations for restoration of the nose. In cutting a flap, it is better, whenever possible, to use curved rather than straight incisions; more tissue is in this way obtained, and there is consequently much less tension when it is fixed in position. The incisions marking out the flap should be made parallel to the line of the blood-vessels, or placed so as to interfere with the vascular supply as little as possible (Fig. 285). The knife must be

directed towards the deep fascia so that the blood-supply to the skin, which is derived from the subcutaneous tissues, is not cut off, and care should be taken that the flap is neither button-holed nor scored on its deep aspect. Its length is proportional to the width of the pedicle, which should be as broad as is consistent with the flap being accurately and readily applied in its new position; in doing so the pedicle must not be twisted or stretched to such an extent as to occlude the blood-vessels.

The raw area from which the flap has been taken is closed by undermining the adjacent skin and subcutaneous tissues, or by skin-grafting.

The method most frequently employed is to simply *glide* the flap obtained from the neighbourhood of the defect into its new position, where it is fixed by sutures (Fig. 285); extensive wounds, such as those left by the removal of the breast for carcinoma, malignant disease of the cheek, &c., are frequently closed in this manner. Sometimes the flap is *transplanted* from another part of the body; the extent and completeness of the union with the surrounding tissues, especially at the distal end of the flap, determines the time when it is safe to sever the pedicle; on an average this is in ten or fourteen days. The flap gradually adjusts itself to its new surroundings, and there is ultimately no difference in the sensibility of it and that of the adjacent parts, but secondary operations are frequently necessary to correct various irregularities in the flap.

Flaps may also be employed in three other ways. *The reversed flap*, in which the cuticle is directed inwards and the deep surface outwards, the latter being covered by skin grafts. *Superimposed or double flaps* (Fig. 328, p. 713); the outer or raw surface of a reversed flap is covered by a second flap with its cuticle directed outwards, the two flaps having their raw surfaces in apposition. Instead of a superimposed flap, the first one may be folded on itself after the pedicle has been divided (Fig. 327, p. 711). *Granulating flaps*; the flap is dissected up, but is left attached by both its extremities for some ten to fourteen days, or longer if necessary. During this time, *i. e.* whilst it is granulating, the deep surface of the flap is prevented from uniting to the adjacent tissues, by the insertion of a sterilized piece of protective. The vitality of the flap in its new position is more likely to be assured after the pedicle is divided if its deeper parts are granulating. This method of using a flap has some advantages. In the first place, it may be cut much longer in proportion to its width, without fear of sloughing; as a rule the length should not exceed three times its width, these dimensions being marked out according to the size of the area to be covered, due allowance being made for shrinkage. The limits of the flap having been determined, it is dissected up freely, carefully, and completely throughout

its whole extent down to the deep fascia or aponeurosis. At the end of ten to fourteen days the flap will have become thick and vascular; one pedicle may then be divided and the flap turned into the place prepared for its reception. Secondly, such a flap will adhere in a short time if care is taken to excise and divide every portion of cicatricial tissue and to have a freshly made raw surface; two weeks is an average time for adequate vascular union to occur in its new position, but the final severance of the flap is a matter of some importance and must depend on the amount and soundness of the union which has taken place. The disadvantage of this method of 'granulating flaps' is that it is very complicated and cannot often be employed.

In the *Indian and French methods* the flap is taken from the parts adjacent to the area to be occupied by it. In the *Italian (Tagliacotian) method* the flap is derived from a distal part, such as one of the arms.

Whenever a flap is being used to close a cicatrizing area, the scar tissue must be removed and the edges carefully refreshed so that everywhere there is a fresh raw surface on which to place it. At the same time care must be taken not to remove too much of the scar tissue without some good reason. Immediate and secure union of the refreshed surfaces with the flap is most essential, and therefore they must be carefully fixed in position by sutures with a minimum amount of tension. If the edges are not in perfect apposition at all points a good result may still be obtained, and attempts to obtain a complete apposition should not be made at the expense of undue tension or dragging on the flap. The position of the flap is maintained by sutures, with or without some form of retentive apparatus (as in the Tagliacotian operations).

Methods of suturing. The suturing is most important, and a good deal of the success or want of success of a plastic operation depends on this factor. Of the many materials used for sutures, silkworm-gut and silver wire are the best. Catgut may be used for buried sutures and for uniting mucous membranes. The great advantage of silkworm-gut is that it does not absorb moisture, and is only slightly irritating unless tied tightly. Fine horsehair, sterilized by boiling, may be used for delicate tissues, whenever it is important to avoid stitch marks and when the parts can be readily brought into apposition, but fine silkworm-gut is equally efficient. Whatever material is chosen, all sutures should be just tight enough to hold the parts in apposition, and there must be no tension or dragging after they are tied.

As soon as the knot is tied the effect on the flap and skin should be noticed. Any suture which is causing tension produces an area of whiteness, which persists in the parts adjacent to it. If a suture is not tied too tightly the blanching which follows its insertion passes away

in a few minutes, and is followed by a red blush. After the operation there is always some swelling of the flap and tissues around it; a stitch, therefore, which appears to be slack, will become tighter, and if any are tied too tightly, a zone of inflammation with a greater degree of swelling will follow. The pressure of the stitch may lead to a local

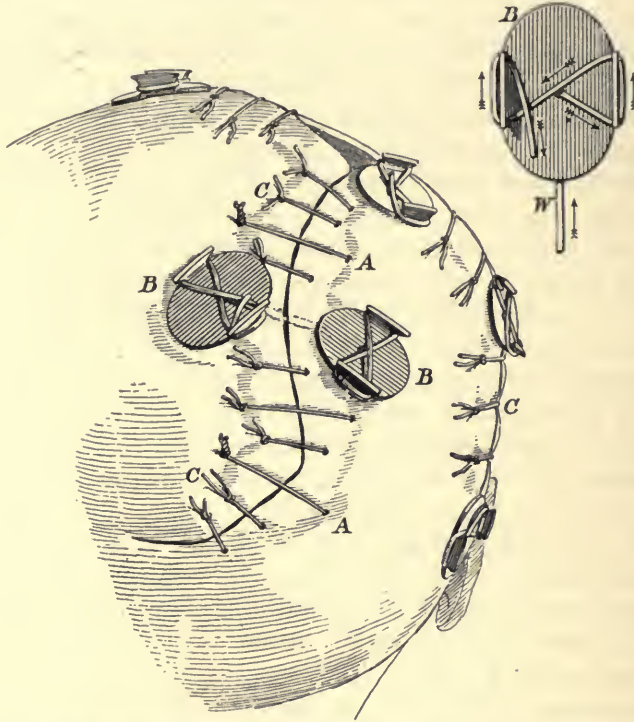


FIG. 286. DIFFERENT METHODS OF USING SUTURES. A, A are silver wires used as deep sutures, and passed some distance from the edges. The ends of the wire are twisted round one another. B, B are 'relief of tension', or 'relaxation' sutures, fastened to leaden buttons. The smaller figure shows more clearly how the wire, w, is fastened to the button. c, c, c are the superficial, or 'stitches of apposition', passed not far from the edges. Instead of being interrupted, it is often preferable to put them in as a continuous stitch. There should be no tension at all on these stitches.

sloughing, and therefore prevent primary union, and should this happen around several of them, a considerable area of the flap may be destroyed. Under these circumstances, the advent of sepsis is not infrequent and further sloughing takes place, resulting in complete or partial failure of the operation.

It is often necessary to use *deep* or '*relief of tension*' stitches in addition to those uniting the edges. They should be passed at some dis-

tance from the margins (Figs. 285 and 286) and tied only just tight enough to bring the deep parts into apposition. Silver wire may be employed for these stitches. The ends of the wire may be passed through a leaden button and fixed by fastening them to the button in 'a figure-of-eight', or they may be loosely twisted round one another (see Figs. 285 and 286). Under each button a pad of gauze must be placed to prevent local sloughing from its pressure. In the absence of the silver wire and buttons, stout silkworm-gut, fastened to small pieces of india-rubber tubing, does excellently (Fig. 287). When these sutures are applied it is generally possible to bring the edges together without tension by the *superficial stitches* or *stitches of apposition*. If they cannot be completely united, as much as possible should be sutured, and the unclosed portions will heal by granu-

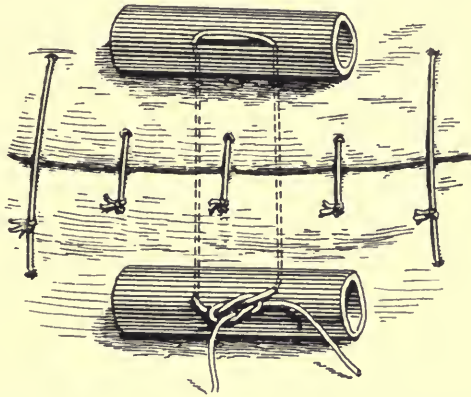


FIG. 287. THE METHOD OF USING INDIA-RUBBER TUBING AND SILKWORM-GUT AS 'RELIEF OF TENSION' SUTURES. The gut is first passed through one piece of the tubing, then through the tissues, and finally through the other piece of tubing. As it is tightened, the edges of the raw area will be approximated, and they are then united by the superficial sutures.

lating, or if an area of some size remains, it may be skin-grafted. In passing the sutures, those should be inserted first which bring the important points opposite to one another and all the deep before the superficial ones.

The deep and 'relief of tension' stitches may be removed about the fourth or fifth day; as a rule they should not be left longer than a week. A little local ulceration may follow from the pressure of the button, if one is used. The remaining stitches are removed when the edges appear to be firmly united, or at such times as may appear to be advisable.

When the flap is taken from a distal portion of the body, such as a limb, it is necessary to fix the limb to the part being restored. A special apparatus may be required, or a casing of plaster of Paris may be employed. Trials should be made before the operation is performed in

order to find the most comfortable and tolerable position of the limb, and the pedicle in these cases should be wide, so that the flap may be as long as possible and capable of being adjusted without tension.

THE CLOSURE OF TRIANGULAR GAPS

1. If the gap is small and forms an equilateral triangle, the edges may be brought into apposition simply by undercutting them.

2. If the gap is large, one of the following methods may be used:—

(a) An incision BD continues the side AB . The triangular flap CBD , consisting of skin and subcutaneous tissue, is then dissected up to allow BC to be sutured to AC (Fig. 288).

(b) If one flap is not sufficient, another similar flap, EAC , may be raised

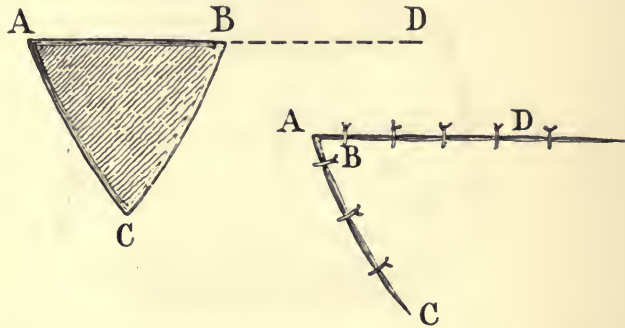


FIG. 288. METHOD OF CLOSING A TRIANGULAR GAP OF SMALL SIZE. By making an incision, BD , the flap CBD can be raised so as to allow BC and AC to be united by sutures, as in the figure. More accurate apposition may be obtained by the use of a continuous suture.

from the opposite side of the triangle and the edges AC and BC brought together in the middle of the gap. If there is much tension on the flaps, parallel incisions may be made beyond the points D and E . When the flaps are in position, oval-shaped gaps are left which will heal by granulation, or these may be closed by further undercutting the tissues around them (Fig. 289).

(c) Instead of a straight incision, a curved incision, as in Fig. 290, p. 664, is often preferable for marking out the flaps when the defect is large, and when it is desirable to have a scar as little evident as possible.

THE CLOSURE OF QUADRILATERAL GAPS

A gap, $ABCD$, may be closed by making the incisions BE and DF and dissecting up the flap $EBDF$ so that BD and AC can be united by stitches (Fig. 292, p. 665). If one flap is insufficient, a second flap, $GACH$,

may be obtained from the opposite side of the gap by making the incisions GA and HC and sliding the two flaps inwards over the gap, so that AC and BD meet, and are united by sutures. These incisions must be sufficiently long to allow the flaps to meet without tension (Fig. 293, p. 666).

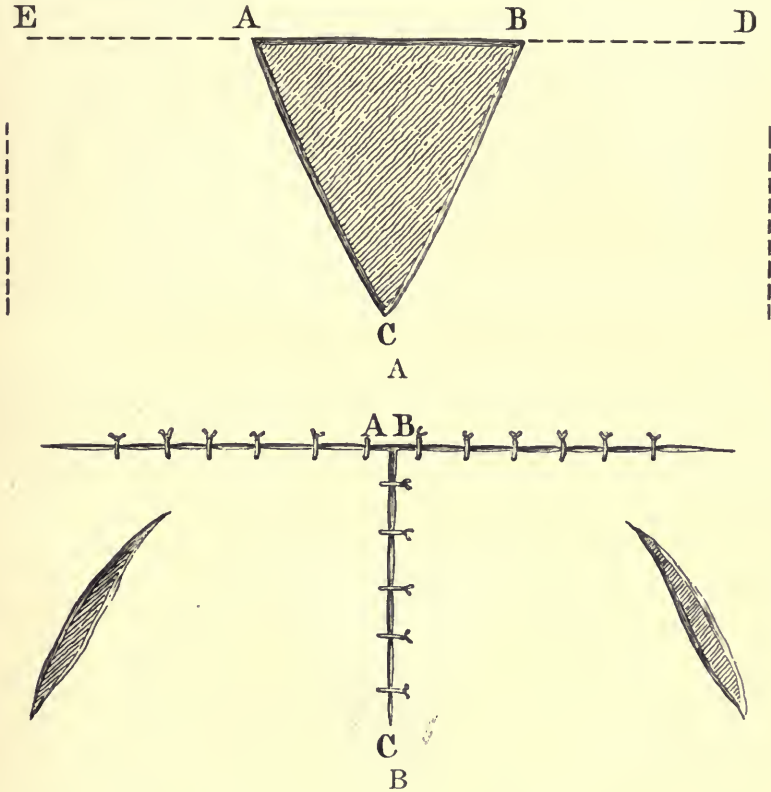


FIG. 289. METHOD OF CLOSING A TRIANGULAR GAP OF LARGE SIZE. In A the lines EA and BD represent the incisions made to allow of the flaps EAC and DBC being raised, so that AC and BC may be united by sutures as in B. If there is much tension on the flaps, incisions, in A represented by the vertical dotted lines, may be made to allow the edges to be readily approximated, and the oval-shaped gaps left by making these incisions are shown in B.

THE CLOSURE OF ELLIPTICAL GAPS

This may often be effected by simply undermining the skin around the edges of the gap (Fig. 294, p. 667), or by means of a curved incision, EDF , parallel to one of its margins. An incision CD divides the area $EABF$ into two flaps, $EDCA$ and $FDCB$, which are glided over the raw area so that AC and BC are united to the edge AGB (Fig. 295, p. 668).

In the closure of any defect, attention must be paid to the following points: (1) As far as possible the incisions should be made parallel to the lines of the vessels, and the division of important nutrient arteries must

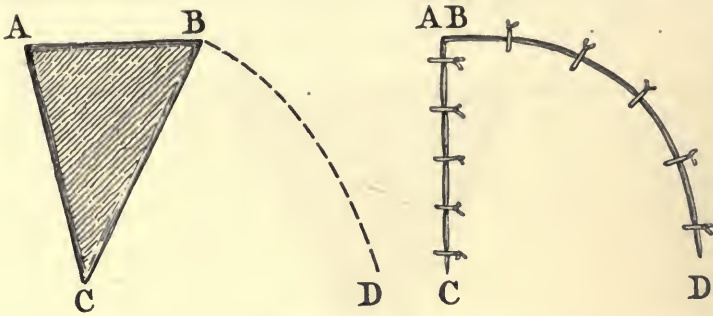


FIG. 290. METHOD OF CLOSING A TRIANGULAR GAP BY USING A CURVED INCISION. The flap CBD is dissected up and BC united to AC.

be avoided; (2) the incisions should be made in the natural lines of cleavage of the skin; the scars will then be least visible; (3) free undercutting of the adjacent subcutaneous tissue, provided the whole or greater part of it is taken up and the skin is not scored on its deep aspect.

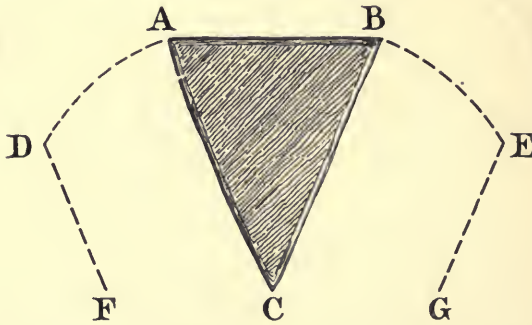


FIG. 291. METHOD OF CLOSING A LARGE TRIANGULAR DEFECT BY MEANS OF FLAPS. A quadrilateral flap, FDAC and GEBC, is raised on each side of the defect and then glided inwards, so that AC and BC are in contact and united by sutures.

SKIN-GRAFTING

Skin-grafting is one of the most important and widely applicable forms of plastic surgery. It may be used when other methods are not suitable or available, or in conjunction with them, and is most valuable in obtaining rapid and sound healing, not only of granulating wounds

but also of large freshly-made wounds, which cannot otherwise be closed. It is often required when large raw surfaces are left, such as follow burns, sloughing of the skin after cellulitis and injuries, ulcers, extensive lupus, and the large wounds remaining after removal of a rodent ulcer or a cancer of the breast, &c. In such cases, a sound supple scar is desirable, and whenever it is important to avoid contraction, one of the methods of skin-grafting may be employed. To obtain these

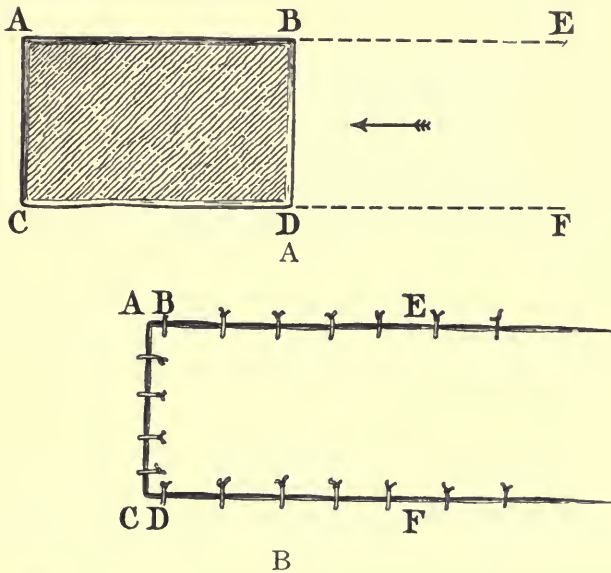


FIG. 292. METHOD OF CLOSING A SMALL QUADRILATERAL DEFECT. A. The incisions BE and DF are made, continuing the sides AB and CD of the gap outwards into the surrounding tissues. A flap, EBD, is raised sufficiently freely to allow BD to be sutured to AC without tension. This is accomplished by making BE and DF longer than they are here represented.

B. The flap is in position, and its edges are sutured to those of the defect.

results it is essential to carry out the operation with great attention to the principles which underlie its successful performance. Moreover the general state of health of the patient plays an important part, and unless all these details are attended to, the result will be a failure.

The first point is that the raw surface to be grafted must be healthy, or if it be an ulcer, it must have commenced to heal, as shown by the presence of a thin bluish-red epithelial line at its edges. When these conditions are present, the sooner the raw area is grafted the better will be the ultimate result, because the amount of contraction will be the least possible. A large raw surface left by the removal of a tumour may be grafted at once. It is useless to attempt to graft a septic ulcer or wound.

Secondly, the tissues in the neighbourhood of the area to be grafted must be in a healthy condition. If they are congested or inflamed, or otherwise diseased, the grafts are certain not to take, and therefore, before the operation is undertaken, every means must be employed to get the parts into a healthy condition. It is well recognized that many ulcers show no signs of healing so long as the surrounding tissues are diseased. This may be due to local and general causes, and before undertaking skin-grafting any such influences must be

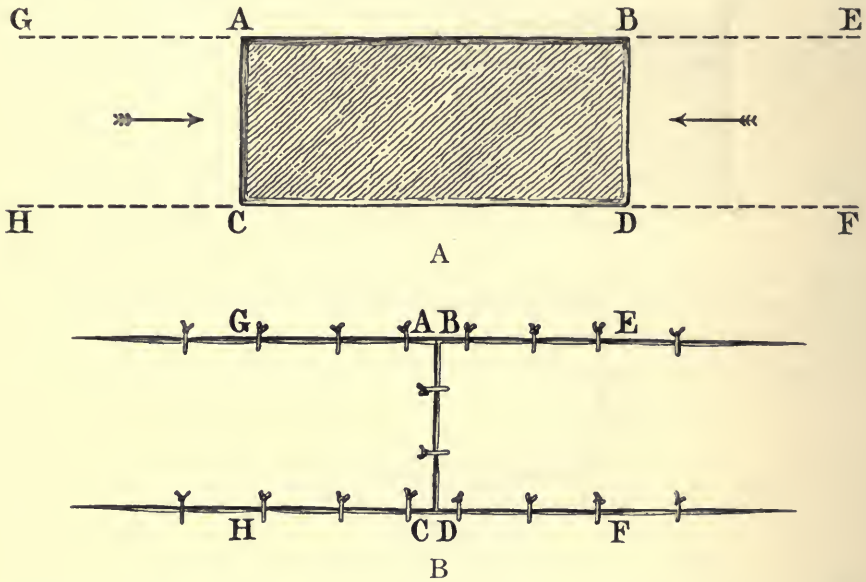


FIG. 293. METHOD OF CLOSING A LARGE QUADRILATERAL DEFECT. A. Two flaps (one from each side of the defect) are dissected up, in a manner similar to that shown in Fig. 292. B. They are then pulled towards the centre of the defect and the apposing edges sutured.

remedied; thus, in the case of a chronic ulcer of the leg, varicose veins may require removal, or if the ulcer is due to tertiary syphilis, the patient must be given anti-syphilitic remedies. Tertiary syphilis in itself is not necessarily a contra-indication to skin-grafting, and very successful results may be obtained in such patients provided the general health of the patient and local conditions are satisfactory. In fact, it may be said that if the ulcer shows signs of healing as evidenced by the state of the edges, the patient's general health is such that the grafting will probably be successful. In old and feeble patients with a poor circulation, or in diabetics or those with extensive disease of the lungs, skin-grafting will not succeed.

Thirdly, the situation of the raw surface to be grafted has an important bearing on the result. Absolute rest and firm pressure are essential to success, and therefore in parts of the body, such as the limbs, a successful result is more frequent than where immobility is less easy to secure, *e. g.* the neck and back. In the neighbourhood of joints, excellent and permanent results may be obtained provided that care is taken to prevent movements being carried out too soon after the

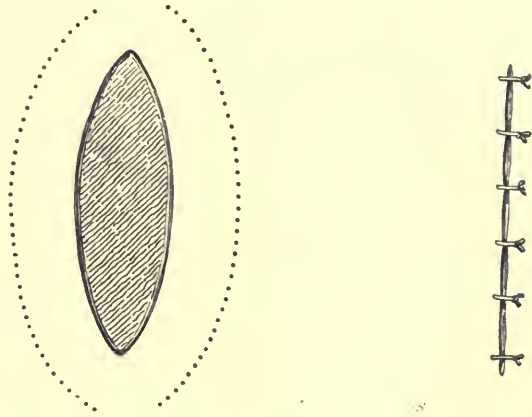


FIG. 294. THE CLOSURE OF AN ELLIPTICAL AREA BY UNDERMINING THE SKIN AND SUBCUTANEOUS TISSUES AROUND IT. The dotted lines indicate the extent to which this should be done. The edges are then united by a continuous or interrupted suture.

raw surface has been grafted and healed. Lastly, the after-treatment is most important.

The principles of the operation itself may be considered under the following heads :—

1. The preparation of the raw area to be grafted, and of the area from which the grafts are to be taken.
2. The method of grafting.
3. The after-treatment.

The preparation of the raw area to be grafted. It has been pointed out that the raw area must be as aseptic as possible and therefore means must be taken to obtain this condition. The surrounding skin must be shaved and thoroughly washed with ether soap and water, or ordinary soap and turpentine may be used, the parts being thoroughly scrubbed with a nail-brush. The skin is then washed with 1 in 500 biniodide of mercury in spirit and afterwards with 1 in 2,000 perchloride of mercury lotion. If an ulcer, hot fomentations are applied and

changed every three or four hours. The fomentations may be made with boro-glyceride, sanitas and water, or chlorinated soda if the ulcer is very foul.

The use of strong germicides may be discussed here. There is no doubt that these are very efficacious in destroying septic granulations, but they also impair the vitality of the underlying healthy tissues, and should therefore be only used sparingly and at the commencement of the preparatory treatment. It is unnecessary to use any such agents when the ulcer is

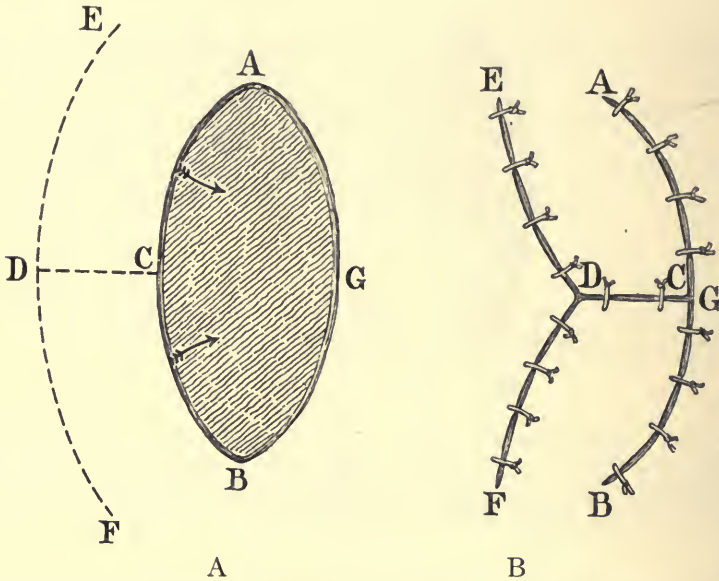


FIG. 295. CLOSURE OF A LARGE ELLIPTICAL AREA BY MEANS OF FLAPS. In A the curved incision EDF is made parallel to the edge ACB, and the intervening portion of skin and subcutaneous tissue is divided by the incision DC into two flaps, which are glided over the raw area, and sutured as in B. The tissues on the outer side of EDF and AGB may require to be undermined, so that the edges may be sutured without tension.

not very foul ; they lower the vitality of the young growing cells and render them more susceptible to any micro-organisms which may gain access to the wound. Of these powerful germicides, undiluted carbolic acid is the best : it is applied by dipping a small piece of sponge or wool into the acid, thoroughly rubbing the surface of the granulations and edges of the ulcer, and allowing it to act for some minutes. A good deal of pain is temporarily produced, but it passes off in a short time. Another efficacious way of getting rid of the foul granulations is to scrape them with a sharp spoon, whilst the patient is under a general anæsthetic.

Whilst the preparatory treatment is being carried out, every

means should be taken to improve the local conditions, the skin surrounding the ulcer being regularly washed and disinfected. Eighteen or twenty-four hours previous to the operation, the whole region is again purified and enveloped in a dressing of sterilized gauze, wrung out of 1 in 2,000 perchloride of mercury, covered with protective and bandaged.

The preparation of the area from which the grafts are to be taken. The area from which the grafts are taken should be as free from hairs as possible. The front of the thigh, the flexor aspect of the arm or forearm, will therefore usually be the sites selected. The skin must be thoroughly disinfected by scrubbing with ether soap, spirit and biniodide lotion (1 in 500), followed by 1 in 2,000 perchloride, and then a dressing wrung out of the latter lotion and covered with gutta-percha tissue is put on. It is advisable to do this preparation forty-eight hours before the operation, and to repeat it in twenty-four hours' time.

The method of grafting. Under this heading the following points have to be considered :—

1. The final preparation of the ulcer.
2. The cutting of the grafts.
3. The dressing and after-treatment.

1. The final preparation of the ulcer. The patient having been anæsthetized, the ulcer is first scraped with a sharp spoon, to remove the soft granulations and to leave a smooth, raw, even bed of new-formed fibrous tissue. The edges of the ulcer must be removed at the same time, either by scraping or cutting them away. The raw surface bleeds freely, and it is essential to arrest the hæmorrhage, after having first washed away the separated granulation tissue by douching with 1 in 2,000 perchloride of mercury lotion, followed by sterilized normal saline solution. Pressure is the most efficient means of arresting the bleeding. A sufficiently large piece of dextrinized protective or gutta-percha tissue, which has previously been sterilized by keeping it for a prolonged time in 1 in 20 carbolic acid lotion, is laid flat on the raw surface and covered by layers of gauze. A sterilized bandage is then firmly applied outside the gauze, or, if the area is small, an assistant can make the desired pressure manually. It is well to make some small holes in the protective, which must be rinsed in sterilized salt solution or boracic acid lotion before it is used. The protective or gutta-percha tissue is applied to the raw surface in preference to making direct pressure by gauze, because the latter adheres to the raw surfaces, and when removed fresh bleeding occurs. One of the most essential points to be attended to is that there should be no oozing going on when the grafts are placed in position.

Whilst the hæmorrhage is being arrested, the grafts are prepared, but before doing this it is advisable for the operator to thoroughly disinfect his hands or to put on sterilized gloves and during the remainder of the operation to use sterilized salt solution or dilute boracic acid lotion.

2. The cutting of the grafts. There are three methods of cutting the grafts: (1) *Thiersch's*, (2) *Reverdin's*, (3) *Wolfe's*. Thiersch's is the best and most widely applicable method, but there are occasions when it may be desirable to use one of the other methods. Whichever

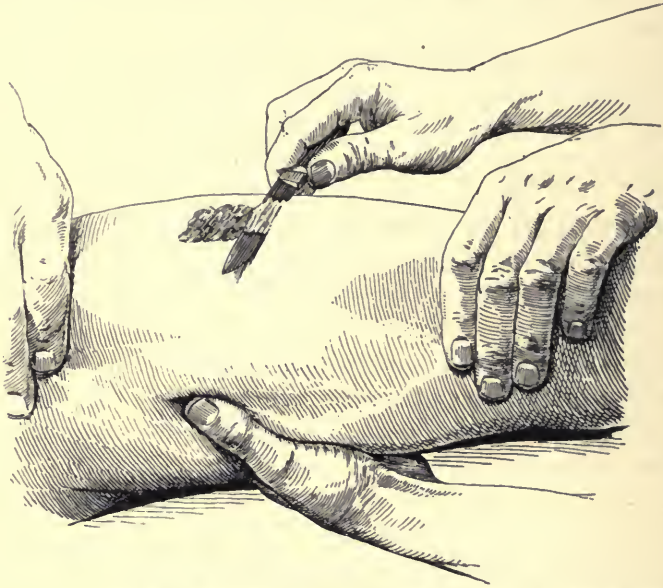

FIG. 296. THIERSCH'S METHOD OF SKIN-GRAFTING. To show how the knife should be held, and the position of the hands to steady and make tense the skin. On the right leg it is convenient to cut the grafts from below upwards and in the reverse direction on the left leg.

is employed the utmost delicacy and care in handling the grafts must be exercised.

1. *Thiersch's method* (Figs. 296 and 297). The grafts consist of the whole thickness of the epidermis together with the superficial portion of the cutis vera, so that the tips of the papillæ are just severed. If the grafts are cut too thick they curl up and become very difficult to manipulate. The proper thickness of the grafts is obtained when the raw surface left by their removal shows numerous minute punctiform hæmorrhages. If this thickness of skin only is removed no scarring follows. In the course of time it becomes almost impossible to distinguish the place

from which the grafts were taken, though a certain amount of light brown pigmentation may be left; in fact the same site can be used, if necessary, for providing a second series of grafts.

Very few simple instruments are required; these are a knife, a pair of scissors, dissecting forceps, a couple of fine probes, and possibly a broad smooth metallic spatula (Fig. 298) for transferring the grafts. Thiersch's razor, which has a broad flat surface (Fig. 299), is used by many surgeons, but an amputating knife with a blade four or five inches long is the best kind of knife to use. Whatever kind of cutting instrument is employed, it must be extremely sharp in order to work easily; therefore in sterilizing it some means must be taken to protect the edge.

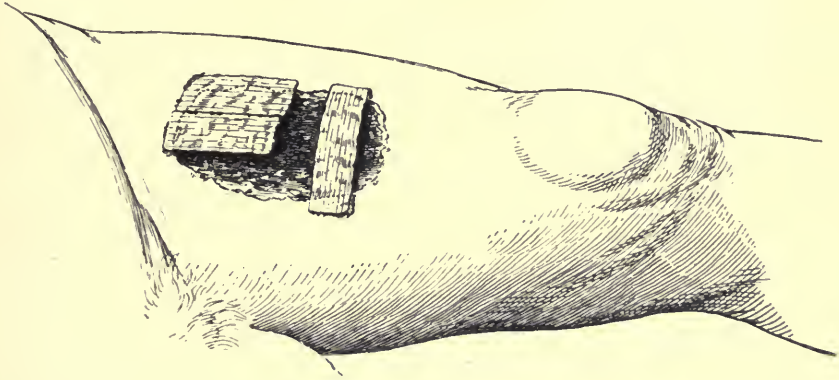


FIG. 297. THIERSCH'S METHOD OF SKIN-GRAFTING. The grafts are shown in position on the area to be covered. The overlapping of the grafts, and of the latter over the edges of the raw area, is shown.

Whilst the grafts are being cut the blade should be kept moistened with normal saline solution or boracic acid lotion; unless this is done the grafts adhere to the blade and curl up.

The skin is kept as tightly stretched as possible in the long axis of the limb, the assistant placing his hands one above and the other below the selected area (Fig. 296). The operator grasps the limb from behind forwards with his left hand and keeps it on the stretch in a lateral direction, at the same time pushing the muscles forwards so as to have a flat surface. The blade of the knife is placed at such an angle, that when it penetrates the skin, the graft shall be of the requisite thickness. The graft is cut by a rapid, even, lateral sawing movement and should be as large as possible. With practice, grafts four or five inches or more in length and two inches wide may be easily cut. The final severance of the graft is often best accomplished by cutting with scissors. The number required will depend on the size of the raw area to be covered and the size of the

individual grafts. If many are needed, each one as it is cut may be left lying on the bleeding surface or may be transferred to normal saline solution at a temperature of 100° F. Either of these methods is preferable to the immediate transference of each graft to the area to be covered.

The dressing is cautiously removed from the raw area and any blood

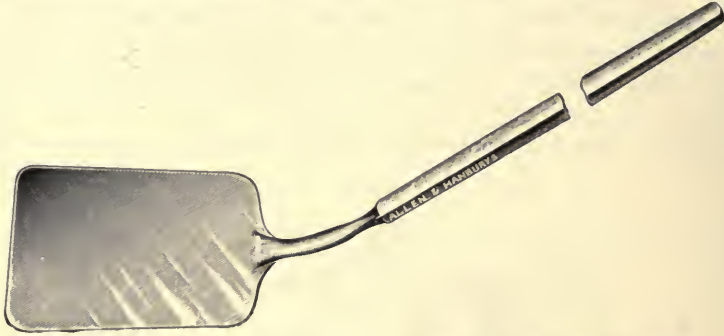


FIG. 298. A BROAD SMOOTH METALLIC SPATULA FOR TRANSFERRING THE SKIN GRAFTS.

is carefully wiped away from its surface. The graft is gently lifted by the forceps, or if it is large, placed on the spatula with the raw surface downwards, and transferred to the wound, where, by means of the probe, it is uniformly and evenly spread out. Each graft must be placed in close contact with its neighbour or their edges be allowed to overlap; if this is not done any uncovered area would become covered with skin,



FIG. 299. THIERSCH'S KNIFE FOR CUTTING SKIN GRAFTS.

but the scar at such places is likely to be thin and to break down. The margins of the ulcer or wound should likewise be overlapped by the grafts for about one-eighth or a quarter of an inch (Fig. 297). No air or fluid must be allowed to remain between the under surface of a graft and the raw area. Any such accumulation may be got rid of, by making firm pressure on the grafts by means of long broad pieces of sterilized protective grasped at each end and stretched tightly across the grafts. Once the grafts are in position, every care must be taken not to displace them.

2. *Reverdin's method.* This method consists of snipping off small pieces of the superficial layers of the epidermis and placing them on the surface of the ulcer at short distances (half an inch) from each other.

These pieces form foci from which the epithelium spreads over the ulcer and if the grafts be placed close enough together the ulcer is soon cicatrized. If the separate growths of epithelium do not coalesce, the intervening granulation tissue becomes converted into bands of scar tissue, which is very likely to be the starting-point of fresh ulceration.

This method is inferior to Thiersch's, but it is useful in some cases of burns on the face and in large burns on the trunk when the whole area cannot be covered in by the Thiersch grafts. It hastens the healing process and to some extent diminishes the amount of subsequent contraction.

3. *Wolfe's method.* The whole thickness of the skin without any of the subcutaneous fat is employed to form the graft. The size of the graft must be larger than the area to be covered to allow for the contraction of the skin, and it must be taken from some part (usually the thigh) where the cicatrization of the wound left by its removal will produce the least amount of inconvenience.

The graft must be taken from a part of the body which is free from hair, as the normal structures in the skin are neither absorbed nor destroyed. The whole of the fat is removed, and the graft is well stretched before placing it in position. It may be fixed by means of a few stitches. When successful this method provides a thick and complete covering for the part. The amount of scar tissue is greatly diminished, and thereby the tendency to reproduction of the deformity. It is therefore especially useful for cases of burns of the hands and fingers.

Instead of a portion of skin, the healthy prepuce removed by circumcision may be employed; but it is not easy to sterilize, and there is a great tendency for it to curl up. It should be divided into small portions, which are placed close to one another.

The objection to the method is that it is not so successful as Thiersch's: part or even the entire central portion of the graft may slough; in any case the superficial epithelium is shed in the course of a few days, but provided the deeper part remains, the wound is speedily covered in.

3. The Dressing and After-treatment. As soon as all the grafts are in position, they are covered by a sterilized layer of protective or a perforated piece of thin silver foil, outside which a thick layer of sterilized gauze is applied, and the whole is firmly and uniformly bandaged. If necessary some sort of splint may be used. Complete and absolute rest must be secured, in order that the grafts may adhere to the raw surface. The place from which the grafts were obtained is dressed in a similar manner, this dressing being left undisturbed for a week or ten days, by which time the surface will usually be healed.

The dressing on the grafted surface will require changing about the fourth or fifth day. In those cases where the asepticity of the wound

is certain, it is possible to defer the first dressing for a week. Especial care must be taken not to disturb the grafts during the removal of the protective, and if on removal of the gauze there is no pus or discharge the protective need not be disturbed. To detach the protective, plenty of normal saline, or 1 in 4,000 perchloride of mercury lotion, must be used. If the grafts are of a pink or reddish colour they are living; if whitish or greyish, they no longer live. The protective is reapplied with fresh outside dressings and bandages as before, and the wound is dressed subsequently as often as seems necessary.

In the after-treatment it is important to protect the newly grafted area, both from injuries, and from being detached by movement of the adjacent structures; therefore a period of prolonged rest is necessary to get a permanently sound scar; this is especially indicated in the case of chronic ulcers of the leg. At the same time appropriate means to improve the nutrition of the surrounding skin must be adopted. A dilute, bland, unirritating ointment or oily preparation should be kept constantly applied when there is any tendency to thickness or cracking of the epidermis of the grafts.

CHAPTER II

RHINOPLASTY

GENERAL PRINCIPLES

PLASTIC operations on the nose are performed for congenital and acquired defects. In this chapter only the external defects or abnormalities will be considered. True congenital defects are very rare and in the vast majority of the cases which require rhinoplasty, the deformity is due to injury, an operation, or disease. These defects or deformities may be divided into three classes: (1) The nose may be totally destroyed, usually by syphilis, and be represented by one or two openings on the face and some cicatricial tissue. Occasionally such a condition is due to injury. (2) Partial destruction, usually of the cartilaginous portions—the alæ, the tip, and septum—the bony portions remaining intact. Such defects may be the result of syphilis, lupus, injury, frost-bite, or an operation for the removal of tumours. (3) Deformity from sinking in of the bridge, secondary to an injury or syphilis. As a result of syphilitic necrosis, or defective development due to congenital syphilis, the bony bridge may be almost absent, and the nostrils are directed forwards instead of downwards.

Rhinoplastic operations are divided into (1) **complete**, in which the whole nose has to be re-formed, and (2) **partial**, in which the restoration of some part, such as the tip, the alæ, the septum, or the bridge, is required. In any case, a flap operation is almost invariably employed, the flap being taken from the forehead or face, or from more distal parts, such as the arm.

When a complete rhinoplastic operation is required one of the following methods may be used:—

(a) *In the Indian method* the flap is obtained from the forehead and twisted into position. An obvious objection is the large scar which is left on the forehead; and, of course, the method is inapplicable when the forehead is the seat of cicatrices. (b) *In the French method* the flaps are obtained from the adjacent portions of the cheek. It is most suitable for those cases in which the upper part of the nose is intact. (c) *In the Italian or Tagliacotian method* the flap is taken from the arm. It has not been widely adopted, and is only to be used when other methods are inapplicable or unavailable. The chief objections to this method are the constrained position of the arm and the cumbersome apparatus required to keep the parts in apposition. Moreover, the flap is not so

well adapted for the purpose as one obtained from the forehead. Whichever of these three methods is employed the final results are never very satisfactory when the whole nose has to be restored. The chief drawbacks are (1) the difficulty of forming a columella, and (2) the tendency to continued contraction of the anterior nares of the new nose, a tendency which persists for many months. The new-formed nose at first may appear to be very good, but it shrinks, in such a way that sooner or later a shapeless mass of skin is left on the face. In addition the scarring causes marked disfigurement when the flaps are taken from the adjacent portions of the face or from the forehead. These operations are rarely practised at the present day, and before performing them the surgeon should see whether a better cosmetic effect cannot be obtained by the use of a carefully moulded and coloured artificial nose.

Partial rhinoplastic operations are much more satisfactory and are frequently practised. For the restoration of the bridge, bone has been successfully transplanted, in some cases, from an animal such as the rabbit; and during recent years the subcutaneous injection of paraffin has been largely and very successfully employed to restore the shape of the bridge.

It is, perhaps, hardly necessary to reiterate the caution already given, that all signs of active local disease, syphilis, tubercle, or other inflammatory conditions, must be absent before undertaking any of these operations.

COMPLETE RHINOPLASTIC OPERATIONS

THE INDIAN METHOD

A piece of gutta-percha tissue to indicate the size and shape of the flap is laid flat on the forehead in the position from which it is proposed to take the flap, which is then marked out fully one quarter or a third of an inch larger in all its dimensions, in order to allow for shrinkage. The edges of the defect are refreshed and freed from the underlying parts, so that the attachment of the frontal flap may be made more secure with the borders of the skin around the defect. If there is any healthy skin left at the root of the nose it should be detached from above downwards, as a quadrilateral flap, its attached margin being at the lower end (see Fig. 300 c). The raw surface of this flap will then be directed outwards; it serves to support the frontal flap, and at the same time diminishes the amount of subsequent shrinkage. The forehead flap should be more or less pyriform in shape (Fig. 300 A) or cut after Langenbeck's method (Fig. 300 B), and should be placed obliquely on the forehead, especially when the latter is a low one and the line of the hair comes far down, but care must be exercised not to place it transversely, as the contraction of the scar may

then draw up the corresponding eyebrow. The obliquity of the flap serves to minimize the risk of the vessels being unduly compressed in the pedicle when it is twisted into position. One limb of the incision is

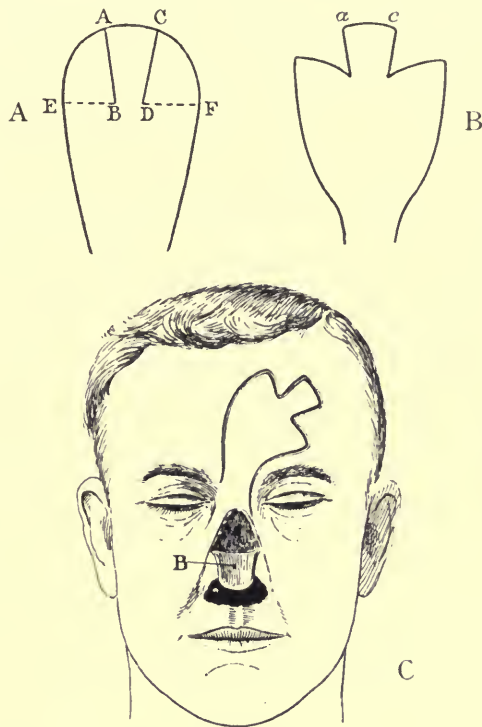


FIG. 300. THE INDIAN METHOD OF RHINOPLASTY. A is the outline of a pyriform-shaped flap. AB and CD represent the lines for marking out the columella. The dotted lines BE and DF indicate the lines along which the flaps ABE and CDF are folded to form the alæ of the nostrils. AC is sutured to a prepared raw area on the upper lip.

B represents Langenbeck's method of cutting the flap. The prominent part forms the columella, ac being sutured to the upper lip.

C. The flap is shown in position on the forehead: one margin of the pedicle ceases at the inner limit of the eyebrow and the other reaches to the raw area on the nose. B is a quadrilateral flap, turned downwards from the outer surface of the nose: its point of attachment is at the lower extremity of the nasal bones: its raw surface is directed forwards, and is covered by the forehead flap which it serves to support.

carried down into the refreshed area, the other one ceases about the level of the inner end of the eyebrow (see Fig. 300 C); the latter incision may be continued horizontally outward, if necessary, to make the turning of the flap easier. The pedicle is thus placed at the root of the nose and is

made as broad as possible and contains one nutrient artery, viz. the frontal. The incisions are carried down to the bone; the whole flap, including the periosteum, is then dissected up. (There are two possible objections to dissecting up the periosteum: (a) the frontal bone may superficially necrose, (b) the periosteum has no bone-forming function and therefore is useless from this point of view. Most surgeons, however, include the periosteum in the flap.) It is also recommended to remove by a chisel a thin layer of bone and transplant it together with the flap in order to better retain the shape of the nose. All hæmorrhage being arrested, the flap is rotated into position, taking care not to twist the pedicle more than necessary. If a pyriform flap has been made, the two longitudinal cuts, A B, C D (see Fig. 300 A), are made, dividing it into three parts; the middle part forms the columella, and the two lateral parts, after being bent back along the lines B E, D F, form the alæ nasi.

The septum is formed from the middle portion of the flap by folding it longitudinally and securing this longitudinal fold by means of catgut sutures. The two lateral portions are also doubled on themselves (Fig. 300 A) for the formation of the alæ nasi, and secured in the same way by catgut sutures. If by the doubling of the lateral portions the alæ are made too thick and the nostrils too small, the excision of a small wedge-shaped portion or the removal of the subcutaneous tissue may be employed to overcome the difficulty.

The flap is sutured to the defect with fine silkworm-gut or horse-hair sutures, the edges being carefully brought into apposition without tension. If a columella has been formed, it is sutured to a groove or bed made for it in the mid-line of the lip, but in many cases, when the forehead is a low one, it is advisable to form the columella from the upper lip, either at once, or at a later period. The lower aperture of the nose must be supported by gauze plugs, or if the nostrils have been formed, a small drainage tube is inserted into each. The defect in the forehead is closed as completely as possible by sutures, any remaining portion being grafted by Thiersch's method.

The new-formed nose may be left without a dressing or else a simple collodion dressing may be applied. The sutures remain untouched for four or five days, and their removal is then gradually accomplished. The gauze in the lower opening will require to be changed twice or thrice daily; the drainage tubes should be changed frequently, but not finally removed for some weeks. The pedicle of the forehead flap is divided at the end of four to six weeks, the redundant portion being removed or replaced in the lower portion of the forehead wound. Secondary operations will probably be required to improve the alæ, but these should never be undertaken till the nose has ceased to shrink.

THE ITALIAN METHOD

In this method the flap is taken from the anterior surface of the upper arm and sutured to the defect. The arm is fixed to the forehead, and kept in this position for three or four weeks, when the pedicle is severed and the operation completed. A full account of the method may be found in a paper by the late Sir William MacCormac in the *Clinical Society's Transactions*, vol. x, p. 181.

PARTIAL RHINOPLASTIC OPERATIONS

OPERATIONS FOR DEFECTS OF THE BRIDGE

Saddle-back nose. In a typical case, the bridge is completely depressed and on a level with the cheeks, the cartilaginous portion being tilted upwards so that the nostrils look forwards instead of downwards. The deformity may be due to a depressed fracture, or to necrosis after injury, or may have followed congenital or acquired syphilis. In the latter cases there is likely to be a considerable amount of scar tissue, and the results are not so good as in the former cases.

The objects of the operation are: (1) to restore the shape of the bridge by some means which will be permanent; (2) to correct the position of the nostrils. Very many operations have been devised, including the use of frameworks made of gold, amber, aluminium, &c., but at the present day these latter are not employed.

*Sir Watson Cheyne's method*¹ (Fig. 301 A). A median vertical incision is made from the root of the nose downwards on to the cartilaginous portion, extending on the latter for a quarter of an inch. Transverse incisions are then made at the upper and lower ends of this incision, thus forming two lateral flaps, which are dissected up, taking if possible any periosteum and fragment of the nasal bones which may be present. The cartilaginous portion of the nose is then separated from the remains of the bony portion, the nasal cavity being opened and the cartilaginous septum divided sufficiently to enable the tip of the nose to be readily pulled into its normal position. Two vertical and parallel incisions, each about an eighth of an inch on either side of the median line and beginning half an inch above the root of the nose, are carried upwards on the forehead to the margin of the hair, and their upper ends are united by a transverse cut. These incisions divide all the structures down to the bone. A narrow chisel being introduced along each lateral incision and into the upper transverse incision, a portion of the external table of the frontal bone is separated together with the

¹ Cheyne and Burghard, *Manual of Surgical Treatment*, Part V, p. 154.

soft parts. The flap is then turned downwards, and when the lower end is reached the bone is broken across. The flap is rotated so that when in position it will have on its outer surface a thin layer of bone and on its deep surface the soft parts of the forehead, *i. e.* the skin is directed towards the nasal cavity. The flap must be long enough for its free end to be attached to the cartilaginous portion when this is pushed into its proper position, and to enable this to be done without tension it

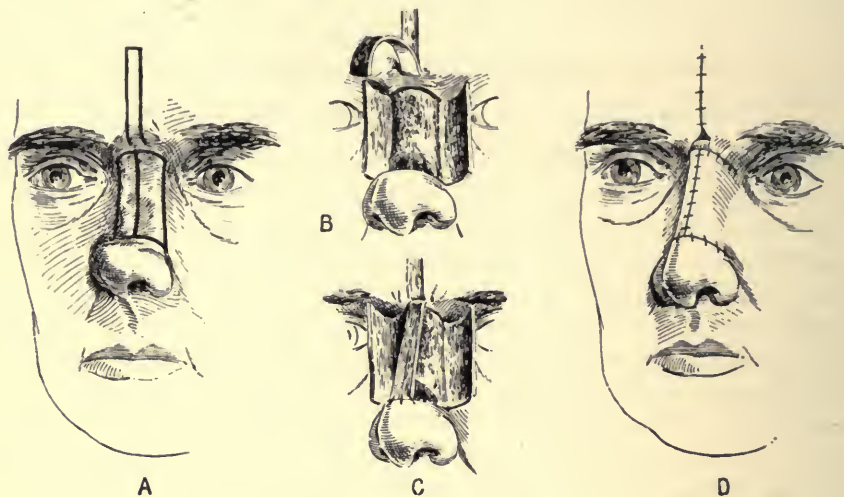


FIG. 301. SIR WATSON CHEYNE'S METHOD OF RESTORING THE BRIDGE OF THE NOSE. A shows the lines of incision for the various flaps. In B the flaps have been reflected and the tip of the nose freed and brought into position. In C the reflected flap from the forehead is sutured in position, while in D the lateral flaps have been brought together over the reflected forehead flap. The small triangular gap left at the root of the nose is afterwards filled by the divided pedicle of the forehead flap, which is trimmed into shape and turned up again. (Cheyne and Burghard's *Manual of Surgical Treatment*.)

may be necessary to prolong the lateral incisions a little downwards on each side of the root of the nose; but a sufficiently broad pedicle must be left for the proper nutrition of the flap. The flap is stitched to the freshened end of the cartilaginous portion of the gap, so that its cutaneous surface covers the aperture between the bony and cartilaginous portions of the nose. Above this gap the skin on the deeper surface of the flap is carefully shaved off, in order to make it readily adhere to the remaining refreshed surfaces of the bridge. At the root of the nose there is a certain redundancy of the skin from the folding of the pedicle, which will be divided subsequently and the excess turned upwards. The lateral flaps are finally replaced and united over the raw

surface of the reflected forehead flap. The upper transverse incisions should be curved downwards and outwards; this allows a certain amount of sliding of the flaps downwards so that they can cover the opening between the tip of the nose and the new bridge. The incision in the forehead is readily stitched up and leaves a hardly perceptible scar. At the end of three weeks the base of the reflected flap is divided and the little portion remaining is trimmed into a triangular shape and fitted in at the lower part of the vertical incision.

The new bony bridge tends to sink downwards as healing occurs and will as a rule not be high enough. After healing has occurred, the bridge may be heightened to the required extent by turning aside the skin flaps and introducing pieces of bone removed from the femur of a newly-killed rabbit in sufficient quantity to raise the bridge to its proper level. Great care must be taken not to reopen the nasal cavity at this second operation, otherwise necrosis of the grafted bone is likely to follow.

Sir Watson Cheyne also describes¹ a method in which the femur of a rabbit, split longitudinally into several fragments, was used with great success to restore the bridge. A flap with its convexity to the right was raised from the right side of the nose and turned over to the left. A fragment of femur, two inches in length, was first inserted into the nasal cartilage, pushing down the tip of the nose and its upper end was wedged against the frontal bone. Four or five smaller fragments were then laid around this till the necessary height for the bridge was obtained. The skin flap was replaced and sutured after undermining the skin on the left side of the nose. Union by first intention occurred, and nine months after the operation the result was excellent, though the bridge was slightly less prominent than at the time of the operation and slight movement of the bones could be still obtained on firm pressure. Ricord has used the fourth metatarsal bone to make a new bridge.

It will be evident that when the skin over the depressed bridge is very thin and cicatricial the flaps may be so poorly nourished as to slough when they are separated; in such a case a flap from the forehead may be employed to cover in the bone.

The Subcutaneous Injection of Paraffin for the Restoration of the Bridge. This method was first introduced by Gersuny in 1900, and has been extensively employed in the correction of saddle-back noses. The most suitable cases are those in which the deformity is secondary to a depressed fracture of the nasal bones, and those in which there is defective development of the bridge due to congenital syphilis. The skin over the bridge

¹ *Clinical Society's Transactions*, vol. xxxii, p. 218.

should be supple, thick, and freely movable: if it is thin, cicatricial, or closely adherent to the periosteum, the case is not so suitable, and the results are not so good; when these adhesions are present they may be divided by introducing a tenotome, and cutting them with the blade parallel to the skin.

The best kind of paraffin to use is one which has a melting-point of 110° to 115° F. The syringe is shown in Fig. 302. A general anæsthetic is usually desirable but is not essential. The skin of the

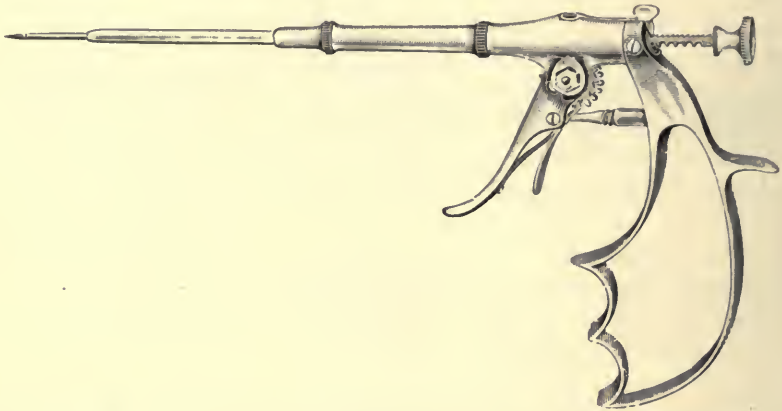


FIG. 302. MAHU'S SYRINGE FOR THE INJECTION OF COLD PARAFFIN WAX. The wax is supplied in small cylinders sterilized at 120° C., and is fusible at 45° C. The cylinder of wax is inserted into the barrel, being pushed home with the rod supplied for the purpose. The piston is then inserted and fixed in position. The trigger, on being pressed by means of the ratchet wheel, forces the piston along the barrel, pressing out the wax, which emerges at the needle point in the form of a thin thread. Instead of using this specially prepared wax, the paraffin may be melted and sterilized by heat. Whilst still liquid, a heated small syringe is filled with the wax, and then the barrel of the Mahu's syringe is charged. The wax is allowed to cool before injecting it into the tissues. (*Mayer and Meltzer.*)

nose must be efficiently disinfected. The paraffin, syringe, and needle are first sterilized and then placed in a water bath at a temperature of 6° or 7° above the melting-point of the paraffin, which is allowed to become semi-solid or opaque in the syringe before it is injected. The injection must be given slowly and gradually. The skin having been pinched up, the needle with its point directed upwards and passed well under the skin, is entered on one side of the mid-line and some distance below the place where the bridge ought to be.

The quantity to be injected varies, and should be rather less than that required to entirely remove the deformity. The needle should not be withdrawn until the required amount is injected, and it may be necessary to repeat the operation to improve still more the appearance

of the patient. After the withdrawal of the needle, the puncture is sealed with a collodion dressing. The skin at first becomes white and tense, the degree depending on the quantity of paraffin employed ; some inflammatory reaction may follow in a few hours, the redness slowly subsiding, or perhaps persisting for many days. Pain is not usually complained of, but there may be some tenderness. The results obtained by this method in suitable cases are excellent and permanent, but it is important to recognize that it has its limitations. Many accidents have occurred from the use of hot paraffin, which are avoided by the use of cold paraffin. This method is superior to that in which melted paraffin is employed. In the latter the operation has to be done very quickly, and diffusion of the paraffin into the eyelids is not uncommon. Moreover, in the former method an assistant is not necessary. There is no fear of poisoning and very little of sloughing or suppuration if the skin is healthy. Failure is usually due to insufficient antiseptic precautions or because too much paraffin has been used.

Paraffin has also been successfully employed for elevating depressed scars, especially those on the face, for filling large bony cavities and the depression remaining after removal of the upper jaw. It has also been used with success in the treatment of prolapse of the rectum and of the vagina.

OPERATIONS FOR RESTORATION OF THE SOFT PARTS

Syme's operation. When the end of the nose only has been destroyed this operation (Fig. 303) may be employed. Two flaps are marked out, one on each cheek, having a median conjoint pedicle at the root of the nose between the inner canthi. The size of the flaps is regulated by the size of the nose which it is required to restore according to measurements previously made. The area to be closed having been carefully refreshed, the flaps are dissected up and united in the middle line after all bleeding has been arrested. The outer edges of the flaps are sutured to the raw area at a proper distance to form the nasal orifice. It is advisable, if possible, to fold over the free inferior margin of the flaps and unite the apposed raw surfaces in order to have a cutaneous surface at the margin of the new nostrils which are supported by drainage tubes. The septum may be formed at a later date from the upper lip. The edges of the wounds left in the cheeks are brought together as closely as possible, any unclosed area being left to granulate, or it may be skin-grafted. By this method a conspicuous frontal scar is avoided, but the nose is apt to be very flat, as there is a good deal of shrinkage.

Keegan's method. This method was introduced to restore noses which had been mutilated by injury, and is only applicable, in its fullest extent, to those cases in which the skin and tissues over the nasal bones

have been undamaged. Superimposed flaps are employed ; one flap is taken from the forehead, the size of it being proportioned to the face of the patient. This flap is placed obliquely on the forehead, with the pedicle at the internal angle of the orbit, and it must contain the angular artery. The other flaps are taken from the skin of the bridge. The method is thus described in the *Lancet*, vol. i, Feb. 21, 1891: 'The cavities on both sides of the septum are plugged with pledgets of wool, to which sutures are attached. The operation is begun by carrying two converging incisions from two points slightly external to the roots of the

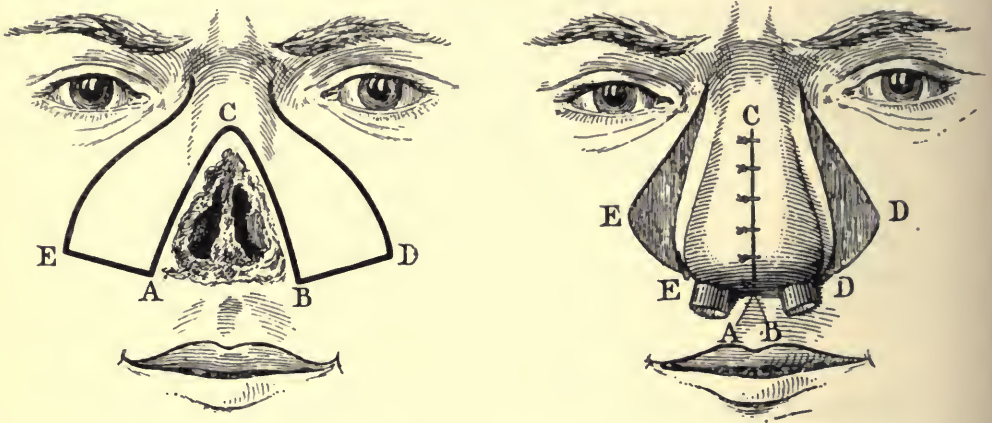


FIG. 303. SYME'S OPERATION FOR THE RESTORATION OF THE SOFT PARTS OF THE NOSE. In the left-hand figure the incisions marking out the flaps are shown, and the raw area on the nose, the edges of which are refreshed. In the right-hand figure the flaps are in position, and the edges A C, B C sutured. A small piece of drainage tube has been placed in each nostril. The areas from which the flaps are raised are closed, partly by undermining the adjacent cheek and partly by skin-grafting.

alæ nasi to two points about three-quarters of an inch apart on the bridge of the nose where a pair of spectacles would rest. These two points on the bridge of the nose are now joined by a horizontal incision, A F (Fig. 304). This horizontal incision is bisected and a perpendicular incision, B D, E G, is drawn downwards from the point of bisection nearly as far as where the nasal bones join on to the cartilage of the nose. In other words, this perpendicular incision follows the course of junction of the nasal bones, but is not carried down as far as their inferior borders. The skin and tissues are now dissected from off the nasal bones from above downwards in two flaps, A B C D and E F G H (Fig. 304). The two inferior borders of the flap, C D and G H, are not interfered with and constitute the attachment of the flaps to the structures and tissues which clothe

the inferior borders of the nasal bones where they join the cartilage of the nose. If these two flaps are reflected downwards so that their raw surfaces look forwards and their cutaneous surfaces look backwards, it will be found that they overlap in the centre. The surgeon has, therefore, a redundancy which he can utilize a little later on, when he has raised the flap from the forehead. He now proceeds to do this.' The flap has the shape shown in Fig. 304, its size being marked out according to that of the nose to be restored. 'This flap should embrace all the tissues down to the pericranium, and should be handled as little as possible.

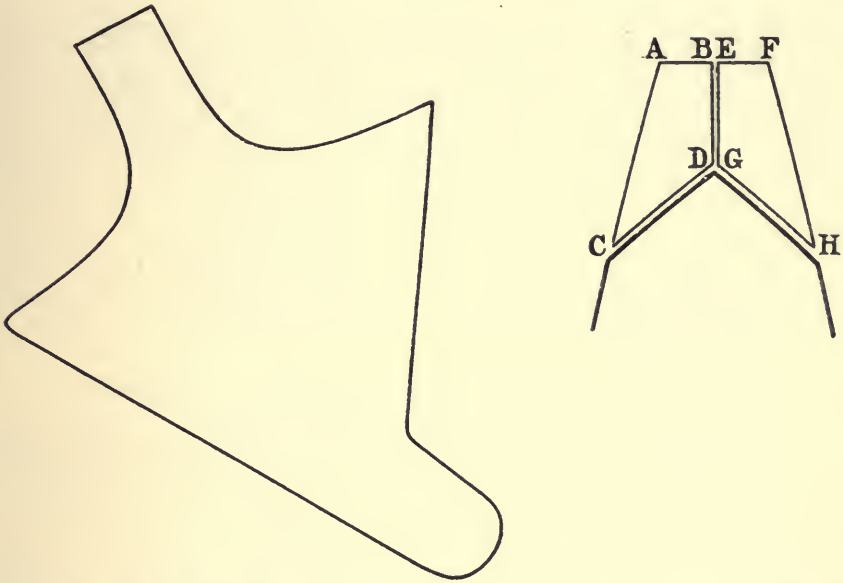


FIG. 304. KEEGAN'S METHOD OF RHINOPLASTY. On the left hand the shape of the forehead flap is shown; on the right hand, the incisions marking out the nasal flaps. (*Lancet*, February 21, 1891.)

The sides of the gap in the forehead are approximated as quickly as possible with horsehair sutures, and it is surprising how small a raw area is left behind on the forehead if the approximation of the sides of the gap be carefully and rapidly carried out. Attention is now directed to preparing a bed for the reception of the columella, and this does not require any description. The two flaps, ABCD and EFGH, which have already been raised from off the nasal bones, are now reflected downwards, and as they overlap in the centre, two triangular pieces are cut away and placed in the middle of the gap left in the forehead, in order to expedite the healing of the frontal scar. The forehead flap is now

brought down over the nasal bones and rests inferiorly on the two reflected flaps, *ABCD* and *EFGH*, which have already been raised from the nasal bones. The raw surface of the frontal flap inferiorly lies on the raw surfaces of the two reflected nasal flaps, and the nostrils of the newly formed nose are therefore lined inside with the skin of the reflected nasal flaps. The free inferior margins of the forehead flap and the nasal flaps are now brought together by horsehair sutures. The columellar portion of the forehead flap is now fixed in the bed prepared for it by sutures, and the two original incisions drawn from the root of the *alæ nasi* on either side to the bridge of the nose are deepened and bevelled off for the reception of the sides or lateral margins of the forehead flap. The lateral margins of the forehead flap are most accurately stitched by horsehair sutures to the bed prepared for them. Two pieces of drainage tube are inserted into the newly formed nostrils. If the root or pedicle of the newly formed nose is broad enough and is not dragged upon, and the angular artery has not been wounded, there need be no fear of sloughing, and the new nose will largely adhere by first intention.' The pedicle is divided at the end of a fortnight and a wedge-shaped slice is cut out of the root, so that the new nose may not be parrot-shaped. As the inside of each nostril is lined by skin, the drainage tubes can be discarded at the end of ten days.

OPERATIONS FOR RESTORATION OF THE ALÆ NASI AND SIDE OF THE NOSE

It is impossible to give a detailed account of the actual operation which may be required in any given case. A flap will be required in all cases, and this may be obtained (1) from the opposite side of the nose; (2) from the same side of the nose above the defect; (3) from the adjacent portion of the cheek. The first and second methods can be employed only when the skin of the nose is sound.

By a flap taken from the sound side of the nose. *Langenbeck's method.* The base of the flap is placed near the inner angle of the orbit of the affected side. The edges of the defect are refreshed and sutured to those of the flap. The raw area left by elevation of the flap is covered by skin-grafts, or by undercutting the skin of the cheek and gliding it over the raw area. The flap should be long enough to allow the lower border to be folded on itself to form a more natural margin for the nostril, and a small drainage tube is placed in the newly formed nostril to support it (Fig. 305).

By a flap taken from the same side of the nose.¹ A straight incision, *ADB* (Fig. 306), is made down to the periosteum along

¹ Berry, *Clinical Society's Transactions*, vol. xxxviii, p. 174.

the anterior edge of the defect up to a point a short distance below and internal to the inner canthus of the eye. A second curved incision, BEC, of about the same length is made downwards and outwards along the upper border of the naso-labial fold to a point about one inch external to the outer margin of the gap. The flap, thus obtained, is then dissected downwards and includes everything down to, but not including the facial artery and vein. The neighbouring parts of the cheek and upper lip are freely raised by undercutting them.

The tissues on either side of AD are dissected up to form a deep

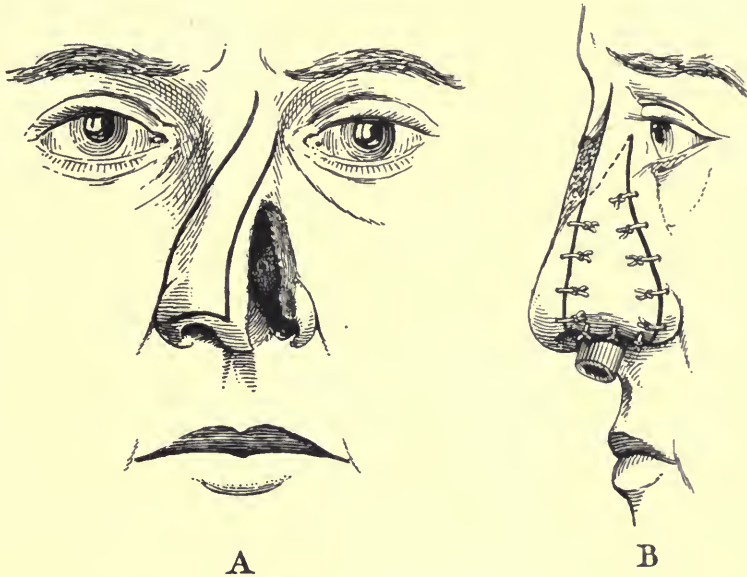


FIG. 305. LANGENBECK'S METHOD OF RHINOPLASTY. In A the flap is shown marked out on the sound side of the nose. In B it is stitched in position and the nostril is supported by a drainage tube. The stitches holding the folded lower margin of the flap in position are shown.

groove for the reception of the edge of the transplanted flap. The latter is folded on itself and then twisted inwards and downwards, so that the upper angle, B, is brought down to the tip of the nose at A. The upper half, BE, of the outer edge of the flap is then sutured to the lower half, AD, of the first incision along the side of the nose. The raw inner edge, DB, of the flap is thus left free to form part of the anterior edge of the restored nostril; this granulation edge curls inwards and disappears behind the new ala. The lower part, CE, of the outer edge of the flap is acutely doubled upon itself, and this portion of the flap is thus made to present a prominent angle in imitation of the prominent

part of a normal ala. The triangular raw area, DBE, can be closed by undercutting, chiefly on the side of the cheek. Deep tension sutures will

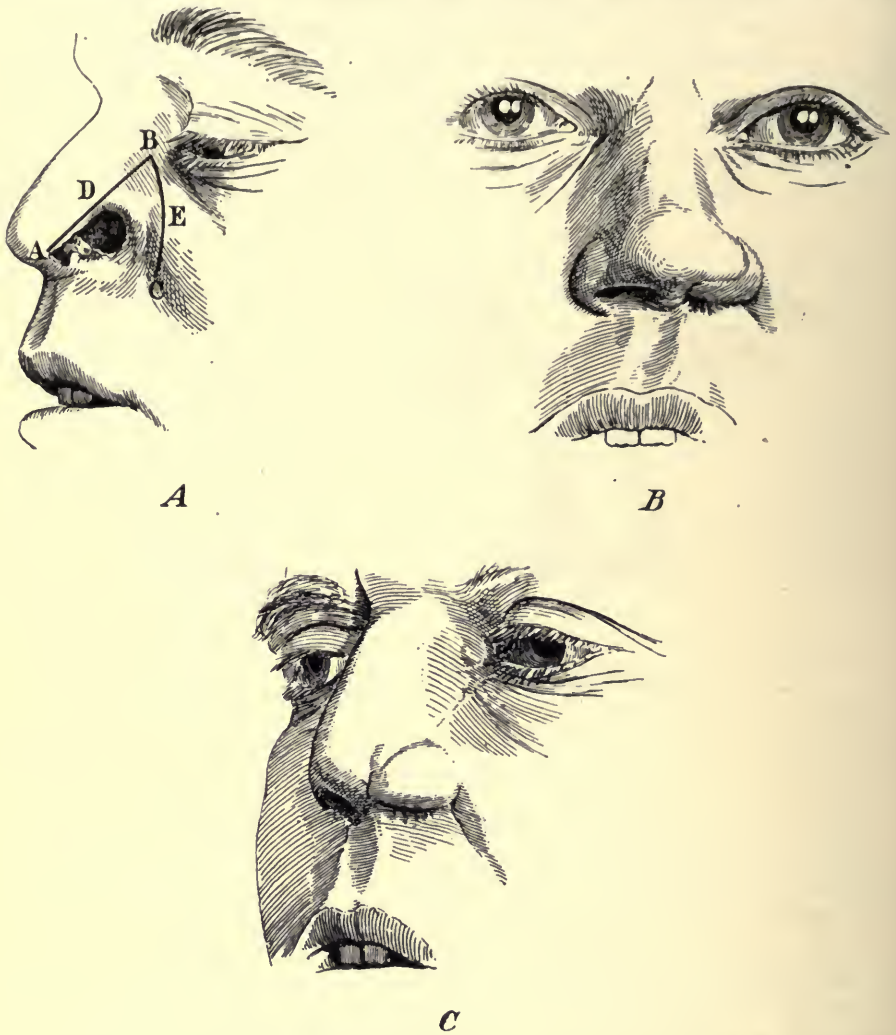


FIG. 306. RESTORATION OF THE ALA NASI BY A FLAP TAKEN FROM THE SAME SIDE OF THE NOSE. In A the defect and the lines marking the incisions are shown. In B the front view, and in C the lateral view, of the restored nostril is shown. The figures are drawn from photographs. Three and a half years after the operation there had been no shrinkage, and the result was excellent. (*Mr. J. Berry's case.*)

be probably required, or the gap may be closed by skin-grafting if its edges cannot be brought together.

In the patient illustrated in Fig. 307 the lower part of the septum and the whole of the left ala of the nose had been destroyed by gangrene following a specific fever. An incision, *A D B*, was made, the point *A* being just below the level of the lower limit of the nostril of the opposite side, and the point *B* just above the inferior margin of the nasal bone. The incision completely separated the remains of the ala along *B D*. On each side of *A D* the scar tissue was freely removed, so as to form a broad raw surface. An oblique incision, *B C*, then separated the whole thickness of the soft parts below *C B D* as a thick flap, which was detached from the nasal bone. The whole flap, *C B D*, was rotated downwards so that

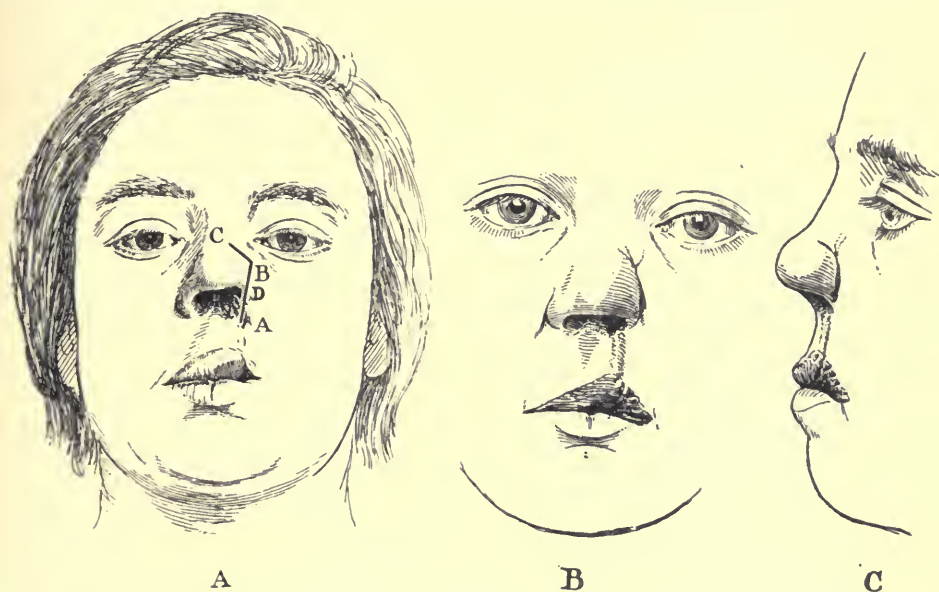


FIG. 307. RESTORATION OF THE ALA NASI. In *A* the line of the incision for marking out the flap is shown. In *B* the front view, and in *C* the side view, of the restored nostril is shown. The scars in the lip are the results of an operation to restore it (see Fig. 317, p. 701). Taken from photographs. (*Author's case.*)

D was opposite *A* and the part of the incision *B D* opposite *D A*. A gap was thus left on the side of the nose above the displaced flap. By freely undercutting the skin of the adjacent part of the cheek and pulling it inwards, this gap was easily closed. The margin, *B D*, was united by silk-worm-gut sutures to the raw surface along *D A*. The effect and the resulting scar are shown in Fig. 307 *B* and *C*.

FORMATION OF A NEW COLUMELLA

A new columella may be formed from either the upper lip or the dorsum of the nose.

From the lip (Fig. 309, p. 691). Two parallel incisions, separated from one another about a quarter of an inch, are made through the whole thickness of the central portion of the upper lip. The pedicle of the flap is at its upper end and the lower end is formed by the free border of the lip. The flap is twisted upwards after the frænum has been divided, so that the mucous membrane looks forwards, and the skin surface towards the nasal cavity. The free end of the flap, after its mucous membrane has been removed, is sutured to the prepared raw surface on the tip of the nose. In time the exposed mucous membrane becomes thickened and resembles the skin. In males it is advisable to dissect

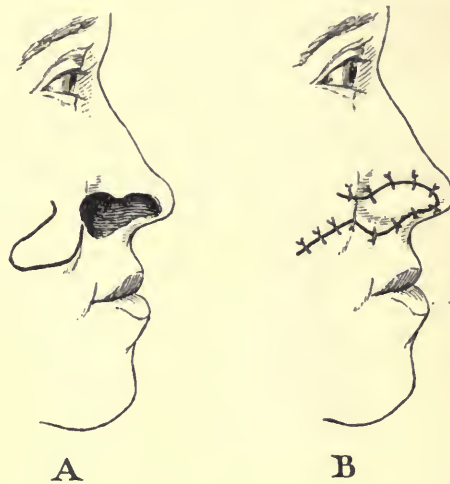


FIG. 308. RESTORATION OF THE ALA NASI BY A FLAP TAKEN FROM THE CHEEK. The flap may be placed in the defect with its cutaneous aspect directed outwards, or it may be so placed that its raw (deep) surface is directed outwards, and its cutaneous surface towards the nasal cavity. The former is then skin-grafted.

off the skin and hair follicles from the flap before placing it in position. The upper lip is restored by separating it on each side of the gap from the underlying bone and uniting the raw edges together (Fig. 309 B), especial care being taken to preserve the line of continuity of the skin and mucous membrane and in the formation of the free border of the lip, that a V-shaped depression is not left.

From the dorsum of the nose (Fig. 310 A, p. 691). A long flap, including the periosteum, is dissected up, having the pedicle near the tip of the nose. The flap is then twisted into position and its lower margin is sutured to a raw area prepared for it in the mid-line of the lip at its

upper border. The raw area on the nose is closed by suturing its edges (Fig. 310 B), or by skin-grafting.

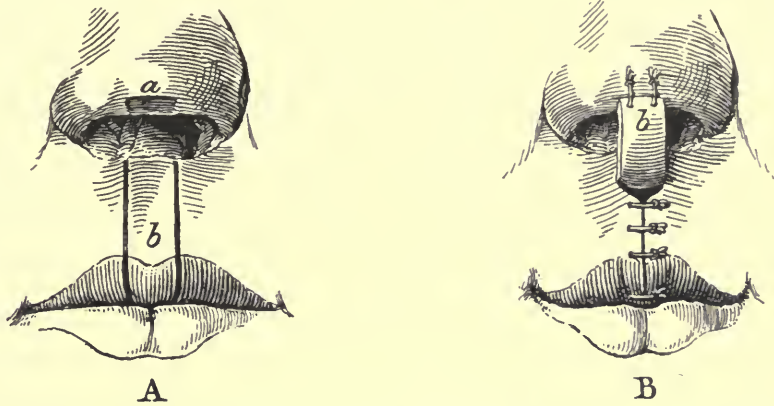

FIG. 309. FORMATION OF THE COLUMELLA FROM THE UPPER LIP. In A the flap *b* in the upper lip is marked out, and the raw area, *a*, on the tip of the nose, to which the free end of *b* is attached, is shown. In B the operation is completed.

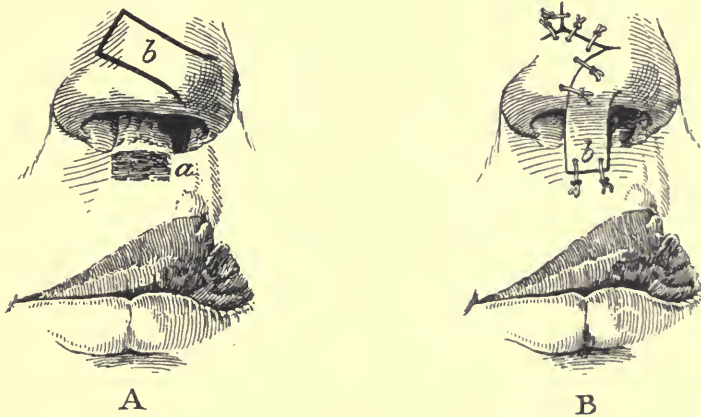


FIG. 310. FORMATION OF THE COLUMELLA FROM THE DORSUM OF THE NOSE. In A the raw area, *a*, on the upper lip, to which the extremity of the flap *b* is stitched, is shown. In B the operation is completed. The upper lip had also been restored.

PLASTIC OPERATIONS ON THE AURICLE

The deformities of the external ear which require a plastic operation are (1) undue prominence, (2) excessive size. Other malformations are occasionally seen, but these are often associated with defects of the

auditory apparatus, which preclude the necessity of performing any operation.

To reduce undue prominence, an incision is made immediately behind the attachment of the auricle, from the adjacent posterior surface of which a triangular or elliptical portion of the skin is removed. It is sometimes necessary to excise a portion of the cartilage, and the amount of skin and cartilage removed depends on the degree of the deformity. When the margins of the defect are sutured together, the ear should be in its normal position and it is well to unite the cut edges of the cartilage by separate sutures. The operation is not called for in young infants and children, and the result is sometimes very satisfactory; at other times it is disappointing.

Excessive size can be reduced by the excision of wedge-shaped pieces of the whole thickness of the auricle. The wedge is taken from the upper part if the vertical measurement requires to be diminished, the apex being placed near the external meatus, and from the middle portion if the transverse diameter has to be lessened.

CHAPTER III

PLASTIC OPERATIONS ON THE LIPS, MOUTH, AND FACE

GENERAL PRINCIPLES

THESE operations are frequently required to remedy defects which follow operations, and the deformities which are the result of injuries or the effects of cicatrization following ulceration. The earlier operations for the restoration of the lips were designed at a time when it was the custom to remove epitheliomata with a minimum amount of surrounding tissues. At the present day a much greater amount of these tissues is removed; thus most of the earlier plastic operations are inapplicable and need not be described. The whole thickness of the lip or cheek is not infrequently removed by an operation, and if the defect is not closed, great deformity will follow. The defects left by these extensive operations are very varied in shape and size; each case has to be considered on its merits, and the operations described are only those which have been actually used and found to be satisfactory. To obtain the best result a combination of methods may have to be employed; thus skin-grafting and the use of flaps are often necessary. In some cases, especially when the superficial portions of the cheek only have been removed or destroyed, skin-grafting alone is sufficient. In other cases, when the whole thickness of the cheek is deficient, flaps may be the only possible means of remedying the defect or deformity, and they may be obtained from the structures adjacent to the defect, or from distal parts, such as the neck or one of the upper limbs. Whatever method is employed, it is very probable that a certain amount of subsequent contraction will occur, and this is especially the case when the operation has been undertaken for the repair of a cicatricial deformity.

Curved incisions are especially useful in marking out the flaps, and they should be so placed that the resulting scars are as little visible as possible.

More than one operation is frequently necessary; it is also better to do what is required in separate stages rather than to endanger the whole effect by attempting too much at one operation. Secondary operations are often needed to correct some of the results of the primary operation and these should be delayed rather than done too soon.

When the whole of the lower lip has required restoration, although the external appearance may be very good, the muscular tone may be deficient, and the saliva is liable to dribble away from the mouth for some time, if not even permanently. There may be also some difficulty in preventing the escape of food during the process of mastication.

The proximity of the mouth and teeth introduces a septic element to all these operations; therefore before doing them all stumps should be removed, decayed teeth stopped, and the mouth rendered as aseptic as possible and kept so during the process of healing.

OPERATIONS ON THE LIPS: CHEILOPLASTY

For ectropion. Ectropion or eversion of the lip is generally the result of extensive cicatrization following burns or ulceration due

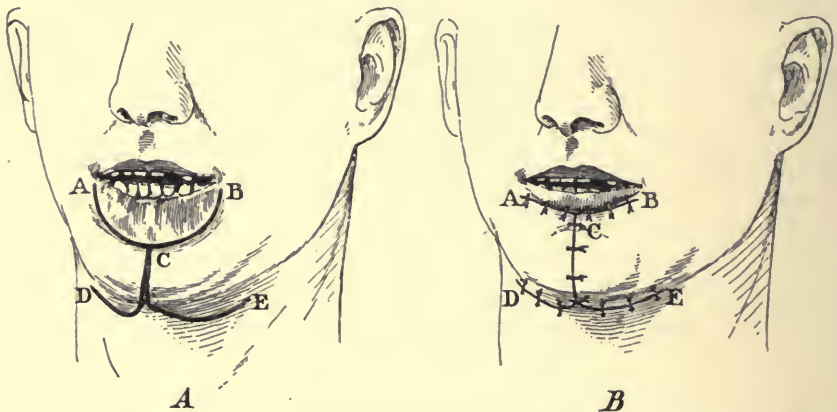


FIG. 311. OPERATION FOR ECTROPION OF THE LOWER LIP. In A the everted mucous membrane is separated as a thick flap by the incision A C B, and is then placed in its proper position. The curved incisions C D and C E mark out the flaps, A C D and B C E, which keep the lip in position. In B the method of suturing is shown. (After Cheyne and Burghard.)

to syphilis or lupus. In the worst cases the teeth and gums are exposed, and when the lower lip is affected the saliva constantly dribbles away.

The operation may be either easy or difficult according to the amount and depth of the scar tissue and the extent of the involvement of the muscles.

1. *For slight cases.* (a) A curved transverse incision is made at the junction of the mucous membrane and skin. The mucous membrane is separated sufficiently to form a flap to over-correct the deformity, and this flap must be as thick as possible. The raw area on the outer surface is then skin-grafted by Thiersch's method. It is difficult to maintain the grafts in position and to keep the wound from becoming infected from the mouth. In order to keep the flap in position it has

been suggested that a sharp-pointed stiff probe should be passed through the flap, entering it a quarter of an inch outside the angle of the mouth on one side and bringing it out at a corresponding place on the opposite side. The probe traverses the flap of mucous membrane and is left in position till the grafts have taken.

(b) An incision (AB, Fig. 311) is made along the edge of the everted mucous membrane from one side to the other. A vertical incision is then made from the mid-point of this transverse incision to the chin, and it is then carried in a curved direction in the submaxillary region of each

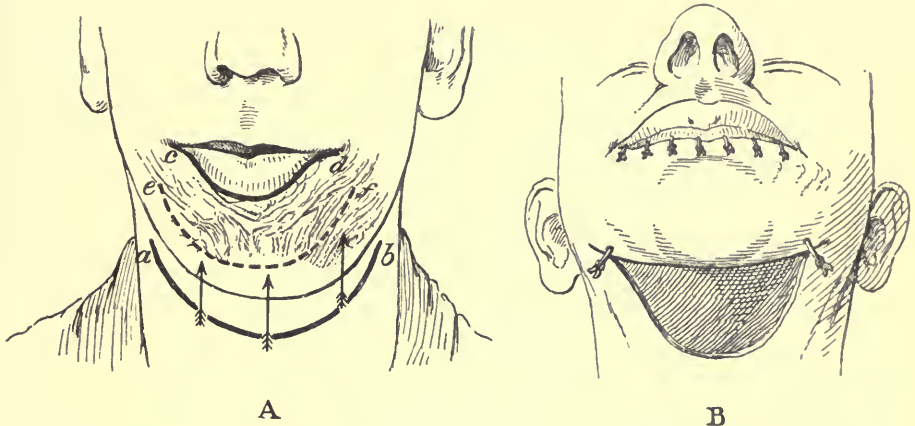


FIG. 312. OPERATION FOR SEVERE ECTROPION OF THE LOWER LIP, WITH MUCH SCAR TISSUE. The flap is taken from the submental region. In A, *ab* is the line of incision marking out the lower limit of the flap; *cd*, the incision for raising the mucous membrane to its proper position; *ef*, the line along which the scar tissue may be excised; the arrows indicate the direction in which the flap is displaced upwards. In B the flap is in position and sutured to the mucous membrane of the lip. The shaded area is the gap left by the displacement of the flap.

side for a sufficient distance. The mucous membrane of the lip is dissected up as a thick flap and restored to its natural position. The two flaps, ACD and BCE, containing the subcutaneous tissue are freed by undercutting and then united as in Fig. 311. The stitches may be removed on the fifth day.

2. For severe cases where there is much scar tissue (Fig. 312). An incision, *cd*, is made along the muco-cutaneous border of the lip, which is elevated to its proper position by free dissection through the scar tissue. If there is much scar tissue, portions of it may be excised. A transverse incision (*ab*, Fig. 312 A) four or five inches long is made in the neck about the level of the hyoid bone. This incision should be slightly convex downwards. The bridge of tissue between the two

incisions is completely raised from the underlying deep fascia, and then glided upwards over the chin. The flap is stitched by its upper margin to the edge of the mucous membrane of the lip (Fig. 312), and to prevent it slipping downwards, two or three buried sutures attach its deep surface to the periosteum of the jaw and muscles of the chin. The gap left in the submental region is closed, partly by undercutting the adjacent skin and partly by skin-grafting.

3. *In the worst cases* the scarring or destruction is so extensive that there is no possibility of obtaining flaps locally, and skin-grafting would not correct the deformity. In such a case, the flaps must be taken from

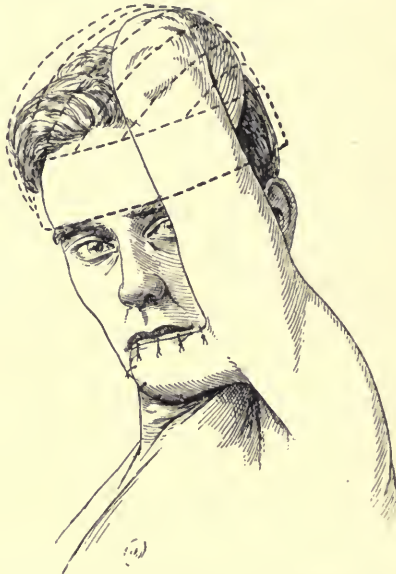


FIG. 313. RESTORATION OF THE LOWER LIP BY MEANS OF A FLAP TAKEN FROM THE UPPER ARM. The method of fixing the limb to the head is shown.

a distal part, such as the upper arm; Mr. Brown¹ of Leeds obtained an excellent result by means of this method. The child was aged 11, and some years previously had been severely burnt about the head and neck. Salivation was profuse; the head was drawn downwards, and to remedy this, a cut was made across the neck from angle to angle of the jaw; all the scar tissue was divided, the head was pushed into its proper position and the wide gaping wound which resulted was closed by flaps of skin taken from the shoulders. When this wound had completely healed the lip was restored by making a transverse incision at the junction of the mucous membrane and skin; the lip was elevated into its natural position

¹ *Brit. Med. Journ.*, Jan. 7, 1905.

and kept there by means of a stitch. The large raw area was then closed by suturing a flap taken from the bicipital surface of the arm to the margins of the gap, the arm being brought across the face and fixed there by an apparatus. The pedicle was divided at the end of fourteen days, the flap being living and healthy. The patient was kept quiet by small doses of opium, and the necessary dressings were done under an anæsthetic. Berger also speaks highly of restoring the lip by taking a flap from the arm in these severe cases. He divides the pedicle on the tenth or fourteenth day. Secondary operations are usually required

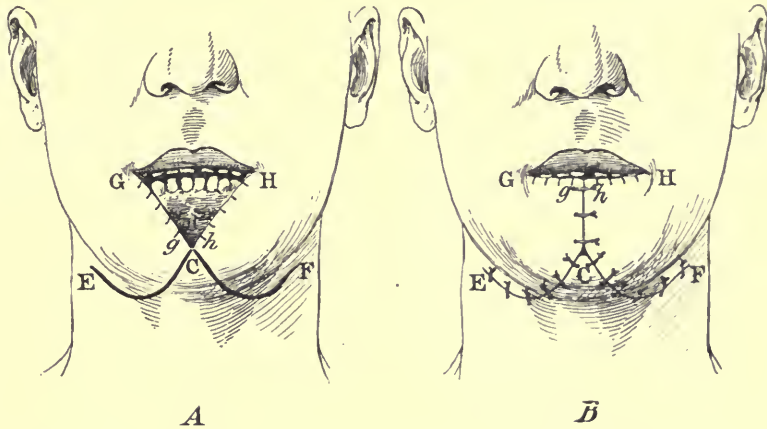


FIG. 314. RESTORATION OF THE LOWER LIP. In A a large V-shaped portion, G C H, of the lip has been removed. The mucous membrane is sutured to the skin along the lines G g and H h, to form the margin of the new lip. From the apex of the V (the point c), curved incisions, C E and C F, are made on each side into the submaxillary region. In B the operation is shown completed. It may be necessary to undermine the skin to bring the edges together. (After Cheyne and Burghard.)

to complete the adjustment of the flap and to restore the angles of the mouth.

Feeding is often a difficult problem in these cases and may be accomplished by means of a tube and funnel. The dressings should be kept as dry as possible and will require to be frequently changed.

For restoration of the lips. This operation is required after the removal of a carcinoma involving the whole of the lip. Either a V-shaped portion with the apex at the margin of the jaw or a quadrilateral portion of the lip and chin will have been removed.

First method (Fig. 314 A and B). From the apex of the V a curved incision is made on each side down to the level of the hyoid and is then continued backwards and upwards towards the angle of the jaw. The

whole thickness of the tissues of the lip and chin is dissected off the jaw and deep fascia, care being taken that the facial artery of each side is not divided. The edges of the original V are then brought together in the horizontal line to form the lip; the mucous membrane on the deep surface of each flap is elevated as far as may be necessary, so that it can be

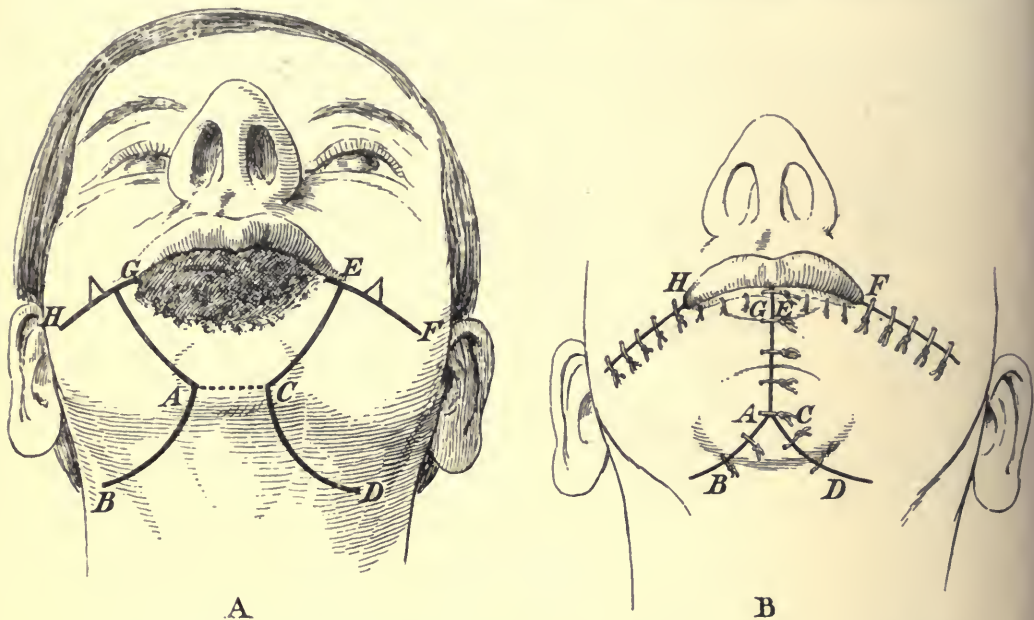


FIG. 315. RESTORATION OF THE LOWER LIP. In A the lines GA, CE show the incisions for the removal of an epithelioma. The dotted line AC completes the incision for the portion, GACE, to be removed; this should be more quadrilateral in shape. AB and CD are curved incisions in the submaxillary region; they extend down to the deep fascia. HG and EF are horizontal incisions carried outwards from the angles of the mouth; they divide the whole thickness of the tissues of the cheek, but the mucous membrane should be divided at a higher level, in order to allow of it being sutured to the skin to form the new lip. The flaps HGA B and FEC D are raised from the lower jaw and sutured as in B. The small triangular areas above HG and EF may be excised, if necessary, to make the flaps come together more easily. (Dowd.)

sutured without tension to the skin to form the red margin of the new lip. The edges of the flaps are then united vertically in the median line. The skin beyond the lower edges of the incisions in the neck will probably require to be undermined in order to close this portion of the wound.

Second method (Fig. 315 A and B). From the apex of the V or the lower angles of the quadrilateral space, curved incisions, AB and CD, are carried backwards on each side into the submaxillary region nearly as

far as the angles of the jaw. From the corners of the mouth horizontal incisions, EF and GH, are made outwards through the substance of the cheek for a sufficient distance to allow the flaps H G A B and F E C D to be approximated. These latter incisions are carried down to the mucous membrane, which is then divided one-third of an inch higher to allow of its being stitched to the skin without tension in order to form the new lip. The flaps are then glided inwards and united in the median vertical line. Any excess of tissue in the cheeks above the horizontal incisions may be removed by the excision of small wedge-shaped portions (Dowd).

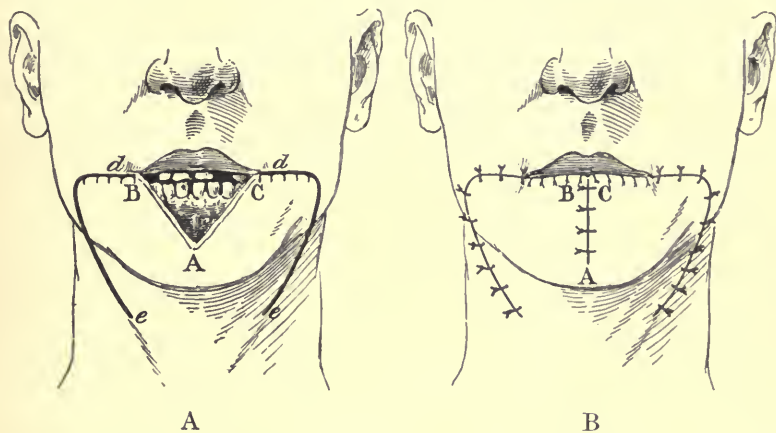


FIG. 316. RESTORATION OF THE LOWER LIP. In A the thick black line *d e* represents the incision on each side for raising the flaps: the new lip is formed by stitching the mucous membrane to the skin along the horizontal portion, *d*, of the incision. In B, *B A* and *B C* are shown united by sutures in the middle line, the flaps being displaced inwards to allow of this being done. (After Cheyne and Burghard.)

The facial arteries must not be damaged in dissecting up the flaps, which contain the whole thickness of the tissues down to the periosteum.

By these two methods the nerve-supply to the muscles in the flaps is preserved, and they are well nourished.

Third method (Fig. 316 A and B). In this method the flaps are obtained wholly from the cheek. A horizontal incision is made from the angle of the mouth on each side to the edge of the masseter, dividing the whole thickness of the cheek. The incision then curves downwards over the mandible and then forwards in the submaxillary region nearly as far as the hyoid. The mucous membrane is divided vertically at the anterior border of the masseter and horizontally where it is attached to the jaw. When the flaps have been raised sufficiently they are glided inwards to meet in the middle line, where they are united by their edges. Before

uniting the mucous membrane to the skin to form the lip, it must be separated so that there is no tension on it; with this object in view it is well to divide the mucous membrane in the horizontal part of the incision at a higher level than the skin and muscles. This method produces much more scarring on the face; the nerve-supply to the muscles is more interfered with and the vascular supply is inferior to that in either of the other two methods, and in marking out the flaps the pedicle must be made sufficiently wide. Free undercutting of the skin on the outer sides of the incisions will be necessary to close the gap left by sliding the flaps into their new position.

RESTORATION AFTER INJURIES AND SLOUGHING OR LOCAL ULCERATION

The operation required to restore the lips in these cases depends on the extent of the injury and the amount of destruction of the adjoining parts of the chin and cheek.

Fig. 317 is taken from a patient whose upper lip on the left side had been almost completely destroyed. A wide gap extended from the left angle of the mouth to the right of the mid-line. There was a large amount of scar tissue, and ectropion of the mucous membrane of the right half of the lip. The scar tissue was excised and the lip freely separated from the alveolus on the right side; in order to allow this portion of the lip to be glided over the defect, a horizontal incision was made at its junction with the right nostril and then curved round the margin of the latter (see Fig. 317, *de*). The margins of the gap on each side were completely refreshed, the mucous membrane of the lip being separated and preserved along the free border. The left cheek was widely detached from the upper jaw, the line of reflection of the mucous membrane from the cheek on to the jaw being divided as far as was found to be necessary. It was then possible to unite the refreshed surfaces; a broad lip was made, but with some eversion of the mucous membrane and leaving a notch in the free margin, which was corrected by a subsequent operation (Figs. 307 and 310).

This method of gliding the margins of the gap towards each other can be usually employed, if the cheek and lip be freely separated from the jaw. Their whole thickness must be elevated and the elasticity of the tissues is sufficient to allow of them being united without undue tension. Another great advantage of this method is that there is a minimum amount of visible scar tissue.

When the defect is so extensive that the whole length of the lip has been destroyed, Dieffenbach's operation (Fig. 318) may be employed. A quadrilateral flap is marked out on each side of the defect. The base

of the flap is at its lower end and thus a good blood-supply is ensured. The flaps which contain the whole thickness of the cheek are turned inwards, so that AB is sutured to CD , and the gap left by the displacement is closed by undercutting and uniting its edges.

In some cases not only is the lip destroyed, but there is also extensive loss of the adjacent tissues, such as the chin, and a very wide gap is left. If it is impossible to close such a gap by one of the methods above



FIG. 317. RESTORATION OF THE UPPER LIP, FOLLOWING AN INJURY. The dotted line abc represents the incision to free the left half of the lip and excise the scar tissue; de , an incision to allow the right half of the lip to be separated from the nose. The dark line at the junction of the mucous membrane and skin represents the incision to allow the former to be separated from the latter. By freely separating the cheeks from the maxillæ the margins of the defect were sutured, and the resulting lip is shown in Figs. 307 and 310. (Author's case.)

described it is necessary to take a flap from some distal part, such as the arm (Fig. 313, p. 696). A very successful case in which this method was employed is reported by Watts in the *Annals of Surgery* for January, 1905. Another method is illustrated in Fig. 319. On each side of the defect two rectangular flaps, $ABCD$ and $DEFG$, comprising the whole thickness of the cheek, are marked out. The mucous membrane at the upper margins, BC and EF , of each is stitched to the skin to form the new lip. The flaps are then displaced towards the mid-line, and their adjacent edges, CD

and DE, are sutured together. By freely raising the cheek from the bone, the gaps left by the displacement of the flaps may be closed (Fig. 319 B).

When the upper lip has to be restored, the proximity of the nose and the small amount of space render necessary some slight modifications of these operations. When only a part has to be restored, it is possible by freely separating the remainder of the lip from the jaws to bring the edges of the defect together (Fig. 317). In order to prevent the nostrils being unduly compressed, an incision should be made round the ala on each side (Figs. 317 and 320), removing, if necessary, an elliptical portion of the skin (Fig. 320). When the whole lip is removed or has

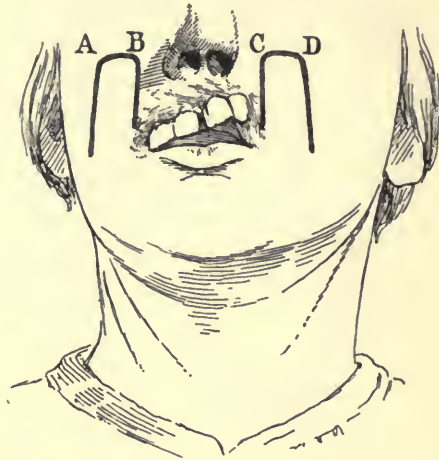


FIG. 318. DIEFFENBACH'S OPERATION. The flaps on each side of the gap contain the whole thickness of the tissues of the cheek and are rotated inwards, so that A B and C D are sutured. The scar tissue must be sufficiently removed. A similar operation may be employed to restore the lower lip.

been destroyed, the incisions round each ala should meet in the mid-line below the septum. If scar tissue is present, it must be excised. The flaps on each side are freely raised and the mucous membrane is stitched to the skin along the margins of the raw surface to form the new lip, which is then brought down to its proper position. The portions of the incision below the nostrils are stitched together to make a median vertical line, on either side of which the tissues will form the lip proper (Fig. 321).

Operations for microstoma (Fig. 322, p. 706). This condition is often the result of extensive ulceration, not infrequently syphilitic in origin; sometimes it is due to an injury or an operation.

To restore the mouth to its proper size, an incision (*a b*, Fig. 322 B) is made outwards on each side of the contracted orifice through the whole thickness of the cheek and sufficiently long to make the new mouth large

enough. The mucous membrane is carefully freed as much as possible from the tissues of the cheek and stitched to the skin to form the red margin of the lips (Fig. 322 c). If the mucous membrane is deficient the skin must be turned inwards and stitched to it. Especial care must be taken in the formation of the angles of the mouth, that the skin and mucous membrane in these places are very accurately united, in order to prevent recurrence of the contraction. In some cases it is better to dissect up at the new angle a thick triangular flap of skin with its

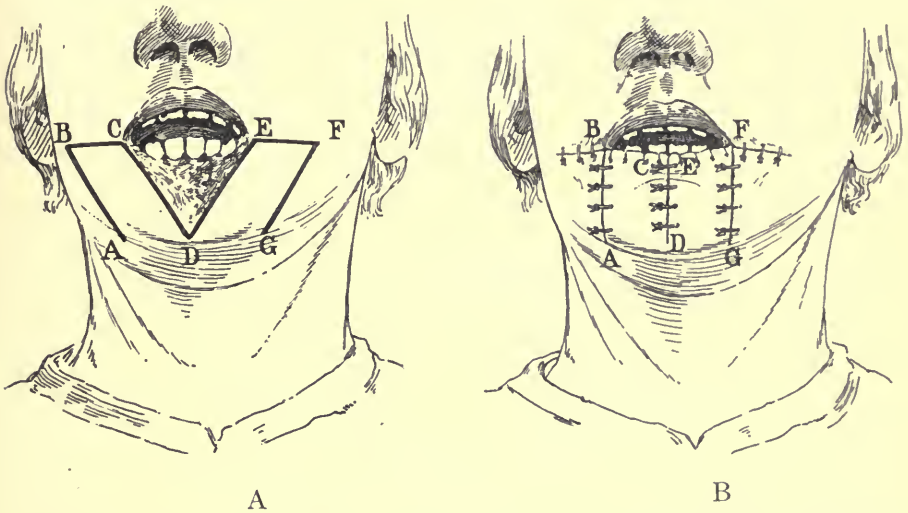


FIG. 319. RESTORATION OF THE LOWER LIP. In the left-hand figure the quadrilateral flaps, ABCD and DEFG, are marked out. They contain the whole thickness of the cheek, and the mucous membrane is stitched to the skin along BC and EF to form the new lip. In the right-hand figure the method of suturing the flap is shown.

base directed outwards. The mucous membrane is then divided as far as the new angle and the flap of skin turned inwards and sutured to the mucous membrane to form the angle of the mouth (Fig. 323, p. 707).

In all these operations the dressings should be of the simplest nature, and changed frequently. It is often best, *e. g.* in cases of restoration of the lips and for microstoma, not to apply any dressings at all. The vascular supply is so abundant and union occurs so rapidly that they are unnecessary. It is also most important to keep the parts as dry as possible, and this cannot be done if an elaborate dressing is used. Of course, if extensive incisions in the submaxillary region have been made, a dressing should be put on, but at the same time the mouth and lip should not be kept covered up.

It is perhaps hardly necessary to point out that before undertaking

these plastic operations on the lips and mouth, all signs of active disease and ulceration must be absent, or to emphasize the importance of curing any constitutional disease, such as syphilis.

PLASTIC OPERATIONS ON THE CHEEK

These are required to close recent defects remaining after surgical operations, or those which follow extensive destruction from ulcera-

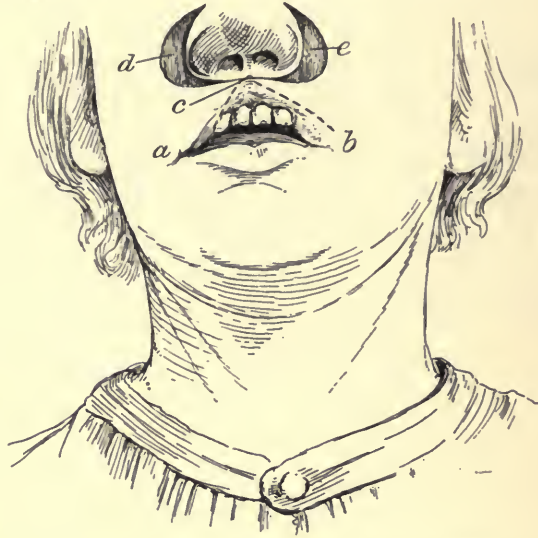

FIG. 320. RESTORATION OF THE UPPER LIP. The dotted lines indicate the line of incision for removal of the scar tissue. *d* and *e* represent elliptical portions of skin removed from each cheek in order to prevent compression of the nostrils when the lip is completed. It may not be necessary to remove these. The mucous membrane is stitched to the skin along *a c* and *b c* in order to form the free margin of the lip; *c* is then drawn downwards and the operation completed as in Fig. 321.

tion, cancrum oris, &c. In the latter group of cases there is often closure of the jaws, either from cicatricial contraction in the structures attached to them, or the cheek is firmly adherent to the jaw, and if it is separated by division of the adhesions, it is exceedingly likely to become again adherent. If the defect which is left by the removal of the whole thickness of the cheek is not closed by an immediate plastic operation, extensive contraction and adhesions to the jaw may also occur. There are, therefore, a number of factors to be considered which materially influence the result of these operations.

All active ulceration must be at an end and the condition of the teeth must be investigated, and when necessary, stumps must be removed and the mouth rendered as aseptic as possible.

Attempts must be made to remedy the cause of the closure of the jaws before undertaking the operation to close the defect. It may be possible to overcome the closure by stretching the cicatricial tissue by various kinds of gags. If the scar tissue is divided, some means must be employed to prevent its reproducing the closure, and this can often only be done by means of a flap. In very bad cases, the adhesions are so dense and firm that it is almost impossible to divide them completely and to prevent them reforming, so that an operation to make a false joint becomes necessary; or excision of the temporo-maxillary

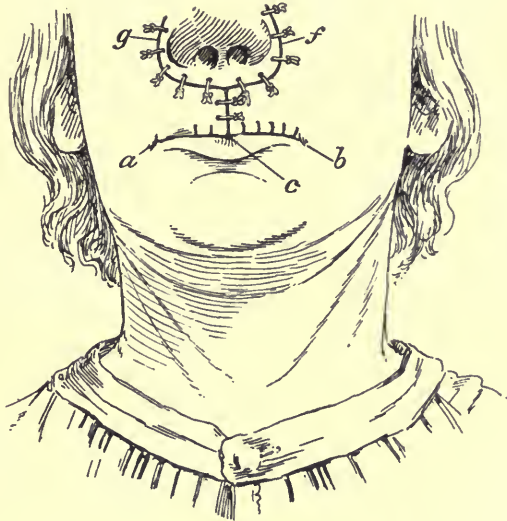


FIG. 321. RESTORATION OF THE UPPER LIP. COMPLETION OF THE OPERATION SHOWN IN THE PREVIOUS FIGURE. It is important to make the depth of the lip as great as possible.

joint may be undertaken, but the latter operation is not often beneficial in these cases.

When flaps are employed to close the defect, they may be obtained from the adjacent parts of the cheeks, (*a*) the masseteric area, (*b*) from above or below the defect; or (*c*) from more distal parts, viz. the forehead or temporal regions, and from the neck or from the arm.

When the flap is taken from the masseteric region, it is usually twisted on its pedicle so that its cutaneous surface is directed inwards. The continual growth of hair into the mouth is a serious drawback to the patient's comfort, and therefore in males, whenever possible, some other flap should be used. It may, however, be possible to dissect out the layer containing the hair bulbs; it is probably useless to attempt to destroy the hair follicles by X-rays. The outer surface of the flap

is covered by a superimposed flap taken either from some convenient

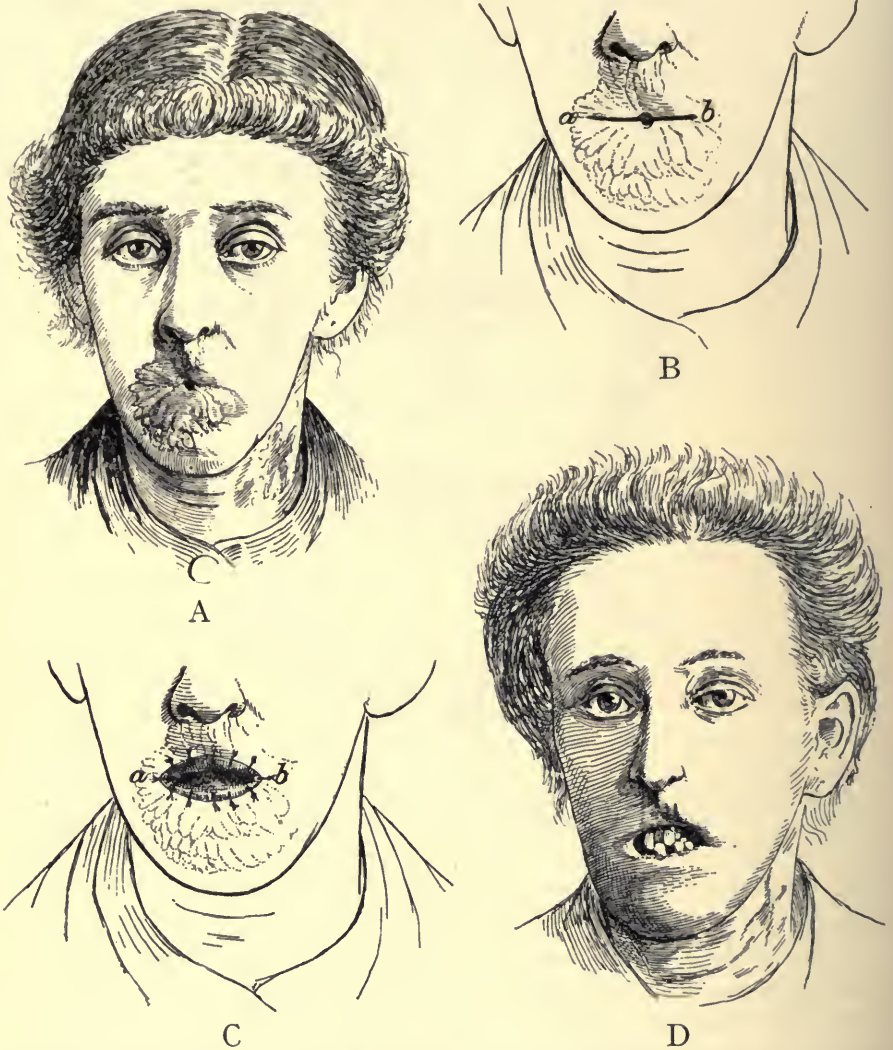


FIG. 322. OPERATION FOR MICROSTOMA. A shows the condition before the operation. In B the line of the incision *a b* for dividing the scar tissue, and in C the method of stitching the mucous membrane to the skin, is shown. Especial care must be taken in stitching the mucous membrane to the skin at the angles of the mouth. D shows the result some months after the operation. (*Mr. Burgard's case.*)

part of the neck or from the tissues over the inferior maxilla (Fig. 329 C), or it may be skin-grafted. When the flap is taken from above or below

the defect it is not necessary to reverse it—it can be glided into position with its raw surface inwards (Figs. 325 and 326); this will cicatrize and remain non-adherent to the mucous membrane of the jaw, and thus the mouth can be satisfactorily opened. If a flap is taken only from the cheek above the defect, considerable distortion of the eyelids and mouth may follow, and therefore this method is rarely available.

In cutting the flaps from the cheek, the direction and position of



FIG. 323. OPERATION FOR MICROSTOMA. FORMATION OF NEW ANGLE OF THE MOUTH. In A a triangular flap of skin is turned back and the dotted line shows the place of division of the mucous membrane. In B the flap is turned in around the new angle and sutured in position.

the parotid duct must be remembered and care taken not to injure it. After the flap has become united in its new position, subsequent operations will be required to form the angles of the mouth, &c.

A flap from the forehead and neck has the great advantage of being hairless. The former leaves a very obvious scar, but has a plentiful vascular supply. The raw area left on the forehead may be considerably diminished in size by undercutting the adjacent scalp and at once uniting the apposed edges, but in doing this the hair must not be brought

too low down, or the effect may be more conspicuous than a scar. Any uncovered area may be skin-grafted. The skin of the neck is said to shrink a great deal, but excellent results may be obtained by its use, provided the flap is made long enough.

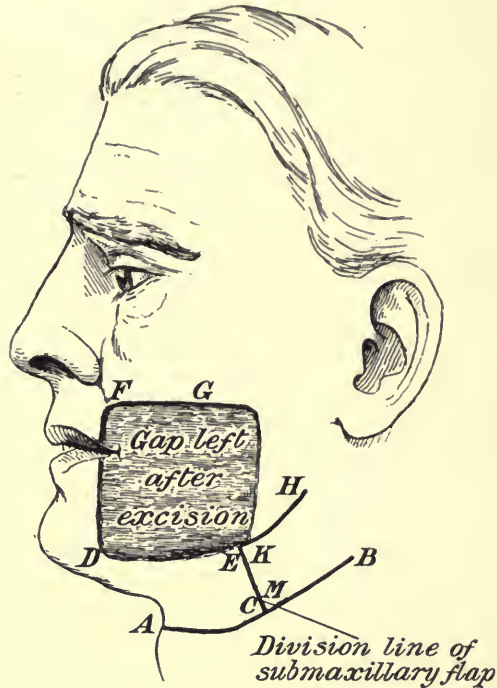


FIG. 324. METHOD OF CLOSURE OF A LARGE GAP IN THE CHEEK BY TRANSPLANTATION OF A FLAP FROM THE SUBMAXILLARY REGION. The patient had an epithelioma of the cheek and angle of the mouth, and its wide removal left the large gap shown in the figure. The incision $A C B$ was made low down in the submaxillary region and a large flap of skin and subcutaneous tissue was raised; part of the upper border of the flap was formed by the lower margin of the gap. The incision $E C$ divided the flap into two portions, $A C E D$ and $B M K H$, which were placed in the gap as in Fig. 325. The glands were removed from the submaxillary region after the flap had been raised. It will be noticed that the raw deep surfaces of the flaps are directed towards the mouth, which could be opened widely after union had occurred. (*Mr. Cunning's case.*)

Whatever method is used, the flap must be large enough to allow for its contraction, and thereby to reduce the subsequent distortion to the smallest amount.

Closure of a large defect (Figs. 324 and 325). A large defect, such as one left after the removal of an epithelioma, may be closed in the following manner:—A curved incision, $A C B$, is made low down in

the submaxillary region, and a flap of skin and the whole of the subcutaneous tissue is dissected up. The upper margin of this flap is formed by the lower edge of the defect, and from the point *K* the incision *KH* is carried backwards. Care must be taken not to divide the facial artery. The flap has therefore two pedicles, and is divided by the incision *EC* into two parts. The anterior portion, *ACED*, is twisted into the gap so that *EC* and *FG* are united by sutures; the posterior

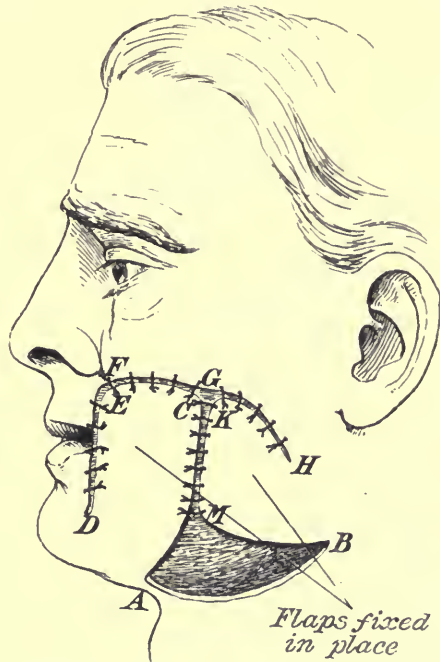


FIG. 325. RESTORATION OF A LARGE DEFECT IN THE CHEEK. COMPLETION OF THE OPERATION SHOWN IN FIG. 324. The margins of the flaps and defect are united by sutures. The raw area, *A M B*, was closed by undermining the skin below *A B*. Drainage tubes should be placed on the deep aspect of the flaps. (*Mr. Cunning's case.*)

portion, *B M K*, is then placed in the remainder of the gap, and the apposed edges are sutured to one another. A large raw area is left in the submaxillary region, and this is closed by freely undercutting the surrounding skin. A drainage tube is placed on the deep aspect of the flaps and brought to the surface at the lowest point of the operation area.

Another method of closing a large gap by means of a submaxillary flap glided upwards into the defect is shown in Fig. 326 *A* and *B*. The patient had a recurrent nodule of cancer in the position shown in the figure. It was excised with a wide margin of skin and deep tissues

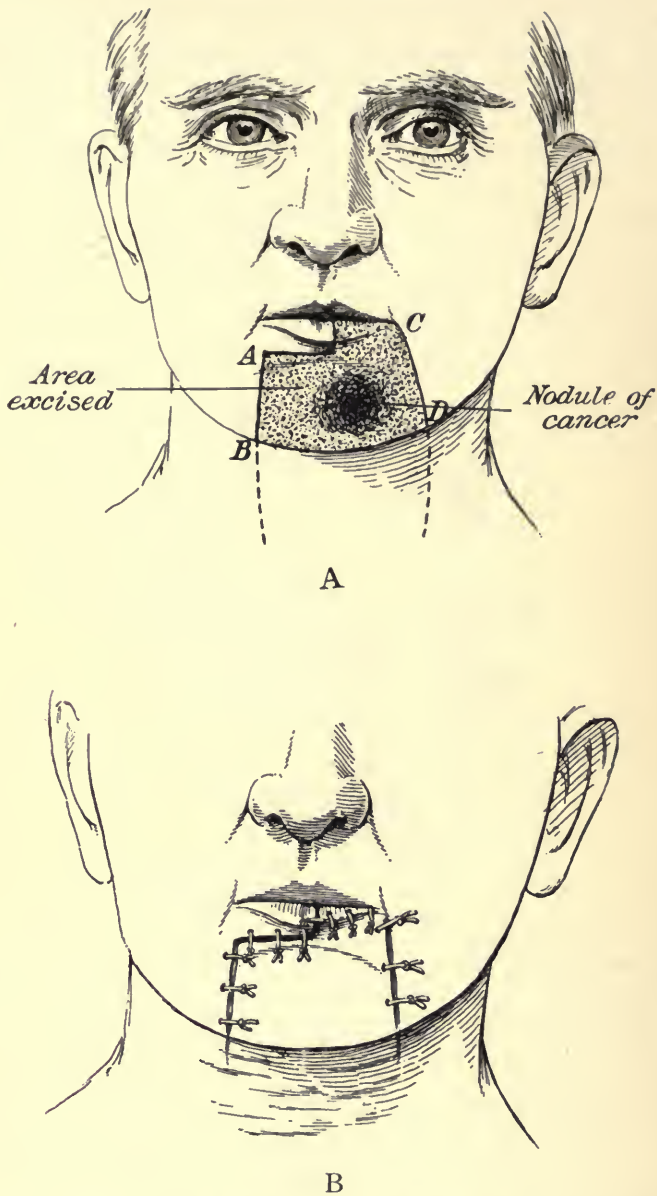


FIG. 326. CLOSURE OF A DEFECT IN THE CHEEK BY GLIDING A FLAP FROM THE SUBMAXILLARY REGION. In A the lines of incision for the removal of a nodule of cancer and the surrounding portion of the skin are shown. The dotted lines indicate the prolongation of these lines into the submaxillary region, in order to form a flap which was displaced upwards into the gap, B, and sutured to its margins. (*Mr. Cunning's case.*)

from all sides of it. The incisions AB and CD were prolonged downwards and a large rectangular flap was dissected up, having its broad pedicle at the lower end. The flap with its deep surface directed inwards was placed in the gap, and the apposed edges sutured to one another as in Fig. 326 B. A small amount of sloughing took place at the junction of the mucous membrane of the lip and flap. A drainage tube should be placed beneath the lower end of the flap. This method may also be

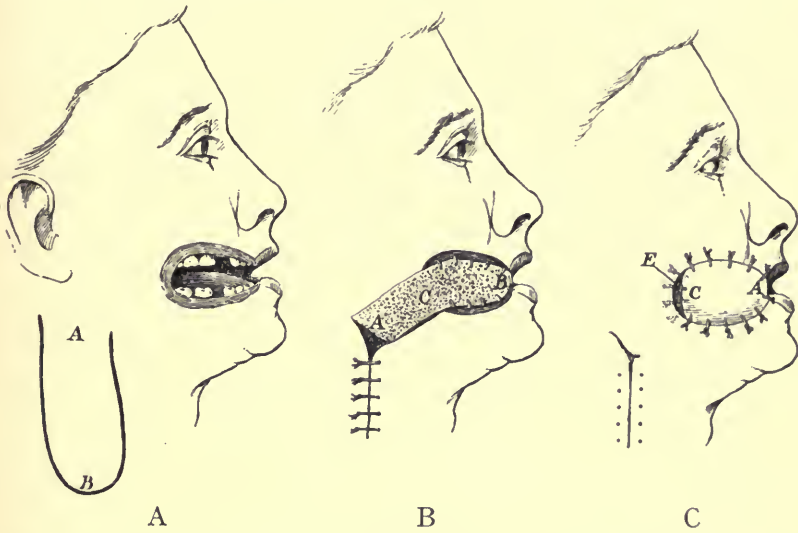


FIG. 327. ISRAEL'S METHOD OF CLOSING A DEFECT IN THE CHEEK. In A the flap AB is marked out, having its pedicle near the angle of the jaw and its lower end reaching nearly to the clavicle. In B the flap is stitched to the refreshed margins of the gap; the part AC bridges over the skin behind the defect. The raw area in the neck is closed by sutures. In C the part of the flap AC is shown folded over BC, so that the raw surfaces are in contact and the edges are united to those of the defect. A hole, E, is left communicating with the mouth. This is subsequently closed by the sutures (shown dotted) after refreshing the apposing edges. A secondary operation will be required to form the angle of the mouth.

usefully employed to close the gap left after the removal of a cancer situated at the angle of the mouth.

Israel closed a large gap by taking a long flap from the neck (see Fig. 327). The pedicle, placed near the angle of the jaw, is made broad whilst the lower end of the flap reaches nearly to the clavicle. The flap, consisting of skin and subcutaneous tissue, is placed in the defect, so that its distal extremity, B, is at the situation of the angle of the mouth, and the upper portion of the flap AC 'bridges over' the skin behind the defect. The edges of the flap and those of the defect are

then united by sutures. The pedicle is severed in about seventeen days. The posterior part, AC, of the flap (Fig. 327 B) is then folded over and placed on the raw outer surface of the anterior portion, A being placed at the angle of the mouth. The borders of the flap are united to the upper and lower edges of the margins of the defect. After union has taken place between the edges of the flap and those of the defect, it is necessary to close the opening, E, into the mouth, which exists at the place where the flap was reduplicated on itself (Fig. 327 C). This is accomplished by refreshing the raw edges of the gap and excising the posterior end of the flap. The two raw surfaces are then accurately united by sutures. A further operation will be necessary to make an angle for the mouth by dissecting up the mucous membrane of the lips and uniting it to the anterior edge of the flap. The wound in the neck is closed by sutures, after undermining the surrounding subcutaneous tissue.

Flap from forehead. This method may be employed as an alternative to taking the flap from the neck, or it may be used in conjunction with a neck flap, the latter being superimposed on the former (Fig. 328). The flap, consisting of skin and subcutaneous tissue, is made sufficiently large to enable it to be turned downwards, and fixed without tension to the margins of the defect, which are pared, except the upper which is not touched at this stage. As a rule the pedicle will be in the region of the zygoma, and must be made broad; the upper end of the flap may reach as high as the hair and anteriorly the edge will skirt the outer margin of the orbit (Fig. 328). It may be necessary to make a backward prolongation of the flap in order to provide a covering for any raw surface on the inner aspect of the ascending ramus of the jaw remaining after adhesions have been freely divided in this region, and to enable the mouth to be opened. When the flap is in position, its cutaneous surface will be directed inwards. The raw surface of the backward prolongation is sutured to the raw surface of the inner aspect of the jaw, by means of stitches which pass from the flap through the whole thickness of the cheek; the knots being tied on the cheek, the stitches can be easily removed.

The second flap for superimposing on to the raw surface of the deep or forehead flap is obtained from the skin and subcutaneous tissue of the neck (Fig. 328). This superficial flap has, of course, its cutaneous surface directed outwards, the two raw surfaces of the flaps being apposed to one another. It is sutured to the deep flap and to the margins of the gap, and is also used to close any portion of the defect not covered in by the forehead flap. It is well to provide for drainage, the tube being placed between the flaps and brought to the surface at the lower margin of the superficial flap. The raw area left by transplanting the neck flap

is closed by undercutting the edges and bringing them together by sutures in the usual way.

The pedicle of the forehead flap is divided in about a fortnight or three weeks. The upper margin of the gap is now refreshed and united to the upper edge of the deep flap by silkworm-gut sutures. Any redundant portion of the pedicle is replaced in the raw area on the forehead, the remainder of this area being skin-grafted.

Further operations will be required to make an angle for the mouth,

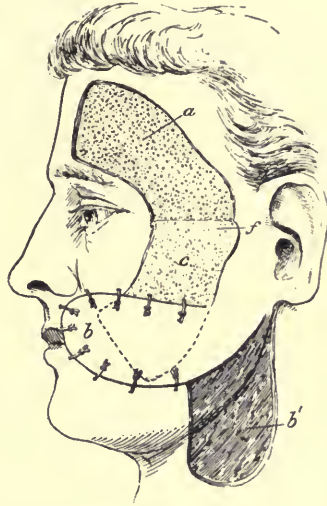


FIG. 328. METHOD OF CLOSING A DEFECT IN THE CHEEK BY SUPERIMPOSED FLAPS. A large forehead flap, *c*, is being used to close a defect in the lower part of the cheek, and has superimposed on it the flap *b* taken from the neck. This flap is also sutured to the margins of the gap. After the division of the pedicle of the forehead flap the upper edge of the defect is refreshed and united to the edge of this flap. *f* is the redundant portion of the forehead flap, and is replaced in the raw area *a*; *b'* is the raw area in the neck, which is closed by undermining its edges. Drainage must be provided at the lower borders of the flaps. Any uncovered area on the flap *c* may be skin-grafted.

and to correct any displacement of the eyebrow or eyelids. These operations are employed to close large defects, when there is no sound skin or the latter has been removed, as in some cases of excision of the upper jaw or of a rodent ulcer.

Closure of a small defect. (*a*) When the defect is small and the mouth can be freely opened, it may be possible to close it by dissecting up the cheek freely on each side of the gap; the cheek below the gap should be the more widely displaced in order that the eyelids may not be distorted. The edges of the gap are then accurately united by sutures.

Or a single flap may be taken from the cheek behind the gap (Fig. 329 A). The flap is turned forwards on its pedicle so that the cutaneous surface looks inwards. The pedicle should be attached a little distance behind the posterior margin of the defect and may be severed at the end of a fortnight; any redundant portion is replaced in the area from which it was taken. The outer surface of the flap is covered by skin-grafting or by a superimposed flap taken from the tissues over the lower jaw (Fig. 329 c).

(b) When the defect is small and there is inability to open the mouth on account of cicatricial contraction, **Gussenbauer's operation** (Fig. 330),

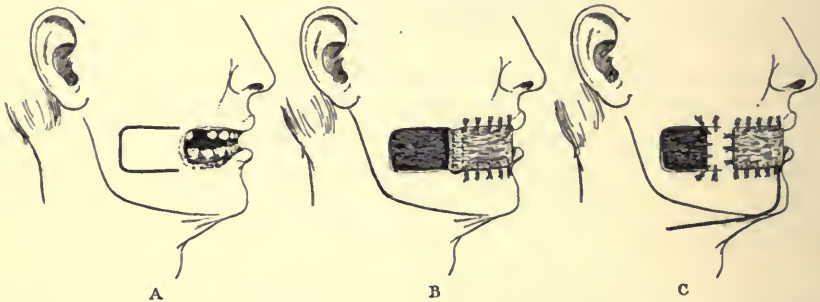


FIG. 329. TO ILLUSTRATE THE CLOSURE OF A SMALL DEFECT BY A FLAP TAKEN FROM THE SKIN OVER THE MASSETER. In A the flap is marked out, having its pedicle a short distance behind the gap. In B the flap is shown sutured to the refreshed margins of the gap; the cutaneous surface is directed towards the buccal cavity. In C the pedicle is divided after union of the flap and the edges of the gap has taken place; the redundant portion of the pedicle is also shown replaced in the raw area, the remainder of which is closed by skin-grafting or by a flap raised from over the lower jaw. The thick black line indicates the line of incision for raising this flap, which also covers the outer surface of the flap in the defect. Another operation will be required to form the angle of the mouth. (After Cheyne and Burghard.)

performed in two stages, is most useful, provided the skin is abundant. A flap of skin and subcutaneous tissue, somewhat broader at its posterior end than at its anterior end, is dissected up, the pedicle being placed about the anterior border of the masseter. The cicatricial tissue is divided from before backwards and the mouth widely opened. The skin flap is turned into the defect so that its anterior free border is inside the mouth; its edges are stitched to those of the defect, the raw (deep) surface of the flap being sutured to the inner aspect of the internal pterygoid muscle. At the end of four weeks the pedicle *bb* is divided and the posterior part of the flap is brought into the anterior part of the defect and sutured to its refreshed margins. The cutaneous surface of the flap is thus directed towards the mouth and the exposed raw surface is covered by a superimposed flap taken from over the lower jaw (Fig. 330 c).

Flaps from the arm have been used to close very large defects when other methods have been unavailable or inapplicable. The method of employing them is similar to that described under restoration of the lips (Fig. 313).

Defects in the mucous membrane of the cheek remaining after the removal of large portions, have been closed by transplanting a flap from the neck to the inside of the mouth through an incision made in the cheek in front of the masseter. The pedicle of the flap must be broad and the flap must be long. The raw surface of the flap is applied to the raw surface in the mouth and united to it by sutures, the pedicle being divided after the lapse of ten days to a fortnight. The excess of

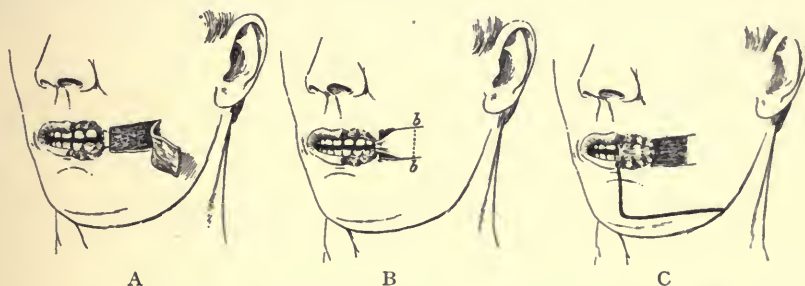


FIG. 330. GUSSENBAUER'S OPERATION. In A the flap is dissected backwards: the dotted lines indicate the incisions for dividing the mucous membrane. In B the anterior end of the flap is shown carried round into the mouth, preparatory to being stitched in position. *bb* is the line along which the flap is subsequently divided and turned forward into the gap, to the margins of which it is sutured in C. The thick black line in C indicates the incision for marking out the flap which is placed on the outer surface of the one filling the gap. The raw surface left where this flap is taken from may be skin-grafted or closed by undermining the adjacent skin. (After Cheyne and Burghard.)

flap is replaced in the gap left by its removal, the remaining portion being closed by undermining its edges. This may be done either at the first operation or when the pedicle is divided. Finally, the incision in the cheek is closed by silkworm-gut sutures.¹

OPERATIONS FOR ANKYLOSIS OF THE LOWER JAW

Ankylosis of the lower jaw not infrequently complicates the worst cases of destructive ulceration of the cheeks and is due to the presence of adhesions between the alveolar margins and the cheek, or to the formation of a large amount of scar tissue in the masseter and internal pterygoid muscles. In such cases excision of the condyle of the lower jaw is not a satisfactory operation, because the cause of the ankylosis

¹ See Keetley, *Lancet*, March 4, 1905.

remains untouched, the seat of the mischief not being in the joint. Division of the cicatricial bands alone is often insufficient, as they are liable to reform. Something may be accomplished by forcible stretching of the adhesions under an anæsthetic by means of a powerful mouth gag, repeating the operation from time to time, and in the intervals the jaws must be kept separated by constantly wearing a prop between the teeth. In the majority of cases it will be necessary to perform what is known as Esmarch's operation (Fig. 331), in front of the cicatricial tissue. This operation consists of the removal of a wedge-shaped piece of bone from the horizontal ramus in front of the masseter. The base of the wedge is at the lower border of the bone and should not be less than one and a quarter inches long; the apex is at the alveolar margin and is half

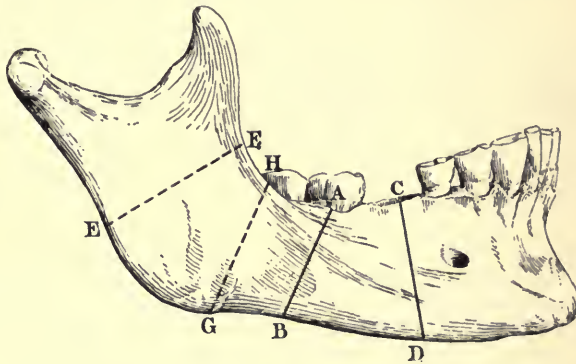


FIG. 331. OPERATIONS FOR ANKYLOSIS OF THE LOWER JAW. A B and C D represent the lines along which a portion of the horizontal ramus is removed; E F and G H, the lines for excision of a part of the ascending ramus.

or three-quarters of an inch long; in a child these measurements will be proportionately reduced. An external incision, somewhat longer than the base of the wedge to be removed, is made along the lower border of the jaw. The soft parts are raised from both surfaces of the bone, which is then divided by means of a fine saw along the lines indicated. Any irregularities in the bone are smoothed down by means of bone forceps. The wound is closed, a small opening being left for a gauze drain, which is removed in the course of two or three days.

Instead of removing the bone from the horizontal ramus, a wedge may be taken from the angle of the jaw, or a portion of the ascending ramus may be excised. An incision is made along the posterior border of the jaw, and carried as low as the angle; if necessary it may be continued forwards along the horizontal ramus. The periosteum, with the masseter and internal pterygoid muscles, is raised from each aspect of the ramus for a sufficient extent; the bone is divided by a fine saw, enough being

taken away to enable the mouth to be freely opened and to prevent a recurrence of the closure. This method is suitable for those cases in which the cicatricial contraction is in the masseter and internal pterygoid muscles.

The results of these operations vary; sometimes the effect is very good; at other times it is very disappointing. A good deal depends on the care which is taken with the after-treatment. The passive opening of the jaws (under an anæsthetic if necessary) must be assiduously carried out for a long time, in order to prevent too firm fibrous union taking place between the ends of the divided bone, and it is advisable for the patient to wear a mouth prop as much as possible.

PLASTIC OPERATIONS FOR SYPHILITIC AFFECTIONS OF THE PALATE

As a result of syphilitic ulceration, the hard or soft palate may be more or less completely destroyed. In the hard palate a round or oval hole is usually produced by necrosis of the palatal processes of the superior maxillæ; when the soft palate is affected, the loss of tissue is often extreme and the most striking feature is the formation of adhesions between the remains of the palate and the pharyngeal wall. These may be so abundant as to completely shut off the naso-pharynx from the oro-pharynx, or the communication may be so small that only a probe or small-sized bougie can be passed through it. Nasal respiration may be rendered difficult: much mucus may collect in the nose and only be got rid of with difficulty, and progressive deafness, accompanied by attacks of earache, may follow. The voice becomes nasal and indistinct, and this is the usual symptom which the patient wishes to have remedied.

If the perforation is in the hard palate, an obturator made by a dentist is generally the best method of treatment. It should never fit into the hole tightly, but always take the form of a plate, which can be readily removed for cleansing purposes and easily replaced. Such an appliance will restore the natural character of the voice and prevent food and liquids passing into the nose. If it is desirable to operate, the hole may be closed by means of flaps of the muco-periosteum, raised on each side of it, as in the ordinary operation for cleft palate, the raw edges being united by silkworm-gut sutures. A better method is to raise the flaps as in Davies-Colley's operation for cleft palate, making the flaps as large as possible in order to allow for their subsequent contraction.

When the soft palate is adherent to the pharyngeal wall, the operation is performed in the following manner:—A Smith's gag is introduced into the mouth, which is opened as widely as possible compatible with free respiration. The adhesions are divided by means of an angular cleft-

palate knife or by curved scissors; a cleft-palate raspator is also sometimes useful in separating them. There may be a good deal of hæmorrhage, but by keeping the head low, and using sponge-pressure, it is controlled without much difficulty. The soft palate is drawn forwards as much as possible, and fixed by silkworm sutures either to the muco-periosteum of the hard palate, or by sutures, one on either side, passed through the whole thickness of the palate, the free ends being brought forwards and fixed round the front teeth. Instead of silkworm-gut sutures, silver wire may be employed. The sutures are left to cut their way out, which they will do in the course of one or two weeks. During this time, healing of the raw surfaces will have taken place to a considerable degree, but it will be necessary to keep the opening into the naso-pharynx patent by the regular passage of bougies, and from time to time by stretching the soft palate with a blunt hook or the finger passed behind it from the mouth. During the stage of healing after division of the adhesions, union of the raw surfaces may be prevented by using a piece of lead plate cut to the full breadth of the naso-pharynx and so bent that one arm of it rests on the upper surface and the other on the lower surface of the palate, the separated margin being received between the two portions of the plate and apposed to the bend in it. Silk threads being fixed to the four corners of the piece of lead, the two from the upper corners are passed, one through each nostril, and the two lower ones are brought forward across the hard palate to the interval between the lateral and central incisor teeth of each side. The upper and lower threads of each side are then tied together in front, over the upper lip, after being passed through a piece of rubber tubing, in order to prevent them cutting. The plate is left in position for a fortnight.¹

In all these cases the chief difficulty is to prevent recurrence of the adhesions. The immediate results of the operation are often good, but in the course of time contraction frequently occurs again. As an almost complete occlusion of the passage from the naso-pharynx to the oro-pharynx may exist without causing any evidences of discomfort, these operations should not be undertaken in the absence of some definite symptoms such as those already enumerated, nor should they be performed so long as ulceration is present, or shortly after the ulcer has healed, and bearing in mind that the patient is syphilitic, iodides and mercury should be given in full doses.

¹ Robinson, *Trans. Laryngol. Soc.*, vol. xiv, p. 106.

CHAPTER IV

OPERATIONS FOR CONGENITAL AND ACQUIRED DEFORMITIES

OPERATIONS FOR WEBBED FINGERS

GENERAL PRINCIPLES

WEBBED fingers present varying degrees of deformity.

1. The web may be only slightly longer than normal.
2. The fingers may be united by a band of tissue extending their whole length. This band may either be thick and loose, or thin and binding the fingers closely together.
3. The fingers may be united by bone, the phalanges of the individual fingers being more or less completely fused.

The operative measures to be adopted depend on the variety and degree of the union, and it not infrequently happens that different operations have to be used in conjunction ; if several fingers are affected one method may be suitable for some, and another for the other fingers. A great variety of operations have been practised, but none of them are completely satisfactory except in the cases where the web is broad and thick and there is plenty of tissue. The web has a great tendency to re-form, and when the union is close and thin, there is a great likelihood of subsequent contraction of the fingers taking place. If the separation of the fingers leaves a scar on the palmar aspect, flexion is very likely to follow from its contraction. Unless it is quite certain from the mobility of the fingers on one another that there is no bony union, an X-ray photograph should be obtained before an operation is undertaken ; the extent of the union and the possibility of improving the state of affairs can then be more accurately estimated. If several fingers are fused together and a shapeless digit is present, it is generally best not to attempt any operation at all ; though unsightly, such a hand is often very useful and may be made much worse by an unsuccessful operation. If two fingers are united by bone and their usefulness is thereby considerably impaired, some improvement may be obtained by the removal of the bones belonging to one finger. In these cases it is not possible to give the patient two separate fingers as the covering of skin is insufficient.

The hand in cases of webbed fingers is smaller and does not develop to the same extent as the normal hand. Therefore, to improve the use-

fulness of the hand, to encourage its development and to remove if possible an unsightly deformity, it may be necessary to operate, but this should not be done before the third or fourth year. It is not advisable to operate in early infancy, for the parts are so small and the tissues so delicate that a good result cannot be expected, and if the operation is a failure, the prospect of success from later operations is much diminished. It is advisable also not to attempt to correct the deformity of all the fingers by one operation, but to take them in pairs. The effect can then be observed, and the succeeding operations modified, or if necessary entirely changed. Some weeks or months may elapse between the dates of the operations; this applies especially to cases in which flaps have been taken from the dorsum of the hand—the succeeding operations should not be undertaken until the scar and the flap are soundly healed.

Whatever method is adopted, the dressings must be applied to each finger in such a way that they are kept separate during the healing process.

The after-treatment is most important. To prevent subsequent contraction it is necessary that the patient should wear a splint, at first both by day and night, subsequently at night only. The exact time the splint should be worn varies, but in any case it will be for months. When the splint is being worn constantly, it should be removed daily in order that passive movements may be carried out. Some form of moulded splint is the best; it should be applied on the dorsum of the hand and fingers, and should be long enough to reach from just above the wrist to the ends of the fingers. It must be well and carefully padded, so as not to exert pressure on the parts.

The available methods of operating are:—

1. Simple division of the web and union of the raw surfaces.
2. Division of the web combined with the formation of a triangular flap at its base.
3. The formation of a dorsal and palmar flap from the conjoined fingers (Didot's operation).
4. A combination of one of these methods with skin-grafting, where there is not enough tissue to cover all the raw surfaces.
5. Removal of the bones of one finger when there is osseous union.

SIMPLE DIVISION OF THE WEB AND UNION OF THE RAW SURFACES

This method may be used when the web is large and thick, and may be combined with perforation of the apex of the web by means of a stout silver wire which is kept *in situ* till the perforation is healed and a round hole remains (Fig. 332). The web is then divided throughout the rest

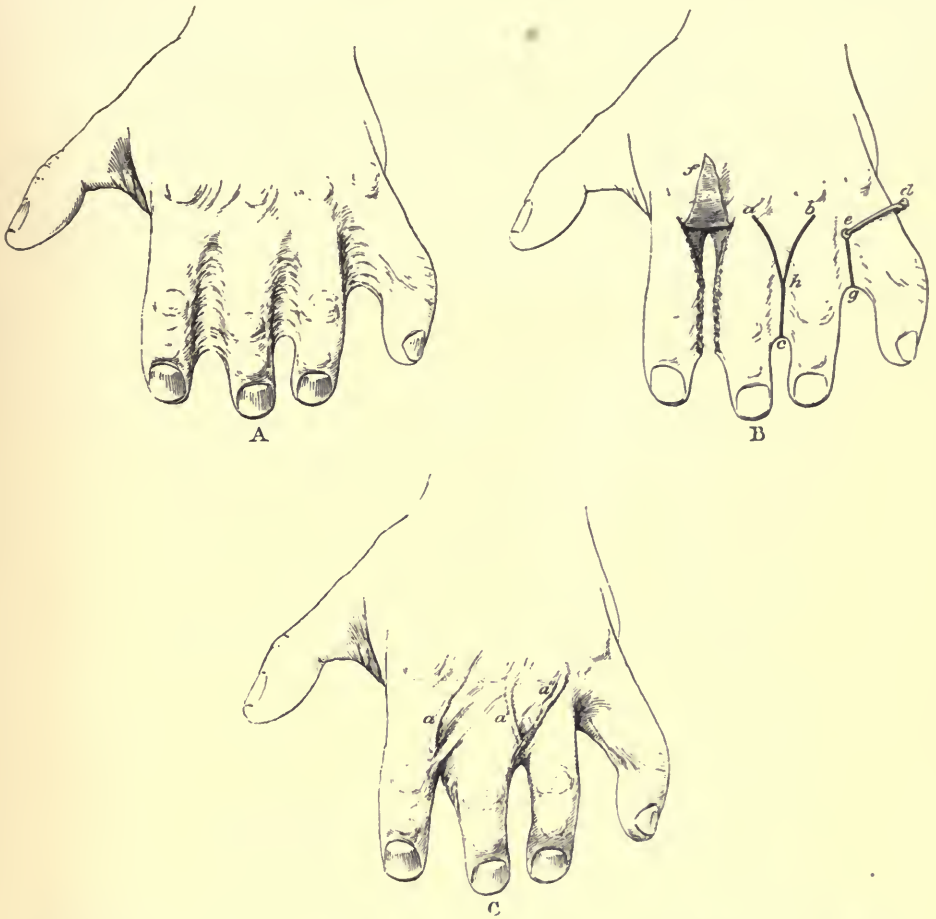


FIG. 332. OPERATIONS FOR WEBBED FINGERS. In A a well-marked web is shown between each of the fingers. In B two methods of operating are shown. The web between the third and fourth fingers has been perforated at *e*, and a stout silver wire, *ed*, has been inserted. This is left *in situ* till the perforation is cicatrized. The remainder of the web is then divided along the line *eg*, any redundant portion is removed, and the raw edges are sutured to one another on the sides of each finger.

A better method of operating is shown on the webs between the other fingers. *ah* and *bh* show the incisions marking out a dorsal V-shaped flap; *hc* is the incision for splitting the remainder of the web; *f* is the flap dissected up: this is sutured to the palmar surface between the fingers to form the new web. The raw area on the sides of each finger is closed by stitching the margins together after any redundant portion has been removed. In C the result of operating by this method on the hand A is shown. The webs between the first and second and the second and third fingers have re-formed to some extent; *a*, *a'*, *a''* are the scars. The operation on the web between the third and fourth fingers was quite successful. (*Author's case.*)

of its extent ; any excess of tissue is removed and the raw surfaces of the two flaps on each finger are united by sutures. It is a tedious and not very satisfactory method.

TRIANGULAR FLAP AT THE BASE OF THE WEB

This method should be employed when the web is a broad one, whether it is partial or complete. A triangular flap having its apex at the centre of the web and its base opposite the metacarpo-phalangeal joint of the finger is marked out on the dorsal aspect. The flap must be long enough to be

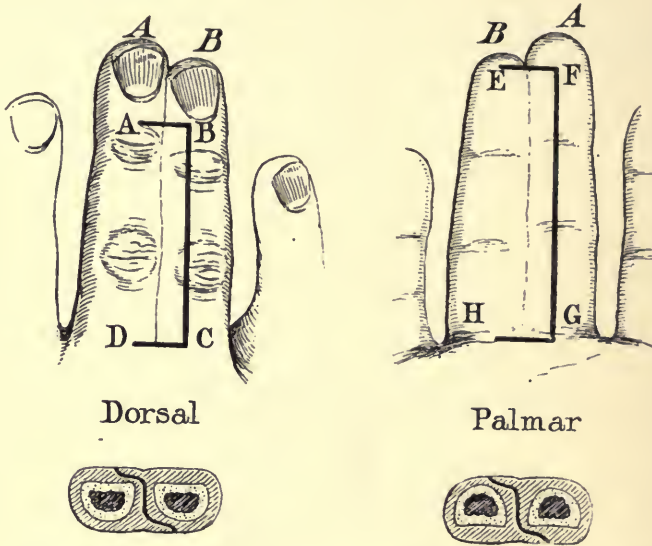


FIG. 333. DIDOT'S METHOD OF OPERATING FOR WEBBED FINGERS. The lines of the incision for the dorsal and palmar flaps are indicated. The smaller figures represent a transverse section of the fingers, and show the direction of the line of separation. The dorsal flap should be sufficiently broad to be united to the incision on the palmar aspect of the finger.

turned into the palm and stitched in position without tension, and it must also be as thick as possible. The remainder of the web is divided along its median line (Fig. 332 B). The flap is then passed between the fingers and its apex stitched to the palmar edge of the cleft, the margins being united to the skin of the edges of the wound at the sides of the fingers. Any excess of tissue left after splitting the web, or any protruding fat, is removed and the raw surfaces on each side of the fingers are then united.

Instead of a long dorsal flap, two smaller flaps, one from the dorsum and one from the palmar aspect of the web, may be employed. These

flaps having been dissected up, and the remainder of the web divided, are then united together and form the new web. The raw edges of the web attached to each finger are then sutured together as accurately as possible, any excess of subcutaneous tissue being removed.

DORSAL AND PALMAR FLAPS. DIDOT'S OPERATION

(Figs. 333 and 334)

This method is employed when the web is narrow and thin. An incision, *BC*, is made along the dorsal aspect of one finger, and at each end

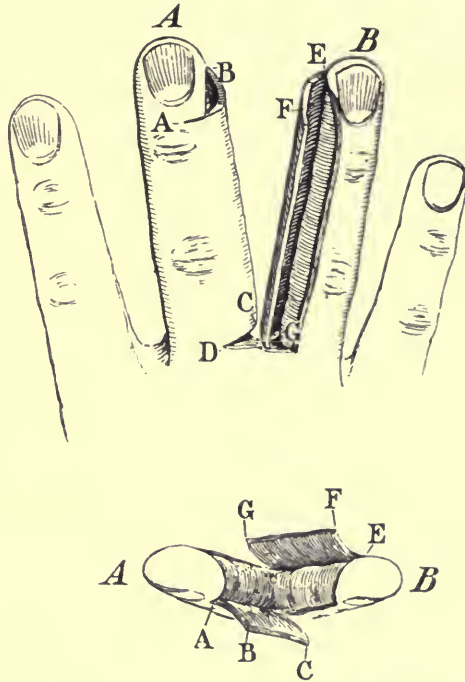


FIG. 334. DIDOT'S METHOD OF OPERATING FOR WEBBED FINGERS. This figure shows the flaps dissected up and being applied to the raw area on each finger. The lower figure is another view of the same stage.

of this incision, short incisions, *AB* and *DC*, are made. On the palmar aspect of the other finger an incision, *FG*, is made, and transverse cuts, *EF*, *HG*, are made at the ends of the longitudinal incision. These flaps, which should be as thick as possible, are carefully dissected up, the rest of the tissues between the fingers being divided and their separation completed. One finger (*A*) thus has a dorsal flap, and the other (*B*) has a palmar flap, attached to it. Each flap is carried round the side of its own finger and stitched in position to the edges of

the raw surface. It rarely happens that both flaps are sufficiently large to cover the whole of the raw surfaces ; one finger may be well covered and the other incompletely. Skin-grafting will be necessary to cover any raw area, and should be carried out at the same operation.

There is also a difficulty in making a satisfactory web unless it is possible to make a triangular flap from the dorsum of the hand between the bases of the fingers. Again, the finger which has the scar on its palmar aspect is more likely to become flexed, and therefore, in planning the flaps, an endeavour should be always made to give this finger the better flap to cover it, that is, the dorsal flap should be the larger. Lastly, from the thinness of the tissues used to form these flaps, the operation should not be done before the patient is four or five years old.

REMOVAL OF THE BONES OF ONE FINGER WHEN THERE IS OSSEOUS UNION

If it is necessary to perform an operation when osseous union is present, a rectangular flap is dissected up from one side of the conjoint finger, and the bones of one finger removed after the tendons, &c., have been separated. The flap should be taken from the palmar aspect, and after removal of the bones, it is applied to the raw surface and sutured with silkworm-gut. A dorsal scar is thus made. The majority of these cases are, however, often best left without an operation.

OPERATIONS FOR SUPERNUMERARY DIGITS

These are a not infrequent congenital deformity ; they are often symmetrical, either the fingers or the toes being affected. From an operative point of view, the most important point is the method of union of the digit. This may be simply by a band of fibrous tissue, or the extra digit may be attached, with or without an articular surface, to the side of the metacarpal or metatarsal bone. Much more rarely the extra digit has also a metacarpal or metatarsal bone, and then there is an articulation with the carpus or tarsus. Sometimes the terminal phalanx alone is affected and is more or less completely divided, so that a bifid digit results.

If the union is fibrous, all that is necessary is to cut through the bond of union after making an elliptical incision in the skin round its attached base so as to form a flap and then unite the edges by sutures. When there is an articular surface or projecting piece of bone on the side of the metacarpal, this must be removed after the amputation, so as to leave a smooth level surface on the bone ; otherwise, as growth continues, a very obvious projection will be formed. Flaps

consisting of the whole thickness of the tissues down to the bone are dissected up, care being taken in shaping them that they do not contain any excess of tissue. If the supernumerary digit has an extra metacarpal bone, this must be removed together with the digit; any projecting articular facet left after the removal of the extra bones must be smoothed down with a chisel, and, as some part of the carpal joints may be opened, strict precautions against sepsis will be necessary. The operation is performed in the manner described on p. 112.

When the terminal phalanx is bifid, it is necessary to remove one portion, and that part which is the more deviated from the line of the digit should be excised. If the phalanx is only partially divided, it must be completely split down to its base and one part removed. It may be necessary to divide the ligaments of the joint, in order to put the remaining part of the phalanx in a straight line with the rest of the finger. By means of a splint fixed round the wrist and applied to the finger, the latter must be kept as straight as possible during the healing process and for some time after. Massage or passive movements are required to restore the mobility of the joints, but the splint will have to be worn for some weeks.

When the toes are affected similar methods of treatment should be employed, if it is thought desirable to do any operation, but very often the presence of the additional toe causes no inconvenience.

OPERATIONS FOR ACQUIRED CONTRACTIONS OF THE FINGERS

General principles. Acquired contractions and adhesions of the fingers are often due to burns and scalds. These cases are most difficult to treat, (1) because of the extensive cicatrization and adhesions between the various structures; (2) the great liability to reproduction of the deformity, as healing and contraction occur after the parts have been freely separated; (3) the skin is usually destroyed and replaced by thin scar tissue which is almost useless for any plastic operation; and (4) the small size of the parts and the difficulty in getting healing to take place by first intention. When the contraction is one of long standing the ligaments of the joints may require division before the fingers can be straightened. It is impossible to describe these operations in detail, for each case will present features of its own. The first thing to do is to divide and remove enough of the cicatricial bands to reduce the deformity to a minimum. The result will be that a raw area of greater or less extent is produced; very often raw areas at the sides and bases of the fingers will be in close contact, and unless these are kept separate during

the healing process they will become again united to one another. The next step is to cover in the raw surfaces with skin-grafts. These may be the ordinary Thiersch's grafts, or a graft of the whole thickness of the skin, cut after Wolfe's method; again, in the case of the palm, it may be possible to use a flap taken from the buttock (Fig. 339) or thigh. If the contraction is confined to the flexor aspects of the fingers the scar should be excised and by undercutting the adjacent skin the edges of the raw area may be brought together by means of sutures.

Whatever is done to remedy these deformities, a certain amount of re-contraction will occur. Still, on account of the crippling nature of the contraction, it is advisable to attempt to improve the state of affairs and it is better to perform several operations rather than to try to effect complete restoration by one operation.

In all these cases the after-treatment requires much careful attention and has to be continued for a long time. Active and passive movements of the fingers must be regularly carried out as soon as healing is complete. Appropriate splints, specially adapted for each case, must be worn at first by day and night, and subsequently at nights only, for many months.

OPERATIONS FOR DUPUYTREN'S CONTRACTION

The operations for the relief of this deformity may be done either subcutaneously or through an open incision.

Subcutaneous division of the fascia through multiple small punctures, commonly known as Adams's operation, is the method most frequently employed. A sharp-pointed small tenotomy knife is introduced parallel to the surface of the skin. The cutting edge is then turned towards the contracted fascia, which is made taut by stretching the affected finger. The bands are divided one after the other, as many as possible through the same puncture. When this has been done at one place, the knife is withdrawn and introduced at a fresh spot, and more of the bands are divided. If the skin and the palmar fascia are closely adherent, it may be necessary to sever the adhesions by passing the knife horizontally between these structures.

In performing this operation, several details require careful attention. The skin of the palm must be thoroughly disinfected and then softened by frequent soaking in water. Especial attention is to be paid to the removal of dirt from the furrows caused by the contraction, also to remove the thickened epidermis. The division of the bands must be carried out thoroughly and carefully in a systematic manner; but at the same time the relation of the digital vessels and nerves to the deep aspect of the fascia should be remembered, and injury to these structures avoided. It is better to make many punctures rather than to attempt the division of

all the bands through one or two; the punctures should be made where the skin and fascia are not adherent; and if adhesions are present they must be divided. In bad cases it is better either not to attempt to completely straighten the fingers at the first operation, but to trust to the after-treatment to effect this, or else to operate a second time. If these precautions are not taken the wounds may gape widely, or the adherent skin may be lacerated and the resulting scars become the starting-point of a recurrence of the deformity.

The operation being completed, an antiseptic dressing is applied to the palm and fingers. A palmar or dorsal splint, which should reach on to the forearm, is then fixed to the hand and fingers which are carefully bandaged to it. The fingers must not at first be over-extended; in fact, in bad cases it is advisable to leave them slightly flexed for three or four days and then to gradually straighten them. This is easily accomplished by using a malleable metal splint or by having attached to the splint elastic bands which are passed round the fingers, sufficient padding being placed between the bands and the fingers and on the splint to prevent injurious pressure effects. At first the splint must be worn night and day; after the punctures have healed it should be removed daily to permit of active and passive movements being carried out. It should be worn for at least six months at night, and very often for a longer time; the proper time when it can be discarded altogether must be determined specially for each case, and this will vary according to the severity of the deformity. The patient should be warned of the liability of the condition to relapse, and told to hyper-extend the affected fingers many times daily after the splint has been discarded in the daytime, as it is only by persistent and long-continued careful after-treatment that a cure can be effected by this as by all other methods of operating for the relief of this deformity.

The open methods of operating are three: (1) multiple division of the fascia through a longitudinal incision, (2) excision of the contracted fascia, (3) division of the skin and fascia through a V-shaped incision.

Multiple division of the fascia through a longitudinal incision. This operation is practically Adams's, done through an open incision with strict antiseptic precautions. An Esmarch's tourniquet is applied to the arm; the hand is placed in the supine position with the fingers outstretched as much as possible. 'A longitudinal incision is made through the skin and into the contracted fascia. If the finger is much contracted, the incision can only be completed by degrees, as the division of the bands gradually permits the fingers to be extended. The fascia is divided transversely and completely in many places, both

in the palm and in the finger, until all resistance from the fascia has been removed, and nothing but 'nutritive shortening' of the structures surrounding the finger-joints remains. This should be left to be overcome by after-treatment. Here and there the skin itself may have to be freed by a touch of the knife. The skin incision is closed

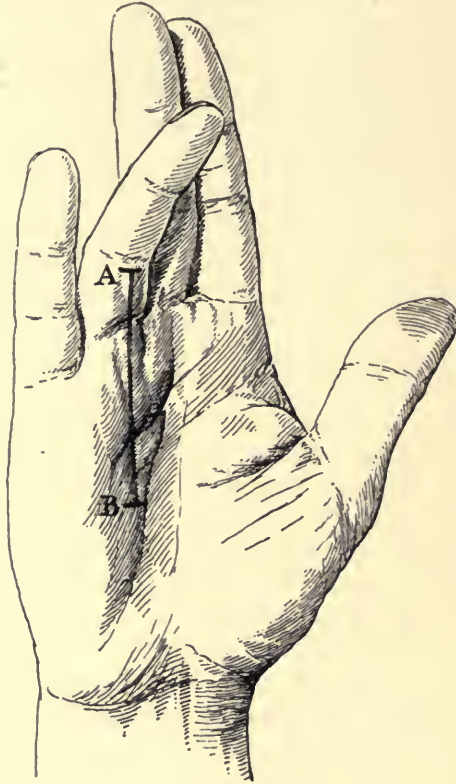


FIG. 335. OPERATION FOR DUPUYTREN'S CONTRACTION BY EXCISION OF THE CONTRACTED FASCIA. A B is the line of incision for exposing the fascia; the short transverse lines at each end of it enable the skin to be reflected in the form of two flaps.

by silkworm-gut sutures, inserted as near to the edge of the wound as possible. The fingers should at this stage not be straightened any more than is possible without using very much pressure or causing painful tension. If the above directions are strictly followed, merely a linear cicatrix will remain.'¹

Excision of the contracted fascia (Fig. 335). A longitudinal incision,

¹ Keetley, *Orthopædic Surgery*.

AB, is made over the contracted fascia from its upper to its lower end. Small transverse incisions are made at each end of the longitudinal cut and the skin is turned back on each side, exposing the fascia which is then dissected out and removed, together with any bands going to the fingers. This operation is by no means an easy one, especially in

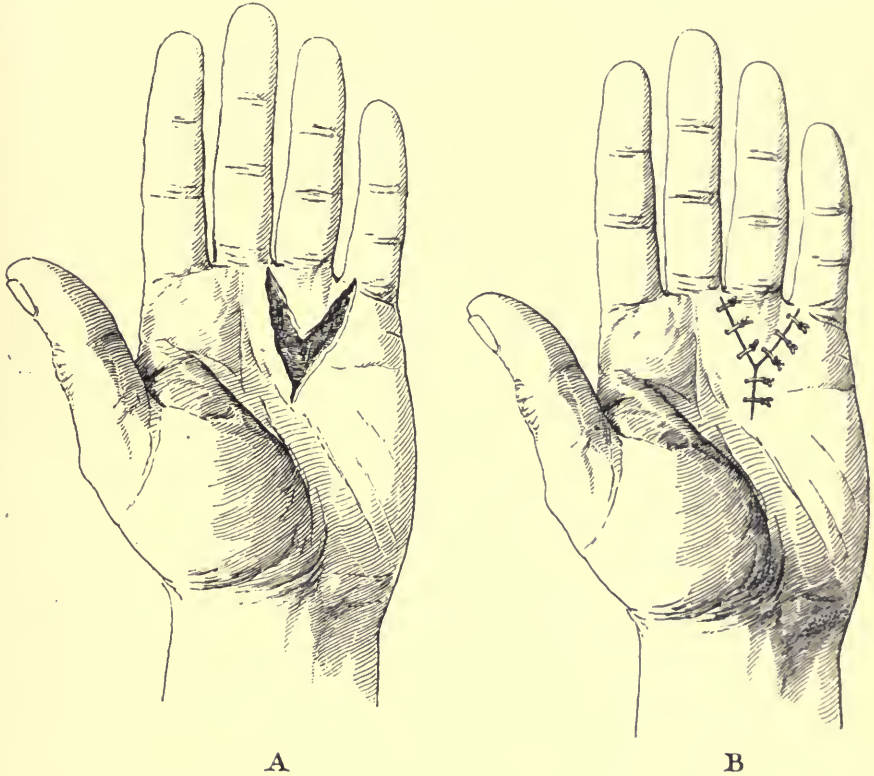


FIG. 336. OPERATION FOR DUPUYTREN'S CONTRACTION BY A V-SHAPED INCISION. In A the raw area left after the skin and fascia have been divided and the finger has been straightened is shown. In B the method of uniting the edges of the raw area is indicated. Any unclosed part should be covered with a skin-graft.

bad cases. In the first place, if the finger is much flexed it is not easy to separate the skin or to make the longitudinal incision; the separation of the skin is liable to be followed by sloughing, and if a portion is excised, a raw area is left, which has to close by granulation or be skin-grafted. Re-contraction is therefore very liable to follow. Secondly, it is difficult to bring the edges of the incision into apposition; and thirdly, the after-results are not any better than those obtained

by other methods. It is not, therefore, an operation which can be recommended.

Division of the skin and fascia by a V-shaped incision (Fig. 336). In this method the fascia is not removed, but is divided together with the skin by means of a V-shaped incision, the apex of the V being opposite the mid-line of the affected finger about the middle of the palm, and the base corresponding to its root. The fascia, without any separation from the skin, is completely divided by carrying the incisions through it. The finger having been straightened, a triangular wound is left in the palm. The edges of the wound are then sutured together, so that a Y-shaped scar results; if it cannot be completely closed the raw area is skin-grafted.

The after-treatment of all these operations requires to be carried out in the same thorough and methodical manner as after subcutaneous division of the fascia.

The choice of the method will depend on the severity of the deformity. Speaking generally, it will be found that subcutaneous division of the fascia, or division through a longitudinal incision, will give the best results, and should always be employed before resorting to other methods.

OPERATIONS FOR CICATRICIAL DEFORMITIES AFTER INJURIES

The deformities which follow cicatrization are so various that it is impossible to describe any operation which will meet an individual case. Thus one patient will have an arm closely bound to the side of the chest; another will have a large mass of scar tissue preventing movements in a joint; and a third will have a cicatrix binding the chin down to the neck.

The general principles to be followed in these cases are:—

(1) Division of the scar tissue till healthy tissues are reached. Tight bands and large masses of cicatricial tissues will need to be excised, but care must be exercised not to remove unnecessary portions; at the same time, the whole area and its edges must be completely refreshed. As a result there will probably be a good deal of bleeding, which must be arrested by pressure before proceeding further with the operation.

(2) The means by which the deformity may be prevented from recurring: these are (*a*) skin-grafting, (*b*) the use of flaps. (*a*) As regards skin-grafting, Thiersch's method does not permanently prevent the recurrence of the contraction, especially when the area to be grafted is large and it is essential in these cases to have a thick sound covering of skin. Moreover, when a very large area requires to be covered, it

may be almost impossible to get enough skin. Wolfe's method is not so suitable for these cases and is also inferior to the use of flaps. Therefore skin-grafting should be used for small areas and when other methods are not available, or in conjunction with these methods.

(b) Flaps are the best means of treating these cases; these may be obtained either from adjacent parts, or from a distal part of the body,

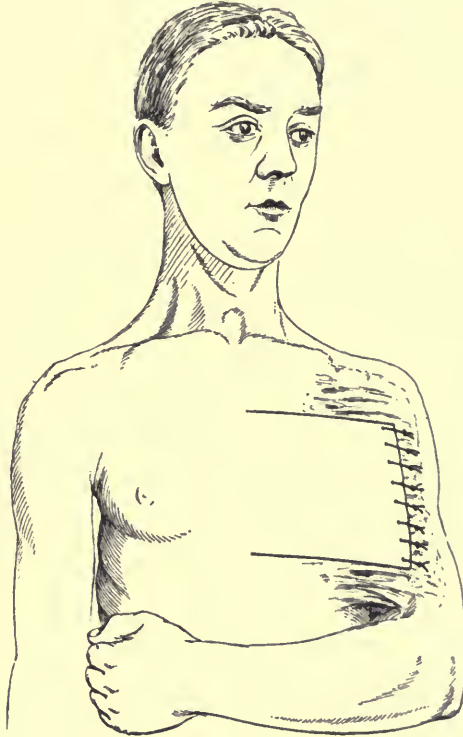


FIG. 337. TO SHOW HOW A FLAP MAY BE USED TO CORRECT CICATRICAL CONTRACTION. The arm is bound to the side of the chest by adhesions; a large flap has been raised from the thorax and stitched at its distal end to a prepared raw area on the arm. When union has taken place, the pedicle of the flap is divided, and the arm is freed by dividing the cicatricial bands. A raw area is thus made on the inner side of the arm, to which the flap is sutured.

such as a limb. The flap may be raised and immediately transplanted to its new position, or it may be glided into position or may 'bridge over' an intervening portion of the skin. For example, if the arm is firmly bound down to the chest (following a severe burn or similar injury) a flap may be raised from the chest (Fig. 337) or back of the shoulder. The distal end of the flap is sutured to the raw area on the scar tissue

prepared to receive it. When union has taken place, the pedicle is divided and at the same time the remaining adhesions uniting the arm to the side of the thorax are cut through, thus freeing the limb and leaving a large raw area on the inner side of the arm. The proximal portion of the flap is then applied to this area and sutured to its edges. The flap must be made broad in proportion to its length and does not always correspond exactly in size and shape to the raw area, but care should be taken to make their relative sizes equal as far as possible, and especially to obtain primary union between the raw area and the distal end of the flap, because this portion is the most likely to slough. The pedicle may be usually divided in ten days or a fortnight, the exact time depending on the amount of union between the flap and raw area and the condition of the flap.

Instead of transplanting the flap at once, it may be raised, left attached by both ends, and allowed to granulate. Such a flap may be taken from an adjacent portion of the body; thus, in the case of a large contracted area on the inner side of the arm or forearm, it may be obtained from the outer surface of the limb. The incisions must be made parallel to the line of the blood-vessels and so arranged as to allow the flap to be readily twisted into its new position. The flap must be thick, and the raw area left by its elevation should be closed as much as possible in order to diminish the amount of contraction which follows the healing of the wound. A piece of sterilized gutta-percha or oiled silk is placed beneath it, especial care being taken to prevent union occurring in the angles between the pedicles and the raw surface. In about two or three weeks' time, the flap is transplanted by division of one of the pedicles and sutured to the edges and surface of the raw area prepared for it. When union has taken place, the other pedicle is severed and the remaining portion is then sutured in position. At first the flap is very bulky and unsightly, but in the course of time it shrinks and flattens out.

Another method of using a double-pedicled flap is shown in Figs. 338 and 339. This method is particularly useful in the case of the forearm and hand, and especially for the palmar surface of the latter, where elasticity and resistance are required. Instead of taking the flap from the buttock or thigh, it may be taken from the abdomen. The flap has two pedicles and should not be cut too thick; it must contain a part of the subcutaneous tissue and must be long enough to be free from tension. The edges of the raw area are dissected up, to make their union with those of the flap more easy of accomplishment. The pedicles of the flap are divided at different times, the first in ten to fourteen days, and then the other after a further lapse of some days,

viz. about the third week. If the fingers have to be covered they should be first separated as widely as possible and the flap marked out with them in this position, so as to ensure a sufficient amount of covering. It may be possible to make separate pockets for each finger, the attached portions of the flap between the fingers being subsequently divided. This also should be done in stages, one finger at a time, and each portion sutured to its proper finger. When this method is used, the nails must be cut quite short and thoroughly cleaned, every care being taken to minimize septic influences. A large raw area will be left on the buttock

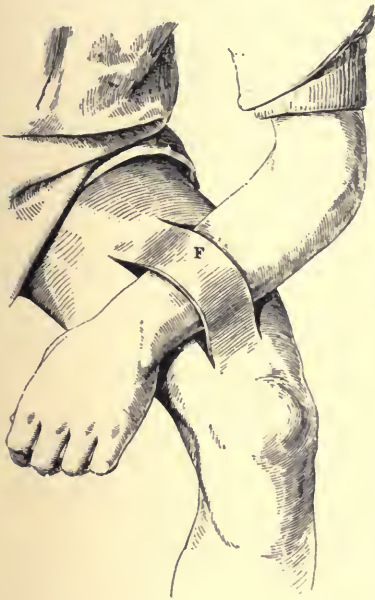

FIG. 338. TO ILLUSTRATE THE USE OF A FLAP, F, WITH TWO PEDICLES.

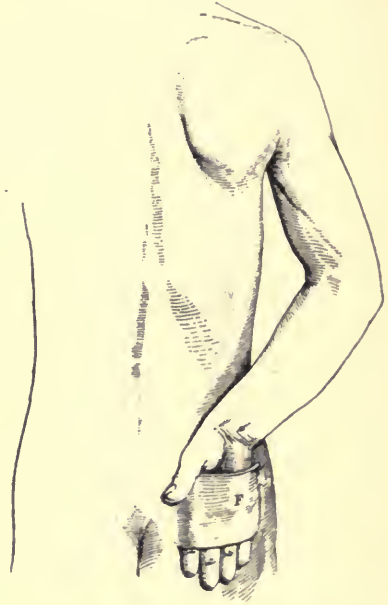


FIG. 339. TO SHOW HOW THE PALM OF THE HAND MAY BE COVERED WITH A FLAP, F, TAKEN FROM THE BUTTOCK.

or from wherever the flap is taken; this is closed as far as possible by undercutting the adjacent skin and stitching together apposed surfaces, Thiersch's grafts being used to cover any remaining uncovered parts.

(3) During the various stages the parts must be kept absolutely at rest and it is therefore often necessary to employ some form of fixation apparatus. Plaster of Paris is one of the most useful and easily applied; a window may be left so that the wound can be dressed without disturbing the flap, or the whole case may be put on in such a way as to be easily removable.

(4) Many operations will probably be required to obtain a good result, and no attempt should be made, except in the least serious cases, to effect a complete cure by one operation.

Here it may be helpful to give some indications as to the positions from which these flaps may be obtained.

1. For the upper arm and axilla, the flap may be taken from the chest (Fig. 337).

2. For the forearm and dorsum of the hand, from the abdomen (Fig. 340) or thigh (Fig. 338). For the dorsum and palm of the hand, and the fingers, the buttock may be used to supply the flap (see Fig. 339).

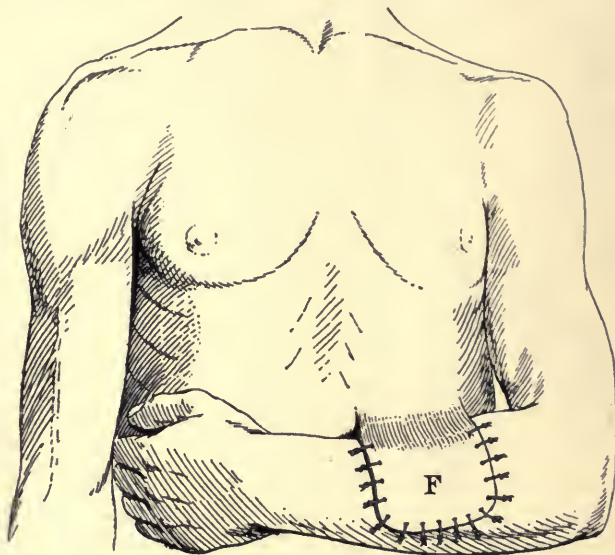


FIG. 340. TO SHOW HOW A FLAP, F, MAY BE TAKEN FROM THE SKIN OF THE ABDOMEN AND APPLIED TO THE FOREARM.

3. For the lower limbs, the opposite limb may be used (Fig. 341).

4. For the neck, the back of the shoulder or upper part of the chest may be employed to supply the flap.

OPERATIONS FOR HAMMER-TOE

This deformity is characterized by dorsal flexion of the first phalanx at the metatarso-phalangeal joint and plantar flexion of the second phalanx on the first. The terminal phalanx may be in its normal position or in the same straight line as the second phalanx. The condition is primarily due to a shortening of the lateral ligaments of the first inter-phalangeal joints, and complicated in bad cases by contraction of the glenoid liga-

ment, of the flexor tendons, and of the skin on the plantar aspect of the toe. Hallux valgus frequently accompanies this deformity, and in cases requiring operative treatment there is usually a corn on the dorsal aspect of the first inter-phalangeal joint or at the extremity of the toe. The patient usually seeks advice on account of this painful corn or because he wishes to enter one of the public services. The pressure of the boot on the displaced toe interfering with walking is another indication for operation.

The operative measures available are : (1) division of the contracted

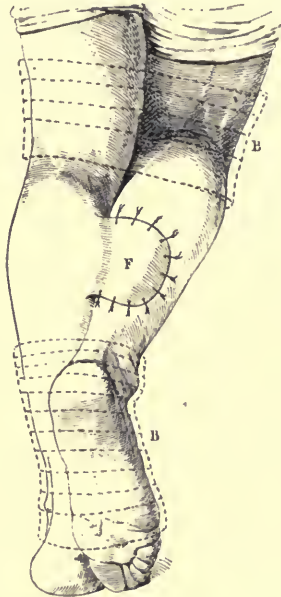


FIG. 341. TO SHOW HOW A FLAP, F, TAKEN FROM ONE LEG, MAY BE APPLIED TO THE OTHER. B is the appliance (a plaster of Paris casing is very convenient) for fixing the limbs immovably together.

structures around the joint ; (2) excision of the head of the first phalanx ; (3) amputation of the toe. The first method is suitable only for slight cases ; in the majority of cases the choice lies between excision and amputation and generally excision is to be preferred. Amputation is certainly an effective means of relieving the deformity, but it is an unnecessarily severe remedy, which increases the amount of hallux valgus, if this is present, and favours its occurrence in every case. Moreover, the loss of the toe may prevent the patient from entering one of the public services. If a marked degree of hallux valgus is present, this should be rectified at the same time that the hammer-toe is operated on.

Division of the contracted structures around the joint. The foot having been thoroughly cleansed and sterilized, a small sharp-pointed tenotome is entered on one side of the toe, opposite the first inter-phalangeal joint, at the junction of the dorsal and lateral aspects. The lateral ligament is made tense and divided, and the knife is carried across the plantar aspect of the joint, dividing the glenoid ligament, the long flexor tendon, and opposite lateral ligament. If the flexor tendon and plantar ligament are not contracted, the knife may be withdrawn and a fresh puncture made on the other side of the joint in order to divide the plantar ligament of that side. The toe is then straightened, and in doing so the skin may be lacerated, or may require to be divided if it is tense. An antiseptic dressing is applied to the toe, and a well-padded splint is placed on its plantar surface. The splint should be made of thin metal and be T-shaped; it should extend far back on the sole, the transverse limb being fixed to the foot by an elastic band passing round the instep, and the longitudinal limb fastened to the toe by another band. Instead of these elastic bands, it is sometimes more convenient to use a bandage.

Excision of the head of the phalanx. A longitudinal incision is made on one side of the extensor tendon down to the bone. The soft structures are separated from the bones and the tendon displaced to one side. The ligaments of the joint being divided, the head of the phalanx is made to project out of the wound and is then divided above the articular cartilage by means of sharp bone forceps. Enough bone must be removed to allow the toe to be easily and completely straightened. The corn which will usually be present must be excised before the wound is closed by two or three sutures. An antiseptic dressing is applied, and the toe is placed on a well-padded splint with an extra amount of padding beneath the terminal phalanx, to keep it in a straight line. After the wound is healed, the toe should be kept on a splint, or put in a silicate bandage for three or four weeks.

Amputation. The method of amputating the toe is described on p. 158.

INDEX

	PAGE		PAGE
ABDOMINAL AORTA		AMPUTATIONS (<i>continued</i>)—	
ligature of the	339	of the finger, surgical anatomy of	96
ADAMS'S OPERATION		and its metacarpal	109
for Dupuytren's contraction	726	foot	158
AIR		forearm	123
bacteria in	6	by the circular method	126
germless. Supply of	7	cuff method	126
infection	6	Gordon Watson's	200
supply to operating theatres	7	of the hand and wrist	96
AMPUTATIONS		Hey's	212
General considerations:		of the hip (<i>see</i> Disarticulations)	
arrest of hæmorrhage in	93	interscapulo-thoracic	153
cases always requiring	64	Le Fort's	199
occasionally requiring	65	of the leg; Hey's	212
characters of a faulty stump	74	Lister's	214
good stump	73	Lisfranc's	166
choice of methods	84	Pirogoff's	196
closure of wound after	93	at the 'seat of election', circular	217
conical stump after	76	by equal lateral	
dangers of	68, 71	flaps	219
division of the bone in	89	Farabeuf's	221
drainage after	93	Spence's	148
factors influencing form of	72	Stokes-Gritti's	235
flap methods in	83	supra-malleolar, by a long pos-	
future of the stump after	94	terior flap	209
general principles underlying	71	by an oblique ellipti-	
how to hold the knife in	86	cal incision	206
immobilizing the limb after	94	Syme's	189
indications for	64	at the tarso-metatarsal joints	165
mortality of	95	through thigh	239
raising the flaps in	85	by antero-posterior	
retractors for	89	flaps	241
shock as influencing	69	circular	239
varieties of	63	of the thumb and its metacarpal	109
<i>v.</i> conservative treatment	72	toes	158
In special situations:		trans-condyloid; Lister's	233
of the ankle (<i>see</i> Disarticulations)		by long anterior and	
arm	139	short posterior flaps	232
by circular method	142	of the upper arm	139
Berger's interscapulo-thoracic	153	wrist by an external flap	121
of the elbow (<i>see</i> Disarticulations)		ANALGESIA	
finger, by circular racket	103	Local	
elliptical	107	adrenalin and eucaine	33
Farabeuf's	106	Barker's solution for	33
by flap methods	83	cocaine	32
oblique racket	104	duration of	35
		eucaine	33
		technique of	36

	PAGE		PAGE
ANALGESIA (continued)—		ARTERIES (continued)—	
Regional		anterior tibial. Ligature of . . .	295
for goitre	37	in upper third	297
removal of finger or toe	37	middle third	299
Spinal		lower third	301
advantages of	41	axillary. Ligature of	358
amount injected	60	of first part	360
Barker's solution for	47	third part	363
Bier's solution for	47	brachial. Ligature of	354
canula for	56	at the bend of the elbow	358
Chaput's solution for	47	in the middle of the arm	355
densities of compounds used in	47	carotid, common. Ligature of	
difficulties in	43	above the omo-hyoid	377
duration of	42	below the omo-hyoid	377
ANASTOMOSIS OF THE FACIAL		external. Ligature of	383
NERVE	452	internal. Ligature of	386
with the hypoglossal	452	dorsalis pedis. Ligature of	293
spinal accessory	454	facial. Ligature of	393
'ANATOMICAL SNUFF-BOX'		femoral. Ligature of	313
ligature of the radial artery in the	349	in Hunter's canal	316
ANEURYSM		below Poupart's	
orbital. Operation for	386	ligament	320
varicose. Operations for	278	at the apex of Scar-	
ANEURYSMAL VARIX		pa's triangle	318
operations for	278	iliac, common. Ligature of	331
ANKLE-JOINT		external. Ligature of	324
arthrodesis of	596	Astley Cooper's	326
arthrotomy of	592	extra-peritoneal	325
for Pott's fracture	594	trans-peritoneal	329
disarticulation at, by a large in-		internal. Ligature of	330
ternal flap	194	innominate. Ligature of	365
Syme's ampu-		through Δ -shaped incision	
tation	189	a median vertical	
drainage of	592	incision	368
by excision of astrag-		lingual. Ligature of	390
alus	593	occipital. Ligature of	394
excision of	597	popliteal. Ligature of	306
fractures into. Arthrotomy for	593	from back of leg	310
ANKYLOSIS		inner aspect	307
of the elbow. Operation for	570	posterior tibial. Ligature of	302
jaws. Operations for	715	behind inner ankle	305
knee. Excision for. 625, 632		in the middle third	303
shoulder. Excision for	582	lower third	304
ANTERIOR TIBIAL ARTERY		pudic, internal. Ligature of	337
ligature of	295	radial. Ligature of	344
ANTISEPTICS		in the upper third	346
chemical, use of	21	middle third	348
AORTA		lower third	348
abdominal. Ligature of	339	removal of an embolus from	261
ARM		sciatic. Ligature of	336
amputation of	139	subclavian. Ligature of	368
by antero-posterior flaps	143	of first part	
circular method	142	of right	370
ARTERIES		of third part	373
ligature of, general considera-		superior gluteal. Ligature of	334
tions.	284	temporal. Ligature of	394
		ulnar. Ligature of	350
		in upper third	353
		middle third	351

	PAGE		PAGE
ARTERIES (<i>continued</i>)—		AURICULO-TEMPORAL NERVE	
ulnar. Ligature in lower third	350	resection of	434
vertebral. Ligature of	388	AUTOPLASTIC	
suture of wounds of	262	nerve-bridging	420
ARTERIORRHAPHY	261	tendon-grafting	495
ARTERIO-VENOUS ANASTO-		Dawbarn's	495
MOSIS		AVULSION OF A LIMB	
operations for	398	amputation for	64
ARTERY COMPRESSOR, CRILE'S	263	AXILLARY ARTERY	
ARTHRECTOMY	560	ligature of the	358
ARTHRITIS, SUPPURATIVE		of the first part	360
of the ankle, drainage for	592	third part	363
elbow, drainage for	565	BACTERIA	
hip, drainage for	635	in atmosphere	6
knee, drainage for	626	exclusion of, during operations	3
shoulder, drainage for	575	scientific tests for exclusion of	4
ARTHRODESIS	559	BALLANCE AND EDMUNDS	
of the ankle	596	' stay-knot '	289
elbow	573	BANDAGES	
knee	632	sterilization of	12
shoulder	588	BARKER	
ARTHROPLASTY	557	analgesic solutions	33, 47
ARTHROTOMY		BARNARD	
of the ankle	592	method of draining knee-joint	606
elbow	565	BARTLETT	
knee, for drainage	606	splint for compound fractures	543
exploration of		BERGER	
joint	555	cheiloplasty	697
fractures	611	interscapulo-thoracic amputa-	
acute inflammations	555	tion	153
displaced semilu-		BERRY	
nar cartilage	555	rhinoplasty	686
removal of syno-		BICEPS TENDON	
vial membrane	609	division of the	482
repair of the cru-		BIER	
cial ligaments	608	analgesic solution	47
shoulder	575	BLAKE	
ASEPSIS		aneurysm of subclavian	370
definition of	3	BLOOD	
and medical education	5	infection of	4
and operating methods	25	BLOOD-CLOT	
in scrotal wounds	25	liquefaction of in wounds	24
and ward units	8	BOLTON	
ASTLEY COOPER		method of draining ankle	593
ligature of external iliac artery	326	BONE	
ASTRAGALUS		amputation for cancer of	64
excision of	597	cavities in, bevelling edges of	524
for drainage of the ankle		obliteration by skin	
injury	597	flaps or grafts	525
in talipes equinus	597	plastic operations	
talipes varus	598	upon	524
AURICLE		' stopping '	526
plastic operations on	691		

	PAGE		PAGE
BONE (<i>continued</i>)—		CIRCULATION, SYSTEMIC	
division of, in amputations	89	reversal of in a limb	280
obliteration of aseptic cavities in	527	COMPRESSION, DIGITAL	
of septic cavities in	523	in amputation	77
BRACHIAL		CONGENITAL DEFORMITIES	
artery, ligature of	354	operations for	719
plexus, exposure of in the neck	457	CONGENITAL DISLOCATION OF	
BROWN (of Leeds)		THE HIP	
cheiloplasty	696	operation for re-position of	647
BURGHARD		CONGENITAL TALIPES VARUS	
operation for congenital disloca-		excision of astragalus for	598
tion of hip	651	CONTACT INFECTION	6
microstoma	706	disinfection of hands	17
orbital aneurysm	386	patient's skin	19
BURSÆ		CONTROL OF HÆMORRHAGE	77
operations upon	505	by circular constriction of the	
CANULA		limb	78
for intra-venous infusion	406	digital compression	77
spinal analgesia	56	during disarticulation at the hip-	
CARDEN'S OPERATION		joint	246
Lister's modification of	233	by preliminary permanent liga-	
CAROTID ARTERY		ture of main vessels	78
ligature of the common	375	pressure forceps of Lynn	
external	383	Thomas	79
internal	386	special apparatus	79
CARTILAGES		temporary ligature	77
removal of displaced semilunar	603	Wyeth's pins	80
CATGUT		COSTUMES, OPERATING	15
sterilization of	14	CRANIAL NERVES	
CERVICAL NERVES		operations on	430
resection of the posterior pri-		CRILE	
mary divisions of the first		arrest of bleeding in removal	
three	455	of the Gasserian ganglion	443
CHAPUT		artery compressor	263
analgesic solution	47	CRUCIAL LIGAMENTS	
CHEEK		suture of the	608
plastic operations on	704	CRURAL NERVE	
closure of a large defect in	708	exposure of the anterior	466
small defect in	713	CUFF METHOD	
CHEILOPLASTY		of amputation of forearm	126
for ectropion	694	CULTURE MEDIA	
restoration of the lips	697	diagnosis by	3
CHEYNE, SIR WATSON		for testing wounds	5, 28
rhinoplastic operation	679	CUNNING	
CHOPART'S AMPUTATION	175	plastic operation upon cheek	708
CIRCULAR AMPUTATION		CUSHING	
at the elbow-joint	131	removal of Gasserian ganglion	436
of the forearm	126	DAWBARN	
at the 'seat of election'	217	method of tendon-lengthening	495
through the thigh	239	DEFORMITIES	
of the upper arm	142	amputations for	67
wrist	116	congenital and acquired. Opera-	
CIRCULAR RACKET		tions for	719
amputation of fingers	103		

PAGE		PAGE
	DEFORMITIES (<i>continued</i>)—	
	of the fingers after injuries.	
	Operations for	730
	DIDOT	
	operation for webbed fingers	723
	DIGITAL COMPRESSION	
	in amputation	77
	DIGITS, SUPERNUMERARY	
	operation for	724
	DISARTICULATION	
	at the ankle by a large internal	
	flap	194
	the racket method	196
	Syme's	189
	Chopart's	175
	at the elbow	131
	by the circular method	131
	elliptical method	134
	at the hip	245
	by the anterior racket	
	method	253
	control of hæmorrhage	
	during	246
	Furneaux Jordan's	249
	at the inter-phalangeal joint of	
	the toe	158
	at the knee, oblique elliptical	229
	Stephen Smith's	225
	metacarpo-phalangeal	101
	metatarso-phalangeal	159
	by a large internal	
	flap	160
	by a large square	
	internal flap	162
	by a racket in-	
	cision	163
	at the shoulder	146
	by the racket	
	method	150
	Spence's ampu-	
	tation	148
	subastragaloid	178
	Farabeuf's	179
	Nélaton's	187
	by a racket in-	
	cision	188
	Roux's	188
	tarso-metatarsal	165
	at the terminal finger-joint	97
	of the four outer toes at the	
	metatarso-phalangeal joints	164
	at the wrist	116
	by an elliptical in-	
	cision	117
	by an external flap	121
	by a long palmar	
	flap	118
	DISINFECTION	
	of the anal canal and rectum	20
	external genitals	20
	face and neck	19
	septic orifices	20
	septic sores or ulcers	20
	the skin	19
	DISLOCATIONS	
	OF ELBOW	568
	unreduced, of the elbow.	
	Operations for	569
	unreduced, of the radius.	
	Operation for	570
	OF THE HIP, congenital. Opera-	
	tion for re-position of	
	recent traumatic. Opera-	
	tions for	645
	traumatic of long stand-	
	ing. Operations for	646
	OF SHOULDER. Operations for	577
	unreduced. Excision	
	for	578
	operations for recent	578
	operation when fracture	
	complicates	577
	unreduced. Operation	
	for	579
	DORSALIS PEDIS	
	ligature of the	293
	DOWD	
	tendon-lengthening	494
	DRAINAGE	
	in amputations	93
	of the ankle	592
	by excision of the	
	astragalus	593
	elbow	565
	hip-joint	635
	knee	606
	in acute infections	607
	mild infections	607
	septic wounds	28
	the shoulder	575
	tubes	25
	of wounds in general	24
	DIEFFENBACH'S OPERATION.	700
	DRESSINGS	
	sterilization of	12
	DOYEN	
	removal of Gasserian ganglion	450
	DUPUYTREN'S CONTRACTION	
	operation for	726
	DUPUYTREN'S FRACTURE	
	arthrotomy of the ankle for	593
	EDMUNDS (AND BALLANCE)	
	'stay-knot'	289

	PAGE		PAGE
ELBOW-JOINT		EXCISION (<i>continued</i>)—	
amputation at the	123	OF THE SHOULDER	581
ankylosis of the. Operation for	570	for ankylosis	582
arthrodesis of the	573	compound frac-	
arthrotomy and drainage of the	565	tures	581
disarticulation at the	131	by Kocher's pos-	
by circular incision	132	terior incision	586
elliptical incision	134	for tuberculous dis-	
dislocations of the	568	ease	581
drainage in acute suppuration .	565	unreduced dis-	
excision of the	569	locations	582
fractures into. Operations for	565	TENDON SHEATHS	503
operation for unreduced disloca-		THE WRIST	561
tion of the radius	570	FACE	
operation for fracture of the		disinfection of the	19
head of the radius	570	FACIAL	
unreduced dislocations of. Oper-		artery. Ligature of	393
ation for	569	nerve. Anastomosis of with	
ELECTRICAL FITTINGS FOR		hypoglossal	452
OPERATING THEATRES	10	with spinal ac-	
ELLIPTICAL GAPS		cessory	454
closure of	663	FARABEUF	
ELLIPTICAL INCISION		amputation of a finger	106
amputation by	82	'at seat of election'.	221
EMBOLUS		subastragaloid disarticulation .	179
removal of	261	FEMORAL ARTERY	
ENDO-ANEURYSMORRHAPHY	266	ligature of	313
obliteration of the sac	274	below Poupart's liga-	
the obliterative suture	271	ment	320
reconstructive suture	275	in Hunter's canal	316
restorative suture	273	in Scarpa's triangle	318
ESMARCH		FEMUR	
operation on lower jaw	716	exposure of the neck of the	634
EUCAINE AND ADRENALIN		operations for fractures of the	
SOLUTION		neck of the	637
practical points in the use of . .	34	osteotomy of the neck of the . .	636
strength of	33	sub-trochanteric osteotomy of	
EVE		the	516
drainage of the knee-joint	606	FIFTH NERVE	
EXCISION		exposure of the divisions of the	430
OF THE ANKLE.	597	FINGERS	
ASTRAGALUS	597	amputations of the	96
for injury	597	surgical anatomy	96
in talipes equinus	597	with their metacarpals	114
varus	598	operations for acquired contrac-	
ELBOW	569	tions of	725
HIP	641	operations for Dupuytren's con-	
by an external incision	642	traction of	726
KNEE	560, 625	operations on supernumerary	
for ankylosis	625, 632	digits	724
injury	625, 627	regional analgesia for removal of	
suppuration	626	webbed. Operation for	719
tuberculous dis-		FISCHER (AND MÜNZER)	
ease	625	nerve regeneration	418
OS CALCIS	601	FLAPS	
SCAPULA	589	methods of fashioning	82
		suturing in plastic	
		surgery	657

	PAGE		PAGE
FLEXOR LONGUS HALLUCIS		GASSERIAN GANGLION	
division of the tendon of	479	removal of the	435
FOOT		Doyen's method	450
amputations of the	158	the Hartley-Krause	
FORAMITTI		method	447
nerve-bridging	422	the modified Cushing	
FOREARM		method	437
amputation of by the circular		GENITALS, EXTERNAL	
method	126	disinfection of	20
by equal flaps	129	GERSUNY	
FRACTURES		paraffin injections	681
amputation for compound	65	GLOVES	
severe crush	64	sterilization of	16
Dupuytren's. Arthrotomy of		GLUTEAL ARTERY	
the ankle for	593	superior. Ligature of the	334
into the ankle. Arthrotomy for	593	GOÛTRE	
into the elbow-joint. Opera-		regional analgesia in	37
tions for	565	GRAFTING	
involving the shoulder-joint	576	skin	664, 669
of the femur. Arthrotomy of		tendon	497
the knee for	611	GUSSENBAUER	
of the head of the radius.		plastic operation on cheek	714
Operation for	570	HÆMORRHAGE	
of the humerus, compound.		arrest of	93
Excision of the shoulder for	581	control of, during disarticulation	
of long standing. Operations on	547	at the hip-joint	246
of the neck of the femur.		in amputations, control of	77
Operations for	637	HAMMER-TOE	
of the olecranon. Operation for	567	operations for	734
of the patella. Operations for	612	HAMSTRING TENDONS	
Barker's method	618	division of	482
Lord Lister's		HAND	
method	613	amputations of the wrist and	96
of the shaft of the femur.		HANDLEY, SAMPSON	
Operations for	534	lymphangioplasty	408
operations for mal-union of	550	HANDS	
operations upon	535	disinfection of	17
methods of fixation	538	HARTLEY	
fixation in	544	removal of Gasserian ganglion	436
the time to operate	536	HETEROPLASTIC NERVE-	
recent simple multiple. Opera-		BRIDGING	420
tions for	533, 535	HETEROPLASTIC TENDON-	
recent simple combined with		LENGTHENING	495
dislocation. Operations for	535	HEY	
ununited. Operations for	547	amputation of leg	212
FURNEAUX JORDAN		HIBBS	
disarticulation at the hip-		method of tendon-lengthening	494
joint	249	HIP-JOINT	
GANGLION, GASSERIAN		congenital dislocation of. Opera-	
operations on	430	tion for re-position of	647
GANGRENE		disarticulation at the	245
amputation for	65	control of hæmorrhage during	246
incipient. Operations upon		Furneaux Jordan's operation	249
arteries for	262		
GARMENTS			
sterilization of	12		

	PAGE		PAGE
HIP-JOINT (<i>continued</i>)—		JOINT (<i>continued</i>)—	
drainage of	635	ELBOW. Disarticulation by the	
excision of	641	circular method	132
by external incision	642	by an elliptical	
HORSLEY, SIR VICTOR		incision	134
aseptic wax	437	operations upon the	565
removal of the Gasserian ganglion	436	HIP. Disarticulation at the	245
HUNTINGTON		Furneau Jordan's	
method of bone grafting	530	operation	249
HYPOGLOSSAL NERVE		control of hæmor-	
anastomosis with facial	452	rhage during	246
exposure of the	453	operations upon the	634
ILIAC ARTERY		KNEE. Disarticulation at, by	
common, ligature of	331	an oblique elliptical incision	
external, ligature of	324	Stephen Smith's	
internal, ligature of	330	method	225
INFECTED WOUNDS		operations upon the	603
treatment of	28	INTER-PHALANGEAL JOINTS.	
INFECTION		Disarticulation at the	97, 158
aerial	6	MEDIO-TARSAL JOINT. Chopart's	
contact	6	disarticulation at the	175
disinfection of the hands		METACARPO-PHALANGEAL JOINTS.	
disinfection of the		Disarticulation at the	101
patient's skin	19	METATARSAL JOINTS. Disarticu-	
of suture needles	5	lation of four outer toes at	
the blood	4	the	164
wounds	4	METATARSO-PHALANGEAL JOINTS.	
treated by vaccines	3	Disarticulation at the	159
INFILTRATION ANALGESIA	31	by a large square	
INFUSION, INTRA-VENOUS	405	internal flap	162
INNOMINATE ARTERY		by a large internal	
ligature of the	365	flap	160
INSTRUMENTS		by a racket incision	163
sterilization of	12, 19	SHOULDER. Disarticulation at	
INTER-PHALANGEAL DISAR-		the	146
TICULATIONS		by the modified racket	
of a finger	97	method	150
of toes	158	Spence's amputation	148
INTERSCAPULO-THORACIC		operation upon the	575
AMPUTATION	153	TARSO-METATARSAL JOINTS.	
INTRA-VENOUS INFUSION	405	Disarticulation through the	165
ISOTONIC FLUIDS		WRIST. Disarticulation by an	
injection of	33	external flap	121
ISRAEL		operations upon the	561
plastic operation on cheek	711	JORDAN, FURNEAUX	
JAWS		disarticulation at the hip-joint	249
operations for ankylosis of	715	KEEGAN	
JOINT		rhinoplasty	683
ANKLE. Disarticulation at the		KEETLEY	
by a large internal		operation for Dupuytren's con-	
flap	194	traction	726
Syme's amputation	189	plastic operation on the cheek	715
operations upon the	592	unreduced shoulder dislocations	578
ELBOW. Disarticulation at the	131	KILVINGTON	
		nerve suture	418, 424
		KNEE-JOINT	
		arthrodesis of	632
		arthrotomy of	611

	PAGE
KNEE-JOINT (<i>continued</i>)—	
disarticulation at, by an oblique elliptical incision	229
by Stephen Smith's method	225
drainage of, in acute infections	607
mild infections	607
excision of	625
for ankylosis	625, 632
injury	625
suppuration	626
tuberculous disease	625
repair of the crucial ligaments	608
KOCHER	
incision for the infra-orbital nerve	432
posterior excision of the shoulder	586
excision of hip-joint	642
KRAUSE	
removal of the Gasserian ganglion	436
LANGENBECK	
rhinoplasty	686
LE FORT	
trans-calcaneal amputation	199
LEG	
amputations through the	205, 212
LENGTHENING OF TENDONS.	493
LEXER	
joint-grafting	558
LIGAMENTS	
crucial. Repair of the	608
LIGATURE	
of the abdominal aorta	339
anterior tibial	295
in the upper third	297
lower third	301
middle third	299
axillary	358
brachial	354
at the bend of the elbow	358
in the middle of the arm	355
common carotid	375
iliac	331
dorsalis pedis	294
exposure of an artery	285
of the external carotid	383
iliac	324
Astley Cooper's method	326
extra-peritoneal method	325
trans-peritoneal method	329
facial	393
femoral	313
at the apex of Scarpa's triangle	317

	PAGE
LIGATURE (<i>continued</i>)—	
of the femoral below Poupart's ligament	320
in Hunter's canal	316
first part of the right subclavian	370
innominate	365
through a median incision	368
Δ-shaped incision	366
internal carotid	386
iliac	330
pubic	337
lingual	390
at its origin	390
beneath the hyoglossus	390
occipital	394
popliteal	306
from the back of the leg	310
inner aspect of the thigh	307
posterior tibial behind the inner ankle	305
in the lower third	304
middle third	304
radial artery	344
in the 'anatomical snuff-box'	349
in the lower third	348
middle third	348
upper third	346
sciatic	336
subclavian	368
superior gluteal	334
temporal	394
ulnar	350
in the lower third	350
middle	351
upper third	353
vertebral	388
preliminary, to control hæmorrhage	78
temporary, to control hæmorrhage	77
LIGHTING OF OPERATING THEATRES	10
LILLIENTHAL	
mortality of ligature of the first part of the subclavian	371
LINGUAL	
artery. Ligature of the	390
nerve. Resection of the	434
LIPS	
cheiloplasty for ectropion	694
for the restoration of the plastic operations on, for sloughing	697
ing	700

	PAGE		PAGE
LIQUEFACTION OF BLOOD-CLOT	24	MURPHY, J. B.	
LISFRANC		method of arthroplasty	558
amputation of the foot	166	MUSCLE-LENGTHENING	472
LISTER, LORD		MUSCLE SUTURE	469
amputation of leg	214	MUSCULO-SPIRAL NERVE	
thigh	233	exposure of the	461
excision of the wrist	561	NECK OF THE FEMUR	
operations for fractured patella	613, 622	exposure of the	634
LOCAL ANALGESIA		operations for fractures of the	637
adrenalin and eucaïne	33	osteotomy of the	636
Barker's solution for	33	NEEDLES	
cocaine	32	infection of	5
duration of	35	for spinal analgesia	55
eucaïne	33	NÉLATON	
technique of	36	subastragaloid disarticulation	187
LYMPHANGIOPLASTY	408	NERVES	
LYMPHATICS		anterior crural. Exposure of the	466
operations upon the	408	auriculo-temporal. Resection of the	434
LYNN THOMAS		brachial plexus. Exposure of in the neck	457
pressure forceps	79	bridging	418
MACCORMAC, SIR W.		autoplastic	420
Italian method of rhinoplasty	679	heteroplastic	420
MACEWEN, SIR W.		cervical. Resection of posterior primary divisions of the first three	455
supra-condyloid osteotomy	511	cranial. Operations on the	430
MAHU		Cushing's method for removal of the Gasserian ganglion	437
paraffin syringe	682	Doyen's method for removal of the Gasserian ganglion	450
MATAS		external popliteal. Exposure of the	466
endo-aneurysmorrhaphy	266	facial. Anastomosis of the	452
MECKEL'S GANGLION		grafting	425
removal of	432	great sciatic. Exposure of the Hartley-Krause method for removal of the Gasserian ganglion	464
MEDIAN NERVE		hypoglossal. Exposure of the	447
exposure of the	459	inferior dental. Resection of the maxillary. Resection of the	433
MEDICAL EDUCATION AND ASEPSIS	5	internal popliteal. Exposure of the	466
MEDIO-TARSAL DISARTICULATION		lingual. Resection of the	434
Chopart's	175	median. Exposure of the	459
MERZBACHER		musculo-spiral. Exposure of the plastic operations upon	413
nerve transplantation	419	removal of the Gasserian ganglion	435
METACARPO - PHALANGEAL DISARTICULATIONS	101	spinal accessory. Exposure of the	454
METATARSO - PHALANGEAL DISARTICULATIONS	159	superior maxillary. Resection of the	431
by a large internal flap	160		
large square internal flap	162		
racket incision	163		
of four outer toes	164		
MICROSTOMA			
plastic operations for	702		
MORTALITY IN AMPUTATIONS	95		
MÜNZER AND FISCHER			
nerve regeneration	418		

	PAGE		PAGE
NERVES (<i>continued</i>)—		ORBITAL ANEURYSM	
supra-orbital. Exposure of the	430	operation for	386
suture, primary	413	OS CALCIS	
secondary	416	excision of	601
transplantation methods	423	OSTEOTOMY	509
ulnar. Exposure of	460	of the femur, sub-trochanteric	516
OCCIPITAL ARTERY		neck of the femur	636
ligature of the	394	cuneiform	636
OLECRANON		simple	636
operation for fracture of	567	tibia	513
OPERATING		open	510
costumes	15	Macewen's supra-condyloid	511
tables	10	subcutaneous	509
theatres	7	PACK	
cubic capacity of	8	aneurysm of the thyroid axis	371
electrical fittings of	10	PALATE	
equipment of	9	plastic operations on the, in	
lighting of	10	syphilis	717
supply of air to	7	PARAFFIN	
OPERATIONS		injections in rhinoplasty	681
for acute infective osteomyelitis	517	syringe, Mahu's	682
aneurysmal varix	278	PATELLA	
upon arteries	259	operations for recent fracture of	
bursæ	505	the	611
on the cheek, plastic	715	operations on fractures of long	
for dislocations of shoulder	577	standing	621
hip	645	PERONEI TENDONS	
exclusion of bacteria during	3	division of the	481
Farabeuf's, subastragaloid	179	PHALANGES	
upon fractures	535	amputation through the	101
for fractures of elbow	565	PINS	
of the neck of the femur	637	Wyeth's	80
olecranon	567	PIROGOFF	
patella	611	trans-calcaneal amputation	196
Furneaux Jordan's	249	PLASTIC OPERATIONS	
for hammer-toe	734	on the auricle	691
Le Fort's	199	upon bone cavities	524
Lisfranc's	166	on the cheek	704
Lister's	214	closure of a large defect	708
upon the lymphatics	408	small defect	713
Matas's endo-aneurysmorrhaphy	266	for defects in mucous	
Nélaton's subastragaloid	187	membrane	715
upon the nerves of the extremi-	459	by flaps from the arm	715
for the obliteration of aseptic		a flap from the fore-	
cavities in bone	257	head	712
of septic cavities		on the lips after sloughing	700
in bone	523	for microstoma	702
organization of	26	upon nerves	413, 418
for re-position of congenital dis-		for syphilitic affections of the	
location of the hip	647	palate	717
rhinoplastic, complete	675	upon veins	397
partial	679	PLASTIC SURGERY	
Roux's subastragaloid	187	closure of elliptical gaps	663
for the sequelæ of osteomyelitis	517	quadrilateral gaps	662
upon tendons	473	triangular gaps	662
for ununited fractures	548	flap methods	657
varicose aneurysm	278	general principles	655
upon varicose veins	399		

	PAGE		PAGE
PLASTIC SURGERY (<i>continued</i>)—		RESECTION	
gliding flaps	658	of the auriculo-temporal nerve	434
granulating flaps	658	inferior dental nerve	433
history of	655	maxillary nerve	433
methods of suturing flaps	659	lingual nerve	434
reversed flaps	658	posterior cervical nerves	455
skin-grafting	655, 664	superior maxillary nerve	431
dressing and after-treatment	673	RETRACTORS	89
method of grafting	669	REVERDIN	
preparation of area from which grafts are to be taken	669	method of skin-grafting	672
preparation of the area to be grafted	667	REVERSAL OF THE SYSTEMIC CIRCULATION IN A LIMB	280
Reverdin's method	672	RHINOPLASTIC OPERATIONS	
Thiersch's method	670	complete	675
Wolfe's method	673	for formation of a columella	690
superimposed flaps	658	general principles	675
transplanted flaps	658	for restoration of the soft parts	683
PLEXUS		Keegan's method	683
brachial. Exposure of	457	Langenbeck's	686
posterior cervical. Resection of	455	partial	676
POPLITEAL		for saddle-back nose	679
artery. Ligature of the	306	injection of paraffin	681
from the back of the leg	310	Sir Watson Cheyne's method	679
inner aspect of the thigh	307	the Indian method	676
nerves. Exposure of the	466	Italian method	679
POSTERIOR TIBIAL ARTERY		ROBINSON	
ligature behind the ankle	303	plastic operation on the palate	718
in lower third	303	ROBSON, MAYO	
the middle	303	repair of the crucial ligaments	608
POTT'S FRACTURE		ROSE	
arthrotomy of the ankle for	594	removal of the Gasserian ganglion	436
PRESSURE FORCEPS		ROUX	
Lynn Thomas's	79	subastragaloid disarticulations	187
PRIVATE DWELLINGS		SAC	
organization of operations in	27	obliteration of in endo-aneurysmorrhaphy	279
QUADRILATERAL GAPS		SCAPULA	
closure of, plastic surgery	662	excision of the	589
RACKET INCISION		SCARPA'S TRIANGLE	
amputation by	103	ligature of the femoral artery at the apex of	318
RADIAL ARTERY		SCIATIC	
ligature of the	344	artery. Ligature of the	336
RAUSCH AND SCHONEBERG		nerve. Exposure of the	464
bone grafting	530	SCROTAL WOUNDS	
RECTUM		asepsis in	25
disinfection of	20	'SEAT OF ELECTION'	
REGIONAL ANALGESIA		amputations at the	205
for goitre	37	by equal lateral skin-flaps	219
history of	31	by a large external flap (Farabeuf's method)	221
for removal of finger or toe	37		
REMOVAL OF SEMILUNAR CARTILAGES	603		

	PAGE		PAGE
SEMILUNAR CARTILAGES		SKIN GRAFTING (<i>continued</i>)—	
removal of the	603	preparation of area from which	
SEMIMEMBRANOSUS		grafts are to be taken	669
division of the tendon of the	483	preparation of the area to be	
SEMITENDINOSUS		grafted	667
division of the tendon of the	483	Reverdin's method	672
SEPSIS AND ORGANIZATION	8	Thiersch's method	670
SEPTIC		Wolfe's method	673
orifices. Disinfection of	20	SMITH, STEPHEN	
wounds. Cultural diagnosis of	28	disarticulation at the knee-joint	225
drainage of	28	SORES, SEPTIC	
SEQUESTROTOMY	518	disinfection of	20
after acute osteomyelitis	519	SPENCE	
in syphilitic necrosis	257	disarticulation at the shoulder-	
SEQUESTRUM		joint	148
due to acute osteomyelitis. Re-		SPINAL ACCESSORY NERVE	
removal of	519	exposure of the	454
in long-standing cases.	522	SPINAL ANALGESIA	40
syphilitic. Removal of	257	advantages of	41
tuberculous. Removal of	529	amount injected	60
SERA		Barker's solution for	47
infection treated by	3	Bier's solution for	47
SHOCK		canula for	56
influence on amputation	69	Chaput's solution for	47
SHOULDER-JOINT		densities of compounds used in	47
arthrodesis of the	588	difficulties in	43
arthrotomy and drainage of the	575	duration of	42
disarticulation at the	146	needles for	55
by the modified racket		SPONGES	
method	150	sterilization of	14
Spence's amputation	148	STERILIZATION	12
dislocations. Operations for		of catgut	14
recent	578	dressings, bandages, swabs,	
excision of the	581	garments, and towels	12
by Kocher's pos-		gloves	16
terior incision	586	instruments	12, 19
for ankylosis	582	marine sponges and swabs	14
for compound frac-		patient's skin	19
tures	581	silk and silkworm-gut	12
for tuberculous dis-		STERNO-MASTOID	
ease	581	division of	484
for unreduced dis-		STOKES-GRITTI	
locations	582	supra-condyloid amputation	235
fractures involving the	576	STOVAINE	
operation when fracture com-		amount used for spinal analgesia	60
plicates dislocation of the	577	for spinal analgesia	43
operation for dislocation of the	577	STUMP	
SILK		characters of a faulty	74
sterilization of	12	good	73
SILKWORM-GUT		conical	76
sterilization of	12	the future of the	94
SKIN GRAFTING	655, 664	SUBSTRAGALOID DISARTICU-	
disinfection of the skin	19	LATIONS	178
dressing and after-treatment	673	Farabeuf's	179
method of grafting	669		

	PAGE		PAGE
SUBASTRAGALOID DISARTICU- LATIONS (<i>continued</i>)—		TEMPORAL ARTERY	
Nélaton's	187	ligature of the	394
racket	188	TEMPORARY LIGATURE OF ARTERIES	77
Roux's	187	TENDO ACHILLIS	
SUBCLAVIAN ARTERY		division of the	475
ligature of the	368	TENDON	
SUBCUTANEOUS OSTEOTOMY .	509	biceps. Division of the	482
SUB-TROCHANTERIC OSTEO- TOMY	516	division of	473
SUPERIOR GLUTEAL ARTERY		flexor longus hallucis. Division of the	479
ligature of the	334	grafting	497
SUPERNUMERARY DIGITS		hamstring. Division of the	482
operations for	724	lengthening	493
SUPRA-CONDYLOID		Dawbarn's method	495
amputations	231	heteroplastic grafting	495
Stokes-Gritti's	235	Hibbs's method	494
osteotomy, Macewen's	511	oblique section	493
SUPRA-MALLEOLAR AMPUTA- TIONS	206	reflected slips	494
SUPRA-ORBITAL NERVE		the L-method	494
exposure of the	430	operations upon	473
SUTURE		peronei. Division of the	481
of an artery	265	semimembranosus. Division of the	483
a nerve	413	semitendinosus. Division of the sheath. Excision of a	503
obliterative, in endo-aneurys- morrhaphy	271	shortening	496
of tendons	487	sterno-mastoid. Division of the suture	484
primary	488	tendo Achillis. Division of the tibialis anticus. Division of the posticus. Division of the	475
secondary	492	transplantation	497
for relief of tension in plastic operations	660	TENOTOMY	
of the thoracic duct	408	of the biceps cruris	482
reconstructive, in endo-aneurys- morrhaphy	273	flexor longus hallucis	479
SWABS		hamstrings	482
sterilization of	12	peronei	481
SYME		semimembranosus and semitendinosus	483
disarticulation at the ankle-joint rhino-plastic operation	189 683	sterno-mastoid	484
SYNOVIAL MEMBRANE OF THE KNEE		tendo Achillis	475
removal of the	609	tibialis anticus	478
SYPHILITIC PALATE		posticus	479
plastic operations for	717	by the open method	474
SYSTEMIC CIRCULATION		subcutaneous method	475
reversal of the	280	TETANUS	
TABLES, OPERATING	10	amputation for	68
TALIPES		THEATRES	
equinus. Excision of astragalus in	597	operating	7
varus. Excision of astragalus for	598	THIERSCH	
TARSO-METATARSAL JOINT		method of skin-grafting	670
disarticulation at the	165	THIGH	
		amputation through the	239
		THORACIC DUCT	
		suture of the	408

	PAGE		PAGE
THUMB		UPPER ARM	
amputation of the	109	amputation through the, by	
THYREOID TUMOUR		antero-posterior flaps	143
regional analgesia for	37	by circular method	142
TIBIA		UPPER EXTREMITY	
osteotomy of the	513	amputations in	96
TIBIALIS ANTICUS		VACCINES	
division of the tendon of the	478	infections treated by	3
TIBIALIS POSTICUS		VARICOSE	
division of the tendon of the	478	aneurysm. Operation for	278
TILING AND PAULET		veins. Excision of varices	401
incision for unreduced shoulder		operations upon	399
dislocations	578	Trendelenburg's opera-	
TOES		tion	401
amputations of the	158	VARIX, ANEURYSMAL	
four outer. Disarticulation		operations for	278
at the metatarso-phalangeal		VEINS	
joints	164	arterio-venous anastomosis	398
hammer. Operations for	734	plastic operations upon	397
regional analgesia for removal		varicose. Mode of identifying	400
of the	37	operations upon	399
TOWELS		Trendelenburg's operation	401
sterilization of	12	VENESECTION	403
TRANS-CALCANEAL AMPUTA-		VERTEBRAL ARTERY	
TIONS		ligature of the	388
Gordon Watson's	200	WARD UNITS AND ASEPSIS	8
Le Fort's	199	WATSON, GORDON	
Pirogoff's	196	trans-calcaneal amputation	200
TRANS-CONDYLOID AMPUTA-		WATTS	
TIONS		cheiloplasty	701
by long anterior and short pos-		WEBBED FINGERS	
terior flaps	232	operations for	719
Lister's	233	Didot's	723
TRANSPLANTATION		division of the web	720
of tendon	497	triangular flap at base of web	722
TRENDELENBURG		WOLFE	
operation for varicose veins	401	method of skin-grafting	673
TRIANGULAR GAPS		WOUNDS	
closure of in plastic surgery	662	blood-clot in	24
TUBBY		drainage of	24
nerve-grafting	428	infection of	4
TUBERCULOUS SEQUESTRUM		scrotal. Asepsis in	25
removal of	529	septic. Cultural diagnosis of	28
ULCERS		drainage of	28
amputations for	67	testing by culture media	5
disinfection of	20	treatment of infected	28
ULNAR		WRIST	
artery. Ligature of the	350	disarticulation at the	116
nerve. Exposure of the	460	by an external flap	121
UNREDUCED DISLOCATION		excision of	561
of elbow. Operations for	569	WRIST AND HAND	
hip	646	amputations of the	96
shoulder.	579	WYETH'S PINS	80

OXFORD : HORACE HART
PRINTER TO THE UNIVERSITY





Author Burghard, F. F. (ed.) Med. 126504 Surg.
Title A system of operative surgery. Vol.1.

UNIVERSITY OF TORONTO
LIBRARY

Do not
remove
the card
from this
Pocket.

Acme Library Card Pocket
Under Pat. "Ref. Index File."
Made by LIBRARY BUREAU

